

# MOBILE PHONE RADIATION AND PUBLIC HEALTH

Maher Al-assaf<sup>1</sup>, Charif Barakat<sup>2</sup>

1. DDS - Msc, Department of Oral Pathology, Faculty of Dentistry, Damascus University, Damascus, Syria.

2. DDS - Msc - PhD, Department of Oral Pathology, Faculty of Dentistry, Damascus University, Damascus, Syria

## ABSTRACT:

Handheld mobile phones emit nonionizing electromagnetic radiations and generate heat during use which can be absorbed by the adjacent tissue. Mobile phones have become an integral part of modern communication methods. For years, debate has been raging about the dangers of radiation from mobile phones, and the researchers haven't come yet to a conclusion about the negative role of this radiation entering the human body, but what is agreed by all scientists is the presence of these radiations with different aspects of health problems. Electromagnetic fields caused by mobile phones are classified by the International Agency for Research on Cancer into (2b) i.e. maybe being carcinogenic to humans. That make the detection of the risks of these radiations a very important study.

**Keywords:** mobile phone, microwave radiation, cancer

## INTRODUCTION:

Electromagnetic spectrum, electromagnetic radiation, or electromagnetic waves all carry the same physical meaning. When talking about a special part of this spectrum such as visible light, x-rays and gamma rays, they are all rays known as electromagnetic radiation, but they differ in wavelength, and when the wavelength increases, the frequency decreases, and vice versa.<sup>[1]</sup>

The electromagnetic spectrum starts with radio waves which have long wavelength and low frequency, then the microwave area, followed by Infrared, Visible light, Ultraviolet, X-ray, Gamma-ray. This sequence is depending on the frequency increase of these waves, and each region of the electromagnetic spectrum has distinct characteristics.<sup>[1]</sup>

The Microwave radiation with frequency (300 MHz - 300 GHz) are located between the radio and infrared waves, i.e. in the area defined by non-ionizing radiation<sup>[2]</sup>, where the electromagnetic spectrum can be divided into two group:

- Ionizing radiation:

Which have sufficient energy to extract atoms from cells, such as gamma and x-rays, and these radiations undoubtedly cause damage to DNA.

- Non-ionizing radiation:

Which are unable to make changes in molecules and atoms or break chemical bonds, but cause high temperature of the part of the body exposed to, including radio waves, visible light and microwave radiations.<sup>[1]</sup>

*The general principle of how the mobile phone works:*

Non-ionizing radiation is widely distributed in the human environment; its most important source is the microwave radiation produced by mobile phones, with 6.9 billion subscriptions worldwide.<sup>[3],[4]</sup>

The communication process between mobile phones depends on two main factors: the mobile phone itself, and the base transceiver stations.<sup>[5]</sup>

The mobile phone is made up of a transmitter and receiver circuit. When a phone call is made, the mobile phone converts the sound waves to electrical signals, which carry by the radio waves to the nearest base transceiver station, which in turn transfers radio waves from transmitter phone to the receiver phone which turns radio waves into electrical signals that translate into sound again.<sup>[5]</sup>

#### THE POTENTIAL HEALTHY EFFECTS OF MICROWAVE RADIATION:

For years, debate has been raging about the dangers of radiation from mobile phones, and the researchers haven't come yet to a conclusion about the negative role of this radiation entering the human body, but what is agreed by all scientists is the presence of these radiations with different aspects of health problems.<sup>[6]</sup>

Electromagnetic fields caused by cell phones are classified by the International Agency for Research on Cancer (IARC) into (2b), i.e. They may be carcinogenic.<sup>[7],[8]</sup>

The potential effects of microwave radiation can be divided into two categories:

- Thermal effects:

When using a mobile phone, most of the thermal effect will occur on the surface of the head, causing increasing in temperature due to heating the water molecules in the tissue, and this rise in temperature can be classified directly at the level that precedes the rise of heat resulting from exposure to sunlight.

The blood circulation in the brain has the ability to get rid of excess heat by increasing the local blood flow, while the cornea does not have the mechanism itself to regulate the temperature, so the exposure to microwave radiation for 2-3 hours led to cataracts in the eyes of rabbits.<sup>[9]</sup>

- Non-thermal effects:

Studies that studied the non-thermal effects of microwave-radiation have supported the theory of increased oxidative stress in the tissue exposed to microwave radiation.

The researchers hypothesized that exposure to these radiations leads to increased levels of free radicals, and because they are chemically unstable compounds, they seek in any way to stabilize by stealing electrons. Once they attack a stable molecule and steal one of the electrons, the molecule itself becomes a free radical and thus attacks another stable molecule and produces a series of negative reactions that causes imbalance between free radicals and antioxidants and eventually damaging cells.<sup>[10]</sup>

This article reviews more than 30 papers published in the medical literature, and has been divided into three categories:

- The first category:

included articles that studied the effect of microwave radiation on oral and facial structures.

- The second category:

included articles that studied the effect of microwave radiation on different organs of the body.

- The third category:

included articles that studied the potential carcinogenic effects of microwave radiation on brain and parotid gland.

***Category 1:***

***Refer table at the end***

***Category 2:***

***Refer table at the end***

***Category 3:***

Since 2000, many studies have been conducted on mobile phone impact on public health, particularly the carcinogenic effects on the brain, salivary glands, auditory nerve and other tumors in the head and neck.<sup>[37]</sup>

In 2005, Lonn S et al., found that the results do not support the hypothesis that there is a relationship between mobile phone use and increased risk of Gliomas and Meningioma.<sup>[38]</sup>

In the same year, the Schoemaker M et al., study indicated that there is no significant risk of auditory nerve tumors after the first 10 years of mobile phone use, but this possibility can't be ruled out in long-term use.<sup>[39]</sup>

Then in 2006, Danish cohort study was conducted to discuss the relationship between use of mobile phones and cancer (brain, parotid gland, breast, gastric, pancreatic and bladder tumors). In this study more than 420,000 Danish citizens were followed up for 20 years, and there was no increase in the risk of cancer.<sup>[40]</sup>

**13-nation INTERPHONE:**

This study was conducted by the International Agency for Research on Cancer (IARC) in thirteen different countries, it's the largest study of its kind ever undertaken and did not find a solid link between mobile phone radiation and glioma, meningioma, and schwannoma. But the World Health Organization's IARC has classified the radiation emitted by mobile phones as "possibly carcinogenic to humans" (Class 2B).<sup>[41]</sup>

However, the previous series of studies can't fully explain the fact because it often takes several years between the use of the new risk factor -microwave radiation- and the observed increase in the incidence of tumors. According to this point, it is probably that the time elapsed to detect an increase in cancer rates directly attributable to mobile phone use is very little.<sup>[42]</sup>

In addition, many more studies are still up to this time. Because the parotid gland is placed in front of the ear and under the skin of the face directly, it is one of the most exposed tissues to the effect of radiation from the mobile phone<sup>[43]</sup>, therefore, studies have focused on the relationship between exposure to microwave radiation and tumors of the parotid gland. Some studies have shown that

parotid gland cancers are associated with exposure to mobile phone radiation.<sup>[43]</sup> However, these studies are still insufficient due to the limited exposure period.<sup>[44],[45]</sup>

Relating to this subject in Sweden, Hardell L et al., studied in 2004 whether mobile phone use was associated with the risk of parotid gland tumors. The results indicate that there is no association between the risk factor and the incidence of tumors, but Hardell explained that the exposure period is very limited to detect an increase in cancer rates that we can return directly to the use of mobile phones.<sup>[44]</sup>

Duan Y et al., found similar results in their 2011 study. Duan investigated the association of epithelial parotid gland malignancy due to use of cellular phone. The study group consisted of cases treated for parotid malignancy. Duan tried to compare between the frequency of mobile phone use (duration of daily use and the number of calls made per a day) and the end date of exposure, (date of histological diagnosis of the cancer). The results showed that there was no significant association found of epithelial parotid gland malignancy and frequency of mobile phone, and the association between mobile phone use and parotid gland malignancy requires further investigation.<sup>[46]</sup>

On the opposite side, Sadetzki S et al., investigated whether mobile phone use was associated with development of parotid gland tumors (PGTs). The study included 402 benign and 58 malignant incident cases of PGTs. Sadetzki reported that using mobile phones could increase the risk of developing parotid cancer by 50%, and that risk is increasing for people living in villages and

rural areas because the low number of transmission towers in the villages gives them higher energy, thus increasing radiation and higher of cancer rates.<sup>[43]</sup>

In order to obtain an inevitable result: these studies have recommended a long-term prospective study that involves taking a large number of people, allowing some of them to talk on their mobile phone as they want, preventing the other part from talking, and then following long-term health outcomes.<sup>(43)</sup>

## CONCLUSION:

Based on the findings of previous articles published in medical literature, it is concluded that the microwave radiation emitted from mobile phones had:

- Harmful effects on orofacial structures especially parotid gland, facial nerve, periodontal ligament, flow rate and concentrations of salivary proteins in the parotid gland product.
- Harmful effects on various tissues of the body especially brain, cerebellum and male reproductive system.
- While it was still unclear whether microwave radiation is associated with the development of different neoplasms in brain and parotid glands at the long term.

## REFERENCES:

1. Allison RR. The electromagnetic spectrum: current and future

- applications in oncology. *Future Oncology*. 2013;9(5):657-67.
2. Johansen C. Electromagnetic fields and health effects—epidemiologic studies of cancer, diseases of the central nervous system and arrhythmia-related heart disease. *Scandinavian journal of work, environment & health*. 2004;1-80.
  3. Rosado MM, Nasta F, Prisco MG, Lovisolo GA, Marino C, Pioli C. Effects of GSM-modulated 900 MHz radiofrequency electromagnetic fields on the hematopoietic potential of mouse bone marrow cells. *Bioelectromagnetics*. 2014;35(8):559-67.
  4. Hardell L. World Health Organization, radiofrequency radiation and health—a hard nut to crack. *International journal of oncology*. 2017;51(2):405-13.
  5. Hyland GJ. Physics and biology of mobile telephony. *The Lancet*. 2000;356(9244):1833-6.
  6. Levis AG, Minicuci N, Ricci P, Gennaro V, Garbisa S. Mobile phones and head tumours. The discrepancies in cause-effect relationships in the epidemiological studies—how do they arise? *Environmental Health*. 2011;10(1):59.
  7. IARC W. IARC classifies radiofrequency electromagnetic fields as possibly carcinogenic to humans. Press Release N: 208. 2011.
  8. Di Ciaula A. Towards 5G communication systems: Are there health implications? *International journal of hygiene and environmental health*. 2018.
  9. Council NR. *Effects of Electromagnetic Fields on Organs and Tissues*. 1993.
  10. Rööslü M, Lagorio S, Schoemaker MJ, Schüz J, Feychting M. Brain and Salivary Gland Tumors and Mobile Phone Use: Evaluating the Evidence from Various Epidemiological Study Designs. *Annual review of public health*. 2019;40.
  11. Daroit NB, Visioli F, Magnusson AS, Vieira GR, Rados PV. Cell phone radiation effects on cytogenetic abnormalities of oral mucosal cells. *Brazilian oral research*. 2015;29(1):1-8.
  12. Acar GO, Yener HM, Savrun FK, Kalkan T, Bayrak I, Enver O. Thermal effects of mobile phones on facial nerves and surrounding soft tissue. *The Laryngoscope*. 2009;119(3):559-62.
  13. Kaya FA, Dasdag S, Kaya CA, Akdag MZ. Effects of Radiofrequency Radiation by 900 MHz Mobile Phone. *Journal of Animal and Veterinary Advances*. 2008;7(12):1644-50.
  14. Dasdag S, Yavuz I, Bakkal M, Kargul B. Effect of long term 900 MHz radiofrequency radiation on enamel microhardness of rat's teeth. *Oral health and dental management*. 2014;13(3):749-52.
  15. Aydoğan F, Aydın E, Koca G, Özgür E, Atilla P, Tüzüner A, et al., editors. The effects of 2100-MHz radiofrequency radiation on nasal mucosa and mucociliary clearance in rats. *International forum of allergy & rhinology*; 2015: Wiley Online Library.

16. Saghiri MA, Orangi J, Asatourian A, Mehriar P, Sheibani N. Effect of mobile phone use on metal ion release from fixed orthodontic appliances. *American Journal of Orthodontics and Dentofacial Orthopedics*. 2015;147(6):719-24.
17. Mortazavi S, Daiee E, Yazdi A, Khiabani K, Kavousi A, Vazirinejad R, et al. Mercury release from dental amalgam restorations after magnetic resonance imaging and following mobile phone use. *Pak J Biol Sci*. 2008;11(8):1142-6.
18. Aydogan F, Unlu İ, Aydin E, Yumusak N, Devrim E, Samim EE, et al. The effect of 2100 MHz radiofrequency radiation of a 3G mobile phone on the parotid gland of rats. *American journal of otolaryngology*. 2015;36(1):39-46.
19. Ghoneim FM, Arafat EA. Histological and histochemical study of the protective role of rosemary extract against harmful effect of cell phone electromagnetic radiation on the parotid glands. *Acta histochemica*. 2016;118(5):478-85.
20. Anan H, Gawish M, Amer M, Ibrahim N. Effects of low magnetic irradiation on morphology and ultrastructure of parotid glands in rats and amelioration by vitamin E. *J Cytol Histol*. 2012;3:139.
21. Goldwein O, Aframian D. The influence of handheld mobile phones on human parotid gland secretion. *Oral diseases*. 2010;16(2):146-50.
22. Shivashankara AR, Joy J, Sunitha V, Rai MP, Rao S, Nambranathayil S, et al. Effect of cell phone use on salivary total protein, enzymes and oxidative stress markers in young adults: a pilot study. *Journal of clinical and diagnostic research: JCDR*. 2015;9(2):BC19.
23. Hashemipour M, Yarbakht M, Gholamhosseinian A, Famori H. Effect of mobile phone use on salivary concentrations of protein, amylase, lipase, immunoglobulin A, lysozyme, lactoferrin, peroxidase and C-reactive protein of the parotid gland. *The Journal of Laryngology & Otology*. 2014;128(5):454-62.
24. Ranjitha GE, Austin RD, Ramasamy S, Bharathi CS, Angeline D, Sambasivam S. Influence of Handheld Mobiles on Parotid: A Cohort Study. *Journal of Indian Academy of Oral Medicine and Radiology*. 2018;29(4):254.
25. Helal M, Abdelrahman M. Ki-67 Expression on Major salivary Gland Exposed to Mobile Cell phoneradiation. *EDJ*. 2012;58(3).
26. Kesari KK, Kumar S, Behari J. 900-MHz microwave radiation promotes oxidation in rat brain. *Electromagnetic biology and Medicine*. 2011;30(4):219-34.
27. Grafström G, Nittby H, Brun A, Malmgren L, Persson BR, Salford LG, et al. Histopathological examinations of rat brains after long-term exposure to GSM-900 mobile phone radiation. *Brain research bulletin*. 2008;77(5):257-63.
28. Dogan M, Turtay M, Oguzturk H, Samdanci E, Turkoz Y, Tasdemiir S, et al. Effects of electromagnetic radiation

- produced by 3G mobile phones on rat brains: magnetic resonance spectroscopy, biochemical, and histopathological evaluation. *Human & experimental toxicology*. 2012;31(6):557-64.
29. Ghatei N, Nabavi AS, Toosi MHB, Azimian H, Homayoun M, Targhi RG, et al. Evaluation of bax, bcl-2, p21 and p53 genes expression variations on cerebellum of BALB/c mice before and after birth under mobile phone radiation exposure. *Iranian journal of basic medical sciences*. 2017;20(9):1037.
  30. Erogul O, Oztas E, Yildirim I, Kir T, Aydur E, Komesli G, et al. Effects of electromagnetic radiation from a cellular phone on human sperm motility: an in vitro study. *Archives of medical research*. 2006;37(7):840-3.
  31. Ghanbari M, Mortazavi SB, Khavanin A, Khazaei M. The effects of cell phone waves (900 MHz-GSM band) on sperm parameters and total antioxidant capacity in rats. *International journal of fertility & sterility*. 2013;7(1):21.
  32. Al-Damegh MA. Rat testicular impairment induced by electromagnetic radiation from a conventional cellular telephone and the protective effects of the antioxidants vitamins C and E. *Clinics*. 2012;67(7):785-92.
  33. Erdemli C, Omeroglu S, Sirav B, Colbay M, Seyhan N, Ozkan S, et al. Effects of 2100 MHz radio frequency radiation on ductus epididymis tissue in rats. *Bratislavske lekarske listy*. 2017;118(12):759-64.
  34. Kerimoğlu G, Mercantepe T, Erol H, Turgut A, Kaya H, Çolakoğlu S, et al. Effects of long-term exposure to 900 megahertz electromagnetic field on heart morphology and biochemistry of male adolescent rats. *Biotechnic & Histochemistry*. 2016;91(7):445-54.
  35. Mortazavi S, Owji S, Shojaei-Fard M, Ghader-Panah M, Mortazavi S, Tavakoli-Golpayegani A, et al. GSM 900 MHz Microwave Radiation-Induced Alterations of Insulin Level and Histopathological Changes of Liver and Pancreas in Rat. *Journal of biomedical physics & engineering*. 2016;6(4):235.
  36. Ozguner F, Aydin G, Mollaoglu H, Gökalp O, Koyu A, Cesur G. Prevention of mobile phone induced skin tissue changes by melatonin in rat: an experimental study. *Toxicology and Industrial Health*. 2004;20(6-10):133-9.
  37. Organization WH. The International EMF Project: health effects of static and time varying electric and magnetic fields: progress report 1998-1999. Geneva: World Health Organization, 1998.
  38. Lönn S, Ahlbom A, Hall P, Feychting M. Long-term mobile phone use and brain tumor risk. *American journal of epidemiology*. 2005;161(6):526-35.
  39. Schoemaker M, Swerdlow A, Ahlbom A, Auvinen A, Blaasaas K, Cardis E, et al. Mobile phone use and risk of acoustic neuroma: results of the Interphone case-control study in five North

- European countries. *British Journal of Cancer*. 2005;93(7):842.
40. Schüz J, Jacobsen R, Olsen JH, Boice Jr JD, McLaughlin JK, Johansen C. Cellular telephone use and cancer risk: update of a nationwide Danish cohort. *Journal of the National Cancer Institute*. 2006;98(23):1707-13.
41. INTERPHONE. Brain tumour risk in relation to mobile telephone use: results of the INTERPHONE international case-control study. *International journal of epidemiology*. 2010;39(3):675-94.
42. Bortkiewicz A, Gadzicka E, Szymczak W. Mobile phone use and risk for intracranial tumors and salivary gland tumors-A meta-analysis. *International journal of occupational medicine and environmental health*. 2017.
43. Sadetzki S, Chetrit A, Jarus-Hakak A, Cardis E, Deutch Y, Duvdevani S, et al. Cellular phone use and risk of benign and malignant parotid gland tumors—a nationwide case-control study. *American journal of epidemiology*. 2007;167(4):457-67.
44. Hardell L, Hallquist A, Mild KH, Carlberg M, Gertzen H, Schildt E-B, et al. No association between the use of cellular or cordless telephones and salivary gland tumours. *Occupational and environmental medicine*. 2004;61(8):675-9.
45. Söderqvist F, Carlberg M, Hardell L. Use of wireless phones and the risk of salivary gland tumours: a case-control study. *European Journal of Cancer Prevention*. 2012;21(6):576-9.
46. Duan Y, Zhang H, Bu R. Correlation between cellular phone use and epithelial parotid gland malignancies. *International journal of oral and maxillofacial surgery*. 2011;40(9):966-72.
47. Shizukuishi S, Hanioka T, Tsunemitsu A, Fukunaga Y, Kishi T, Sato N. Clinical effect of coenzyme Q10 on periodontal disease; evaluation of oxygen utilisation in gingiva by tissue reflectance spectrophotometry. In: *Biomedical and Clinical Aspects of coenzyme Q*. Amsterdam: Elsevier; 1986;5:359-68.
48. McRee JT, Hanioka T, Shizukuishi S, Folkers K. Therapy with coenzyme Q10 for patients with periodontal disease. *J Dent Health* 1993;43:659-66.
49. Littarru GP, Nakamura R, Ho L, Folkers K, Kuzell WC. Deficiency of coenzyme Q10 in gingival tissue from patients with periodontal disease. *Proc Natl Acad Sci U S A* 1971;68:2332-5.
50. Hans M, Prakash S, Gupta S. clinical evaluation of topical application of perio-Q gel(coenzyme Q10) in chronic periodontitis patients. *Journal of Indian society of periodontology*. 2012; 16(2):193
51. Chaudhry S, Vaish S, Dodwad V, Arora A. Natural antioxidant: Coenzyme Q10 (Perio Q) TM in management of Chronic Periodontitis: A Clinical Study. *Int J Dent Health Sci*. 2014;1(4):475-84.



**Category 1:**

Author/year	Type of Study	Purpose of study	Study summary	Results
<b>Daroit NB et al., 2015 (11)</b>	Human study	Effect of mobile phone radiation on oral mucosal cells.	Cells were obtained from mobile phone users: lower lip, border of the tongue, and floor of the mouth	individuals using mobile phone for more than 60 minute/week for eight years had increased nuclear abnormalities: karayorrhesis, binucleated and micronuclei.
<b>Acar GO et al., 2009 (12)</b>	Animal study/ Rabbits	Effect of mobile phones generated heat on facial nerves (FN)	Mobile phone (1900 MHz) was kept for 25 minutes over the ipsilateral ear of the rabbit.	temporary dysfunction of facial nerve occurs due to exposure to mobile phone, and that exposure warms up the surrounding oft tissue.
<b>Kaya FA et al., 2008 (13)</b>	Animal study/ Wistar Albino Rats	Investigated the effects of microwave radiation emitted by mobile phone on periodontal tissues	Rats were exposed to radiations (900 MHz) for two hour/day for 10 months	Mobile phones radiations affect the periodontal tissues, because there are many pathological changes: vasodilatation and focal bleeding areas were determined in periodontal ligament, alveolar bone and gingiva.
<b>Dasdag S et al., 2014 (14)</b>	Animal study/ Wistar Albino Rats	Effect of mobile phone radiations on the micro hardness of enamel of rat teeth.	Rats enamel was exposed to the mobile phone emitted radiation (900MHz) for 2 hours/day for 10 months.	The trace elements of enamel (Ca, Mg, P, Zn) were affected by 900 MHz mobile phone radiation, but the enamel micro hardness was not changed.
<b>Aydogan F et al., 2015 (15)</b>	Animal study/ Wistar Albino Rats	Effect of mobile phone radiations on the nasal mucosa and mucociliary clearance.	The nasal mucosa was examined using a transmission electron microscope after exposed to 2100 MHz for 6 hours/day for 40 days.	The exposure groups showed a number of degenerated and apoptotic cells, ciliary disorganization and ciliary loss in the epithelial cells, epithelial metaplasia, alteration of normal chromatin distribution and karyolysis in nuclei, changes in the basal

				cells, and lymphocytic infiltration.
<b>Saghiri MA et al., 2015 (16)</b>	Human study	The level of nickel released in saliva due to exposure to microwave radiation emitted by mobile phones was studied.	Control group: Saliva samples collected from patients with fixed orthodontic appliances that had not used their cell phones for a week. Experimental group: the time of mobile phone use for the next week was recorded and another saliva sample was taken.	Results showed that the level of nickel in experimental group were higher than in the control group with statistically significant differences.
<b>Mortazavi SM et al., 2008 (17)</b>	Human study	The level of mercury released in saliva from amalgam restorations due to exposure to microwave radiation emitted by mobile phones was studied.	Saliva samples were collected from volunteers with amalgam restorations and mobile phone using (experimental group). And saliva samples from the same patients were collected but with a one-week break without using mobile phone before conducting the experiment (control group).	Results showed that the level of mercury in experimental group were higher than in the control group with statistically significant differences.
<b>Aydogan F et al., 2015 (18)</b>	Animal study/ Wistar Albino Rats	Studied the effect of 2100 MHz radiation on the histological structure of parotid gland.	The experimental group was exposed to mobile phones for six hours/day for 40 days.	Histopathological changes were observed in Parotid gland: necrosis in epithelial cells, increase in interstitial space, damage in ductal and vascular system, abnormalities in nucleus, and variations in cell size.
<b>Ghoneim FM et al., 2016 (19)</b>	Animal study/ Albino rats	The parotid gland exposed to mobile phones was studied and the antioxidant activity of rosemary against radiation was investigated.	Group 1 (control), group 2 (rosemary treated), group 3 (exposed to mobile phone) and group 4 (exposed to mobile phone and treated with rosemary).	Rosemary has antioxidant property and it could play a protective role against the harmful effect of the radiation emitted by mobile phone.
<b>Anan H et al., 2012</b>	Animal study/	Investigation of the antioxidant	Group 1 (control), group 2 (exposed to microwave	Degeneration of parotid gland acini and ducts

<b>(20)</b>	Albino rats	activity of vitamin E in parotid gland after exposed to mobile phone.	radiation), and group 3 (exposed to mobile phone and treated with daily doses of vitamin E directly before exposure).	together with cellular infiltrations, fibrosis and mucous transformation of the acinar cells were detected after exposure to mobile phone. These changes were limited with vitamin E supplementation in group 3.
<b>Goldwein O et al., 2010 (21)</b>	Human study	Studying the flow rate of saliva after exposed to mobile phone.	The stimulated salivary samples from parotid gland of healthy individuals were collected.	Exposure to microwave radiation increased salivary flow rate, but However, this increase was low in protein secretion due to continuous and cumulative damage to the glands.
<b>Shivashankar a AR et al., 2015 (22)</b>	Human study	Studying the concentration of salivary enzymes in the parotid glands of volunteers using mobile phones.	Saliva samples were evaluated for amylase, lactate dehydrogenase (LDH), malondialdehyde (MDA) and glutathione (GSH).	Significant changes in salivary enzymes and MDA suggest adverse effect of high use of cell phones on cell health
<b>Hashemipour MS et al., 2014 (23)</b>	Human study	Studied the effect of radiations on parotid glands of individuals using mobile phone.	Individuals using mobile phones were included in study and their stimulated salivary samples were collected from both the parotid glands.	Salivary flow rate and concentrations of protein from parotid gland were significantly higher on the right side compared to the left in those that predominantly held mobile phones on the right side. In addition, there was a decrease in concentrations of amylase, lipase, lysozyme and lactoferrin.
<b>Ranjitha GE et al., 2018 (24)</b>	Human study	Mobile phone induced physiologic changes in the	Ultrasonography of was performed bilaterally to measure gland volume. Systolic velocity of the external carotid artery in	The volume, systolic velocity of blood flow of the external carotid artery, the salivary flow rate, and protein

		parotid gland was studied.	gland was calculated bilaterally using color Doppler imaging. Saliva flow rate was measured bilaterally by Carlson-Crittenden device, and biuret assay was done to determine the protein concentration.	concentration of the parotid gland were significantly more by 11.9, 18, 23, and 8%, respectively, on the dominant side than the nondominant side of mobile phone usage.
<b>Helal M et al., 2012 (25)</b>	Animal study/ guinea pigs	Immunohistochemical Study to find out the effects of mobile phone radiation on the major salivary glands.	The acute exposed group subjected to mobile phone device 2h/day for 3 months while the chronic exposed one subjected to 2h every week for the same period. Parotid, submandibular and sublingual salivary gland specimens were prepared for immune stained of Ki-67 antigen.	Gradual increases of nuclear immune-staining of Ki-67 as the exposure to mobile phone increased, and the serous acini were sensitive than mucous one.

**Category 2:**

Author/year	Type of Study	Purpose of study	Study summary	Results
<b>Kesari KK et al., 2011 (26)</b>	Animal study/ Wistar Albino Rats	Studying the effects of 900 MHz microwave radiation on the brain.	The animals exposed to microwave radiation for 2 hours/day for 45 days.	Increase in antioxidative enzyme activities, protein kinase C, melatonin, caspase 3, and creatine kinase are related to overproduction of reactive oxygen species (ROS) in animals under mobile phone radiation exposure.
<b>Grafstrom G et al., 2008 (27)</b>	Animal study/ Rats	Studying the effects of 900 MHz microwave radiation on the brain.	The animals exposed to microwave radiation for 2 hours/week for 55 weeks. the brains were evaluated for histopathological alterations such as albumin extravasation, dark neurons, lipofuscin aggregation and signs of cytoskeletal and neuritic neuronal changes.	No significant alteration of any histopathological parameters was found.

<b>Dogan M et al., 2012 (28)</b>	Animal study/ Rats	Studying the effects of 2.45 GHz microwave radiation on the brain.	The animals exposed to microwave radiation for 20 min/day for 20 days. Histopathological analyses were carried out to evaluate apoptosis in the brain tissues.	The number of apoptotic cells were no significantly different between groups.
<b>Ghatei N et al., 2017 (29)</b>	Animal study/ Rats	Studying the bax, bcl-2, p21 and p53 genes expression variations on cerebellum of mice before and after birth under mobile phone radiation exposure.	Animals were exposed to microwave radiation at two different frequencies (900 and 1800 MHz) and two different time periods (prenatal and postnatal).	Gene expression of bax and P53 was increased in cerebellar during pregnancy than in after birth, so it was concluded that cerebellar tissue was more sensitive to exposure to these waves in pregnancy period.
<b>Erogul O et al., 2006 (30)</b>	in vitro study	Studying the effects of 900 MHz radiation on human sperm motility	The sample was collected from 27 healthy volunteers.	There was a slight decrease in sperm motility, but there was no decrease in the sperm concentration between the groups.
<b>Ghanbari M et al., 2013 (31)</b>	Animal study/ Wistar rats	Studying the effects of 900 MHz radiation on human sperm Parameters and Total Antioxidant Capacity.	Group 1: control, Group 2: two-week exposure to mobile phone, Group 3: three-week exposure to mobile phone.	The results indicated that sperm viability, motility, and total antioxidant capacity in all exposure groups decreased significantly compared to the control group.
<b>Al-Damegh MA., 2012 (32)</b>	Animal study/ Rats	Studying the effects of microwave radiation on the histological structure of testicular, and the role of antioxidants vit C and E.	The treatment groups were exposed to microwave radiation, microwave radiation plus vitamin C (40 mg/kg/day), microwave radiation plus vitamin E (2.7 mg/kg/day). All groups were exposed to the same radiation frequency for 15, 30, and 60 min daily for two weeks.	The effect of the microwave radiation had a negative impact on testicular architecture. possible role of vitamins C and E in mitigating the oxidative stress imposed on the teste.
<b>Erdemli C et al., 2017 (33)</b>	Animal study/ Wistar Albino Rats	Studying the effects of 2100 MHz microwave radiation on	The animals exposed to microwave radiation for 30 min/day for 2 months.	Reduction in sperm density in some of the channels drew an attention, loss of connective tissue and

		ductus epididymis tissue.		vascularization was highly increased due to high expression of vascular endothelial growth factor (VEGF).
<b>Kerimoglu G et al., 2016 (34)</b>	Animal study/ Rats	Studying the effects of 900 MHz microwave radiation on heart morphology.	The animals exposed to microwave radiation for 60 min/day for 2 months.	Structural alteration of heart tissue: H&E stained exhibited structural changes and capillary congestion in the myocardium and apoptosis in some myocardial cells. Transmission electron microscopy of myocardial cells showed altered structure of Z bands, decreased myofilaments and pronounced vacuolization.
<b>Mortazavi S et al., 2016 (35)</b>	Animal study/ Sprague Dawley rats	Studying the histopathological changes of liver and pancreas after exposed to 900 MHz microwave radiation.	Group1: exposed to microwave radiation 6 hour/day for 7 days. Group 2: sham exposure. Groups 3: exposed to microwave radiation 3 hour/day for 7 days. Group 4: sham exposure.	Mild to severe inflammatory changes in the portal spaces of the liver as well as damage in the cells of islet of Langerhans were observed.
<b>Ozguner F et al., 2004 (36)</b>	Animal study/ Wistar Albino Rats	Studying the Prevention of mobile phone induced skin tissue changes by melatonin.	Group 1: nontreated control group. Group 2: exposure group without melatonin. Group 3: not exposure with melatonin. 900 MHz microwave radiation was applied to exposure group 30 min/day for 10 days. The exposure plus melatonin group received 10 mg/kg per day melatonin in tap water for 10 days before exposure.	increased thickness of stratum corneum, atrophy of epidermis, papillomatosis, basal cell proliferation, increased granular cell layer and capillary proliferation, impairment in collagen tissue distribution and separation of collagen bundles in dermis were all observed. Melatonin treatment can reduce these changes and may have a beneficial effect to prevent 900 MHz mobile phone-induced rat skin changes.

**FIGURES:**

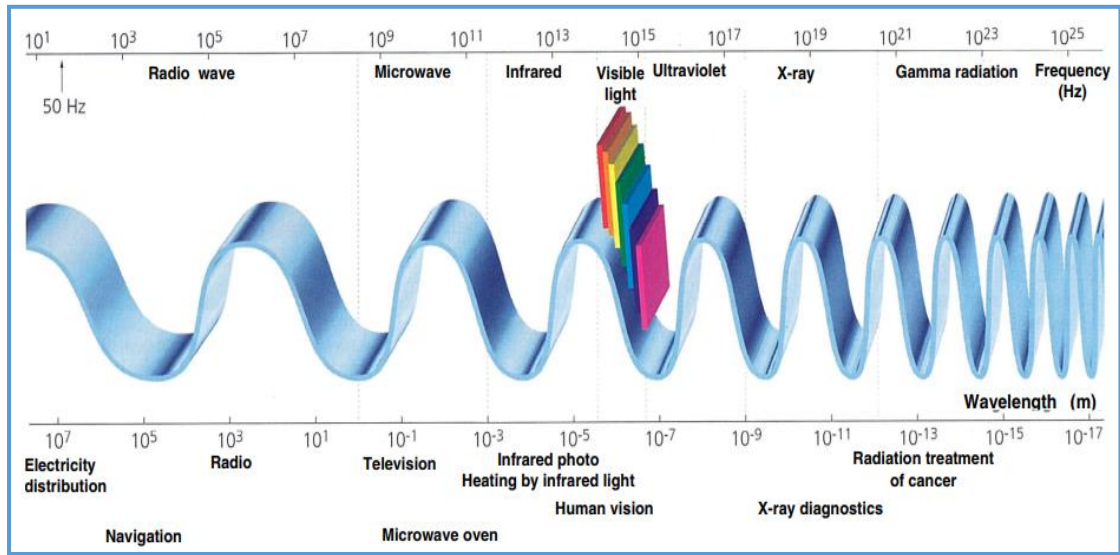


Figure 1: shows the electromagnetic field and the location of microwave radiation <sup>(2)</sup>