

THE USAGE OF CRYOSURGERY WITH LIQUID NITROGEN IN MANAGEMENT OF GINGIVAL MELANIN PIGMENTATION

Ammar Ammon¹, Nora Jawdat Ali²

1. Professor- Department of Oral Medicine - Faculty of Dentistry- Tishreen University- Latakia-Syria

2. MSc student, Department of Oral Medicine, Faculty of Dentistry, Tishreen University, Lattakia, Syria.

ABSTRACT:

The aim of the study was to assess the effect of cryosurgery by means of liquid Nitrogen LN to manage the aesthetic problem caused by gingival melanin Pigmentation (GMP). The study is composed of 20 patients who attended the department of oral medicine at Tishreen University, Lattakia- Syria. Their chief complaint was GMP between November 1st 2013 and April 1st 2016. The clinical observation included capturing photographs pre-procedure and 3 months, 6 months and a year post-procedure. Dummett Oral Pigmentation Index (DOPI) was used as a reference to indicate the colour of the pigmented areas degrees, and statistical analysis was performed by T-student test for paired samples. Ablation of hyperpigmented gingiva was accomplished with minimal discomfort and post-procedure healing was uneventful and with no post-pain. Such statistical study revealed a significant difference between pre- and post-procedure measurements of pigmented areas. In conclusion, the application of cryosurgery using LN appears to be an effective and safe method for elimination of GMP.

Key words: gingival melanin pigmentation, cryosurgery, liquid Nitrogen.



INTRODUCTION

The demands of well appearance increases which leads intern to more asking about dental esthetics treatments (Kumar,2012). The color of the gingiva is determined by several factors, namely number and size of the blood vessels, epithelial thickness, quantity of keratinization and pigments within the gingival epithelium. Melanin, carotene, reduced hemoglobin and oxyhemoglobin are the main pigments contributing to the normal color of the oral mucosa (Tal et al. 2003).

Melanin changes gingival color to brown. It is the basic nature intraoral epithelium die which mainly affect the gingiva color. Its production is basically from melanin cells. Which located at

integrated basal cells and supra basal cells layer of epithelium. (Cicek,2003;Dummett,1980) Usually melanin cells are noticed and seen in large amounts at incisal oral mucosa region. (Perlmutter,1986)

The physiological discoloration of oral mucosa(i.e. gingiva) is clinically defined as melanin pigmentation on several spots or wide spread areas(Dummett,1960; Dummett,Barens,1967) in all human races (Page et al.1977).^[1-6]

It definitely well known that over production of melanin at dark and black skin people is basically the result of increasing the activity of melanin cells

which induced genetically. At dark and black skin raises the melanin cells are highly inductive, whilst have a variable activity in white once (Schroeder,1969; Szako et al. 1969).

Clinically, melanin pigmentation is benign and does not present any medical problems. The patients' chief complaint is basically dark skin, and unaesthetic problem during speech or smiling (Dummett et al. 1980).

In medical literatures, many methods were suggested to remove gingival pigmentation. Some of them were surgical and others chemical. Recently, Cryosurgery and laser were used to achieve such target.

Cryosurgery is defined as a meditative treatment which used frozen principle to induce inflammatory reaction with/without destructive reaction. This technique is used in many dermatological cases. It could also be applied in oral cavity, because of its moisture and softness properties. It is considered the best place for Cryosurgery application. Its application resulted in best results and well appearance in treatment physiological melanin pigmentation, and could be the technique which replaced traditional surgery (Bansal et al.2012). Cryosurgery application needs a light cooling factor(cryogen). There are many frozen factors includes: liquid nitrogen(-196), nitro oxide(-89), solid carbon dioxide(-78), chloride aifloro methan(-41), and day

methi eyther in addition to broban (-24, -42) (Sharma,Kandhpur,2009).

As cold sensitivity differs among tissues, melanin cells are the most sensitive once to cryogen, followed by basal cells, then keratinized tissues, after that bacteria, connective tissues of the nerve cords to be at its least in viruses (Jackson et al. 1992).

The quantity of the cooling factor and the choice to usage method is up to the size of pigmented area, tissues type and the frozen depth. There are also many factors which related to the patient: thickness of dermal layer and its lining components, skin internal water quantity and amount of localized blood supply (Tal et al. 1987).^[7-12]

Methods of application:

- Dipstick method.
- Spray technique
- Cryoprobe technique.

In spray technique, or as it is known open spray method, a special frozen unit is used in two ways handled or placed at a table. The unit is full filled with liquid nitrogen and supplied wish many spray heads with different sizes which are used in accommodation with borders of the affected pigmented area

The spray head is placed at (1 cm) distance of the affected area surface. A medium spray touch is applied at center of the defect. The frozen time starts when the ice formed. Its formation

begins from the center to cover all parts of pigmented area. The defect is retained and ice ball is melted to the room temperature in time usually double the frozen once (Kumar et al. 2012)..

Clinical changes after cryosurgery:

Tissues frosted to have a solid form of an ice ball. The iced tissues began to melt after (15-20) seconds. Which develops from the border to the ball's center.

During the first twelve hours, treated area was filled by a light white liquid membrane, and surrounded by a red area. Within

(24) hours, the defect was healed, and a smooth surface under it was seen. Treated membrane could be easily seen at borders.

The reparation and recurrent of underlying dermal layer removed the membrane and leaved a cleaned smooth surface (Sheetra et al. 2012).

In 1970 Mayer et al. made an investigation to study clinically gingival tissues reaction to the frozen. They noticed undifferentiated multinuclear cells near frosted area after (12) hours of treatment application. They also found that healing occurred after (24-48) hours of treatment application (Kumar et al. 2012).

Tal et al, treated in a selective method the dermal layer which cover gingival slides by using a huge over soldering

technique for (5 sec). Such treatment was done by means liquid nitrogen (-81°C). They concluded that over cold dosage may cause destructive for oral gingiva without cause any morphological noticeable changes at special underlying plate (Kumar et al. 2012).

In a (2-5) years clinical study by Haim et al. after surface treatment of cryosurgery for middle to highly gingival pigmentation for (7) non-smoker patients. Areas on which cryoprobe was applied, had been frozen to (-81°C) for (10) seconds. The patients did not complaint from any side effects nor postoperative pain for (5) years follow up. Cryosurgery is an effective and simple method used to remove gingival pigmentation (Tal et al. 1987).

Chin-Jyh Yeh, treated (20) patients who were suffering from abnormal location of melanin in association with dark gingival color. Treatment was applied by direct application of liquid nitrogen wish cotton stick for (20-30) seconds. Their results presented normal gingiva color after (1-2) weeks after (1-2) times of treatment application. Patients presented well compatible of such treatment method, and its results were excellent. This technique could be considered simple, none bleeding, effective for gingival pigmentation removal, no local anesthesia and did not need any complicated equipment (Yeh,1998).

Faith Arikan, applied cotton stick which is cooled by means of tetraflourethan to

make cryosurgery for gingival pigmentation removal. They concluded that the usage of TFE as a product was not effective to treat simple cases of gingival melanin pigmentation (Kumar et.al. 2012).^[12-16]

Shaees ta ka, made cryosurgery by means of maxilla anterior section gingival slides (5w-5w) size, which was treated to cold probe and usage of nitrogen gas and the probe was cooled (-70,-90) for (30)seconds.

The aim and importance of study:

The aim of study: This study aimed to investigate the effectiveness of cryosurgery in physiological gingival pigmentation removal.

Importance of investigation: The strong point of our research is basically its consideration about the esthetic appearance of the patients by trying to remove the physiological melanin pigmentation which affects the appearance badly.

In our study we tried to find out an effective easy way to remove such pigmentation in dental clinics.

MATERIALS AND METHODS

Study design: This study was designed as an anticipatory, future, clinical random investigation.

Sample: 20 patients from different ages who are suffering from varied degrees of physiological melanin pigmentation. All the patients were visitors to the oral

medicine department- faculty of dentistry – Tishrin University during first October 2013 till first April 2016.

Patients' treatment approval was taken. They were delivered the study questionnaire to fill. The specimens were divided randomly in two equal parts 10 per each.

Treatment plane was applied on upper jaw at first group, and on the mandible at the second once.

Inclusion and exclusion criteria:

Inclusion criteria :the patient who are suffering from different degrees of physiological gingival pigmentation which affected their appearance badly, and good oral hygiene.

Exclusion criteria: Patients with systemic disease which may affect surgery healing. Also who made same previous melanin pigmentation removal, smokers, pregnant and melanin tumor were excluded.

Materials:

Surgical room and surgery room: The surgical part of this investigation was made at oral medicine clinic - faculty of dentistry- Tishreen University- Syria- Lattakia for all cases. The room was supplied with dental unit, test pulp vitality, ultrasonic device(used for scaling) and nitrogen application unit. This unit was in half liter size and supplied by a special head for intraoral application to transfer and store

nitrogen. Also cheek retractors and red wax plates were used to isolate teeth.

Photography: Cleared standard digital photos were taken before, after and during follow up at distinct periods were taken. They allowed a proper documentation and cleared evaluation for each case. Photos were taken with same protocol, camera and photographer.

Photographer: The researcher captured the whole included images by herself.

Capturing protocol: All patients were at half sleepy posture. All images were taken after retracting cheeks and lips and dryness the pigmented mucosa. The light in which the photos were taken was the day light without any additions of it to the working field.

Used camera:It was Sony D6503 which was handles at Sony Z2 mobile device. Such camera was used to capture the whole research included pictures'.

Methods:

Methods of research: Gingival status was evaluated for all the specimens before one week of treatment application. Scaling was made for whom were suffering from gingivitis, and they were given oral care instructions.

The lips were retracted immediately before nitrogen application. Index DOPI value was taken. Teeth were isolated by means of red wax plates. It was placed directly at teeth necks and gingival

borders without any coverage of gingival papilla and free gingival parts.

To apply nitrogen, the colder unit was handled, and placed directly in front of surface treatment. The head's nitrogen unit was placed at (1) cm distance away from gingival margin. The gas was spread until an ice ball was formed superiorly to the gingiva. The spray should cover the whole surface treatment.

After the ice ball was melted an images was taken. Figs (1,2,3,4).

Research variables:

1. The degree of gingival pigmentation reduction. Dummett Oral Pigmentation Index (DOPI).
2. Postoperative pain.

The degree of gingival pigmentation reduction: In our study we use Dummett Oral Pigmentation Index (DOPI)(table1)

This index was taken after 3, 6 months and one year after treatment session.

Postoperative pain:

It was determined by asking patients about pain occurrence at the day next treatment session and getting their answers yes or no.

Sample distribution:

All the results were statistically analyzed by means of SPSS(Statistical Package For Scientific Studies) version 16. T- test was

used to compare the values before and after(3-6) and on year after treatment.

The sample included of 20 patient (9 males,11 females) at ages between (20-33) years old.(fig.5)(table 2)

RESULTS:

Statistical results:

Degree of gingival pigmentation reduction after treatment:

The table 3 shows absence of pigmentation in twelve cases out of twenty cases have been treated on both jaws based on DOPI values. The percentage of maxillary sample distribution and percentage of mandible sample distribution are showed in fig.(6),fig.(7) in order.

By testing the hypothesis that says "no relationship between DOPI value before and after the treatment" versus the hypothesis that says "there is a relationship"- where we used paired student T-test – significance of the test was (0) at the significance level (5%). That means "the zero hypothesis is true" and there is an improvement. And the same results appeared 6 months and 12 months post treatment that has been served maxilla.

By testing the hypothesis that says "no relationship between DOPI value before and after the treatment" versus the hypothesis that says "there is a relationship"- where we used paired student T-test – significance of the test was (0) at the significance level (5%).

That means "the zero hypothesis is true" and there is an improvement. And the same results appeared 6 months and 12 months post treatment that has been served mandible.

Postoperative pain:

No pain was registered after treatment. Only two cases of discomfort from eating hot food were noticed.

DISCUSSION :

We noticed after (3) months of Nitrogen application on mandible pigmented gingiva with DOPI index values complete absence of gingival pigmentation in (5) cases (25%), improvement in gingival color in (3) samples (15%), and mild gingival color defect (5%), and

After (6) months (4) cases (20%) retained without pigmentation recurrent, and 2 mild pigmentation just (1) case (5%) medium pigmentation.

The results were fixed after (1) year.

CONCLUSION:

The usage of cryosurgery by means of liquid nitrogen to remove melanin gingival pigmentation is completely a safe method, well compatible from patient and easy to be applied.

Cryosurgery is an effective method on both upper and lower jaws, and resulted in completely removal of gingival pigmentation or a noticeable improvement in color of the gingiva(healthy, pink).

Recommendations: We strongly recommend to use cryosurgery by means of liquid nitrogen to treat and removal melanin gingival pigmentation.

We suggest to make future researches to study the relationship between the treatment place and improvement of gingival colour.

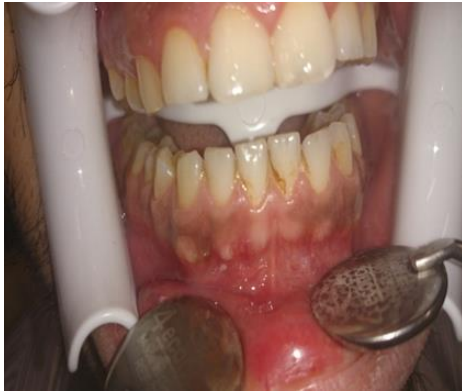REFERENCES:

1. CICEK, Y. The normal and pathological pigmentation of oral mucous membrane: A review. *J Contemp Dent Pract*, 2003,4:76–86.
2. DUMMETT.C.O. Oral pigmentation: First symposium of oral pigmentation. *J Periodontol*. 1960;31:356.
3. DUMMETT.C.O; BARENS, G. Pigmentation of the oral tissues: A review of literature. *J Periodontol*. 1967;38:369–78
4. DUMMETT, C.O. Overview of normal oral pigmentations. *J Indiana Dent Assoc*. 1980,59:13–8.
5. JACKSON, A, COLVER, G; DAWBER, R. Cutaneous cryosurgery. Principles and clinical practice. London, Martin Dunitz,1992, p, 1-5.
6. KUMAR, S; BHAT,G. S; BHAT, K. M. Development in techniques for gingival depigmentation e An update. *Indian Journal of Dentistry*, Vol 3, N 4, 2012 October- December, pp:213-221
7. LIN,Y.H; TU,Y.K; LU,C.T; CHUNG,W.C; HUANG,C.F; HUANG,M.S; LU,H. Systematic review of treatment modalities for gingival depigmentation: a random-effects poisson regression analysis. *J Esthet Restor Dent*. 2014 May-Jun;26(3):162-78..
8. PERLMUTTER, S; TAL, H. Repigmentation of the gingiva following surgical injury. *J Periodontol*, 1986,57:48–50.
9. PAGE.L.R; CORIO.R.L; CRAWFORD. B.E; GIANSANTI. J.S, Weathers DR. The Oral melanotic macule. *Oral Surg Oral Med Oral Pathol*. 1977;44:219–26
10. SCHROEDERr, H.E. Melanin containing organelles in cells of the human gingival: I, Epithelial melanocytes. *J Periodont Res*. 1969;4:1–3.
11. SHARMA,V.K; KANDHPUR,S. Guidelines for cryotherapy. *Indian J Dermatol Venerol Leprol*, 2009,75(2):90-100
12. SHEETRA, K.A; JOANN, P.G; PRABHUJI,ML.V; LAZARUS, F. Cryosurgical treatment of gingival melanin pigmentation - a 30 month follow up case report. *Clin Adv Perio*. 2012;2(2):73e78.
13. SZAKO, G; GERALD, S.B; PATHAK, M.A; FITZ PATRICK, T.B. Racial differences in the fate of melanosomes in human epidermis. *Nature*. 1969,222 :1081.
14. TAL,H; LANDSBERG,J; KOZLOVSKY,A. Cryosurgical depigmentation of the gingiva. A case report. *J Clin Periodontol*. 1987;14:614-617.

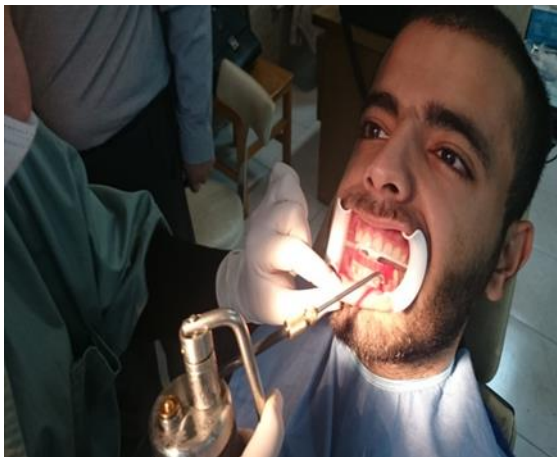
15. TAL, H; OEGIESSER, D; TAL,M. Gingival depigmentation by Erbium: YAG laser: Clinical observations and patients responses. J Peroiodontol. 2003;74:1660-7.

16. YEH, C. Cryosurgical treatment of melanin-pigmented gingiva. Oral Surg Oral Med Oral Pathol. 1998,vol.86,n6,pp: 660 -663

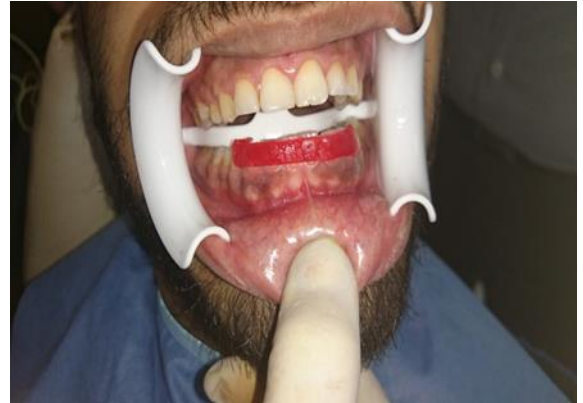FIGURES AND TABLES:



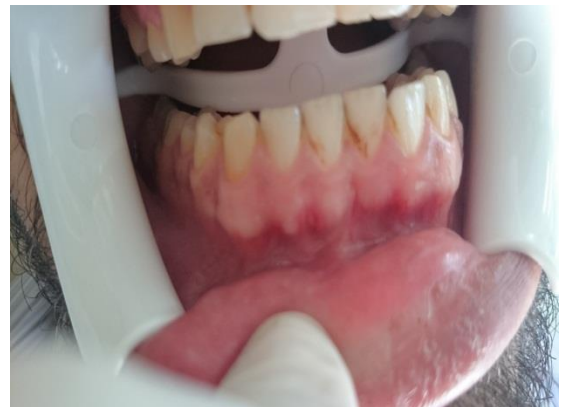Fig(1): diagnostic graph before treatment.



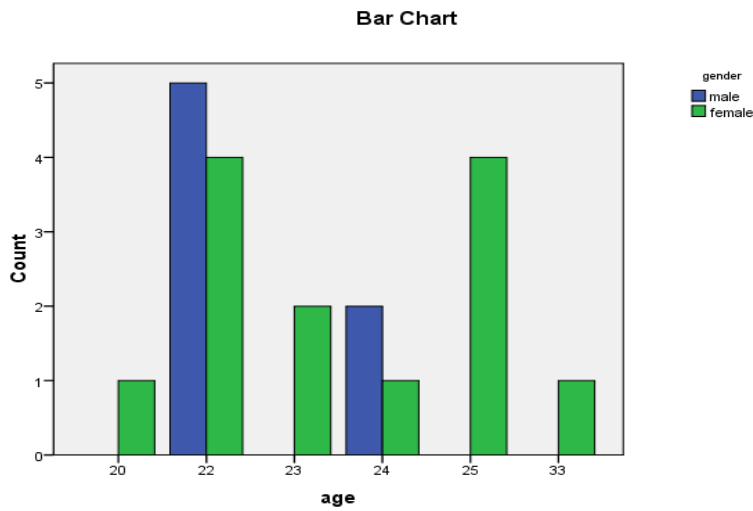
Fig(2): nitrogen application immediately at the gingiva after teeth isolation.



Fig(3): an image immediately after nitrogen application.



Fig(4): 1 year follow up after treatment delivery.



Fig(5): a graph illustrates sample distribution according to age and sex.

Table (2): Sample distribution according to age and sex

Age	Sex		Sum
	Male	Female	
20	0	1	1
22	5	4	9
23	2	0	2
24	2	1	3
25	0	4	4
33	0	1	1
Sum	9	11	20

Table (3): Distribution of both jaws samples based on DOPI values before and 3,6 months and 1 year after treatment:

Period	Jaw	DOPI				Sum
		1	2	3	4	
Pre-treatment	Max.	0	0	6	3	9
	Man.	0	6	2	3	11
	Sum.	0	6	8	6	20
3 months post treatment	Max.	5	3	1	0	9
	Man.	8	3	0	0	11
	Sum.	13	6	1	0	20
6 months post treatment	Max.	4	4	1	0	9
	Man.	8	3	0	0	11
	Sum.	12	7	1	0	20
12months post treatment	Max.	4	4	1	0	9
	Man.	8	3	0	0	11
	Sum.	12	7	1	0	20

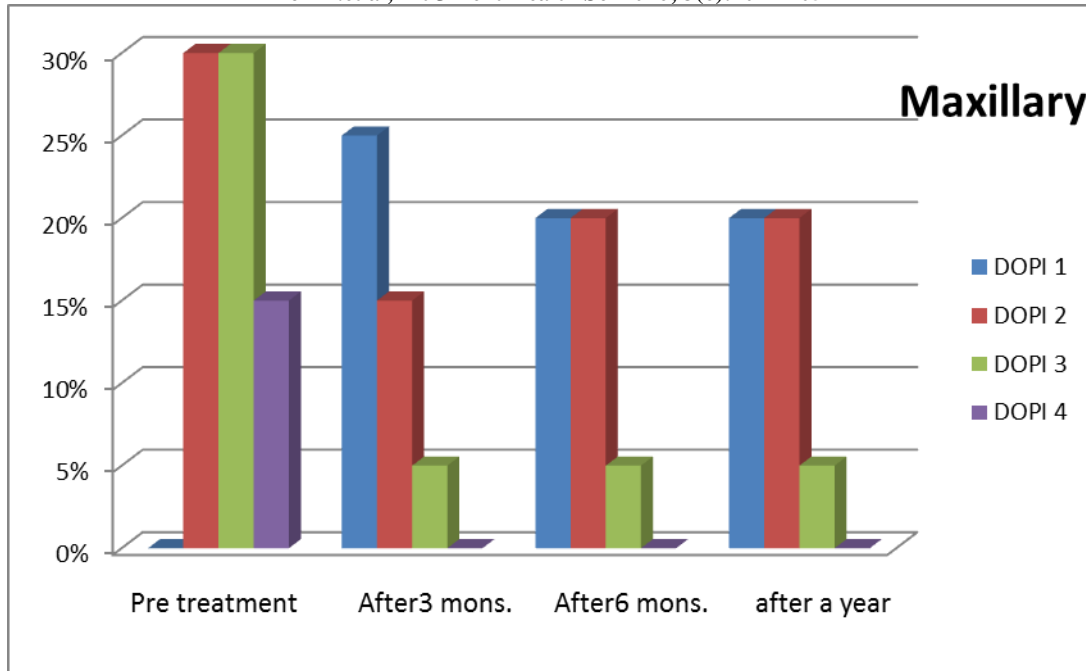
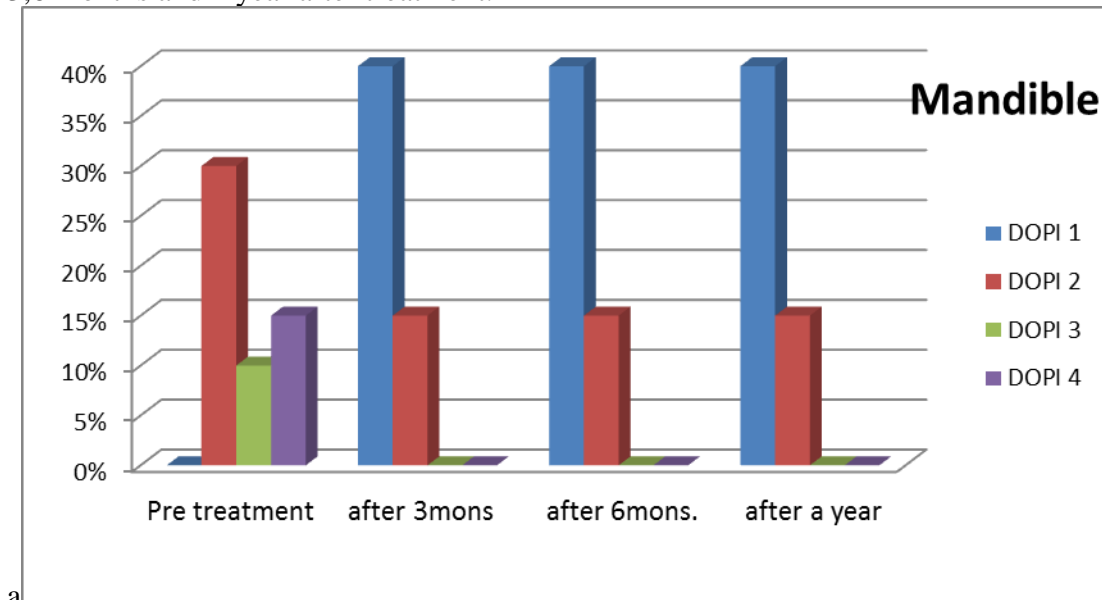


Fig (6): percentage of maxillary sample distribution based on DOPI values before and after 3,6 months and 1 year after treatment.



Fig(7): percentage of mandible sample distribution based on DOPI values before and after 3,6 months and 1 year after treatment.

Period	T value	P value
3 months post treatment	8,432	0,000
6 months post treatment	8,718	0,000
12 months post treatment	8,718	0,000

Table(5): Demonstrates mandible t-test values of comparison between the DOPI before and after 3,6,months and 1 year treatment.		
Period	T value	
3 months post treatment	9,747	0,000
6 months post treatment	9,747	0,000
12 months post treatment	6,718	0,000