

Review On Bovine Hydatidosis

Geda Shendo¹, Birhanu Ayele², Mengestie Abebaw¹ and Genene Girma¹

¹ Faculty of Veterinary Medicine, College of Medical and Health science, University of Gondar, P.O. Box. 196, Gondar, Ethiopia, ²Lecturer at University of Gondar, Faculty of Veterinary Medicine, Department of Paraclinical studies, Faculty of Vet Medicine, University of Gondar, P.O. Box. 196, Gondar, Ethiopia, manabebaw@gmail.com

Abstract: Echinococcosis (Hydatidosis) is a zoonotic disease caused by the larval stage (hydatid cyst) of *E. granulosus*. The disease spread when food or water that contains infective stage of the parasite is eaten or by close contact with infected animal. Bovine Echinococcosis is worldwide in its distribution with only few areas supposed to be free of the disease. Dogs are the primary definitive hosts for this parasite, while livestock and human beings acting as intermediate hosts. The disease poses significant threat in human health and livestock economy. The public health significances lies on the cost of hospitalization, medical and surgical fees, loss of income and productivity, permanent or temporary incapacity to work. In food animals, Echinococcosis causes decreased production of meat, milk, and wool, reduction in growth rate, and predisposition to other diseases. Targeting the major risk factors for the disease and the way it is transmitted, interrupting the life cycle, destroying the reservoir host and improved water sanitation is the most effective way in controlling and prevention of the disease.

[Geda Shendo, Birhanu Ayele, Mengestie Abebaw and Genene Girma. **Review On Bovine Hydatidosis.** *Biomedicine and Nursing* 2017;3(2): 12-23]. ISSN 2379-8211 (print); ISSN 2379-8203 (online). <http://www.nbmedicine.org>. 3. doi:[10.7537/marsbnj030217.03](https://doi.org/10.7537/marsbnj030217.03).

Key words; *Cattle, Economic importance, Hydatidosis*

1. Introduction

Echinococcosis (Hydatidosis) is a chronic cyst-forming parasitic helminthic disease of domestic and wild ungulates as well as human beings caused by infection with the larval (metacestode) stages of dog tapeworms belonging to the genus *Echinococcus* and family *Taeniidae*. Three broad morphological forms of echinococcosis are recognized clinically: cystic echinococcosis caused by *E. granulosus*, alveolar echinococcosis caused by *E. multilocularis*, and polycystic caused by *Echinococcus vogeli* or *Echinococcus oligarthrus* (Craig *et al.*, 2007). Cystic echinococcosis (CE) is caused by ingestion of ova of the cestode *E. granulosus* and then formation of larval stage in different organs and tissues (Eckert and Deplazes, 2004). CE is of public health and economic importance not only in areas of endemicity but also in non endemic countries due to migration of infected people and livestock exchange which promotes emergence in previously free disease areas (Mamuti *et al.*, 2002).

Of the five species, *E. granulosus* is found all over the world. *E. multilocularis* is widespread in the Northern hemisphere, while two species *E. oligarthrus* and *E. vogeli* are found only in Central and South America. The fifth, *E. shiquicus* was discovered in 2006 in the Peoples Republic of China (Tiaoying *et al.*, 2005). *E. granulosus* and *Echinococcus multilocularis* are the most important members of the genus in respect of their economic loss, public health significance and their geographical distribution. Approximately 60 to 70% of *E. granulosus* cysts occur

in the liver and 20 to 25% in the lungs. The remaining cysts can be found almost anywhere in the body including the bones, kidneys, spleen, muscles, central nervous system (CNS) and behind the eye (CFSPH, 2011).

The life cycle of *Echinococcus species* is complex, involving two hosts (definitive hosts and intermediate hosts) and free-living egg stages. Dogs are the usual definitive hosts whilst a large number of mammalian species can be intermediate hosts, including domestic ungulates and man. The definitive host is infected by ingestion of offal containing contaminated fertile cysts and the intermediate hosts are infected by ingesting contaminated feeds, and water with dog feces contains eggs of the parasite (Acha and Szyfres, 2003).

The cycle is completed when an intermediate host or its organ is eaten by a suitable carnivore (Thompson and McManus, 2002), and man is usually a dead end intermediate host (Zhang *et al.*, 2003). Different studies have shown that cystic echinococcosis (*E. granulosus*) represented considerable economic and public health significance in different countries (Azlaf and Dakkak, 2006; Berhe, 2009; Kebede *et al.*, 2009). In food animal hydatidosis has an adverse effect on production causing decreased production of meat, milk, wool, reduction in growth rate, and predisposition to other diseases. Hydatidosis is the major causes of organ condemnation in most Ethiopian abattoirs and slaughter houses causing huge economic losses (Berhe, 2009; Kebede *et al.*, 2009; Fikire *et al.*, 2012; Terefe, 2012).

In Ethiopia, particularly in rural areas, livestock rising is an important activity from which food and non food commodities are produced. Livestock plays a key role in the daily life of the population; particularly the peasant owns over 95% of the country. But the productivity remains very low due to lack of disease control and poor husbandry practice. Hydatid disease/echinococcosis is one of the diseases which decrease productivity and zoonotic importance (Torgerson and Budke, 2003). Despite different studies, in Ethiopia, the disease has not been investigated sufficiently, and information related to its prevalence and economic impact is still limited. Therefore, the objectives of this paper are: To review the epidemiology of Bovine Hydatidosis and to highlight the economic importance, control and prevention methods

2. Literature Review

2.1. Definition

Echinococcosis, or hydatid disease, is an infection caused by tapeworms of the genus *Echinococcus*, a tiny tapeworm just a few millimeters long. Echinococcosis is a zoonosis, a disease of animals that affects humans. Like all tapeworms the life cycle involves two animals. A carnivore is the definitive host, where the adult worms live in the intestine and almost any mammal, including humans can be the intermediate host, where the worms form cysts in various organs. The disease symptoms are caused by the cysts, which are slow growing fluid-filled structures that contain the larvae and are most often located in the liver or lungs, called hydatid cysts (FAO, 2007).

2.2. Echinococcus Species

At present, five species of the genus *Echinococcus* are regarded as taxonomically valid; these are *E. granulosus*, *E. multilocularis*, *E. oligarthrus*, *E. vogeli* and *E. shiquicus*; *Echinococcus oligarthrus* and *E. vogeli* occur less frequently than the first two species; until recently *E. shiquicus* had been discovered only in a specific region of the People's Republic of China (CFSPH, 2011). These five species are morphologically distinct in both adult and larval stages and a number of intraspecific variants have been described for *E. granulosus*, which exhibit morphological and biological characteristics, and these can reliably be differentiated by DNA analysis (Craig *et al.*, 1996).

E. granulosus is known to be one of the most important parasitic infections in livestock worldwide and one of the most widespread parasitic zoonoses (Craig *et al.*, 2007; Cringoli *et al.*, 2007). Dogs are the main source of infection, although in some areas jackals, hyenas, foxes, and wolves could also play a role as definitive hosts and the intermediate hosts are a

wide range of domestic and wild mammals and humans, in which the larval stages developed after oral infection with eggs (Seimenis, 2003). The adult varies between 2 and 11mm in length and usually possesses from two to seven segments, averaging from three to four segments and the last (gravid) segment is usually more than half the length of the entire worm (Eckert, 1998).

The size of the hooks varies between 25 to 49µm in the first row, and 17 to 31µm in the second row. The larval stage is a fluid-filled bladder or hydatid cyst that is unilocular. Individual bladders may reach up to 30cm in the diameter and occur most frequently in the liver and lungs, but may develop in other internal organs and the infection with this stage is referred to as cystic echinococcosis (Craig, 2007).

E. multilocularis, a tapeworm inhabiting the small intestine of carnivorous mammals, is the causative agent of alveolar echinococcosis, one of the most lethal helminthic infections of cattle. The sylvatic cycle of *E. multilocularis* predominantly involves foxes (genera *Vulpes* and *Alopex*) as definitive hosts and many species of rodents as intermediate hosts (Schantz *et al.*, 1995). Domestic dogs and cats can also act as definitive hosts, but foxes are thought to be the main sources of environmental contamination with eggs of *E. multilocularis* in most of the endemic areas (Schantz *et al.*, 1995; Eckert and Deplazes, 1997). Unlike *E. granulosus*, the larval mass often contains a semisolid rather than a fluid matrix and infection with this stage is commonly referred to as alveolar echinococcosis (Gottstein, 1992).

The definitive hosts for *Echinococcus oligarthrus* are wild felids, and the intermediate hosts are rodents and in the intermediate host, the cysts develop in the muscles, subcutaneous tissue, and in internal organs such as the heart and lungs (WHO/OIE, 2001). The adult varies between 2.2 and 2.9mm in length, and normally possesses three segments. The definitive hosts for *Echinococcus vogeli* are bush dogs (*Speothos venaticus*) and the intermediate hosts are South American rodents, especially pacas (*Cuniculus paca*). The adult varies between 3.9 and 5.5 mm in length, and usually has three segments. The metacestode is found primarily in the liver of the intermediate host, but it can also occur in the lungs and other organs. In pacas, *E.vogeli* cysts are fluid-filled, usually 0.5cm to 6cm in diameter, and can occur singly or as aggregates and the infection caused by the larval stage of this species is commonly referred to as polycystic echinococcosis (CFSPH, 2011).

Echinococcus shiquicus has been described in plateau pika (*Ochotona curzoniae*) which serves as the intermediate hosts, and Tibetan foxes (*Vulpes ferrilata*) which are the definitive hosts. The adult

stage is morphologically similar to *E. multilocularis* but differs by its smaller hooks, fewer segments, upper position of genital pore in the premature segment and fewer eggs in the gravid segment. It is easily distinguishable from *E. granulosus* by its shorter

length, branchless gravid uterus and anterior position of genital pore in the gravid segment. The metacestode is found in the liver and is essentially a unilocular minicyst containing fully developed brood capsules (Tiaoying *et al.*, 2005).

Table 1: Useful characteristics for identification of *Echinococcus* Species

Characteristic	<i>E. granulosus</i>	<i>E. multilocularis</i>	<i>E. oligarthrus</i>	<i>E. vogeli</i>	<i>E. shiquicus</i>
Definitive host (DH)	Primarily dogs but also other canids	Primarily foxes, but also other canids and cats	Wild felids	Bush dog	Tibetan fox
Intermediate host(IH)	Primarily ungulates but also marsupials, primates and humans	Primarily rodents, rarely other mammals and humans	Neo tropical rodents	Same as <i>E. oligarthrus</i> but also humans	Plateau pika
Distribution	Cosmopolitan	Northern hemisphere	Central and South America	Central and South America	Tibet plateau
Name of disease	Cystic echinococcosis Hydatidosis, hydatid disease.	Alveolar echinococcosis Hydatidosis or hydatid disease	Poly cystic Hydatidosis	Poly cystic Hydatidosis	-
Localization	Various tissues and organs, primarily liver and lungs.	Liver, rarely other tissues and organs	Primarily muscles, skin, occasionally viscera	Liver, occasionally other viscera	-
Total length (mm)	2.0-11.0	1.2-4.5	2.2-2.9	3.9-5.5	1.3-1.7
Metacestode (larva)	Unilocular cysts In viscera	Multilocular cysts in viscera	Polycystic cysts in muscle	Polycystic cysts in muscle	Unilocular cysts in viscera
Gravid uterus	Branching laterally	Sac-like	Sac-like	Tubular	Sac-like

Source: (Xiao *et al.*, 2006)

2.3. General Morphology of *E. granulosus*

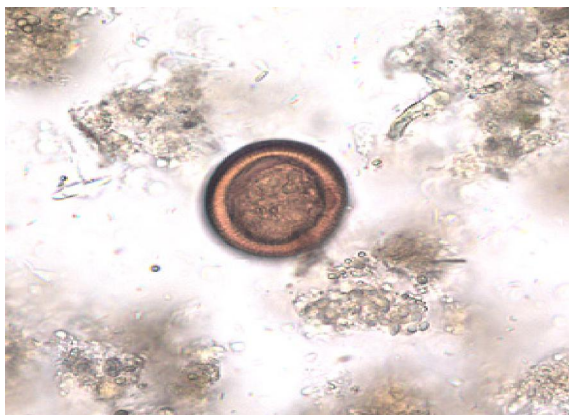


Figure 1: *E. granulosus* egg. Source: (Wikipedia.org).

2.3.1. The eggs

Echinococcus eggs contain an embryo that is called an oncosphere or hexacanth. The name of this embryo stems from the fact that these embryos have

six hooklets. The eggs are passed through the feces of the definitive host and it is the ingestion of these eggs that lead to infection in the intermediate host (John *et al.*, 2006).

2.3.2. The larval stage

From the embryo released from an egg develops a hydatid cyst, which grows to about 5-10 cm within the first year and is able to survive within organs for years (Mandell *et al.*, 2010). Cysts sometimes grow to be so large by the end of several years or even decades, they can contain several liters of fluid. Once a cyst has reached a diameter of 1cm, its wall differentiates into a thick outer, non-cellular membrane, which covers the thin germinal epithelium. From this epithelium, cells begin to grow within the cyst. These cells then become vacuolated and are known as brood capsules, which are the parts of the parasite from which protoscoleces bud. Often, daughter cysts form within cysts (John *et al.*, 2006).

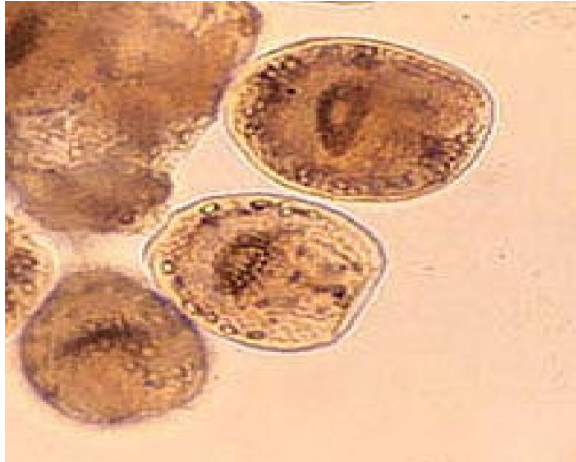

Figure 2: Larval stage of *E. granulosus*. Source: (Mandell *et al.*, 2010).

Echinococcus adult worms develop from protoscoleces and are typically 6mm or less in length and have a scolex, neck and typically three proglotids, one of which is immature, another of which is mature and the third of which is gravid (or containing eggs) (John *et al.*, 2006). The scolex of the adult worm contains four suckers and a rostellum that has about 25-50 hooks (DPDx. CDC, 2009).

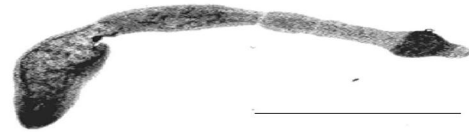


Figure 3: Adult *E. granulosus*. Source: (DPDx. CDC, 2009)

2.3.3. The adult stage

2.4. Life Cycle and Host parasite Relationships

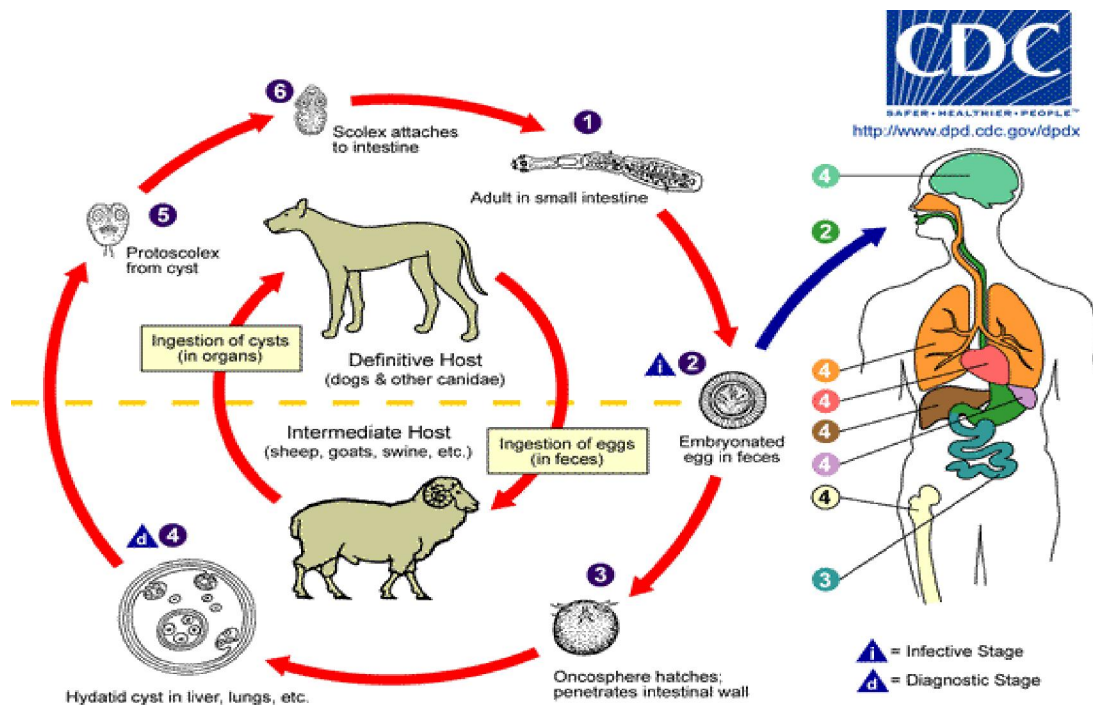


Figure 4: The life cycle of *E. granulosus*. Source: (CDC, 2009)

E. granulosus has an indirect life cycle that is completed between two mammalian hosts, a canid definitive host and an herbivorous or omnivorous intermediate host. An adult worm resides in the small intestine of a definitive host, afterwards, gravid proglotids release eggs that are passed in the feces of definitive host. The egg is then ingested by an intermediate host (cattle) the egg then hatches in the small intestine of the intermediate host and releases an oncosphere that penetrates the intestinal wall and

moves through the circulatory system into different organs, in particular the liver and lungs (Mandell *et al.*, 2010). Once it has invaded these organs, the oncosphere develops into a cyst and the cyst then slowly enlarges, creating protoscoleces and daughter cysts within the cyst. The definitive host then becomes infected after ingesting the cyst-containing organs of the infected intermediate host. After ingestion, the protoscoleces attach to the intestine; then develop into adult worms and the cycle start all over again.

Eggs are infective to the intermediate hosts immediately after excretion from the definitive host into the external environment (John et al., 2006).

2.5. Epidemiology

2.5.1. Geographic Distribution

E. granulosus occurs worldwide, with the exception of a few countries such as Iceland and Greenland (CFSPH, 2011). It has been reported in Europe, the Middle East, Africa, Parts of Asia, Australia, New Zealand, North America and South America (Thompson and McManus, 2002). This worldwide distribution is due to a very low intermediate host specificity of *E. granulosus*, associated with the repeated introduction of infected animals from Europe to other parts of the world (Thompson and McManus, 2002). *E. multilocularis* mainly occurs in the Northern hemisphere, including central Europe, Asia, and North America (Raush,

1995). Unlike the previous two species of *Echinococcus*, *E. vogeli* and *E. oligarthrus* are limited to Central and South America and *E. shiquicus* has been identified on the Tibetan plateau in china (Lozano, 2012).

The prevalence of the disease is variable and depends on several factors, in particular: farming systems, socio-cultural habits, economic development, level of public health education and host-parasite relationship. The frequency of infection is very high in an endemic or hyper-endemic form in the Mediterranean region (North Africa and Southern Europe), on the African continent (particularly in Kenya), in the near and Middle East (Seimenis, 2003), Indian sub-continent (Taylor et al., 2007), China (Tiaoying et al., 2005) and Latin America (Schantz et al., 1995).

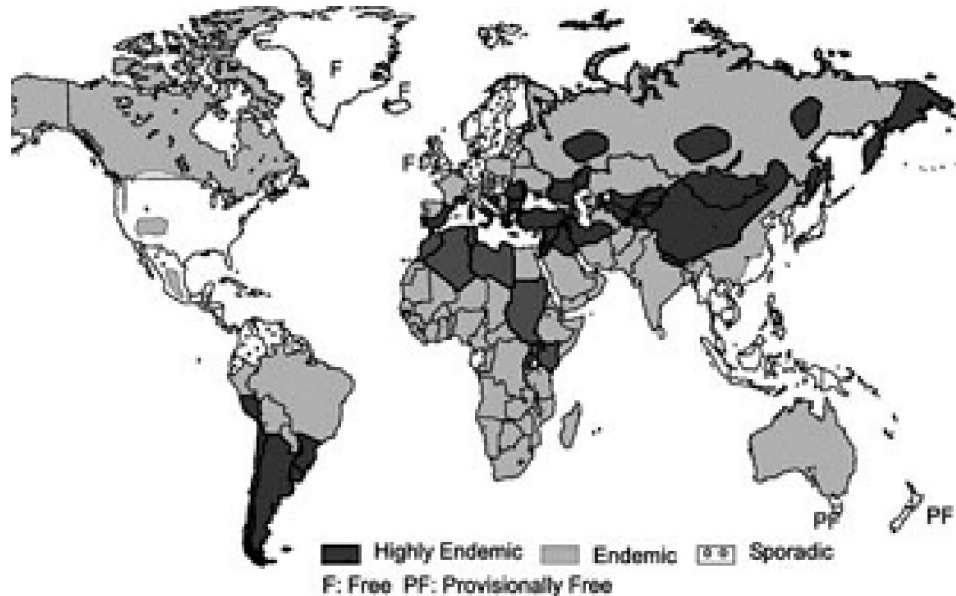


Figure 5: Geographic Distribution of *E. granulosus*. Source: (Eckert and Deplazes, 2004)

2.5.2. Host range

The larval stage of *E. granulosus* (hydatid) develops in many species of domestic and wild mammals. Hydatidosis is encountered in sheep, goats, cattle, buffalo, pigs, equines, camelids, cervids and humans. Among the wild animals, it has been observed in foxes, marsupials (kangaroos, wallabies) in Australia, reindeer and moose in northern Eurasia and North America (Rauch, 2003) and in over 19 species of herbivorous in sub-Saharan Africa (Macpherson and Wachira, 1997).

2.5.3. Transmission

All disease causing species of *Echinococcus* are transmitted to intermediate hosts via the ingestion of eggs and are transmitted to definitive hosts by means

of eating infected, cyst-containing organs. Cattle become infected when they swallow eggs from contaminated pasture and when hydatid eggs are swallowed by an intermediate host or cattle; they migrate through the stomach wall into the bloodstream (Eckert and Deplazes, 2004). They are then carried to various internal organs, usually the liver and lungs, but sometimes the brain, kidney, heart and spleen. A watery hydatid cysts then forms in these soft tissues and in cattle, approximately 10% of hydatid cysts are viable, and these cysts usually die within a few months (Schwabe, 1991). While there are no biological or mechanical vectors for the adult or larval form of any *Echinococcus species*, coprophagic flies, carrion birds

and arthropods can act as mechanical vectors for the eggs (Macpherson and Milner, 2003).

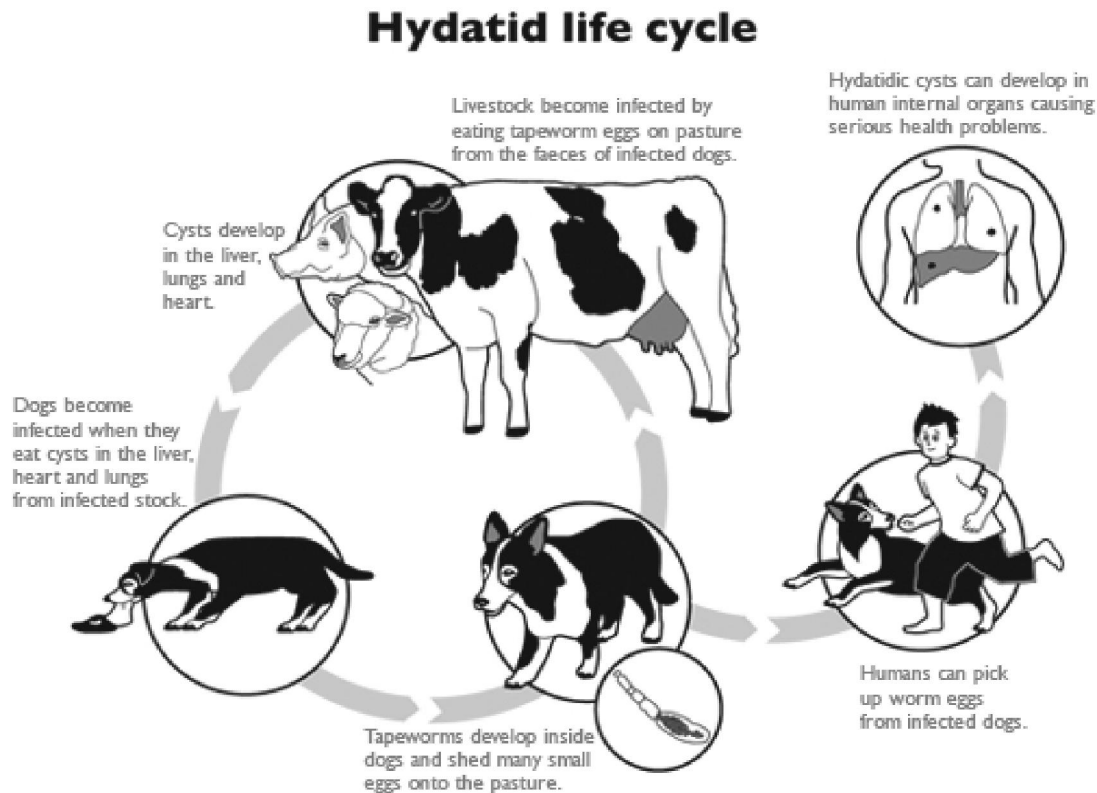


Figure 6: Transmission of hydatid cyst. Source: (CDC, 2009)

2.5.4. Risk Factors

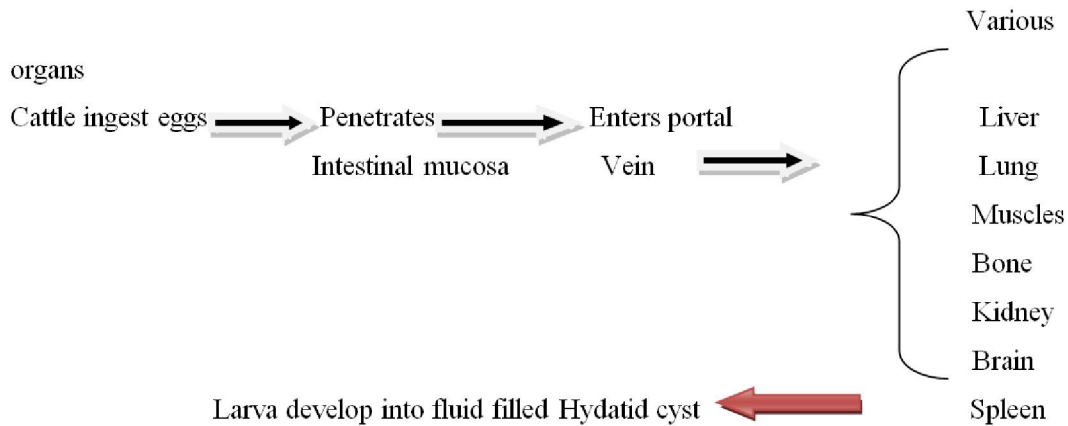
Dogs used for herding in many continents are at risk from infection when they scavenge from dead livestock, particularly cattle and sheep (Schwabe, 1984). Ample opportunities for this occur, particularly in nomadic or transhumant situations where livestock are moved over vast distances and this increase regular close contact with dogs and grazing on pastures contaminated with the egg of hydatid cyst and again this also increase the risk for bovine hydatidosis (Macpherson, 1995). In a number of countries in West Africa and Asia some people eat dogs which would be hazardous to the people preparing them as well as the consumers (Schwabe, 1991). In Turkana, jackals and hyenas were consumed during periods of drought (Macpherson, 1983).

Cattle that graze pastures adjacent to forested land where wild dogs are present have a higher incidence of hydatid cysts. Keeping dogs in close association with cattle, presence of a large number of stray dogs, easy access of dogs to raw viscera of animals, including home slaughtered animals, inadequate facilities for the slaughter and disposal of hydatid-infected organs, number of years of coexistence with dogs, spending the initial years of life

surrounded by a large number of dogs, occupation of raising livestock, nomadic life and close contact with dogs, not protecting food from flies, water wells and other sources of drinking water shared with dogs, inadequate health education, economic instability and poor living conditions are some of the risk factors (Eckert and Deplazes, 2004).

2.6. Pathogenesis and Clinical effects

Pathogenesis of hydatid cyst depends on the severity of infection and the organ in which it is situated (Craig, 1997). During natural course of infection, some cysts may grow to certain size and continue to remain without producing any pathological change for many years. Other cyst may rupture spontaneously or collapse and disappear completely (Schwabe, 1991). Pressure effect by cyst may develop insensitive areas. Hydatid may cause blocking effects and mechanical compressions leading to collapse of infective bones, blinding and rupture of cyst induce sudden anaphylactic shock (Eckert *et al.*, 2002). In addition, the cysts can cause life threatening illness, associated with liver failure, pulmonary edema, and rupture of cysts which may cause fatal anaphylactic shock in intermediate hosts (Taylor *et al.*, 2007).



2.7. Diagnosis

2.7.1. Clinical Diagnosis

In the absence of pathognomonic signs, the clinical diagnosis of hydatidosis in animals is practically impossible. Imaging methods such as, X-ray, ultrasound, computerised tomography or CT scan, that help diagnose hydatidosis in humans are not used as common tools in cattle (CFSPH, 2011).

Definitive hosts only: eggs may be found on fecal flotation; eggs are brown, slightly oval, up to 40µm in size, shell has radial striations; cannot be differentiated from those of *Taenia* species. There are also tests for specific antigens in faeces (coproantigens) which are highly genus specific for *Echinococcus* and exhibit greater sensitivity than arecoline purgation and because of their small size, gravid segments are generally overlooked when shed with feces (Gottstein, 1992).

2.7.2. Serological Diagnosis

Currently, there is no suitably sensitive and specific serological test available for bovine hydatidosis or for any livestock species (Lightowers and Gottstein, 1995). However, identification of exposure to *E. granulosus* at the flock or herd level by use of mean values for serum antibody activity is possible using hydatid fluid antigens in ELISA and may be useful in hydatid screening and surveillance programmes. Serological tests are not generally used for diagnosis in domesticated animals and species of *Echinococcus* sometimes induces relatively poor serological responses in its usual intermediate hosts (CFSPH, 2011). Nevertheless, several serological tests (indirect haemagglutination, immuno-electrophoresis, enzyme-linked Immunosorbent assay (ELISA), etc have been used with antigens from hydatid cysts but none of them is sufficiently reliable for the diagnosis of hydatidosis in individual animals (Craig, 1997).

2.6.3. Postmortem Diagnosis

Detection of hydatid cysts in the organs is generally easy to perform at necropsy or upon meat inspection. In intermediate hosts, diagnosis depends

on the postmortem detection of the cysts particularly in the liver and lungs for *E. granulosus* during meat inspection. The dull white color, the presence of fluid under pressure, the rolling of the cyst wall when opened and the presence of hydatid sand in fertile cysts are the pathognomonic characteristics of hydatid cysts (Eckert and Deplazes, 2004).

However, hydatid cyst should be differentiated from various other lesions in different organs, as follows: abscess, which lacks the characteristics of hydatid cysts, lesions of tuberculosis, Which are identified through bacteriological and histological examinations, ordinary cysts, which have neither parasitic membrane nor the hydatid sand, various *taeniid* larvae, such as cysticerci of *taenia hydatigena* (*cysticercus tenuicollis*) on the liver and peritoneum, which are flaccid with clear fluid and a single scolex that is visible to the naked eye, or the coenurus of *T. multiceps* (*coenurus cerebralis*) in sheep brain, which contains multiple protoscoleces but no brood capsules, pulmonary nodules containing liver fluke (*Fasciola hepatica*) in cattle, small lesions especially in the liver, caused by the migration of parasitic worms, such as ascarids can be identified by histological examination (Gottstein, 1992).

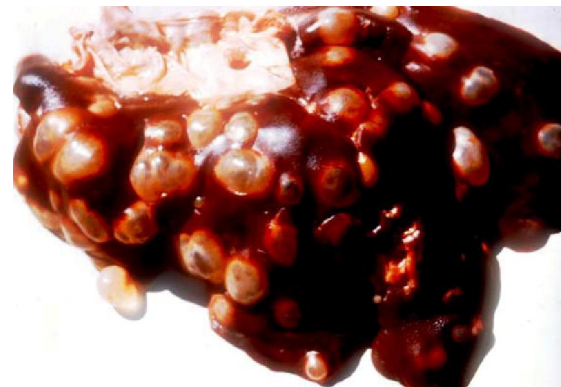

Figure 7: Multiple cysts in bovine liver. Source: (FAO, 2007)

2.8. Treatment

A number of Anthelmintic drugs have proved to be effective against adult stages of *E. granulosus* in the final host. The best drug currently available is praziquantel (Schantz, 1995; WHO, 2011), which exterminates all juvenile and adult echinococci from dogs. Treatment of intermediate host or cattle for tapeworm will have no effect on the cysts in the cattle. Long term treatment with albendazole has a particularly marked effect on the cysts but no treatment of practical use is currently available against hydatidosis in animals and detection of hydatid cysts is not easy to achieve in living animals and, on the other hand, an effective and economic drug is needed (Morris *et al.*, 1990).

2.9. Prevention and Control

The best control measure is to interrupt the life cycle of the parasite. This can be done by: Preventing access of dogs to livestock carcasses or slaughter wastes from farms, households, abattoirs or butchers, treating dogs with Anthelmintics (praziquantel) to kill the adult tapeworms, detecting cysts at meat inspection, thus targeting infected farms or communities, centralizing the slaughtering of animals for food in units with veterinary control, reducing the number of dogs on the ranches and treating them for *Echinococcus* on a regular basis, educating the rural population about hydatidosis and its control, ensuring sanitary conditions for slaughtering done on ranches and preventing dogs access to raw viscera. All condemned organs should be safely disposed and stray dogs and cats must be prohibited from abattoirs and their number should also be systematically reduced and looking for human Hydatidosis during primary health care visits (Craig *et al.*, 2007).

2.10. Economic Significance

Hydatidosis affects both human and animal health and has important economic consequences

(Torgerson, 2003). *Echinococcosis* infections constitute a significant financial constraint derived from human health costs and livestock production losses. Human associated economic losses arise through diagnostic procedures, surgical or chemotherapeutic treatment, hospitalization, convalescence, life impairment and fatalities. Animal associated economic losses arise from decrease in carcass weight, milk production, and fertility rates, and from increased condemnation of viscera. Estimation of the economic burden in humans and livestock is important and should be part of any cost-benefit program for the control of parasitic zoonosis (Budke *et al.*, 2006).

Hydatidosis leads to considerable economic losses either directly through the condemnation of affected organs or indirectly through the reduction in productivity or carcass weight of infected cattle. Further losses are incurred due to restrictions in international trade and the cost of control campaigns. In some countries, such as Morocco where the prevalence of hydatidosis is very high, over one third of the viscera of cattle, sheep and goats are condemned (Kachani *et al.*, 1997). In certain regions, the condemnation rate can reach between 50% and 100%, depending on the age of the animals at slaughter. In Latin America, viscera of over 2 million cattle and 3.5 million sheep are condemned and destroyed every year (Schantz *et al.*, 1995). The financial loss reports due to Hydatidosis in cattle shows great variation from place to place in Ethiopia, for example, Endrias Zewdu *et al.*, (2010) reported annual loss of 160,032.23 ETB at Ambo municipal abattoir, Kebede Woldegiorgis *et al.*, (2009) 25,608 US\$ at Mekelle municipal abattoir, Bezuayehu *et al.*, (2013) 96,315 ETB at Harar municipal abattoir, Endalew Debas and Nuraddis Ibrahim (2012) 674,093.093 ETB at Gondar Elfora abattoir.

Table 2: Financial losses due to Bovine Hydatidosis in Ethiopia

No.	Abattoir name	Year	Financial loss	Reference
1.	Addis Ababa Abattoirs Enterprise	2012	19,847,704.50 (ETB)	Dechasa <i>et al.</i> , 2012
2.	Kombolcha Elfora Industrial abattoir	2012	302,023.60 (ETB)	Alemu <i>et al.</i> , 2012
3.	Mekelle Municipality abattoir	2013	5,200 (\$)	Dawit <i>et al.</i> , 2013
4.	Ambo Municipality abattoir	2010	160,032.23.0 (ETB)	Endrias <i>et al.</i> , 2010
5.	Arbaminch Municipality abattoir	2013	21,833.60 (\$)	Alemu and Yitagele, 2013
6.	North Gondar Elfora abattoir	2013	674,093.038.0 (ETB)	Endalew and Nuraddis, 2013
7.	Bako Municipal abattoir	2014	180,792.0 (ETB)	Haftu and Kebede, 2014
8.	Harar Municipal abattoir	2013	96,315.0(ETB)	Bezuayehu <i>et al.</i> , 2014

2.11. Public Health Importance

Hydatid cysts can cause life-threatening disease in humans, caused by ingestion of eggs passed by dogs

and then development of a cyst or cysts within the human body. This can be a particular risk in children with close contact with pet or working dogs where

there has been less attention to hygiene (hand washing). In man the removal of cysts may require major surgery and life-threatening complications can occur, when cysts develop in critical parts of the body such as the brain, liver or lungs (Lozano, 2012).

The disease occurs in most areas of the world and currently affects about one million people. In some areas of South America, Africa, and Asia up to 10% of the certain populations are affected (WHO, 2014). In 2010, it caused about 1200 deaths (Lozano R, 2012). The economic cost of the disease is estimated to be around 3 billion \$ a year (WHO, 2014). In endemic areas, hydatidosis, is a major zoonosis, incurs significant costs related to diagnosis, surgical and/or chemotherapeutic treatment, hospitalization and lost working days. The global burden of CE and AE has been calculated to be of approximately 1 million and 600,000 DALYs respectively (Budke *et al*, 2006; Torgerson *et al.*, 2010).

2.12. Status of Bovine Hydatidosis in Ethiopia

Many studies from various parts of the country confirm that, Ethiopia is an endemic area for *E. granulosus*. High prevalence of hydatidosis is significant due to several factors of which keeping of dogs in close association with cattle; the knowledge of people about the role of dogs in transmitting echinococcosis of animal is low. Information available regarding the significance of the disease in Ethiopia is not sufficient even though fragment of studies have been reported in different parts of the country. In Ethiopia, Hydatidosis is one of the major parasitic zoonotic diseases especially where sheep, goat, cattle and pigs are still slaughtered traditionally and offal's are easily accessible to scavenging dog and other wild carnivores. Factors like absence of proper meat inspection procedure. Poor management of food animals, traditional practices of backyard farming system, lack of awareness about food born diseases, the presence of large stray dog population are thought to contribute significantly to the prevalence of the disease (Macpherson and Wachira, 1997).

Backyard slaughtering is common in Ethiopia with throwing of offals to dogs which increase the infection of dogs coming across the organs; as result the prevalence of Echinococcosis is increasing from time to time. In Ethiopia some individuals have reported the incidence and economic losses due to hydatidosis vary from region to region which correlates with the disease prevalence and current price of condemned organs at abattoirs and losses as the consequences of the disease (Dawit *et al.*, 2013). The variation in prevalence in different regions may be attributed to strain difference in culture, practice of backyard slaughter, couple provision of infected offals

to dogs, social activities and other related of factors (Urquhart *et al.*, 1996).

Conclusion And Recommendations

Hydatidosis is a worldwide problem and in certain areas has serious zoonotic and socioeconomic importance. Hydatidosis causes substantial visible and invisible economic losses in cattle as a result of condemnation of edible offal and weight loss. The most preferred predilection site of hydatid cysts in cattle like liver, lungs, heart and kidneys and condemnations of these important organs having a single or multiple hydatid cysts is really a huge loss. The huge financial losses due to organ condemnation reflect the economic impact of hydatidosis which deserves serious attention by the various stakeholders. In view of the present review and available information, the following recommendations are forwarded;

- ✓ The government should give attention towards building standard abattoirs with good facilities and control backyard slaughtering houses.

- ✓ Awareness generating/creating programs should be given for butchers, abattoir workers and dog owners as to the dangers of hydatidosis to human and animal health.

- ✓ Appropriate control measure should be taken to stop the sale of contaminated meat for pet animal's consumptions.

- ✓ Dog proof garbage collection and waste disposal system should be applied particularly around slaughter places and abattoirs.

- ✓ Control of stray dogs and preventing of dogs access to raw offal.

- ✓ A control program should be designed and implemented to reduce the number of stray dogs.

- ✓ Information should be obtained for a better identification of geographical risk areas for preventive action.

Acknowledgements

We would like to thank University of Gondar, Faculty of Veterinary Medicine for letting us to write **review on bovine hydatidosis**. We wish also to express our profound gratitude to personnel of the Faculty of Veterinary Medicine, who assist during study period and suggest valuable comments.

Corresponding Author:

Dr. Mengestie Abebeaw
Faculty of Veterinary Medicine, College of Medical and Health science, University of Gondar, P.o.box. 196, Gondar, Ethiopia
Telephone: (+251)0937349340
E-mail: manabebaw@gmail.com

References

1. Acha, P. N., Szyfres, B. (2003): Pan American Health Organization (PAHO): Zoonoses and communicable diseases common to man and animals. Vol.3: Parasitoses. 3rd ed. Washington DC: PAHO: Scientific and Technical Publication No. 580. Hydatidosis Pp 184-199.
2. Alemu, B., Nigatu, K., Tariku, T., Getachew, T, and Tesfu, K, (2012): Occurrence and financial Significance of bovine cystic echinococcosis in Southern Wollo, Northern Ethiopia. *Journal of Veterinary Medicine and Animal Health*, 5(2): Pp.51-56.
3. Alemu, T, and Yitagele, T, (2013): Hydatidosis, Prevalence, Cyst distribution and Economic Significance in Cattle slaughtered at Arbaminch Municipality Abattoir, Southern Ethiopia. *Global Veterinaria*, 11(3):329-334.
4. Azlaf, R, and Dakkak, A, (2006): Epidemiological study of the cystic echinococcosis in Morocco. *Veterinary Parasitology*, 137(2): 83-93.
5. Berhe, G. (2009): Abattoir survey on cattle Hydatidosis in Tigray region of Ethiopia. *Tropical. Animal Health Production*, 41 (7):1347-1352.
6. Bezuayehu, L., Tsegalem, A., Befikadu, U., Ayalew, N. and Abebe, A. (2014): Prevalence of Bovine Hydatidosis and its Economic Significance in Harar Municipality Abattoir, Eastern Ethiopia. *American-Eurasian Journal of Scientific Research*, 9(5): 143-149.
7. Budke, C. M., Deplazes, P, and Torgerson, P. R. (2006): Global socioeconomic impact of cystic echinococcosis. *Emerging Infectious Disease*, 12: 296-303.
8. Budke, C. M., Jiamin, Q., Qian, W and Torgerson, P. R. (2005): Economic effects of *echinococcosis* in a disease-endemic region of the Tibetan plateau: *American Journal Tropical Medical Hygiene*, 73: 2-10.
9. Center for Disease Control and Prevention (CDC, 2009): (Source: <http://www.dpd.cdc.gov/dpdx/html/Echinococcosis.htm>). Accessed 2 June 2015.
10. Center for Food Security and Public Health (CFSPH) (2011): Prevention and Control of cystic Echinococcosis. Iowa State of University, College of Veterinary Medicine, Iowa pp 1 -14.
11. Craig, P. S. (1997): Immunodiagnosis of *Echinococcus granulosus* and a comparison of techniques for diagnosis of canine Echinococcosis.
12. Craig, P. S., Budke, C. M., Schantz, P. M., Li, T, and Qiu, J. (2007): Human Echinococcosis: A Neglected Disease? *Tropical Medicine and Health*, 35: 283–292.
13. Craig, P. S., McManus, D. P., Lightowers, M. W., Chabalgoity, J. A, and Garcia, H. H. (2007): Prevention and control of cystic echinococcosis. *Lancet Infectious Disease* 7, 385-394.
14. Davidson, R., Romig, T., Jenkins, E., Tryland, M, and Robertson, L. J. (2012): The impact of Globalization on the distribution of *Echinococcus multilocularis*: *Trends Parasitology*: 28:239–247.
15. Dawit, G., Adem, A., Simenew, K, and Tilahun, Z. (2013): Prevalence, Cyst Characterization and Economic Importance of Bovine Hydatidosis in Mekelle Municipal abattoir, Northern Ethiopia. *Journal of Veterinary Medicine and Animal Health*, 5(3): 81-86.
16. Dechasa, T., Kibrusfaw, K., Anteneh, W, and Desta, B. (2012): Prevalence and financial loss estimation of hydatidosis of cattle slaughtered at Addis Ababa abattoirs enterprise. *Journal of Veterinary Medicine and Animal Health*, 4(3): 42-47.
17. Eckert, J., Conrathas, F. J, and Tackmann, K. (2000): Echinococcosis: an emerging or re-emerging zoonosis: *International Journal parasitology*, 30: 1283-1294.
18. Eckert, J, and Deplazes, P. (2004): Biological, Epidemiological, and clinical aspects of echinococcosis, a zoonosis of increasing concern. *Clinical Microbiology Review*, 17: 107–135.
19. Endalew, D and Nuradddis, I. (2013): Prevalence and Economic Importance of Hydatidosis in Cattle Slaughtered at North Gonder Elfora Abattoir. *Ethiopia Journal of Applied Sciences*, 5(1): 29-35.
20. Endrias, Z., Yechale T, and Assefa, M. (2010): Bovine Hydatidosis in Ambo Municipality Abattoir, West Shoa, Ethiopia. *Ethiopian Veterinary Journal*, 14: 1-14.
21. Fikire, Z., Tolosa, T., Nigussie, Z., Macias, C, and Kebede, N. (2012): Prevalence and characterization of hydatidosis in animals slaughtered at Addis Ababa abattoir. *Ethiopia Journal Parasitology, Vector Biology*, 4(1):1 -6.
22. Food and Agricultural Organization (2007): Manual on Meat Inspection for Developing Countries: Haramaya University, Harar, Ethiopia.
23. Gottstein, B. (1992): *Echinococcus multilocularis* infection: Immunology and immune diagnosis. *Advanced in Parasitology*, 31: 321-380.
24. Haftu, B, and Kebede, T. (2014): Study on Prevalence and Economic Significance of Bovine

- Hydatidosis in Bako Municipal Abattoir, West Shoa Zone, Oromia Regional State. *Journal veterinary Science Technology*, 5: 197.
25. Hagos, B., Mesfin, M., and Abebe, B. (2006): Hydatid disease of the liver: A 12 year experience of surgical management. *East and Central African Journal of Surgery*, 11: 54-60.
 26. Hydatid Disease on Wikipedia: http://en.wikipedia.org/wiki/Hydatid_disease. Accessed 9 June 2015.
 27. John, T., William, P., William A., Markell, E., Voge, K., and Marietta, L. (January 2006): The Cestodes; *Echinococcus granulosus*, *E. multilocularis* and *E. vogeli* (Hydatid Disease). Markell and Voges Medical Parasitology 9th ed *Health Sciences*. Pp. 224-231.
 28. Kebede, W., Hagos, A., Girma, Z., and Lobago, F. (2009): Echinococcosis/hydatidosis: its prevalence, economic and public health significance in Tigray region, NorthEthiopia. *Tropical Animal Health Production*, 41: 865-871.
 29. Lightowlers, M. W., and Gottstein, B. (1995): Echinococcosis/hydatidosis, Antigen, immunological and molecular diagnosis. In Echinococcosis and hydatid disease (R.C.A. Thompson and A.L. Lymbery, eds): CAB International Wallingford, Oxon, 355-410.
 30. Lozano, R. (2012): Global and regional mortalities from 235 causes of death for 20 age groups in 1990 and 2010: a systematic analysis for the Global Burden of Disease study 2010.
 31. Macpherson, C. N., Zeyhle, E., and Romig, T. (1984): An Echinococcus pilot control program for north-west Turkana, Kenya. *Annual Tropical Medical Parasitology*, 78: 188-192.
 32. Macpherson, C. N. L and Wachira T.W. M. (1997): *Cystic Echinococcosis* in Africa south of the Sahara. In compendium on *cystic echinococcosis* in Africa and in Middle Eastern countries with special reference to Morocco (Anderson, F. L., Ouhelli, H, and Kachani, M eds). Brigham young University, *provo*, 245-277.
 33. Macpherson, C. N. L. (1983): An active intermediate host role for man in the life cycle of *Echinococcus granulosus* in Turkana, Kenya. *American Journal of Tropical Medicine and Hygiene*, 32: 397-404.
 34. Macpherson, C. N. L. (1995): The effect of transhumance on the epidemiology of animal diseases. *Preventive Veterinary Medicine*, 25: 213-224.
 35. Mnadell, Douglas, and Bennett. (2010): Principles and Practice of Infectious Disease (7th ed). Elsevier.
 36. Rauch, R. L. (2003). Cystic Echinococcosis in the Arctic and sub-Arctic. *Parasitology*, 127: 73-85.
 37. Rinaldi, L., Maurelli, M. P., Capuano, F., Perugini, A. G., Veneziano, V, and Cringoli, G. (2008): Molecular update on cystic echinococcosis in cattle and water buffaloes. *Zoonoses and Public Health*, 55:119-123.
 38. Savioli, L, and Daumerie, D. (2010): First WHO report on neglected tropical diseases: working to overcome the global impact of neglected tropical diseases. France: *World Health Organization*. 169p.
 39. Schantz, P. M., Chai, J, and Craig, P. S. (1995): Epidemiology and control of hydatid disease. In *Echinococcus* and hydatid disease (Thompson, R. C.A and Lymbery, A. J, eds): CAB International, Wallingford, 233-331.
 40. Schwabe, C. W. (1984): *Veterinary Medicine and Human Health*. 2nd ed. Williams and Wilkins Baltimore, London. Pp, 28-37.
 41. Schwabe, C. W. (1991): Helminthes zoonoses in African perspective. In: Macpherson, C. N. L and Craig, P. S. (eds): *Parasitic Helminths and Zoonoses in Africa*. Unwin Hyman, London, Pp; 1-24.
 42. Seimenis, A. (2003): Overview of the epidemiological situation on echinococcosis in the Mediterranean region. *Acta Tropical*, 85:191-195.
 43. Taylor, M. A., Coop, R. L, and Wall, R. L. (2007): *Veterinary Parasitology*. 3rd ed. London, UK, Black Well Publisher. Pp. 156-159.
 44. Terefe, D., Kebede, K., Beyene, D, and Wondimu, A. (2012): Prevalence and financial loss estimation of Hydatidosis of cattle slaughtered at Addis Ababa abattoirs enterprise: *Journal of Veterinary Medicine and Animal Health*, 4(3):42-47.
 45. Thompson, R. C. A and McManus D. P. (2002): Towards a taxonomic revision of the genus *Echinococcus*. *Trends parasitology*, 18: 452-457.
 46. Thompson, R. C. A. (1995): Biology and Systematics of echinococcus. In Echinococcus and hydatid disease (R.C.A Thompson and A. J. Lymbery, eds): CAB International: Wallingford, 1-50.
 47. Tiaoying, L., Jiamin, Q., Wen Y., Craig, P. S, and Xingwang, C. (2005): Echinococcosis in Tibetan populations, western Sichuan Province, China. *Emerging infectious diseases*, 11: 1866-1873.
 48. Torgerson, P. R. (2003): Economic effects of echinococcosis. *Acta Trop*, 85: 113-8.
 49. Torgerson, P. R, and Budke, C. M. (2003): Echinococcosis: International public health

- challenge. *Research in Veterinary Science*, 74: 191–202.
50. Torgerson, P. R., Keller, K., Magnotta, M, and Ragland, N. (2010): The Global Burden of Alveolar Echinococcosis. *PLoS Neglected Tropical Diseases* 4(6).
 51. Torgerson, P. R., Oguljahan. B., Muminov, A. E., Karaeva, R. R, and Kuttubaev, O. T. (2006): Present situation of cystic echinococcosis in Central Asia. *Parasitology International*, 55: 207–212.
 52. Urquhart, A. M., Armover, J., Duncan, J., L., Dunn, A. M. and Jennings, F. W. (1996): *Veterinary Parasitology*. ed UK: Longman group UK latd. Pp. 123-129.
 53. WHO (2011): Report of the WHO Informal Working Group on cystic and alveolar echinococcosis surveillance, prevention and control, with the participation of the Food and Agriculture Organization of the United Nations and the World Organization for Animal Health.
 54. World health organization (WHO)/Office International des Epizooties (OIE)(2001): WHO/OIE Manual on *Echinococcosis* in Humans and Animals: a Public Health Problem of Global Concern, In Eckert J., Gemmell, M. A., Meslin, F. X, and Pawlowski, Z. S., eds. *OIE (World Organization for Animal Health)*, Paris, France, Pp 1–265.
 55. Xiao, N., Qiu, J., Nakao, M., Li, T., Yang, W., Chen X., Schantz, P. M., Craig, P.S, and Ito, A. (2006): *Echinococcus shiquicus*, a new species from the Qinghai-Tibet plateau region of China: Discovery and epidemiological implications. *Parasitology International*, 55, 233-236.
 56. Zhang, W., Li, J, and McManus, P. D. (2003): Concepts in immunology and diagnosis of hydatid disease. *American Society Microbiology*, 16(1):18-36.

4/1/2017