


During our last visit to Nha Trang there were two Laotian surgeons who came to observe two surgical procedures that we were performing on the kidney. They have invited us to go to Laos to meet with the medical establishment and set a similar program there.

I have also been asked by a charitable institution in southern India to visit their hospitals and see if we can improve their delivery of medical services. Because of these requests, I will be returning to South Asia in February of next year to visit hospitals in Laos, Cambodia, and southern India to assess their needs and see where we can be of assistance. Because of our expanding role in this area and because all the doctors volunteer their time and resources to this endeavor, I will be establishing a website that will be giving us more exposure.

Once again, I want to thank all my friends for their support in the past and hope that their financial support continues in the future.



All contributions can still be made to:

MILPHAP-19
c/o Gerald Zelikosky, MD
5 East 84th Street
New York, NY 10028

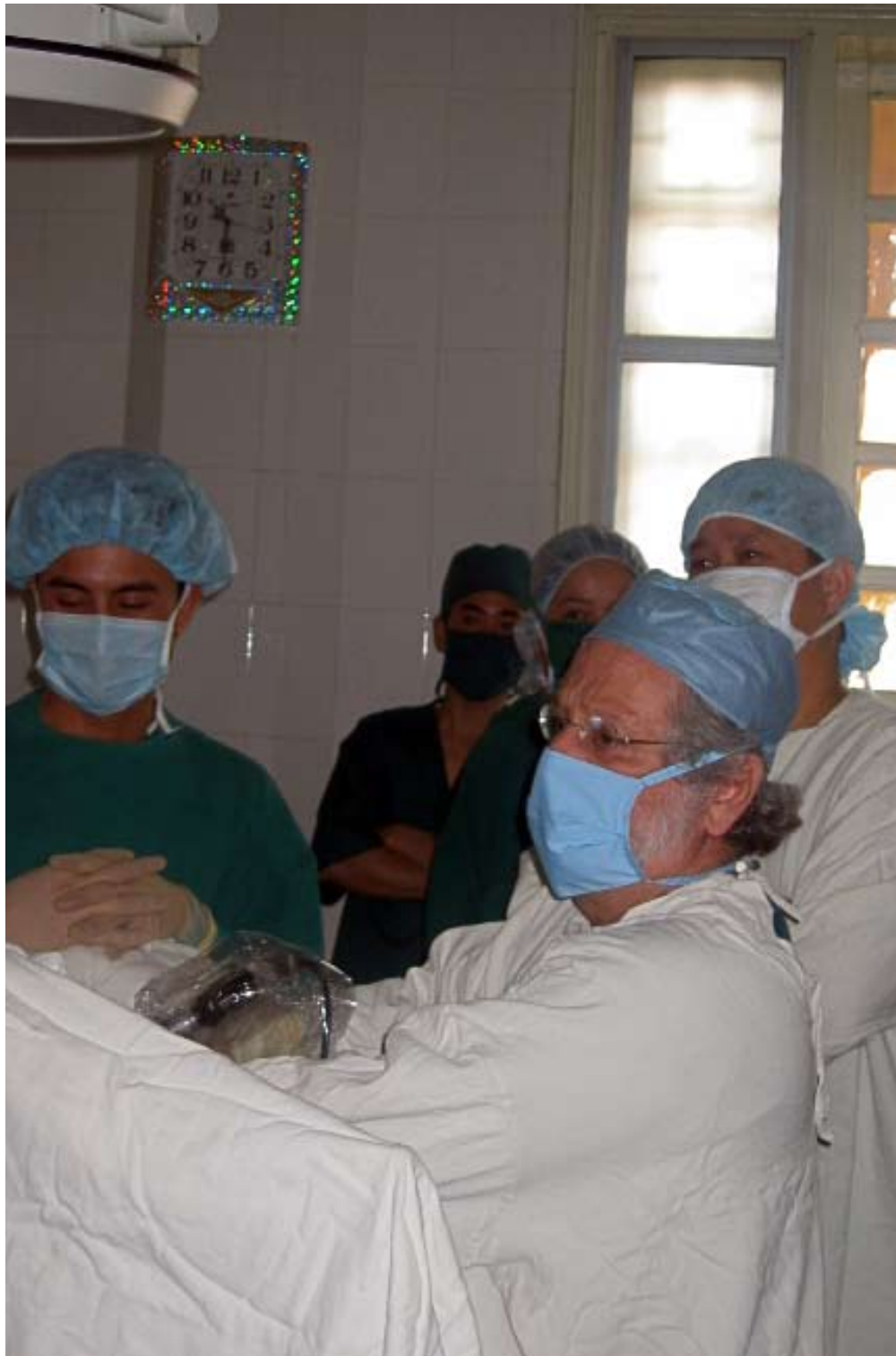MILPHAP-19 (Vietnam, MD) News Letter 2009



MILPHAP TO EXPAND SERVICES BEYOND VIETNAM



Ethnic minority children of Kontum Province



Dr. Zelikovsky performing first prostatectomy ever done in Kontum

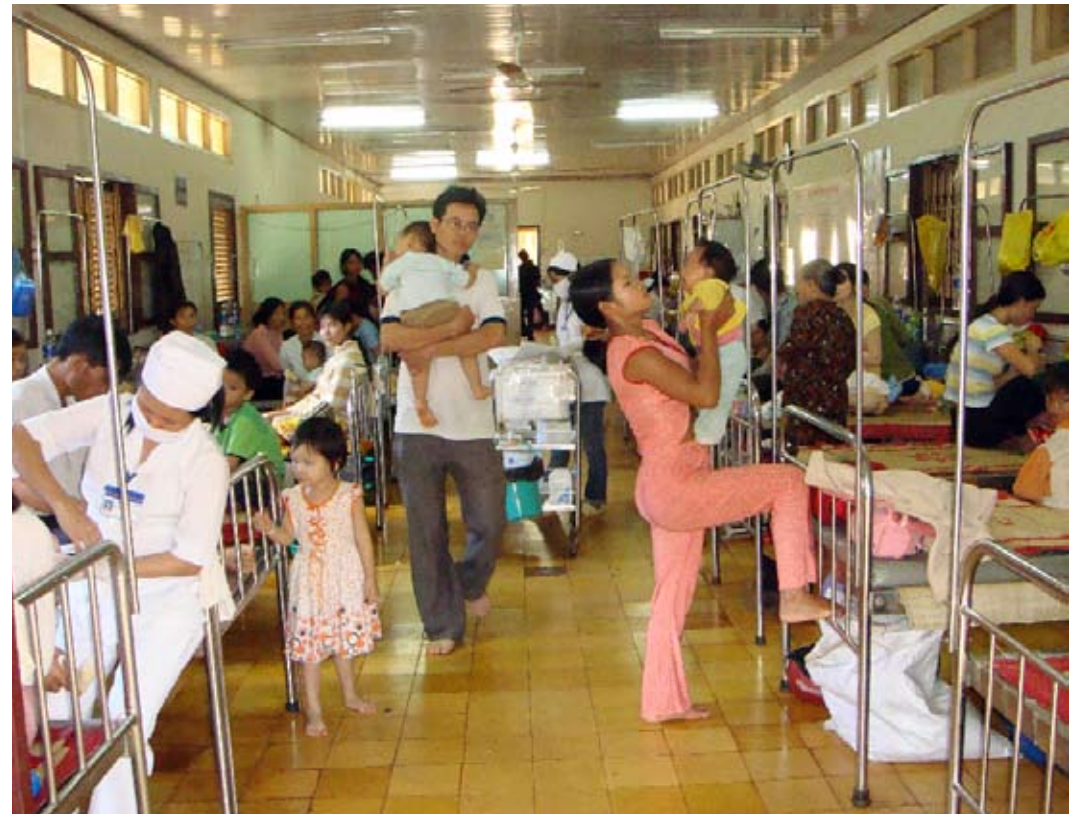

fig.11 Above Ghia Nghia Hospital-Built in the 1920s

fig.12 Below Hospital Now under construction



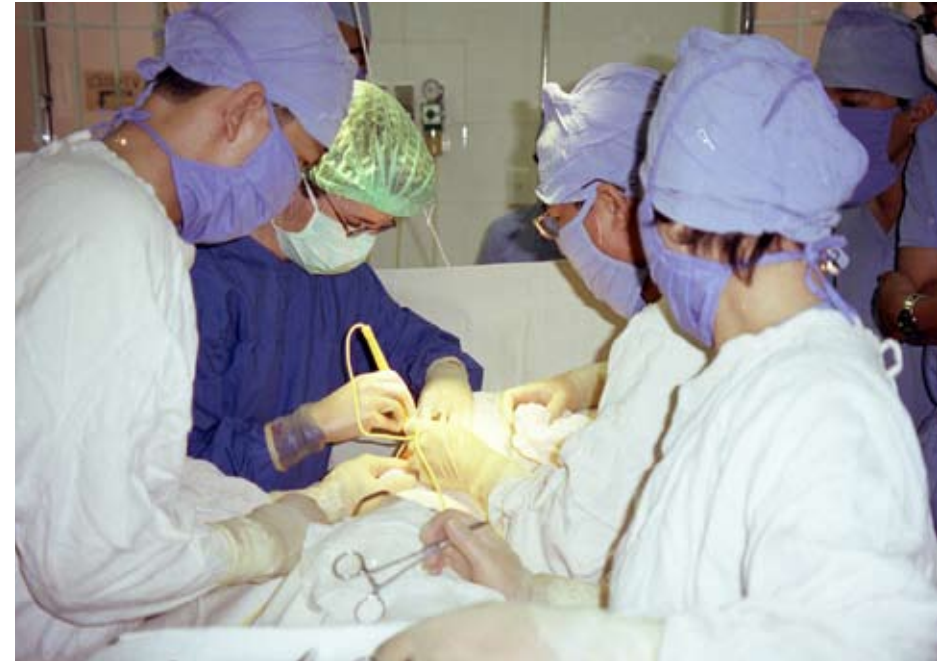
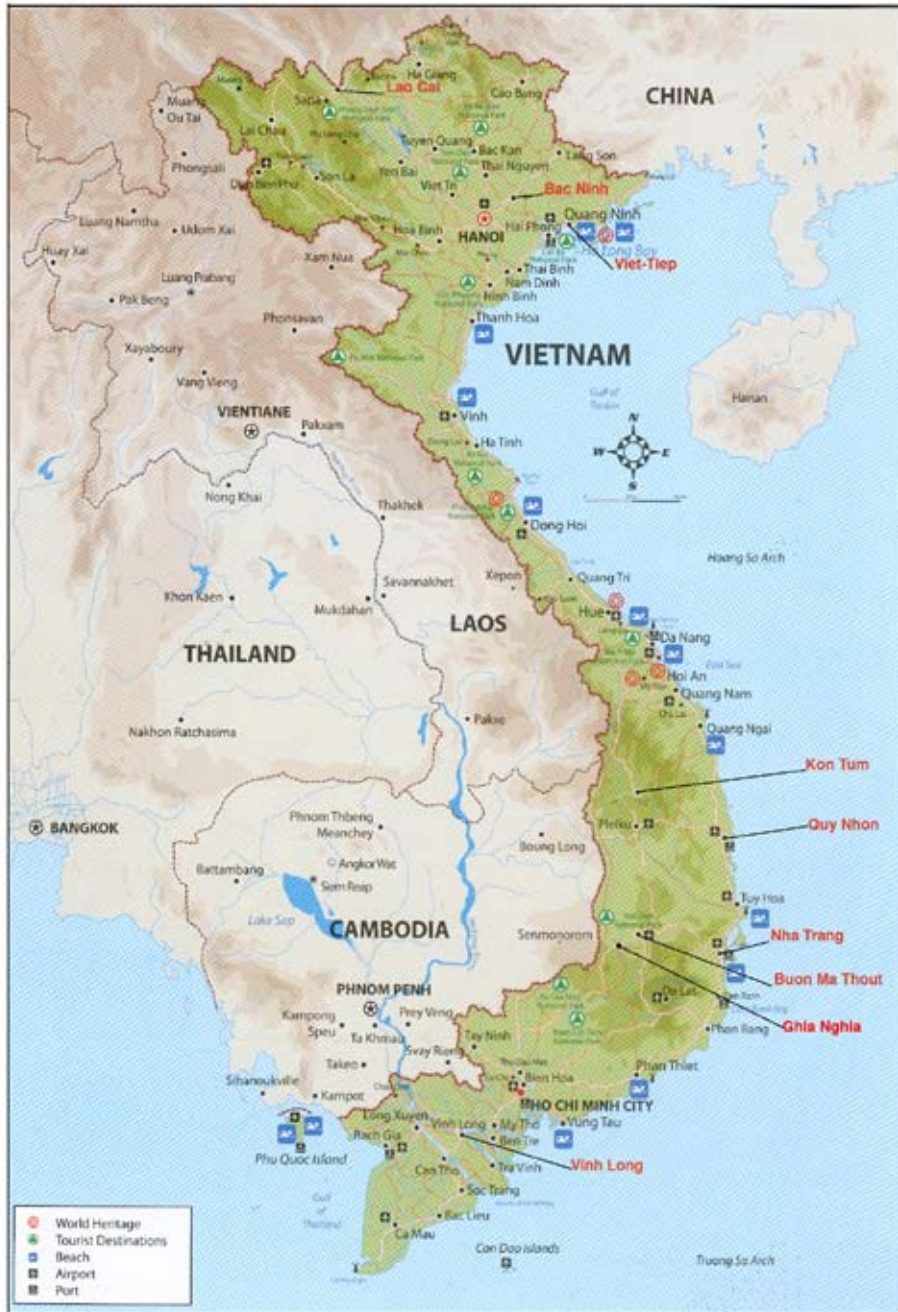

fig. 2 Dr. Karen McGuiness

Our mission statement is to promote and advance medical education and improve medical care in Southeast Asia. We have done this by providing medical equipment to various remote hospitals throughout Vietnam and instructing the surgeons on its use. MILPHAP-19 has been more successful than I had originally imagined when we

started this program 11 years ago.

Prostatic surgery was unknown and the equipment necessary for this was not available throughout most of Vietnam. We donated this equipment and have instructed the local surgeons on its use at six province hospitals scattered throughout Vietnam. All of these surgeons have become very proficient.

MILPHAP has established surgical training programs in the cities indicated in red.

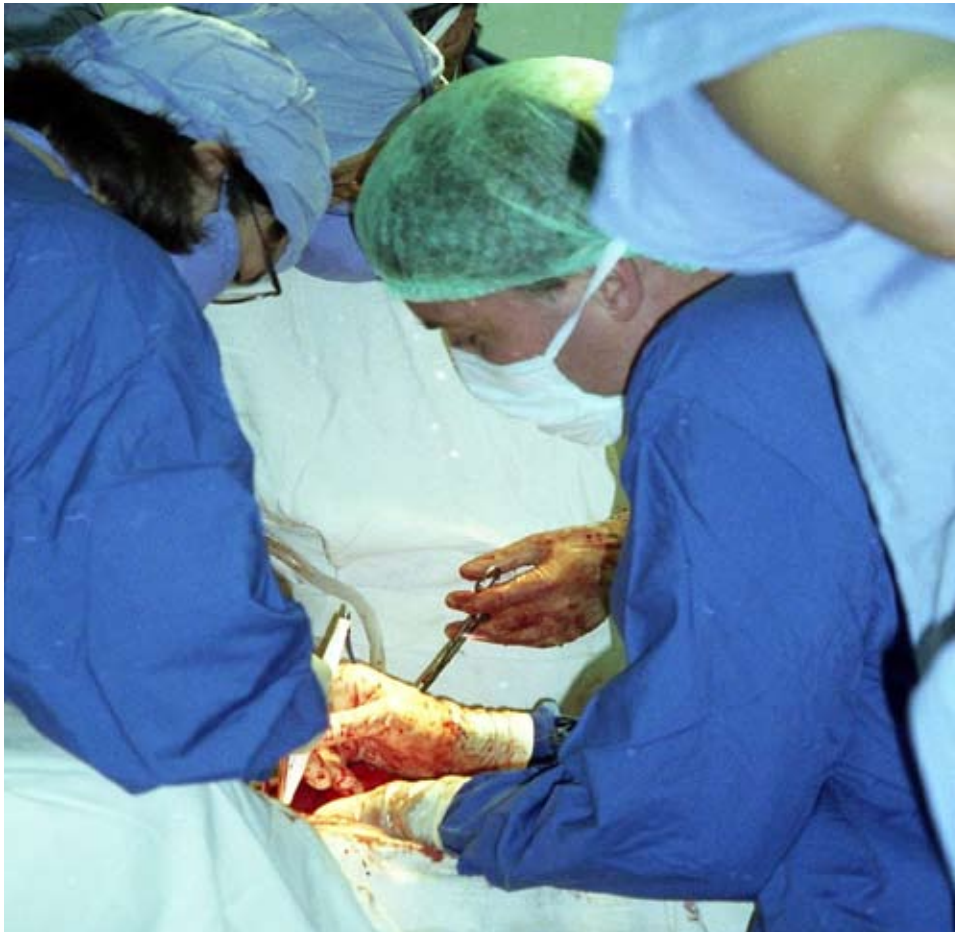

fig. 3 Dr. Ronald Chamberlin

Dr. Karen McGinnis performed the first open lung surgery ever done in Nha Trang Province Hospital, removing a cancerous lung, and instructing the local surgeons on this technique. *fig.2*

Dr. Ronald Chamberlain instructed local surgeons on new techniques in surgery of the large intestines and the gall bladder in Nha Trang, Vinh

Long, and Ghia Nghia. *fig.3*

Dr. Jerome Siegel and Dr. Franklin Kasmin have taught advanced techniques in endoscopic surgery of stone in the bile ducts that drain the liver in Vinh Long, Nha Trang, Ghia Nghia and Lao Cai. *fig. 4*

An additional mission that MIL-PHAP has undertaken is to provide



THIS IS THE HOME OF THE YOUNG GIRL OF THE CENTER FOLD WITH HER FAMILY, AN EXAMPLE OF REAL POVERTY!

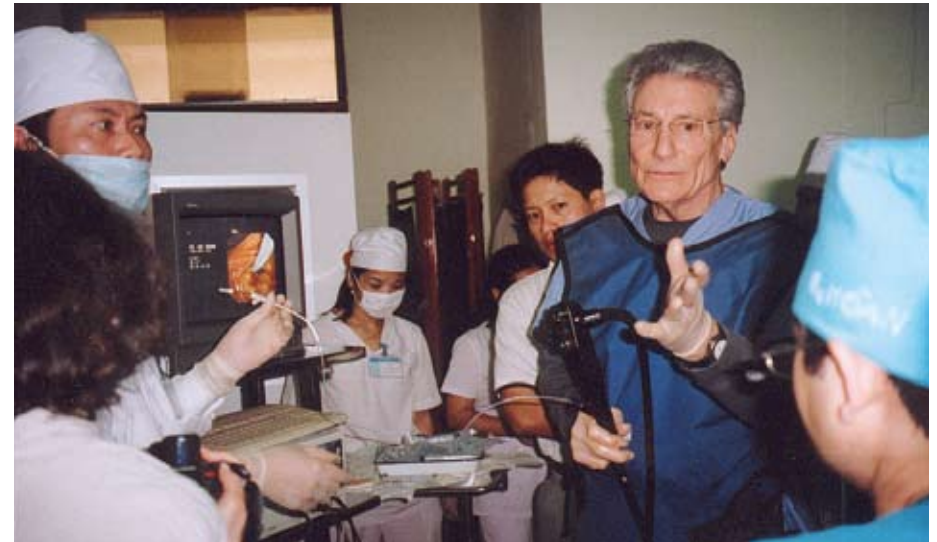progress of the local surgeons and provide them with more advanced surgical equipment as needed.

The Doctors in Ghia Nghia are still working in a hospital that was built by the French in the 1920s. They are in the process of constructing a new facility that should be completed in the spring

of 2010. They have requested that we return at that time with physicians in as many specialties as possible to help them move into the hospital. This should be a very satisfying and important project and will greatly improve the medical care to this community, which is one of the poorest in Vietnam. *fig. 11 - fig. 12*




fig. 9 Child at 3 1/2 years Below Children of Catholic Orphanage in Nha Trang



Above fig. 4 Dr Jerome Siegel

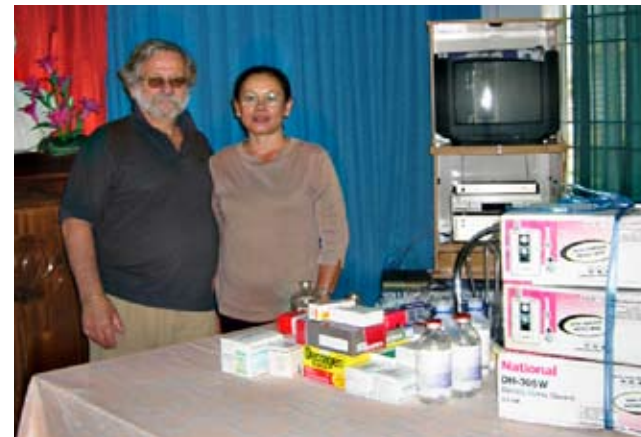

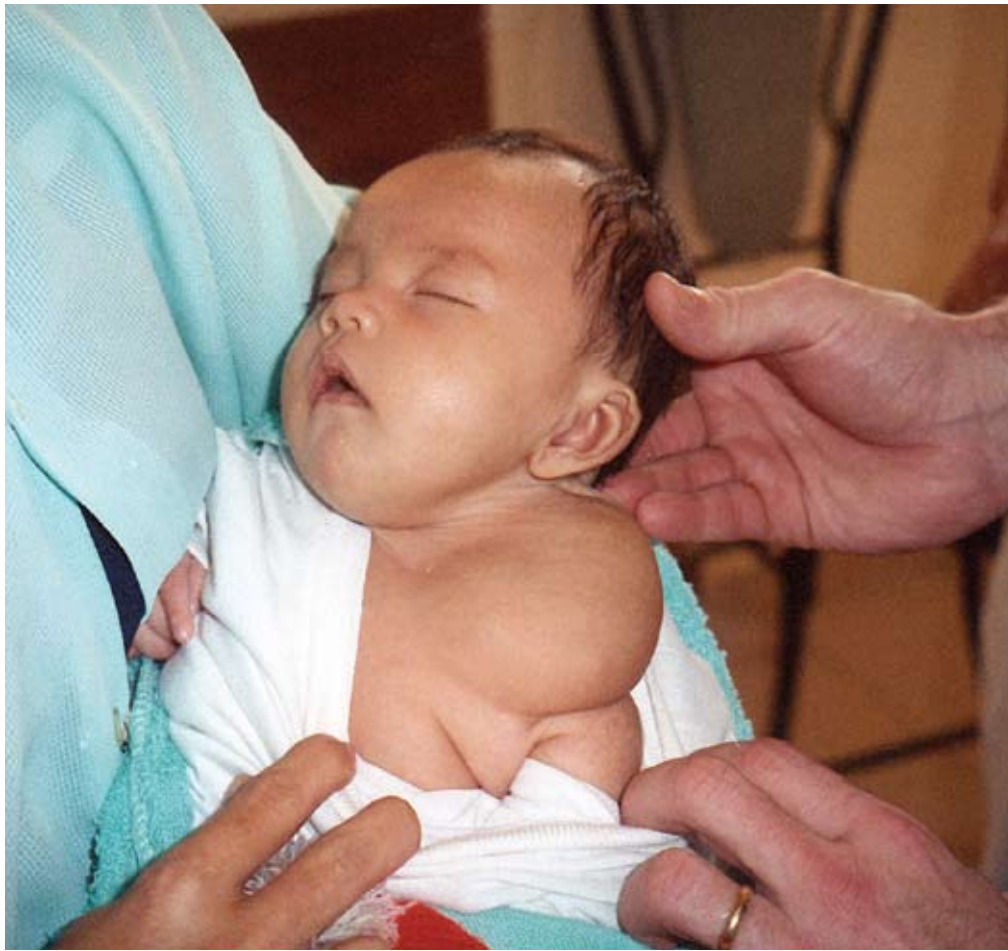fig. 5 Orphanage in Nha Trang

medicine and purchase appliances to improve the health and hygiene of orphanages located in the cities whose hospitals we come to work in. We did this in Nha Trang, Buon Ma Thuot, Kon Tum, and Lao Cai. fig.5

A third undertaking that we've done is to subsidized surgery on indigenous Vietnamese, whose needs can only be met by specialists out-

side of the area in which we engaged. We provided the funds necessary to transport a six-week old baby with a large benign tumor of the neck and her parents to go to Ho Chi Min City for the required surgery. The results were spectacular. fig. 6,7,8,9,

We will continue to return to Vietnam in the future to monitor the



Above fig.6 Child at age 6 weeks Below fig.7 Child at 10 weeks
Next page fig.8 Child at 2 Years

