

DiGeorge Syndrome Can Be Presented with Hydrops and Asubtle Dysmorphic Features

Dr. Sohier Ahmed¹, Dr. Wahid Ali Agab², Dr. Suad Rashid Al Amer³

¹Senior Resident- Department of Paediatrics BDF Royal Medical Services

²Senior Consultant Paediatrician & Paediatric Infectious Diseases & Rheumatologist Department of Paediatrics BDF Royal Medical Services

³Consultant Paediatric Cardiologist Department of Cardiology BDF Royal Medical Services

Abstract: Presentation of digeorge syndrome can be mainly with congenital cardiac defect and affected fetus usually have cardiac anomalies such as truncus arteriosus, tetralogy of fallot, ventricular septal defect, pulmonary atresia or interrupted aortic arch. (4), (5). The most common cardiac defect in a baby with 22q11.2 is truncus arteriosus and interrupted aortic arch. Antenatally polyhydraminos can be detected by ultrasound and fetus microphally, thymic hypoplasia, renal anomalies, and cleft palate can be also detected by ultrasound. We reported acase of neonate born with massive pleural effusion, generalized odema, hydrocele and few dysmorphic features. Fish study confirmed micro deletion of 22 q 11.2 and echo revealed finding of truncus arteriosus

[Dr. Sohier Ahmed, Dr. Wahid Ali Agab, Dr. Suad Rashid Al Amer. **DiGeorge Syndrome Can Be Presented with Hydrops and Asubtle Dysmorphic Features.** *Biomedicine and Nursing* 2017;3(4): 95-96]. ISSN 2379-8211 (print); ISSN 2379-8203 (online). <http://www.nbmedicine.org>. 9. doi:[10.7537/marsbnj030417.09](https://doi.org/10.7537/marsbnj030417.09).

Keywords: DiGeorge Syndrome; Hydrops; Asubtle Dysmorphic; Feature

Introduction

DiGeorge syndrome was first described as a primary immunodeficiency in 1968. Microdeletion of chromosome 22q11.2 results in dysmorphogenesis of the 3rd and 4th pharyngeal pouches early in gestation and this leads to thymic and parathyroid hypoplasia and other abnormalities including congenital heart defects.

Neonate can present with hypocalcaemia as a result of underdeveloped parathyroid gland which can lead to seizure in neonatal period. Presence of hypocalcemia and seizure together with dysmorphic features can be warning sign suggestive of DiGeorge syndrome. Most patients with DiGeorge syndrome have a partial form of the disease and thymic hypoplasia. This defect results in cellular immunodeficiency, although humoral defects have also been described. Autoimmune diseases have been associated with DiGeorge syndrome, Probably in consequence of Tcell regulatory defects and impaired central tolerance (1).

The main cardiac abnormality is conotruncal defect and several authors have pointed out that isolated congenital heart disease may be associated with it (2). New born can present with lymphopenia and screening at neonatal period have been encouraged by several studies (3)

Case Presentation

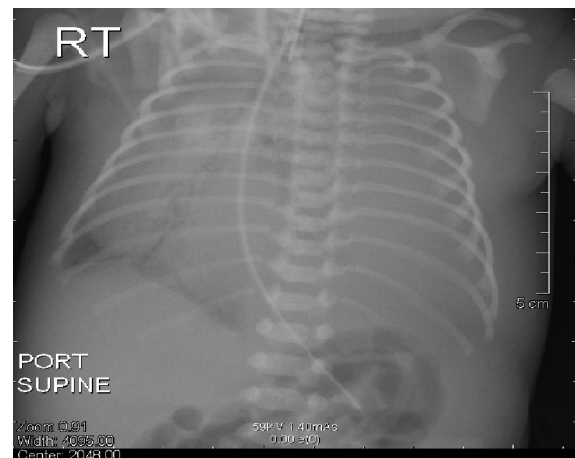
We are reporting an infant boy born at Bahrain Defence Force Hospital at 32 weeks gestation by spontaneous vaginal delivery. He was appropriate for gestational age with a birth weight of 2 Kgs.

Baby was intubated in the labour room for shallow breathing and bradycardia. He received one

dose of Adrenaline through umbilical vein, then shifted to the Neonatal Intensive Care Unit and connected to mechanical ventilator. Oxygen saturation was fluctuating between 70-75% on room air.

On Examination, baby looked Dysmorphic with micrognathia and low set ear. He was pale with peripheral cyanosis but not jaundiced. Auscultation of the chest revealed decreased air entry bilaterally. Heart sound heard on the right side of the chest at the 4th intercostal space and there was grade-III systolic murmur as well. Abdomen was soft, lax with palpable liver 3 cm below the right costal margin. Genitalia normal phallus size descended testicles with hydrocele.

An urgent Chest X-ray done showed massive left pleural effusion and cardiomegaly.



Echocardiogram was revealed Levocardia, dextroposition, Truncus arteriosus Type-I, situs solitus, large VSD 7 mm with left to right shunt, small ASD. There is massive left pleural effusion that was managed by inter costal device insertion. Oxygen saturation improved to 80-85%. Lasix and Aldactone were started initially and later Digoxin was added as the repeated Chest X-Ray showed no improvement in his cardiomegaly.

All his lab investigations were normal. These include CBC, Urea & Electrolytes, TFT, LFT. The karyotyping showed 46, XY but Fish study showed Microdeletion on chromosome 22 at band 22q 11-2. (DiGeorge syndrome).

Hypocalcaemia, Hypokalaemia, Hyponatremia and Hypoalbuminaemia were Corrected

Baby spent 108 days in the Neonatal unit and discharged with a weight of 2.7 Kgs. Corrected age 7 weeks. Tolerating feeds 45 ml 3 hourly and discharged on supplemental oxygen via nasal prongs and the targeted saturation is > 80%. Parents were given oxygen cylinder and suction machine for home use along with being taught physiotherapy at home and sent on Aldactone, Lasix Syrup and Digoxin. future plan of cardiac treatment is surgical truncus repair

Discussion

DiGeorge syndrome can be presented at birth with heart failure as a result of congenital heart defect such as tetralogy of fallot, truncus arteriosus, and pulmonary atresia and interrupted aortic arch (4). The congenital heart defect in a few cases can lead to fetal congestive heart failure or hydrops which is non-immune type of hydrops fetalis (7). Hydrops fetalis is a serious fetal condition characterized by accumulation of fluid, or oedema in at least two fetal compartments, including ascites, pleural effusion, pericardial effusion and skin edema. also impaired renal function causes oliguria or anuria and subsequent hydrops (8). That case we presented above was born with congestive heart failure, massive pleural effusion and generalized oedema and few dysmorphic features. All this finding can give an indication to the different phenotypes that DiGeorge syndrome can present with it.

Dysmorphic features although easily recognized, may be subtle in some patients, and growth of the face and consequent accentuation of abnormalities become more noticeable as they grow older. DiGeorge syndrome diagnoses are based on a set of clinical finding or 22q11.2 deletion, but 22q11.2 deletion is only investigated when there are signs suggesting that the patient may have the syndrome. The presented

case was born with few dysmorphic feature such as small mouth, low set ear and micrognathia. This few dysmorphic features together with cardiac problem directed us to request fish study which came positive and confirmed diagnosis of DiGeorge syndrome.

Learning points

- DiGeorge syndrome can be presented with a subtle dysmorphic features.
- Hydrops fetalis can be one of the presentations of digeorge syndrome due to congestive heart failure.
- Early diagnosis and management can improve the patient outcome.

References

1. Piliero LM, Sanford AN, McDonald-McGinn DM, Zackai EH, Sullivan KE. T-cell homeostasis in humans with thymic hypoplasia due to chromosome 22q11.2 deletion syndrome. *Blood*.2004; 103:1020-25. 10.1182/blood-2003.08-2824 [PubMed].
2. jiang L, Hou Z, Duan C, Chen B, Chen Z, Li Y, Huan Y, et al. Isolated congenital heart (2 ((disease is associated with the 22q11.2 deletion even though it is rare. *Int J Cardiol*. [Epub ahead of print] PubMed PMID: 19923022. [PubMed].
3. Routes JM, Grossman WJ, Versky J, Laessing RH, Hoffman GL, Brokopp CD. Statewide Newborn Screening for Severe T-Cell Lymphopenia. *JAMA*. 2009; 302:2465-70. 10.1001/jama.2009.1806 [PubMed].
4. 67. Volpe P, Marasini M, Caruso G, et al. Prenatal diagnosis of interruption of the aortic arch and its association with deletion or chromosome 22q11. *Ultrasound Obstet Gynecol*. 2002; 20:327-331. [PubMed].
5. 68. Volpe P, Marasini M, Caruso G, et al. 22q11 deletions in fetuses with malformation of the outflow tracts or interruption of the aortic arch: impact of additional ultrasound signs. *Prenat Diagn*. 2003; 23:752-577. [PubMed].
6. 69. Devriendt K, Swillen A, Fryns JP, et al. Renal and urological tract malformations caused by a 22q11 deletion. *J Med Genet*. 1996; 33:346. [PubMed].
7. Gary M Satou, MD, FASE Director, Pediatric Echocardiography, Co-Director, Fetal Cardiology Program, Mattel Children's Hospital; Associate Clinical Professor, Department of Pediatrics, University of California, Los Angeles, David Geffen School of Medicine (medscape).
8. Bellini C, Hennekam RC. Non-immune hydrps fetalis: a short review of etiology and pathophysiology. *Am J Med Genet A*. (3):597-605. [Medline].

12/25/2017