

MANDIBULAR SECOND PREMOLAR WITH ATYPICAL ROOT CANAL MORPHOLOGY: A CASE REPORT

Monika Bhardwaj¹, Sandeep Metgud², Karthik Reddy³, Shubh Prabhat Gupta⁴, Harsh Haren Shah⁵, Apoorva Bhatnagar⁶

1. Post graduate student, Pacific Dental College and Hospital, Udaipur, Rajasthan (India)
2. Professor, Pacific Dental College and Hospital, Udaipur, Rajasthan (India)
3. Senior Lecturer, Pacific Dental College and Hospital, Udaipur, Rajasthan (India)
4. Senior Lecturer, Pacific Dental College and Hospital, Udaipur, Rajasthan (India)
5. Private Practice, Mumbai (India)
6. Post graduate student, Pacific Dental College and Hospital, Udaipur, Rajasthan (India)

ABSTRACT:

A thorough understanding of the basic root canal anatomy and its diversities are necessary for successful endodontic treatment. The aberrant morphology of mandibular premolars has always been a challenge for the endodontists. Generally mandibular second premolar is treated to have a single root and canal. Dental literature has documented cases of having three or four root canals in the mandibular second premolar. Among the various configurations having three root canals is as rare as 0.4% (Zillich and Dowson). This case report describes a case of mandibular second premolar with unusual canals that is treated successfully.

Key Words: aberrant morphology, mandibular premolar, three canals, atypical orifice openings, narrowing of canal space



INTRODUCTION:

A clear understanding of the anatomy of human teeth is an essential prerequisite to all dental procedures especially so in the case of root canal treatment which deals with management of the tooth's internal anatomy.^[1] Successful and predictable endodontic therapy depends on the complete cleaning and shaping of the entire root canal system followed by a three-dimensional obturation to create a fluid tight seal. To achieve this, a thorough knowledge of the of the root canal morphology and pulp chamber anatomy is a prerequisite.^[2] The root canal treatment

of mandibular premolars is challenging due to their aberrant root canal anatomy and morphology. These teeth usually have a single root and a single canal, but anatomic variations can occur. The successful non-surgical root canal treatment of such teeth requires the basic knowledge of root canal anatomy and variation from the normal.^[3] Vertucci found that the lower second premolar has a single root with a single ovoid or round canal in 97.5% and two canals in 2.5% cases. Other authors, including Green, have found that one may encounter other situations, although rarely. One may find

two canals joining at a single foramen (4%) or two completely separate canals (4%) or two canals in separate roots [4]. Even cases with three canals have been described. The prevalence of three root canals with three distinct orifices that end in separate foramina was reported to be 0.4% by Zillich and Dowson in 1973.[3]

The purpose of this case report is to describe a mandibular second premolar with three canals having atypical orifice openings in the pulp chamber.

CASE DETAIL:

A 28-year-old male patient with a non-contributory medical history reported to the Department Of Conservative Dentistry And Endodontics, Pacific Dental College, Udaipur with the chief complaint of pain in a mandibular right posterior region of jaw since 9-10 days. The pain was sharp, intermittent and radiating in nature to the right side of the forehead, aggravated on chewing food and while taking cold beverages, and the sleep was disturbed. Pain temporarily relieved on taking medication (Ketorol DT - BID).

Clinical examination revealed deep proximal caries in the right mandibular second premolar and root stump in the adjacent molar. A pre operative radiograph of the involved tooth was taken, which revealed deep proximal caries in tooth right mandibular second premolar (45) with signs of periapical pathosis. The periodontal probing depths were within normal limits. Diagnosis of chronic periapical abscess in right mandibular second premolar was made

and nonsurgical root canal treatment of the tooth 45 was planned.

Pre-operative IOPAR of the tooth 45 revealed an unusual, complex root canal anatomy with two roots. (Fig. 1)

After administration of the local anaesthetic, an access opening was made in tooth 45 under rubber dam isolation. On entry into the pulp chamber, the canal orifices mesiobuccal, distobuccal and lingual canals were identified using a stainless steel size 10 K-file (Dentsply Maillefer, Ballaigues, Switzerland).

Working lengths were determined using an apex locator Propex II (Dentsply) and thereafter confirmed radiographically (RVG) with size 15 K-files inserted in the canals (Fig.2). Following the working length determination, the root canals were prepared with a crown down technique with HERO Shaper (MicroMega, Besancon, France) upto size 25 and were frequently irrigated with sodium hypochlorite and saline. Calcium hydroxide was used as an intracanal dressing to prevent the growth of micro-organisms inside the root canals during the inter-appointment period. The access cavity was sealed with coltosol.

In the next appointment, when the patient was free from pain, following the application of a rubber dam, the calcium hydroxide dressing was removed by irrigation with 5% sodium hypochlorite. The root canals were dried with sterile paper points . Master cones were placed in the canals and IOPA was taken (Fig.3). Canals were coated with root canal sealer

(AH Plus, Dentsply Milford,) and were obturated with 4% ISO size 25 Gutta percha. The access cavity was adhesively sealed with a packable composite (Brilliant NG, Coltene, Whaledent). A post operative radiograph was taken to confirm the quality of the obturation.(Fig.4)

DISCUSSION:

Knowledge of the root canal morphology as well as possible variation in anatomy of the root canal system is important in achieving successful nonsurgical root canal treatment. This is followed by negotiation, cleaning and shaping, and obturation of the entire canal system in three dimensions ^[5].The incidence of the number of roots and the number of canals reported in anatomic studies vary greatly in the literature.

The root canal morphology of the mandibular second premolar can be extremely complex and highly variable. Mandibular premolars may be the most difficult teeth in the mouth to treat ^[6].Therefore, the internal morphology must be identified precisely to achieve successful treatment. The anatomical landmark of the pulp chamber floor may help to identify supplementary root canals or root canal aberrations ^[7]. The mandibular second premolar has far fewer variations than the first premolar, usually having one root and one well-centered canal. Rarely are Type II, III, or IV canal configurations present.^[8]

There are several clinical indications that are useful in detection of a third canal in

the mandibular premolars. A third canal should be suspected clinically when the pulp chamber does not appear to be aligned in its classic bucco-lingual relationship. The pulp chamber that appears to deviate from this normal configuration and seems to be either triangular in shape or too large in a mesiodistal plane should be suspected of opening into a system containing three canals (Bellizzi & Hartm'ell 1981). Although they are difficult to negotiate because of canal curvature and narrowing, most canals in a tooth with three root canals can be located and instrumented using current endodontic techniques.^[9] Also sudden narrowing of the canal or change in radiographic density of the root canal space suggests canal multiplicity.

In the present case, although the root canal morphology was complex, it was clearly determined on the preoperative radiograph. Microscopes are commonly used to explore the pulp chamber in order to find orifices. The advantages of using a microscope for conventional endodontics include better visualization of the pulp chamber floor and walls that prevents inadvertent missing of orifices. Although we did not use a microscope, we recommend it for better visualization.^[3]

Even in the presence of advanced technology, the careful tactile exploration of the root canal system with hand files is imperative. Matherne et al investigated the use of CBCT scanning in identifying root canal systems and compared it with images obtained by using digital

radiography. They concluded that CBCT images always resulted in the identification of greater number of root canal systems than digital images. It has limitations related to the “cone beam” projection geometry, detector sensitivity, and contrast resolution which create an inherent image “noise” that reduces image clarity and may limit adequate visualization of structures in the dentoalveolar region. Even though the use of CBCT scanning involves less radiation than conventional CT scanning, the radiation dose is still higher than regular conventional intraoral radiographs. At this point of time, CBCT scanning is very expensive. Limitations also include medicolegal issues pertaining to the acquisition and interpretation of CBCT data.^[10]

The Hero Shaper are instruments having triple helix cross-section, with positive rake angles. Hero Shaper reduces the risk of instrument screw in, increases the flexibility and optimizes the removal of the debris ^[4]. HERO Shapers was used because of its minimal debridement characteristics that is more effective when used in narrow canals ^[11]. The HERO Shapers is positioned at the canal orifice and is inserted to the selected penetration

level at a constant rotation speed using a slow, regular, short in-and-out movement. The instrument is simply inserted into the canal and then rotated. One of the advantages of using HERO Shapers sequences is that a limited number of files are required: two for easy cases and four for complex cases.^[12]

The diagnosis and management of extra roots or root canals in mandibular premolars is undoubtedly an endodontic challenge. In order to achieve this, the clinician must have a thorough understanding of the normal root canal anatomy and of its common variations.

CONCLUSION:

The anatomy of mandibular premolar can be very complex. Though variations in root canal configurations do not come across regularly, the clinician should very carefully investigate each case clinically and radiographically, to avoid post endodontic flare-ups. The success of this case might be attributed to accurate diagnosis, complete chemo mechanical debridement, and proper obturation of all the three root canals.

REFERENCES:

1. Root Anatomy And Root Canal Configuration Of Human Permanent Mandibular Premolars: A Systematic Review: Jojo Kottoor, Denzil Albuquerque, Natanasabapathy Velmurugan, And Jacob Kuruvilla: Hindawi Publishing Corporation Anatomy Research International Volume 2013, Article ID 254250, 14 pages
2. Ingle and Bakland. Endodontics. 5th Ed; 2002.
3. A Mandibular Second Premolar With Three Canals And Atypical

Orifices :Mehrddad Lotfi, Sepideh Vosoughhosseini, Vahid Zand, Ali Fatemi, Vahab Shyezadeh And Bahram Ranjkesh: Journal Of Oral Science, Vol. 50, No. 3, 363-366, 2008

4. Arnaldo Castellucci :Endodontics Volume I
5. The Root And Root Canal Morphology Of The Human Mandibular Second Premolar: A Literature Review:Blaine M. Cleghorn, William H. Christie, And Cecilia C.S. Dong: JOE — Volume 33, Number 9, September 2007
6. Slowey Rr. Root Canal Anatomy: Road Map To Successful Endodontics. Dent Clin North Am 1979;23:555–73.
7. De Moor Rj, Calberson Fl (2005) Root Canal Treatment In A Mandibular Second Premolar With Three Root Canals. J Endod 31, 310-313

8. Endodontic therapy.: Weine 6th Ed.; Mosby, St. Louis, 2004.
9. Mandibular Premolar With Three Root Canals—Two Case Reports :Kam Chan, Siu-Chun Yew& Shou-Yee Chao: International Endodontic Journal 1992: 25. 261-264
10. Maxillary First Molar with Seven Root Canals Diagnosed with Cone-Beam Computed Tomography Scanning: A Case Report: Jojo Kottoor, Natanasabapathy Velmurugan, Rajmohan Sudha, and Senthilkumar Hemamalathi: JOE — Volume 36, Number 5, May 2010
11. Shaping Ability Of Twisted File,Hero Shaper And Profile 0.6 Ni-Ti Instruments In Simulated Curved Root Canals: Love RM And Masi OV: Dentistry- Vol. 3- Issue 3
12. Heroshapers: The Adapted Pitch Concept :Paul Calas : Endodontic Topics 2005, 10, 155–162

FIGURES:

Fig. 1: Pre Operative Radiograph

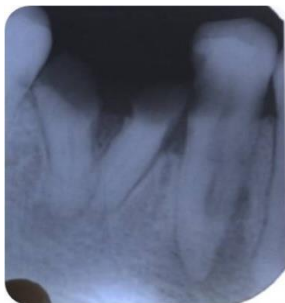

Fig.2: Working Length Radiograph

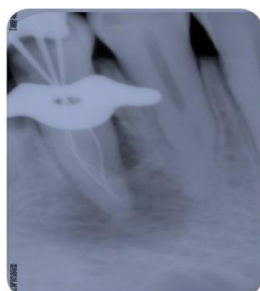


Fig.3: Master Cone Radiograph

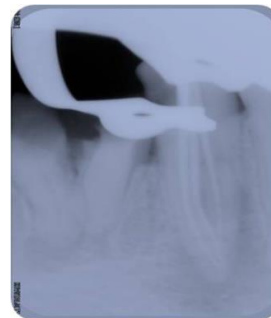


Fig.4: Postobturation radiograph

