

# IDENTIFICATION OF THE SECOND MESIOBUCCAL CANAL IN FIRST MAXILLARY MOLAR USING ULTRASONICS AND VISUALS AIDS

Soumaya Touzi<sup>1</sup>, Dorsaf Jarrar<sup>2</sup>, Kamel Argoubi<sup>3</sup>, Tarek Abuhamed<sup>4</sup>, Mounir Cherif<sup>5</sup>, Abdellatif Abid<sup>6</sup>

1. Associate professor, Department of Dental Anatomy, Faculty of Dentistry, Monastir University, Monastir, Tunisia

2. Assistant Professor, Department of Pediatric and Preventive Dentistry, Faculty of Dentistry, University of Monastir, Monastir, Tunisia

3. Professor, Department of Pediatric and Preventive Dentistry, Faculty of Dentistry, University of Monastir, Monastir, Tunisia.

4. Doctor in dental Medicine. Tunisia.

5. Head of department of fixed prosthodontics, Department of Fixed Prosthodontics, Faculty of dentistry, University of Monastir, Monastir, Tunisia

6. Head of department of pediatric and preventive Dentistry. Department of Pediatric and Preventive Dentistry, Faculty of Dentistry, University of Monastir, Monastir, Tunisia

## ABSTRACT:

**Aim:** The aim of this study was to investigate the frequency of the second mesiobuccal canal in extracted permanent maxillary first molars in a Tunisian population, and to evaluate the role of the ultrasonic inserts and visual aid (binocular loupes, operator microscope) in its localization.

**Materials and methods:** Eighty extracted human maxillary first molars were assessed. After location of the main canals, the second mesiobuccal canal was sought in all teeth first with k files, then with of ultrasonic inserts, after that with the aid of the binocular loupes and operator microscopes. Finally, the mesiobuccal root was sectioned horizontally into three levels and was observed under a stereomicroscope.

**Results:** Using these techniques, the second mesiobuccal canal was detected in 9.46%, 16.21 %, 29.72 %, and 39.189 % respectively. Sectioning of the roots disclosed the presence of the MB2 canal in 75,67% of the teeth.

According to Weine's classification, 24% of the teeth are of type I, 47,29% of type II, 13,51% of type III and 2,70% of type IV.

The two root canals in the mesial roots ending in one foramen in 79.73% , and 20,27% ending in two apical foramen.

**Conclusion:** The results of this study suggested that the combined use of the operating microscope and ultrasonics increased the detection of second mesiobuccal canals in maxillary first permanent molars.

**Keywords:** Maxillary permanent first molar, Mesiobuccal second canal, Operator microscope, Binocular loupe, Ultrasounds

## INTRODUCTION:

Weine's work has shown that a great number of failures in endodontic treatment of maxillary first molars due

to the absence of localization, shaping and closing of the fourth canal. <sup>[1]</sup>

Between 2002 and 2005, a clinical study conducted by Wolcott et al in 5616 cases concludes that the absence of the second mesiobuccal canal (MB2) treatment reduced the long-term prognosis and may explain some of the pathologies observed on the maxillary molars requiring endodontic retreatment. [1]

The incidence of having two canals in the mesial root of the maxillary first molar has been well established by several authors using different approaches, such as radiographs, decalcification, sectioning, ultrasonic, loupes and dental operating microscope as illustrated [2]

The purpose of the present study was to report the incidence of two root canals in the mesial root of the extracted permanent maxillary first molars of a Tunisian population [2] ; and to investigate whether the use of ultrasonics in combination with binocular loupes and an operating microscope increase the detection of the MB2 canals in extracted permanent maxillary first molar teeth.[3]

## **MATERIALS AND METHODS:**

A total of 80 first permanent maxillary molars of Tunisian patients, were collected from clinical procedures performed in different Tunisian hospitals.

Before use, the teeth were stored in 5% hypochlorite solution for a week.

Then the access cavity was carried out using a cylindro-conical diamond bur

giving it an optimal form approaching that ideal. The use of endo Zekrya bur eliminates all pulpal ceiling.

The access cavity is slightly mesialated to an imaginary line between the mesiobuccal canal and the palatal canal. The aim of this modification was to find a possible second mesiobuccal canal.

Clear visualization of the pulpal chamber floor as well as the main root canal orifices was attained.

After the highlighting of the three main canal, the fourth canal was found by using a probe 16 DG, files K n° 8, n° 10 and n° 15.

In teeth where the MB2 could not be identified, a dry abrasive ultrasonic insert was used to peel the dentin depending on the colors of the floor and of the mesial line connecting the MB1 to the palatal canal.

Between each action of the insert, a rinsing was carried with sodium hypochlorite; a DG16 probe was used as well as manual K files of diameter 8, 10 and 15 in an attempt to identify that canal.

When MB2 was found, the tooth was excluded from further manipulations.

As far as teeth where search for MB2 appeared more delicate, dentin removal without visual aid must not exceed a depth of 2 to 3 mm below the pulpal floor.

After that, binocular loupes were used to search MB2 in the teeth which it could

not be identified. Research of MB2 then continued using alternately the ultrasonic insert, the probe and K-files to try again to enter the canal.

In the next step the teeth of which the MB2 was not found in the previous one, were carefully examined using an operating microscope using a magnification of 10. The same operation was then performed (using alternately the insert ultrasonic probe and limes to try again entering the canal (figure1).

During manipulations three of teeth were perforated and three other were calcified, so they had not been taken into account.

In the last step, the 74 teeth were then sectioned transversely at three different levels:

At the coronal third, middle third and apical third of the mesiovestibular root. These cuts were made using a metal disc mounted at a counter angle. This step allowed us to corroborate or not our results to the anatomical reality. Thus, root canal configuration contained in the root could be determined through the use of the stereomicroscope.

## RESULTS:

We noted that the percentages were performed on only 74 teeth because three of them were perforated during handling and three are calcified, have not been taken into account. Without visual aids or ultrasonic inserts, the MB2 canal was located in seven teeth (9.46%). With the use of the ultrasonic inserts,

the MB2 was located in five additional teeth shifting to a percentage of (16.21%). With the use of binocular loupes MB2 was found in ten other teeth, the percentage become (29.72%). Finally with the use of the operating microscope, the MB2 canal was located in seven additional teeth (39.18%) (table 1).

Sectioning of the mesiobuccal root disclosed the presence of a MB2 canal in twenty seven more teeth 75.67% (table 2).

According to Weine's classification, the distribution of canal configuration of mesiobuccal canals was as follows: 18 (24.32%) were type I, 35 (47.29%) type II, 10 (13.51%) type III, and 2 (2.70%) were type IV canal configuration. Nine no defined type 12.16% correspond to mesiobuccal roots whose configuration cannot be classified in four types of Weine (Table 3).

## DISCUSSION:

### Percentage of MB2:

In our study it was found that 75.67% of maxillary first molar possessed a second mesiobuccal canal. This is consistent with the findings of Aysun Kara T. et al. [7] and Somma et al. [6], who found respectively a percentage of 78.18% and 80%. Other studies have found nearby results like the study of Harry H. Peeters et al. [8] and Atool Chandra B. et al. [12] who found respectively 68.5% and 65%.

Other in vitro studies found a percentage a bit remote compared to our study and to the mentioned above studies such as that : of TOURÉ B. and al. [3] 51 %, Adnan AH. [9] 40% , Bestoon M. et al [10] 35.6%, Farhana C. et al. [11] 36%, Ainul Husna A. et al. [14] 28%.

In vivo studies show the lowest results of all studies, it is approximately 23% by Al-Nazhan .S [4] and Abeer S. Al-Khriesat et al. [13]

Limited access and visibility and non-constant location of the second canal as well as the risk of perforation may explain the lower incidence of having two canals in the mesial root of maxillary molars in clinical practice when compared with laboratory studies. The use of dental loupes and dental operating microscope (DOM) provides the clinician with superior lighting and magnification improving the ability to treat cases and finding extra canals [15]

There is a lack of consistency in the reported incidence of second mesiobuccal canal (MB2) in maxillary 1st molars in the literature. The differences may be due to the study design (clinical versus laboratory), method of canal identification (radiographic examination, root sectioning, canal staining and root clearing, examination with SEM or cone-beam computed tomography techniques) or true differences in the sample under investigation (racial variation) [13]

#### **Root canal configuration:**

According to Weine's classification, in our study the root canal configuration was: 24.32% of type I, 47.29% of type II, 13.51% of type III, 2.70% of Type IV, 12.16% with no type defined.

Furthermore, canal configuration of mesiobuccal root of maxillary first molar teeth could be varied according to different ethnic groups.

Most studies find that class II is the most frequent, such as the study of Adnan AH done on a Syrian population. [9] with 71%, Farhana C. et al. [11] with 38.88% done on a Bangladeshi Population, Aysun Kara T. et al. [7] with 82.4% done on a Turkish population, which is consistent with our study.

Our results do not coincide with the results of B. Touré [3] was done on a Senegalese population that finds that the class I is the most frequent with 46.2%, but they are close to the class III with 19.2% and IV with 2.9% .

#### **Use of visual aids**

We found 12 teeth (16.21%) (before section) without visual aid. The binocular loupes have allowed to locate 10 teeth, the percentage increases (29.72%) and with the microscope 7 teeth the MB2 was found in (39.18%) of teeth. Among these 7 teeth found, two present 5 canal entrances.

Burhly et al. [15] show that the use of visual aids can detect MB2 much more easily. In fact, without visual aids, it is found in only 17.2% of the analyzed teeth. With the help of magnifiers

Binocular, the percentage increases to 62.5% and after use of the microscope procedure, the MB2 was found in 71.1% of cases.

Tayfun Alaçam et al.<sup>[16]</sup> found that the combination of the operating microscope and ultrasonics detected significantly more MB2 canals (74%) than when no microscopy was utilized (67%). Sectioning of the roots disclosed the presence of the MB2 canal in 82% of the teeth.

The results of these studies suggested that the combined use of the binocular loupes ,the operating microscope and ultrasonics inserts increased the detection of MB2 canals in maxillary first permanent molars.

## REFERENCES:

1. Arbona L. Le MV2 de la première molaire maxillaire. L'information dentaire 2011 ;31 : 1-7.
2. Bestoon M. F.et all. The Incidence of Two Root Canals in the Mesial Root of the Extracted Permanent Maxillary First Molars Among a Sulaimani-Iraq Population (Ex Vivo Study). Tikrit Journal for Dental Sciences 2012; 2:106-9.
3. Touré B.et all. Configuration of the mesiobuccal root of the maxillary first molar.Study in senegalese population. Rev Odont Stomat 2006;35:197-203.
4. Al-Nazhan S. The Prevalence of Two Canals in Mesial Root of Endodontically Treated Maxillary First Molars among a Saudi Arabian Sub-Population. DENTAL NEWS 2006; 13(1): 46-52
5. BAL S. Nombre de canaux par dents traités dans un cabinet d'endodontie Étude clinique prospective de 1999 à 2007. Clinic 2008 ; 29 :1-9. [in french]
6. Somma F. et all. Root canal morphology of the mesiobuccal root of maxillary first molars: a micro-computed tomographic analysis. International Endodontic Journal 2009 ; 42 :165–174.
7. Tuncera A K.et all. The Location and Accessibility of the Second Mesiobuccal Canal in Maxillary First Molar. European Journal of Dentistry January 2010 ;4:12-6.
8. Harry H. P. et all. Prevalence of a second canal in the mesiobuccal root of permanent maxillary first molars from an Indonesian population. Journal of Oral Science 2011; 53(4) : 489-94
9. Adnan AH. Anatomical study of the mesiobuccal root in maxillary first

## CONCLUSION:

When performing endodontic therapy on maxillary first molars, the clinician should always assume that there are two canals in the mesiobuccal root, until proven differently.<sup>[9]</sup>

Root canal treatment should be performed under visual aids (binocular loupes and microscopy) with the help of an ultrasonic tip. The visual aids provide good visibility and the ultrasonic tip can create a deeper trough in the dentin. Use of these devices increases the likelihood of finding MB2 orifices <sup>[15,17,19]</sup>

- molars. Journal of Taibah University Medical Sciences 2014; 9(2): 123-25.
10. Bestoon M.F. Prevalence of MB2 canal in maxillary first molars. An in vitro study on the Sulaimani population. International Journal of Medicine and Medical Science Research 2014; 2(3): 039-042.
  11. Farhana Chowdhury et all. Canal Configuration of Mesiobuccal Root of Maxillary First Permanent Molar Teeth in Bangladeshi Population: An in-Vitro Study. International Medical Journal 2014; 21(5): 493 -95.
  12. Bhuyan A. Ch et all. Root canal configuration of permanent maxillary first molar in Khasi population of Meghalaya: An in vitro study 2014. Journal of Conservative Dentistry;17(4), 359-63.
  13. Al-Khriesat A.S.et all. The Incidence of a Fourth Canal in Maxillary and Mandibular First Molars in a Group of Jordanians: A Clinical Study. Journal of the royal medical services 2014; 21(4): 32-38.
  14. Ainul Husna A.L et all.CBCT Diagnostic Application in Detection of Mesiobuccal Canal in Maxillary Molars and Distolingual Canal in Mandibular Molars: A Descriptive Study. J Dent Oral Health 2015; 1 (1) :1-3.
  15. Bührley LJ et all. Effect of magnification on locating the MB2 canal in maxillary molars. J Endod 2002 ;28(4):324-7.
  16. Alaçam T.et all. Second mesiobuccal canal detection in maxillary first molars using microscopy and ultrasonics. Australien Endodontic Journal 2007;1-4.
  17. Alaçam T. Second mesiobuccal canal detection in maxillary first molars using microscopy and ultrasonics. Australian Endodontic Journal 2008;34:106-9.
  18. Görduysus MO, et all. Operating microscope improves negotiation of second mesiobuccal canals in maxillary molars. Journal Endodontic 2001; 27: 683-86.

**TABLES:**

Table 1: Percentage of the presence of MB2 for different search techniques

	Number of teeth in the sample concerned	Number of MB2 detected	Percentage of MB2 reported to the overall sample	Total percentage of MB2 after each step
Without ultrasonic inserts and visual help	74	7	9.46%	9.46%
Using ultrasonic inserts	67	5	6.75%	16.21%
Using a binocular loupes	62	10	13.51%	29.72%
Under The operative microscope	52	7	9.46%	39.18%
Total		29	39.18%	

Table 2: Percentage of MB2 after section of mesio buccal root

Number of CMV2 found	56
percentage	75.67%

Table 3: Types of canalar configuration and statistics

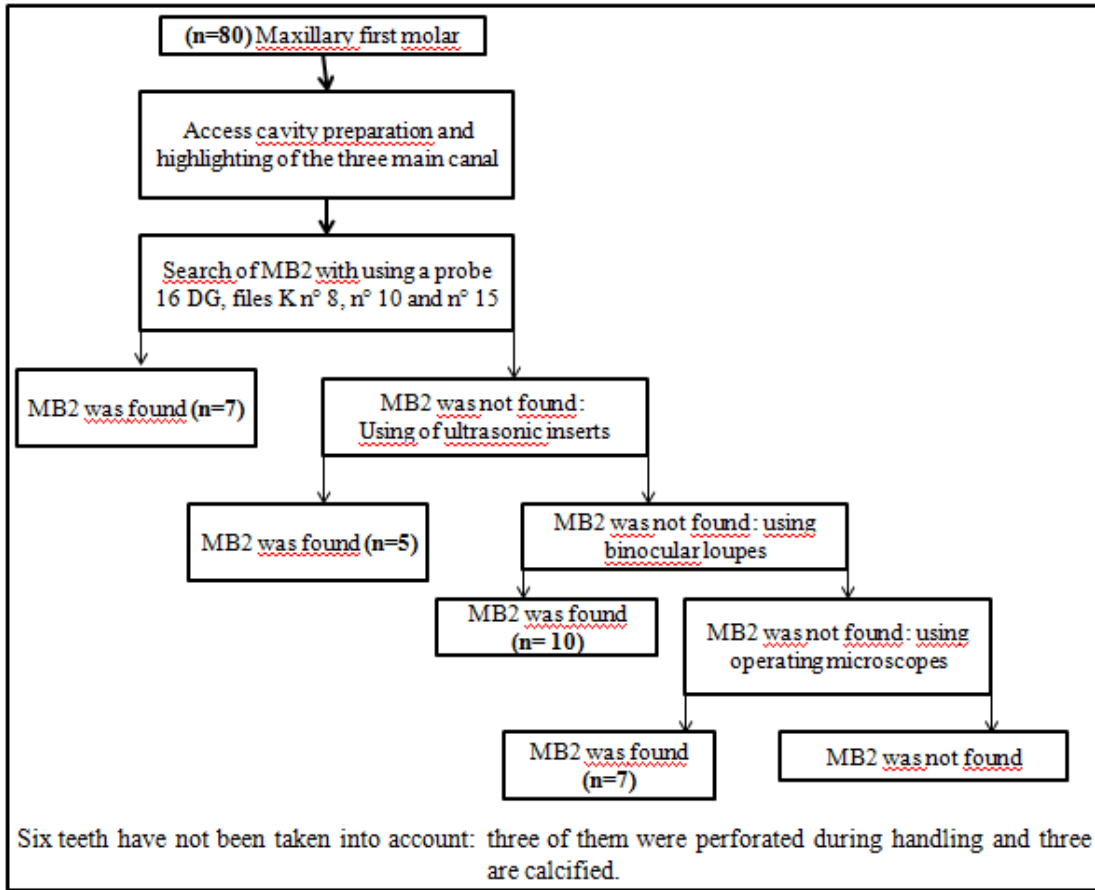
Types according to Weine's classification	Number of teeth with this type configuration	Percentage relative to the total sample size
Type I	18	24.32%
Type II	35	47.29%
Type III	10	13.51%
Type IV	2	2.70%
No type defined	9	12.16%

Table 4: Percentage of MB2 of different studies

<b>Study</b>	<b>Racial origin of the sample</b>	<b>Size of the sample</b>	<b>Type of study</b>	<b>Incidence of MB2</b>
TOURÉ B.et al. [3] 2006	Senegalien population	114	in vitro study	51 %
Saad Al-Nazhan [4] (2006)	Saudi Arabian sub-population	352	Vivo study Clinical	23.3%
Serge BAL[5] 2008	European	794	in vitro study	64,4 %
Somma et al. [6] 2009	Italian population	30	micro tomographic analysis: vitro study	80%
Aysun Kara Tuncera [7] 2010	Turkish population	110	vitro study	78%
Harry H. Peeters et al.[8] 2011	Indonesian		vitro study	68.5%
Adnan Asaad Habib[9] 2014	Syrian	95	vitro study	40%
Bestoon M. et al 2014[10]	Sulaimani-Iraq population	180	vitro study	35.6%
Farhana Chowdhury et al. [11] 2014	Bangladeshi Population	100	vitro study	36%
Atool Chandra Bhuyan et al.[12] 2014	Khasi population of Meghalaya	60	vitro study	65%
Abeer S. Al-Khriesat et al.[13] December 2014	Jordanians	195	Vivo study Clinical	23%
Ainul Husna Abd Latib et al. [14] 2015	Malay & Chinese & Indian	72	vitro study (CBCT)	28%
Present study	Tunisian	80	In vitro study	75.67%



**FIGURE:**



**Figure 1: Protocol for identification of MB2 canal**