

COMPARISON OF SKELETAL AGE AND CHRONOLOGIC AGE IN A SAMPLE PAKISTANI GROWING CHILDREN

Qurrat-UI-Ain Sami¹, Imtiaz Ahmed², Gul-E-Erum³

1.BDS, MDS trainee

2.BDS,FCPS, Associate Professor, Incharge of Department of Orthodontics Ishrat-ul-Ibad Khan Institute of Oral Health Sciences

3.BDS, FCPS,M Orth RCS, Associate Professor of Department of Orthodontics Ishrat-ul-Ibad Khan Institute of Oral Health Sciences

ABSTRACT:

Introduction: Chronological age is considered to be a poor indicator of adolescent development, therefore cervical vertebrae maturation is preferred to assess skeletal age of orthodontic patient.

Objective: Objective of this study was to investigate the relationship between chronological age in maturation of cervical vertebrae.

Material: the study sample of 109 patients (39 males and 70 females) in age range of 10 to 17 years. **Methods:** statistical analysis was performed on SPSS version 16. The baccetti modified version of CVM (stage I-VI) was used in the study. The cervical vertebral stages depend on morphological evaluation of three cervical vertebrae (C2, C3 and C4).

Result: the Spearman ranked correlation between chronological age and vertebral maturation stages was point 0.676 ($P < 0.01$). Mean age of subjects were 13.5 years (13.77 for females, 13.9 for males).

Conclusion: CVM method is more predictable than chronological age alone in the establishment of appropriate timing and types of orthodontic treatment.

Keywords: Chronological age, skeletal age .

INTRODUCTION:

It is important to know the maturational status of a patient whether the pubertal growth spurt has been reached or not because these factors influence on diagnosis, treatment goals, treatment planning and outcome of orthodontic treatment.

Time plays a crucial role in determining the morphological and dimensional result in an organization, differentiation, development and growth of any somatic structure. In orthodontics and dentofacial orthopedics, it is becoming increasingly

evident that timing of treatment on set may be critical ^[1]. Many authors believe that pre-pubertal growth is the best time to modify physiological growth, bone remodeling and correction of skeletal discrepancies in orthodontic patient.

Every bone goes through the series of changes while growing this sequence is same in every individual but timing may differ according to his/her biological clock ^[2-4]. Previous studies have demonstrated that there is wide variation in timing and amount of physical growth between

individual at the beginning of adolescence [5,6,7]. For this reason chronological age is not a reliable indicator to assess maturity [6,8]. Physiological age is best predicted by maturity status. Physiological age is estimated by maturation of one or more tissue systems including dental, skeletal, somatic and sexual maturity [3]. A subject can differ in physical and skeletal maturity at a given chronological age [9]. Therefore, skeletal maturation is routinely evaluated.

In dentofacial orthopedics, investigators use various maturity indicators including body weight, pubertal markers (such as voice changes in male, menarche in females, breast development and the appearance of pubic axillary hairs), dental development and tooth eruption, skeletal maturation of hand and wrist, skeletal maturation of cervical vertebrae [10-11]. Dental development is evaluated by the Demirjian method using intraoral or panoramic radiography. Two most popular methods for assessing skeletal maturation are hand-wrist radiographs by Greulich and Pyle and cervical vertebrae radiographs by cervical vertebral maturation (CVM) method [12-13]. However, in addition, radiation exposure is required for the first method i.e. hand wrist, therefore the second method CVM is preferred.

Hassel and Farman [14] reviewed lateral cephalometric and left hand-wrist radiographs from Bolton-brush growth study at Case Western Reserve University to develop an index based on lateral profile of second, third and fourth cervical vertebrae. Pancherz and Szyska who further evaluated Hassel and Farman

index and relation to increase in body height stated that cervical vertebral analysis had a comparable high reliability and validity [11].

As proven by research and literature cervical vertebral morphology changes with growth. Size and shape of cervical vertebrae are assessed by lateral cephalometric radiographs as it is a biological indicator of individual skeletal maturity [13]. The relationship between cervical vertebral maturation with skeletal maturity has been established. In addition, the relation of cervical vertebral maturation and peak growth of mandible has been documented [14]. Few studies investigated the relationship of chronological age and changes in morphology of cervical vertebrae in adolescence [15-16]. The aim of this study was to investigate the relationship between chronological age and maturation of cervical vertebrae in male and female subjects, as well as to find gender dimorphism of chronological age in each cervical maturational stage.

MATERIAL AND METHODS:

This is a descriptive cross-sectional study design in which the subjects were randomly chosen from the case records of patients attending the dental OPD at Ishrat-ul-Ibad Khan Institute of Oral Health Sciences in Orthodontics department. Patients involved in this research were 10 to 17 years of age (39 male and 70 females) with a sample size of 109 patients. The chronological age was recorded according to actual date of birth confirmed by parents. This selection criteria

includes normally growing patients with no history of illness, trauma and injury to the face region, non-syndromic with no congenital or acquired malformation of cervical vertebrae and hormonal disorder. Lateral skull cephalogram of adequate quality is used in this research. All assessments were performed in a darkened room with a radiographic eliminator to ensure contrast enhancement of bone images. The tracing of the films were done using 4H led pencil and 0.003 inch matte acetate tracing paper. Three parts of cervical vertebrae were traced from lateral cephalogram including dens odontoid process C2, the body of third cervical vertebrae C3, the body of fourth cervical vertebrae C4 [1, 7].

improved version of Cervical Vertebral Maturation (CVM) method¹. This method depends on anatomical changes of three cervical vertebrae (C2, C3 and C4). Evaluation depends upon two variables, firstly the presence or absence of concavity at the inferior border of C2 (odontoid process), C3, C4 and secondly the differences in shape of the body of cervical vertebrae with the progressive age, various shapes of cervical vertebrae includes trapezoid, rectangular horizontal, square, rectangular vertical. These two variables were subdivided into six consecutive stages in cervical maturation (CVM 1 to CVM 6). The below Table 1 shows the cervical maturation stages without knowing the chronological age.

Lateral cephalogram was assessed for skeletal maturation according to recently

Table 1: Six Stages of cervical vertebral maturation [1]

Cervical stage 1	CVM 1	The lower border of all three vertebrae are flat. The body of both C3 and C4 are trapezoid in shape. The peak mandibular growth will occur not earlier than two years after this stages
Cervical stage 2	CVM 2	Concavity at the lower borders of C2 is present. The body of both C3 and C4 are still trapezoid. The peak mandibular growth will occur on average one year after this stage.
Cervical stage 3	CVM 3	Concavities at lower border of C2 and C3 are present. The body of both C3 and C4 are either trapezoid or rectangular horizontal in shape. The peak mandibular growth will occur during one year after this stage.
Cervical stage 4	CVM 4	Concavities at the lower borders of C2, C3 and C4 are still present. The body of C3 and C4 are rectangular horizontal in shape. The peak mandibular growth has occurred within one to two years before this stage.
Cervical stage 5	CVM 5	Concavities at the lower borders of C2, C3 and C4 are still evident. At least one of the body of C3 and C4 is square in shape. If not squared, the body of other cervical vertebrae is rectangular horizontal. The peak mandibular growth has occurred not later than one year before this stage.
Cervical stage 6	CVM 6	Concavities at the lower borders of C2, C3 and C4 are still evident. The bodies of C3 and C4 are rectangular vertical in shape. The peak mandibular growth has ended at least two years before this stage.

Statistics: Statistical analysis was performed with software package of SPSS (version 16, SPSS Inc., Chicago, IL, USA). Skeletal age is determined by computing the intraclass correlation coefficient using Spearman Brown formula. The cervical vertebrae of all randomly selected subjects were rated by same investigator. Descriptive statistics were obtained by calculating the chronologic ages for six stages of cervical vertebrae, skeletal vertebrae indicator for both sexes (including male and female subjects separately). The difference between chronologic and skeletal ages in each age were derived. To determine whether the difference was significant statistically in each group Mann Whitney test and Willcoxon test is used. P value equal to or less than 0.05 was taken statistically significant. (with/without areca nut) as per earlier published protocols. Presence

of attrition and extrinsic stain (< two-thirds of any surface in any teeth) was also noted.

RESULTS:

Results shows high coefficient values. The coefficient ranges of reliability were between 0.676 to 1.00. This cross-sectional study was conducted on total 109 patients. Table 2 shows most frequent cervical vertebrae stages in male and females. In females, most frequent stages were stages 3 and stage 4 (18.2% and 13.7% respectively), stages 5 and stage 6 (11% and 12.8% respectively), followed by stage 1 and stage 2 (1.2% and 6.4% respectively). However in males most frequent stages were stage 2 (10.0%), stage 5 and stage 6 (8.2% and 5.5% respectively), followed by stage 3, stage 4 and stage 1 (4.5%, 5.5%, 1.8% respectively)

Table 2: Sample Distribution according to Cervical Vertebrae Stages in Male and Female

Maturational stage	FEMALE		MALE		TOTAL	
	(n)	%	(n)	%	(n)	%
CVM 1	2	1.8	2	1.8	4	3.6
CVM 2	7	6.4	11	10.0	18	16.5
CVM 3	20	18.3	5	4.5	25	22.9
CVM 4	15	13.7	6	5.5	20	18.3
CVM 5	12	11.0	9	8.2	21	19.2
CVM 6	14	12.8	6	5.5	18	16.5
Total	70		39		109	

The mean ages of subjects were 13.5 years (13.77 for female and 13.9 for males) as shown in figure 1. Distribution of patients according to age in each cervical vertebral maturation stage is shown in table 3. CVM 1 was most frequent in 10 to 11 years, CVM 2 in 11 to

13 years, CVM 3 in 11 to 14 years, CVM 4 in 12 to 14 years, CVM 5 in 13 to 15 years and CVM 6 was most frequent in 16 to 17 years. The Spearman rank order correlation between chronological age and cervical vertebral maturation stages was 0.676 for both sexes. It was statistically significant at (P < 0.01)

Figure 1: Age Distribution by Percentage in Male and Female Subjects

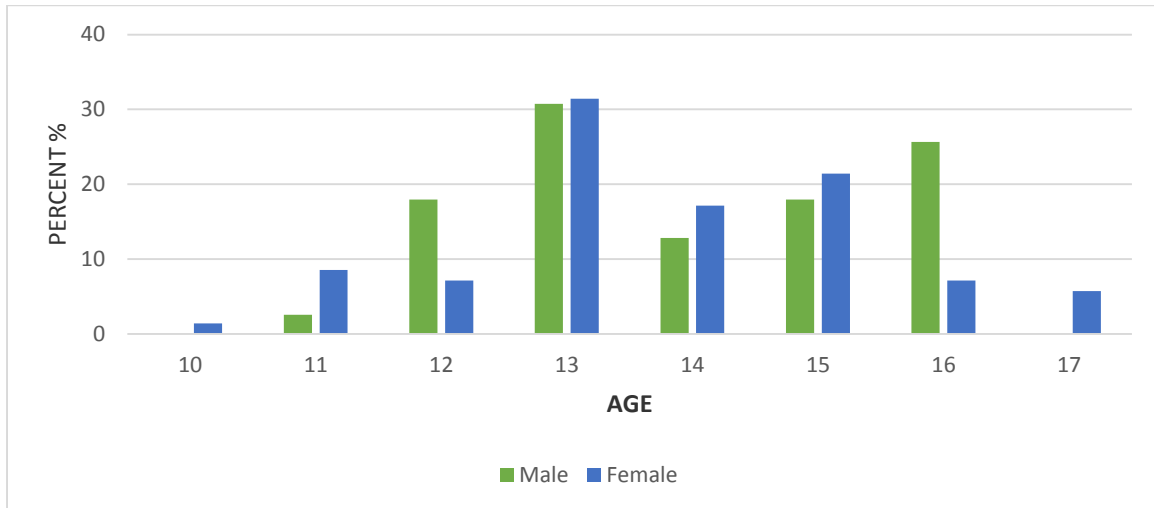


Table 3: Sample Distribution and correlation between Chronological Ages and Skeletal Maturational Stages.

Cervical Vertebrae stages	Chronological Ages (Y)								Correlations (Chronological Ages and Cervical Vertebrae stages)	
	10	11	12	13	14	15	16	17	(r)	Significant value
CVM 1	1	1	1	1					0.676	P<0.01*
CVM 2		2	7	9						
CVM 3		4	4	12	3	3				
CVM 4				7	9	4				
CVM 5				3	6	9	3			
CVM 6				1	1	5	9	4		

(r)= Spearman correlation coefficient
*P<0.01(highly significant)

Table 4: Sample Distribution and correlation between Chronological Ages and Cervical Vertebrae Stages for each Gender

Cervical Vertebrae stages	Gender	Chronological Ages (Y)								Correlations (Chronological Ages and Cervical Vertebrae stages)	
		10	11	12	13	14	15	16	17	(r)	Significant value
CVM 1	F	1	1							0.609	P<0.01*
CVM 2	F		1	3	3						
CVM 3	F		4	2	9	3	2				
CVM 4	F				6	6	3				
CVM 5	F				3	2	6	1			
CVM 6	F				1	1	4	4	4		
CVM 1	M			1	1					0.832	P<0.01*
CVM 2	M		1	4	6						
CVM 3	M			2	3						
CVM 4	M				2	3	1				
CVM 5	M					2	5	5			
CVM 6	M						1	5			

(r)= Spearman correlation coefficient; F=Female; M=Male
*P<0.01 (highly significant)

Frequency distribution of male and female patients separately according to age is shown in table 4. In female subjects, the mean chronological age in CVM 1 was (10.5±0.707 years), CVM2 (12.2±0.755 years), CVM 3 (12.8±1.22 years), CVM 4 (13.8±0.774 years), CVM 5 (14.2±1.055 years) and CVM 6 (15.6±1.215 years). In male subjects, the mean chronological age in CVM 1 was most frequent in (12.5±0.707 years), CVM2 (12.4±0.687 years), CVM 3 (12.6±0.547 years), CVM 4 (13.8±0.731 years), CVM 5 (15.0±0.707 years) and CVM 6 (15.8±0.408 years). Statistically significant correlation (P < 0.01) was also found between

chronological age and cervical vertebral maturation for male and female subjects (0.832 and 0.609 respectively).

The Gender dimorphism of the chronological age in each cervical vertebrae maturation and its difference in each stage is shown in table 5. The females were more advanced than males in each stage and the means chronological age of females in each CVM stage was less than male subjects. The major difference in means age in both genders were statistically significant in all CVM stages. The mean differences in chronological age in male and females were 0.6 years.

Table 5: Gender Dimorphism of Chronological Age in each CVM stage

Stages	Gender	Number (n)	Mean Age	Mean difference	Test Statistics	
					Mann Whitney Test	Wilcoxon Test
CVM 1	Male	2	12.5±0.707	2.0	0.00	3.00
	Female	2	10.5±0.707			
CVM 2	Male	11	12.4±0.687	0.2	33.5	61.5
	Female	7	12.2±0.755			
CVM 3	Male	5	12.6±0.547	0.2	35.5	245.5
	Female	20	12.8±1.22			
CVM 4	Male	6	13.8±0.731	0.0	33.5	169.5
	Female	15	13.8±0.774			
CVM 5	Male	9	15.0±0.707	1.2	30.0	108.0
	Female	12	14.2±1.055			
CVM 6	Male	6	15.8±0.408	0.2	40.0	145.0
	Female	14	15.6±1.215			

DISCUSSION:

It has been known from previous studies, chronological age is considered to be the poor indicator for estimating skeletal maturity [5,6]. In recent years, cervical vertebral maturational method has demonstrate the validity and the ability to detect somatic maturation with special regard to mandibular maturity, which is of great importance in dentofacial

orthopedics [1,9,12,14]. The prediction of time and amount of active growth is an important issue in patients with skeletal discrepancies.

Baccetti at al [1] modified the original hassle and Farman CVM method. This method was adopted in the present study because of its wide utilization in the current literature and acceptability for several corporations.

Sierra [15] found the relationship between chronological age and skeletal age assessment and proved to have relatively high correlation (0.58 to 0.71). In present study, correlation between chronological age and skeletal maturation assessed by cervical vertebrae method was 0.676, a high correlation was also found in both sexes, although it was significantly better for females (0.609) than males (0.832). The values of present study is less as compare to Al-Hadlaq et al [10] ($r = 0.86$ and 0.8 respectively) and Uysal et al [8] (0.72 and 0.79) but it is higher than those reported by Sierra [15], and approximately equal to values of Ghulam et al [2] (0.690). These differences in values is because of differential racial background, environmental conditions, and research methodology associated with sample size and sample distribution. The high correlation values is observed between CVM stages and chronological age, this is significant in estimating skeletal maturity and predicting pubertal growth peak in subjects. However wide variation in chronological age for different maturity level suggest that chronological age is a poor indicator of maturity. At the same time, the validity and reliability of cervical stages method had been proved in different ethnic groups [1, 14,8,16].

Regarding gender, most important factor which influence the timing of adolescence growth spurt is skeletal maturity [6]. The females were more advanced than males in skeletal maturation, and it is supported by previous studies of Tunner [6] and Hunter [17]. The result of present study showed a difference of 0.6 years in male

and female in attaining the same maturity level. Ghulam et al [2] and Shamsheer and Ijaz [4] documented 1 to 1.2 years difference among Pakistani population.

Hunter [17] stated that girls were more advanced by an average of 2.4 years than boys at the onset of puberty, with mean age value of 12.8 years for boys and 10.4 years for girls. These finding indicate that, the cervical stage method can be used as a maturity indicator of pubertal growth spurt with a degree of confidence, better than chronological age. It is appropriate to the cervical vertebral maturation method in daily orthodontics diagnostics practice.

Further studies are inevitable by increasing the sample size and by improving the sample distribution among gender. The most representative sample will help to establish distinct maturity standard for Pakistani subjects.

CONCLUSION:

Regarding the relationship of the chronologic age with cervical vertebrae in 109 subjects, the following general conclusion can be drawn:

- A wide variation in chronological age for different maturity level suggest that chronological age is a poor indicator of maturity. Skeletal maturity indicator are more valid than chronological age for growth status of the individual.
- The most frequent cervical vertebrae stage in females were stage 3 and stage 4 (18.2% and 13.7% respectively) and in males

stage 2 (10.0%), stage 5 and stage 6 (8.2% and 5.5%)

A high correlation coefficient was found between chronological age and cervical

vertebrae skeletal maturation. A high correlation was also found in both sexes, although it was significantly better for females.

REFERENCES:

1. Tiziano Baccetti, Lorenzo Franchi, and James A. McNamara, The Cervical Vertebral Maturation (CVM) Method for the Assessment of Optimal Treatment Timing in Dentofacial Orthopedics, Jr.-seminars in orthodontics 2005
2. Ghulam Rasool, Sohrab Shaheed, Shahab Adil, Age Related Changes in the Morphology of cervical Vertebrae in Adolescent period of Development Vol. 30, No.2 (December 2010)
3. Ali Bagherian and Mostafa Sadeghi, Assessment of Dental Maturity of Children Aged 3.5 to 13.5 years using the Demirjian Method in an Iranian Population, Journal of Oral Science, Vol. 53, No.1, 37-42, 2011
4. Shamsheer, R.M., Ijaz, A., 2005. Age of high growth rate in adolescent period of development. Pak. Oral Dent. J. 25 (1), 53-58
5. Simmons, K., Greulich, W.W, 1943. Menarcheal age and the height, weight and skeletal age of girls aged 7 to 17 years. J Pediat 22(5), 518-548.
6. Tanner, J. M., 1962. Growth at adolescence, 2nd edition. Blackwell Scientific Publications, Oxford
7. Laila Baidas, Correlation between cervical vertebrae morphology and chronological age in Saudi adolescents, (2012) 3, 21-26
8. Tancan Uysal, a Sabri Ilhan Ramoglu, b Faruk Ayhan Basciftci, c and Zafar Saric Kayseri and Konya, Turkey Chronologic age and skeletal maturation of the cervical vertebrae and hand-wrist: Is there a relationship? AJODO, Volume 130, Number 5
9. Flores, M. C., Burgess, C. A., Champney, M., Jenson, R. J., Pitcher, M. R., Major, P.W., 2006. Correlation of skeletal maturational stages determined by cervical vertebrae and hand-wrist evaluation. Angle Orthod. 76 (1), 1-5
10. A. M. Alhadlaq, (2013) 4, 1-5 N.S. Al-Maflehi, New Model for cervical vertebral bone age estimation in boys
11. Eddie Hsiang-Hua Lai, Jenny Zwei-Chiang Chang, Chung-Chen Jane Yao, Shih-Jaw Tsai, Jen-Pei Lui, Yi-Jane Chen, Chun-Pin Lin, 2008 • Vol 107 • No 7 Relationship Between Age at Menarche and Skeletal Maturation stages in Taiwanese Female Orthodontics Patients
12. Baccetti, T., Franchi, L., McNamara, J.A., 2005. The cervical vertebral maturation (CVM) method for the assessment of optimal treatment timing in dentofacial orthopedics. Semin Orthod. 11 (3), 119-129
13. Ghulam Rasool, Zubair Hassan Awaisi, Awais Khalid-Puberty growth

spurt age in local population-20
March 2012.

14. Tiziano Baccetti; Lorenzo Franchi; and James A. McNamara, An Improved Version of the Cervical Vertebral Maturation (CVM) Method for the Assessment of Mandibular Growth, Angle Orthodontist, Vol 72, No.4, 2002
15. Sierra, A.M., 1987. Assessment of Dental and Skeletal Maturity. A New Approach. Angle Orthod 57 (3), 193-198
16. Al-Hadlaq, A., Al-Qarni, M., Al-Khatani, A., Al-Obaid, A., 2007b. Comparative study between Hand-wrist method and cervical vertebral maturational method for evaluation of skeletal maturity in Saudi boys. Pakistan Oral Dent. J. 27 (2), 187-192
17. Hunter, C.J., 1966. The Correlation of facial growth with body height and skeletal maturation at adolescence. Angle Orthod. 36 (1), 44-54