

# ORTHOSURGICAL MANAGEMENT OF IMPACTED MAXILLARY CENTRAL INCISOR ASSOCIATED WITH COMPOUND ODONTOME: A CASE REPORT

Niharika<sup>1</sup>, Satabdi Saha<sup>2</sup>, Krunal S. Soni<sup>3</sup>, Subrata Saha<sup>4</sup>, Subir Sarkar<sup>5</sup>

1.Post Graduate Student, Department of Pedodontics and Preventive Dentistry, Dr. R. Ahmed Dental College and Hospital, Kolkata, India

2.Post Graduate Student, Department of Pedodontics and Preventive Dentistry, Dr. R. Ahmed Dental College and Hospital, Kolkata, India

3.Post Graduate Student, Department of Pedodontics and Preventive Dentistry, Dr. R. Ahmed Dental College and Hospital, Kolkata, India

4.Professor, Department of Pedodontics and Preventive Dentistry, Dr. R. Ahmed Dental College and Hospital, Kolkata, India

5.Professor, Department of Pedodontics and Preventive Dentistry, Dr. R. Ahmed Dental College and Hospital, Kolkata, India

## ABSTRACT:

Odontomas are hamartomatous lesions or malformations rather than true neoplasms and are frequent cause of isolated delayed tooth eruption. Odontomas are asymptomatic in nature and often diagnosed in the second decade of life. Frequently the odontomas interfere with the eruption of teeth leading to their impaction. In present case a 9 years old girl reported with complaint of missing tooth in upper front region. Clinical and radiographic findings were suggestive of compound odontoma. A combination of surgical and orthodontic techniques were planned to produce satisfactory result. In surgical phase, multiple calcified tooth like structures were removed. Afterwards surgical exposure and orthodontic traction of impacted tooth using closed eruption technique resulted in proper incisor positioning.

**Keywords:** Odontogenic Tumors, Impacted Tooth, Compound Odontoma, Surgical removal, Orthodontic Extrusion, Tooth Movement.

## INTRODUCTION:

Odontoma is probably the most common type of benign odontogenic tumour emulating all the hard tissues products of a mature tooth germ.<sup>[1]</sup> These tumours are characterised by slow growth and constitute 22% of all odontogenic tumours. Clinically, they are two types: compound and complex.<sup>[2]</sup> Compound odontomas appear as numerous miniature or rudimentary teeth. Complex odontomas

appear as amorphous conglomerates of hard tissue.<sup>[2]</sup> Compound odontomas are more common in the anterior region while complex odontomas tend to occur in the posterior region of the jaw. Complex odontomas are less common than compound variety in the ratio 1:2. Odontomas are the type of odontogenic tumour, considered to cause the impaction of both primary and permanent teeth.<sup>[3]</sup> The etiology of odontoma is unknown,

however, trauma, local infection, heredity and genetic mutations have been suggested as possible factors.<sup>[4]</sup>

In most cases they are diagnosed when a patient is evaluated radiographically for tooth eruption disturbances. Impacted permanent central incisors is commonly encountered in the clinical practice and has a major impact on dental and facial aesthetics of an individual. The maxillary incisor can be considered impacted if the following conditions exist:<sup>[5]</sup>

1. Tooth is not present in the dental arch and shows no potential for eruption.
2. Eruption delayed beyond the normal eruption time.
3. Contra-lateral tooth has been erupted for at least six months.
4. The root of the unerupted tooth has been completely formed.

Treatment alternatives for an impacted central incisor includes:

1. Surgical exposure, orthodontic space opening and traction of the impacted central incisor into proper position.
2. Extraction of the impacted central incisor and closure of the space by substituting the lateral incisor for the central incisor with subsequent prosthetic restoration.
3. Extraction of the impacted central incisor and restoration with a bridge or an implant after growth completion.<sup>[6]</sup>

The present case report describes the clinical features, diagnosis and

orthosurgical management of impacted maxillary permanent right central incisor due to the presence of compound odontoma in the anterior maxillary region.

#### CASE DETAIL:

A 9 years old female patient reported to the Department of Pedodontics and Preventive Dentistry with the chief complaint of unerupted upper right front tooth. Her past dental, medical and family history were non contributory. Extraoral examination revealed no facial asymmetry. Intraoral examination revealed unerupted maxillary right central incisor while the contralateral tooth had already erupted [ Figure 1]. There was loss of space caused by the mesial inclination of adjacent right lateral incisor. Crown of the maxillary right central incisor was palpable in the labial vestibule, above the mucogingival junction. There were no signs of inflammation, pain and surrounding mucosa was normal. An intraoral periapical and panoramic radiographs revealed presence of maxillary right central incisor with a dense mass consisting of multiple small teeth like radio- opaque structures adjacent to its coronal portion, thereby obstructing its eruption [Figure 2, 3]. The lesion was clinically asymptomatic. Based on the clinical and radiographic findings, a provisional diagnosis of odontoma was established.

**Management** - The treatment plan comprised of surgical removal of the

odontome and orthodontic traction of the impacted incisor to bring it into proper position in the dental arch.

Prior to surgical phase, routine blood investigations were done which were within normal limit.

**Surgical phase** - After administration of local anesthesia, a full-thickness mucoperiosteal flap was reflected and a layer of bone overlying the calcified mass was removed. Multiple calcified tooth like structures were carefully excised without disturbing the impacted right maxillary permanent incisor and was sent for histopathological examinations [ Figure 4]. To ensure that no denticles remained, an intraoral periapical radiograph was taken before the closure of the flap [ Figure 5]. After hemostasis was achieved, the area was irrigated with saline and the mucoperiosteal flap was then sutured back in the position.

The healing was uneventful and the sutures were removed on the 7<sup>th</sup> day after surgery. Follow-up examinations were done after 3 months and 6 months. Even after 6 months the tooth showed no signs of eruption as it was distally inclined and its path of eruption was blocked by the adjacent maxillary right permanent lateral incisor. So, second phase of treatment plan was initiated i.e surgical exposure and orthodontic traction of the impacted tooth.

**Orthodontic phase** - On intraoral examination it was noticed that maxillary right permanent lateral incisor was mesially tipped. On model analysis, it was found that the space available in the arch was not sufficient to accommodate the impacted incisor in the arch. So, it was necessary to regain the space in the maxillary arch. Orthodontic bands were placed on the maxillary 1st permanent molars. 0.018" MBT prescription brackets were bonded on the upper arch. To create adequate space and for initial alignment and leveling, sectional elastic chain along with 0.012" NiTi arch wire was given [ Figure 6]. Surgical exposure of impacted right permanent central incisor was done and an MBT bracket was bonded on its labial surface. A continuous 0.014" NiTi arch was given and secured with ligature wire on the impacted tooth and the flap was repositioned to original position [ Figure 7]. Follow-up was done after 1 week, 4 weeks and 6 weeks. After 6 weeks tooth showed signs of eruption in the oral cavity, 0.016" NiTi arch wire was given to bring tooth in occlusal level [ Figure 8]. 2 months later, 0.019\*0.025" SS wire was given along with elastic chain to close the space and final alignment was done with 0.016" NiTi arch wire [ Figure 9].

Debonding was done after achieving desired results followed by placement of fixed palatal retainer. The duration of treatment was around 14 months. The permanent maxillary right central

incisor was brought into an acceptable position without any radiographic signs of periodontal pathology or unacceptable root resorption [ Figure 10,11,12]. The patient was advised for routine clinical and radiographic follow-up once in 3 months.

## DISCUSSION:

Paul Broca in 1867, first coined and defined the term odontoma as “tumors formed by the overgrowth of transitory or complete dental tissues.”

Odontomas are most commonly classified as benign, mixed and calcified odontogenic tumours. Mostly occur in the first and second decades of life, and the mean age of diagnosis is 14 years. Odontomas act similar to impacted teeth, and thus often cause disturbances in the eruption of teeth (eg, impaction or delayed eruption of the teeth, retention of primary teeth and abnormalities in the position of the permanent teeth, tipping or displacement of adjacent teeth). Usually odontomas are asymptomatic and based on the data of the survey of Philipsen et al, the compound odontoma represents 9 - 37% of all odontogenic tumours.

Radiographically, compound odontomas appear as radiopaque mass of multiple, small, calcified tooth like structures of varying size and shape, whereas complex odontomas are calcified radiopaque masses bearing no anatomical resemblance to teeth. In the present case, multiple calcified

tooth like structures were noticed which were suggestive of a compound odontoma.<sup>[7]</sup>

The treatment option for odontoma comprises of surgical excision and periodic clinical and radiographic examination to evaluate the path of eruption of teeth.<sup>[8]</sup>In present case, when the patient reported, there was almost complete root formation of unerupted tooth, making it necessary to use orthodontic traction of the impacted tooth to guide in adequate position in the dental arch.

Surgical exposure can be performed in 3 ways: (1) Window technique - circular excision of the oral mucosa immediately overlying the impacted tooth, (2) Open-eruption technique - apical repositioning of the raised flap that incorporates attached gingiva overlying the impacted tooth, and (3) Closed-eruption technique - the raised flap that incorporates attached gingiva is fully repositioned in its former position, after bonding an attachment to the impacted tooth.<sup>[9]</sup>

Closed eruption technique was used to prevent any attachment loss associated with forced eruption of the permanent central incisor. The final result showed acceptable periodontal status of erupted incisor.

It is usually preferable to obtain orthodontic traction by attaching a ligature wire or elastic chain to the arch wire. This approach does have several drawbacks, including the need for

frequent reactivation, submucosal portion of ligature wire or traction chain fractures necessitating further surgery. An effective solution is to apply light, direct traction from an orthodontic wire deflected close to the impacted tooth and then completely covered by the flap, which is repositioned in its original location. An alternative method used in this case is to apply direct traction with a light orthodontic wire. This method allows optimal soft-tissue healing, encourages better oral hygiene due to the absence of wires or elastic chains. Furthermore, it reduces the likelihood of breakage that might require re-exposure of the tooth.<sup>[10]</sup>

## CONCLUSION:

Impacted permanent incisors due to odontoma are commonly encountered and often associated with

## REFERENCES:

1. Lewis R, Eversole. Clinical outline of oral pathology-diagnosis and treatment. 3<sup>rd</sup> ed. BC Decker Inc; 2002. p298-9. [SEP]
2. Regezi JA, Sciubba JJ. Oral pathology: clinical pathologic correlations. 3rd edn. Philadelphia, PA: WB Saunders, 1999:350-2.
3. Cildir SK, Sencift K, Olgac V, et al. Delayed eruption of a mandibular primary cuspid associated with compound odontoma. J Contemp Dent Pract 2005;6:152-9. [SEP]
4. Batra P, Duggal R, Kharbanda OP, Parkash H. Orthodontic [SEP]treatment of impacted anterior teeth due to odontomas: A report [SEP]of two cases. J Clin Pediatr Dent 2004;28:289-94
5. Lindauer SJ, Rubenstein LK, Hang WM, Andersen WC, Isaacson, RJ. Canine impaction identified early with panoramic radiographs. J Am Dent Ass 1992; 123:91-97.
6. Lin YT. Treatment of an impacted dilacerated maxillary central [SEP]incisor. Am J Orthod Dentofacial Orthop 1999;115:406-9. [SEP]
7. de Oliveira BH, Campos V, Marçal S. Compound odontoma—diagnosis and treatment: three case reports. Paediatr Dent 2001;23:2

psychological problems in children. Early diagnosis of the odontoma facilitates adoption of a less complex and less expensive treatment and ensure better prognosis. In the case of delayed eruption, orthodontic traction could be an ideal approach if there is enough space in the dental arch to accommodate.

The present case demonstrated successful management of a typical case of impacted permanent central incisor associated with compound odontoma, by surgical exposure and orthodontic traction, which resulted in esthetic rehabilitation of the patient. Long-term monitoring for the stability and periodontal health of the erupted incisor should be evaluated following orthodontic traction.

8. Frank C. Treatment options for impacted teeth. J Am Dent Assoc 2000;131:623- 32.
9. Becker A, Brin I, Ben-Bassat Y, Zilberman Y, Chaushu S (2002) Closed-eruption surgical technique for impacted maxillary incisors: a postorthodontic periodontal
10. Gracco A, Maltoni I, Maltoni M, Zoli L. Eruption of a labially impacted canine using a closed-flap technique and orthodontic wire traction. J Clin Orthod. 2012; 46: 625-30.

**FIGURES:**

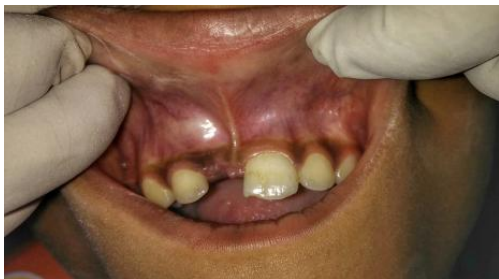

Figure 1: Pre-treatment intraoral photograph showing absence of 11

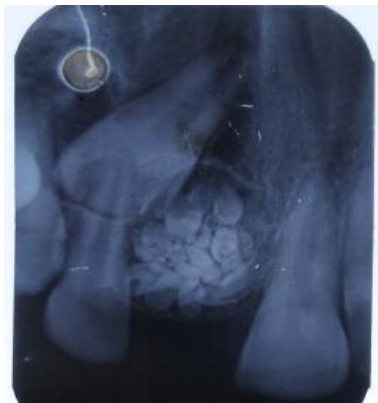


Figure 2: Pre-treatment Intra oral periapical radiograph

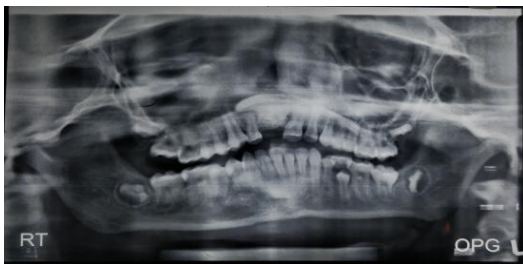

Figure 3: Pre-treatment panoramic radiograph

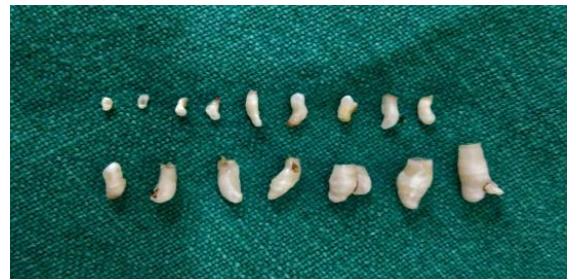

Figure 4: Excised compound odontoma showing multiple teeth like structures

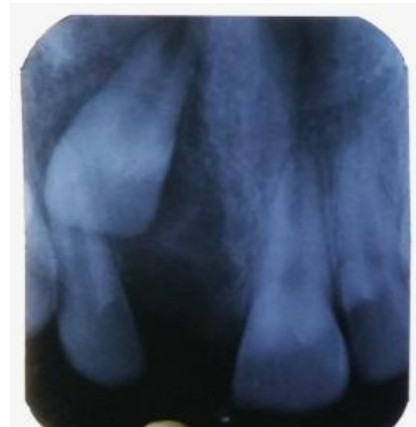

Figure 5: Intra oral periapical radiograph taken after surgery to confirm complete removal of the Odontome

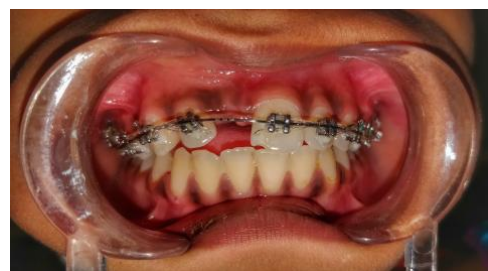

Figure 6: MBT bracket bonded on the maxillary teeth along with 0.012 inch NiTi arch wire and sectional E-chain

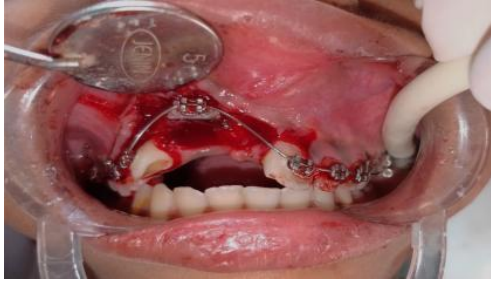

Figure 7: MBT bracket bonded on the impacted incisor along with 0.014 inch NiTi arch wire

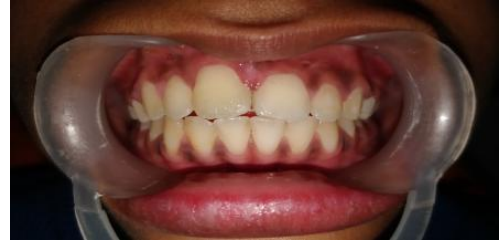

Figure 10: Post-treatment intraoral photograph showing well aligned 11 a minimum gingival height discrepancy

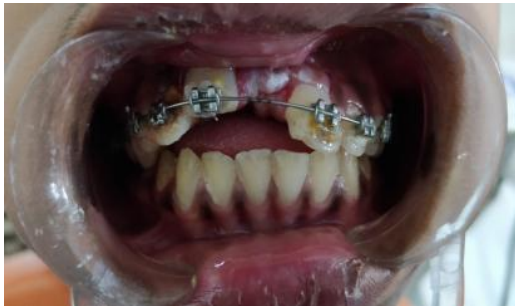

Figure 8: Intraoral photograph showing eruption of the maxillary right central incisor

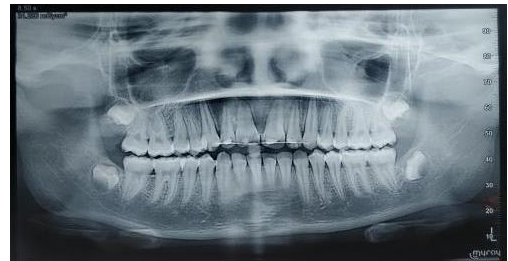

Figure 11: Post-treatment panoramic radiograph

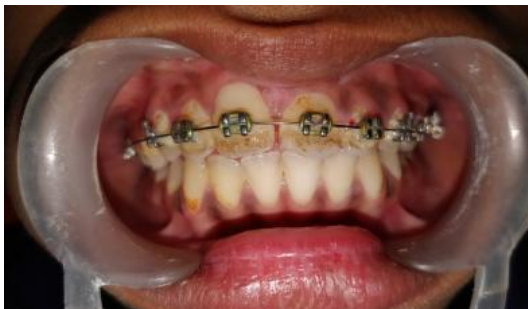

Figure 9: Intraoral view showing final alignment of 11 with 0.016 inch NiTi arch wire

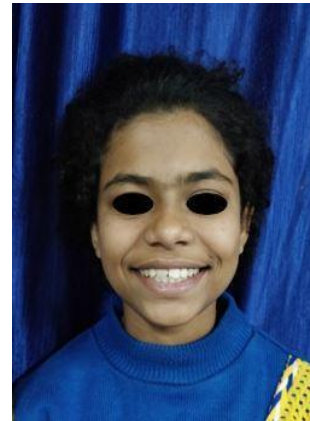

Figure 12: Post-treatment extraoral photograph