

MULTIDISCIPLINARY APPROACH TO CREATE AESTHETICS IN PERIODONTALLY COMPROMISED TOOTH: A CASE SERIES

Manish Ashtankar¹, Mala Dixit B²

1.Postgraduate student, Department of Periodontics and Implant Dentistry, Nair Hospital & Dental College

2.Professor and HOD, Department of Periodontics and Implantology NHDC, Mumbai

ABSTRACT:

Compromised aesthetics in anterior teeth is always unacceptable especially for young patients. Pathological tooth migration because of diseased periodontium requires multidisciplinary approach to gain stable functional & aesthetic result of periodontal pathology for patient. This case series mentions combination of Periodontics-orthodontic approach in first case, periodontics-endodontic-prosthodontic approach for second case, periodontics-prosthodontic approach for third case.

Key words: Aesthetics, Pathological tooth migration (PTM), Multidisciplinary approach.



INTRODUCTION

Pathologic tooth migration (PTM) has been defined as a tooth displacement that results when balance among the factors that maintain physiologic tooth position is disrupted by periodontal disease ^[1]. Pathological tooth migration occurs mostly in anterior region with compromised aesthetics, though posterior region also get affected. Inflammation of gingiva and diseased periodontium can lead to weakened periodontal support in any form of periodontitis. Periodontitis leads to pocket formation and ultimately supporting alveolar bone loss. Pressure from tongue, food and granulation tissue provide additional force in tooth movement in compromised state. Primary trauma from occlusion or secondary contributes for the same as well as external trauma sometimes ^[1].

Pathologically tooth can migrate in any direction and can be encountered by mobility and rotation. Migration in

occlusal and incisal direction is termed extrusion ^[1].

Although some case reports have shown spontaneous repositioning of teeth following periodontal therapy alone, the treatment of severe cases of anterior spacing can be complex and time consuming and a multidisciplinary approach is often required including periodontal, orthodontic and restorative treatment ^[2].

This case series focus on multidisciplinary approach like periodontics, orthodontic, prosthodontics and endodontic. Periodontal management common for all cases and other treatment modalities utilised wherever required.

In entire multidisciplinary approach periodontal therapy stand first to obtain stable functional results because further treatment by any discipline requires healthy periodontium.

Though, natural aesthetics can be replaced by orthodontic treatment, artificial aesthetics by prosthodontic approach sometimes more beneficial in discoloured teeth and patient's early requirement of aesthetics.

CASE DETAIL

Case 1: A 21-year-old male patient presented to the Department of Periodontology and Implantology, Nair Dental College and Hospital, Mumbai Central, Mumbai, India, with a chief complaint of loose and extruded left upper front tooth which led to an irregular alignment. Thorough clinical examination revealed, the left central incisor had extruded and moved labially (Fig 1a), with grade I mobility, with a deep periodontal pocket about 7mm on its distal and palatal surface and bleeding on probing present. Radiographic examination reveals bone loss around left central incisor (Fig 3a). Following intraoral examination treatment plan was decided.

Periodontal treatment:

Supragingival, subgingival scaling and root planing performed followed by oral hygiene instructions to the patient. Patient was then recalled after four weeks for re-evaluation. Periodontal pocket was persisting on re-evaluation. For elimination of persistent periodontal pocket, it was decided to perform periodontal flap surgery. Full thickness flap reflected after crevicular incision (Fig 4a) and debridement was done. One week later suture removal was done and

patient then referred to department of Orthodontics for further treatment.

Orthodontic treatment was considered immediately one week after periodontal treatment for early stimulation of connective tissue and progenitor cells, necessary to foster regeneration^[3].

Orthodontic treatment: Orthodontic appliance was placed for improvement in alignment & levelling of the migrated central incisor (Fig.5a). 0.018slot metallic Roth Pre-adjusted edge wise brackets were bonded molar to molar. For alignment and levelling of all teeth 0.016" nickel titanium arch wire was inserted in all brackets except right central incisor. 6 weeks later 16X22" nickel titanium wire was inserted and rigid 16X22" stainless steel was subsequently placed each at interval of 6 weeks. 0.014" nickel titanium piggy back aligning wire over 16X22" stainless steel wire was then inserted in right central incisor to achieve intrusion and minimise extrusion and flaring of adjacent teeth. 6 months into active treatment intrusion of right central incisor was achieved as measured clinically with respect to incisal edges of all incisors. 16X22" stainless steel wire was reinserted for torque control. At end of 8 months of active therapy, appliance was debonded following assessment of intrusion level, lack of mobility, absence of lateral occlusal forces on right central incisor and radiographic bone level improvement. Lingual fixed spiral wire retainer was bonded lateral to lateral incisor (Fig. 6a).

(Fig.7a) shows 3month postoperative and (Fig.8a) shows 6month postoperative view

after orthodontic treatment. (Fig.9a) shows postoperative probing pocket depth. All these images shows improved gingival tissue with recession between right central and lateral incisor. (Fig.10a) shows postoperative IOPA which demonstrate intrusion of central incisor. Patient was satisfied with hard and soft tissue profile aesthetically. So, no further treatment to improve gingival recession was considered.

Case 2: A 43 years old male patient present with chief complaint of discoloured and migrated front tooth in upper anterior region. Patient gave history of trauma 22 years back. Examination showed labially extruded discoloured right central incisor having grade I mobility (Fig.1b) with deep periodontal pocket and bleeding on probing. Radiographic examination showed bone loss around incisor and periapical radiolucency (Fig. 2b).

After intraoral examination the following treatment was done.

Phase 1 therapy done as performed in case 1. Patient then referred to department of endodontics for root canal treatment in the same tooth. Endodontist performed root canal treatment with rotary Protaper system. (Fig. 3b) shows completed root canal treatment. Patient was appointed for re-evaluation after 4 weeks which showed reduced inflammation and periodontal pocket depth reduce to 6mm from 8 mm (Fig. 4b). Surgical periodontal therapy was planned to eliminate periodontal pathology completely. Full thickness flap

was elevated after crevicular incision and debridement was done (Fig. 5b). Suture removal done after 1 week.

(Fig.6b) showed postoperative view with healthy retracted gingival margin coronally. 4weeks follow up reduces inflammatory components and maintain healthy periodontium with decrease in tooth mobility. This clearly indicates case ready for prosthodontic treatment. On referral, prosthodontist complete tooth preparation for replacement with metal ceramic prosthesis (Fig.7b). So, final prosthesis was cemented with routine protocol (Fig. 8b). Patient was satisfied with aesthetic treatment with no pain and mobility in respected tooth. (Fig. 9b) shows extra oral view of patient after complete treatment.

Case 3: A 47 years old female patient present with chief complaint of bleeding from gums after brushing and spacing between front teeth. Patient gave history of no spacing initially which start increasing gradually since few months. Intraoral examination showed labially extruded left central incisor with grade I mobility (Fig.1c) and bleeding on probing. Intraoral IOPA immediately after crown placement showed bone loss around both upper central incisors which was same before periodontal therapy (Fig.2c).

After intraoral examination the following treatment was done.

Phase 1 therapy done as performed in case 1 and case 2. Patient then appointed after 4 weeks for re-evaluation of phase one therapy. Re-evaluation showed

absence of bleeding on probing but persistent periodontal pocket 6-7 mm around upper central incisors (Fig.3c). Surgical periodontal treatment was then planned for this case. Papilla preservation flap was designed to maintain aesthetic profile of papilla between central incisors (Fig. 4c) and complete debridement done. Three walled bony defect was present distal to left central incisor so, it has been filled with DFDB bone graft (Fig.5c) and suturing done (Fig.6c). (Fig.7c) postoperative view shows healthy and maintains papilla between central incisors. One month after postoperative healing patient was referred to Prosthodontist for closure of diastema. Prosthetic treatment was done by designing metal ceramic prosthesis for central incisors and lateral incisors for improving patients smile on her demand (Fig.8c).). (Fig.9c) showed radiographic view of bone level after 6 months. (Fig.10c) showed periodontal probing depth around central incisor after 6 months. Patient was satisfied with aesthetic treatment with no pain and mobility in respected tooth. (Fig.11c) shows extra oral view of patient.

DISCUSSION

There is evidence-based information that the destruction of periodontal tissues plays a significant role in the etiology of PTM [4,5]. In periodontally compromised adult cases a close interdisciplinary approach is critical for successful outcome [6].

The goal of periodontal therapy is to prevent disease progression and to

regenerate the lost periodontal support. Over the years, open-flap surgical debridement, graft materials and regenerative techniques have been used to achieve this goal in periodontal lesions with infrabony pockets [7,8].

In this case series treatment was planned based on severity of migration with reference to following table [9].

Severity	Sign & Symptoms	Treatment
Mild	Diastema of anterior teeth, ≤2 mm in dimension	scaling, root planing, and flap surgery
Moderate	Extrusion and flaring of the teeth	Periodontal treatment and orthodontic treatment (light intrusive forces)
Sever	Diastema of anterior teeth, >2 mm in dimension due to periodontal disease	Prosthodontic treatment (extraction and replacement with prosthesis)

Roberts and Chase [13] suggested that orthodontic tooth movement may enhance the mitotic activity of the periodontal ligament cells. Early start of

orthodontic movement (7 to 10 days after periodontal surgery) seems to be effective in determining the coronal shift of the soft tissues, which is an important concern from an aesthetic point of view.

Case reports in the literature have demonstrated that, with adequate plaque control, teeth with reduced periodontal support can undergo successful tooth movement without compromising their periodontal condition^[10-12].

So, in case 1 periodontal condition was improved by scaling and root planing, proper maintenance of oral hygiene and then periodontal flap surgical procedure to remove periodontal pocket before the start of the orthodontic treatment, which helps to prevent further bone loss by

orthodontic treatment, if performed on inflamed periodontium.

In case 2 discoloured and endodontically treated central incisor and in case 3 diastema of anterior teeth more than 2mm clearly defined the need of prosthetic replacement.

CONCLUSION

This case series clearly demonstrate that correct planning of interdisciplinary approach on healthy periodontal tissue can establish aesthetics in periodontally compromised situation and fulfil patient demand from our profession.

REFERENCES

1. Carranza FA Jr. Periodontal response to external forces. In: Carranza FA. Jr., Newman MG. Clinical Periodontology, 9th ed. Philadelphia: W.B. Saunders; 1996:313-325.
2. Cirelli JA, et al. Combined periodontal, orthodontic and restorative treatment of pathologic migration of anterior teeth. A case report Int J Periodontics Restorative Dent 2006;26:501-6.
3. Deepa D, et al. Combined periodontic-orthodontic-endodontic interdisciplinary approach in the treatment of periodontally compromised tooth. A case report JISP - Vol 14, Issue 2, Apr-Jun 2010
4. Towfighi PP, et al. Pathologic migration of anterior teeth in patients with moderate to severe periodontitis. J Periodontol 1997;68:967-972.
5. Martinez-Canut P, et al. A study on factors associated with pathologic tooth migration. J Clin Periodontol 1997;24:492-497.
6. Ogihara S. Alveolar bone upper growth in furcation area using combined orthodontic regenerative therapy: A Case Report. J Periodontol 2002; 73: 1522-7.
7. Tonetti MS, Cortellini P. Case selection and treatment considerations of guided tissue regeneration in deep intrabony defects. Curr Opin Periodontol 1997;4:82-8.
8. Laurell L, et al. Treatment of infrabony defects by different surgical procedures. A literature review. J Periodontol 1998;69:303-13.
9. Kim YI, et al. A multidisciplinary approach for the management of pathologic tooth migration in a

patient with moderately advanced periodontal disease. Int J Periodontics Restorative Dent 2012;32:225-30.

10. Ong MMA, Wang HL. Periodontic and Orthodontic treatment in adults. Am J Orthod Dentofacial Orthog 2002; 122: 420-8.
11. Xingmei F, et al. An interdisciplinary approach for improved functional and esthetic results in a periodontally

compromised adult patient. The angle Orthodontist 2005; 75: 1061-70.

12. Van Gastel J, et al. Influence of bracket design on microbial and periodontal parameters in vivo. J Clin Periodontol 2007; 34: 423-31.
13. Roberts WE, Chase DC. Kinetics of cell proliferation and migration associated with orthodontically-induced osteogenesis. J Dent Res 1981;60:174-81.

FIGURES:

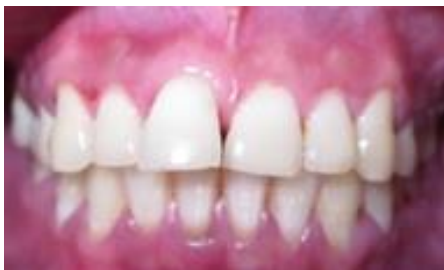

Fig 1(a, a'): Preoperative view showing labial and distal extrusion of right central incisor

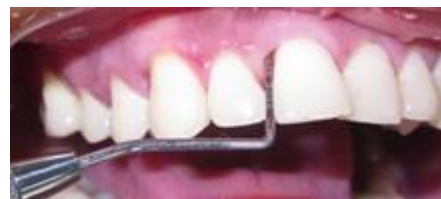
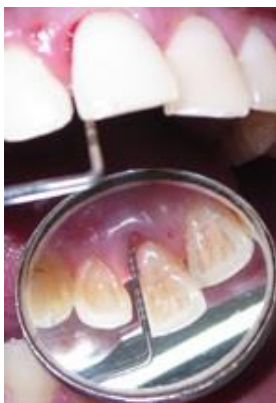
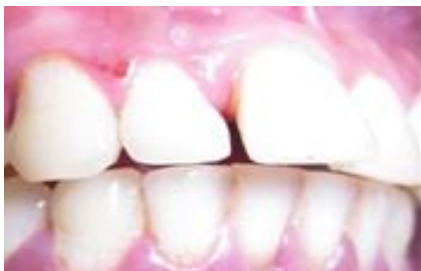Fig 2(a, a'): periodontal probing shows 7-8mm depth

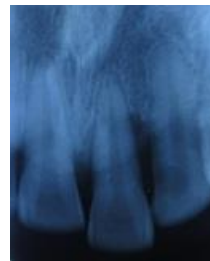

Fig 3a: Preoperative IOPA

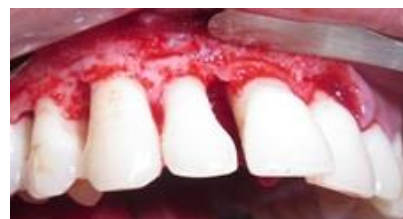
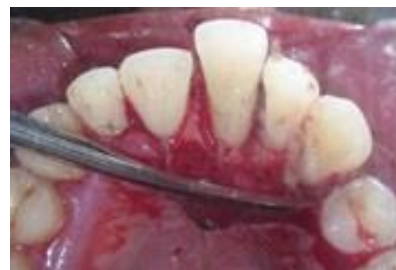
Fig 4(a, a'): Open flap surgery and debridement

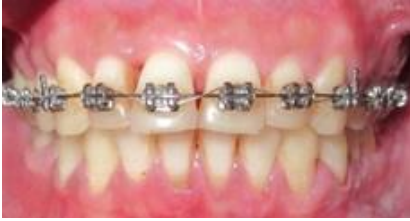

Fig5a: Orthodontic treatment

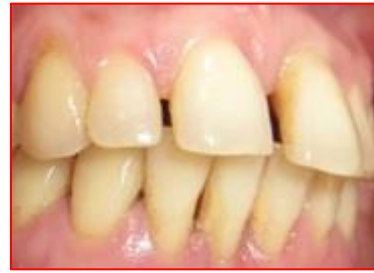

Fig 9(a, a'): Postoperative probing depth

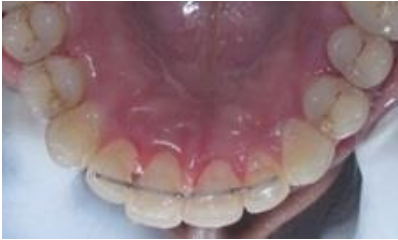

Fig 6a: orthodontic Retainer

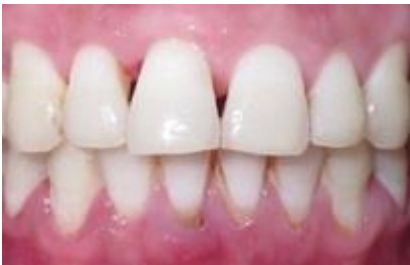
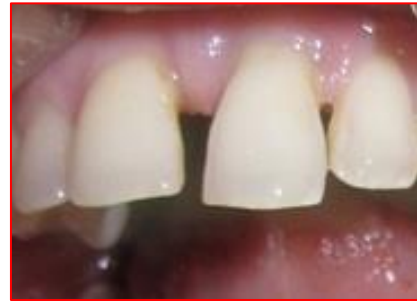
Fig 7a: Postoperative view (3month)

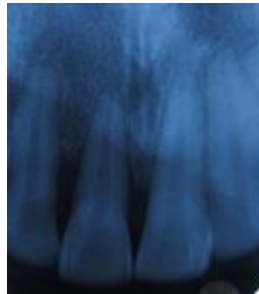

Fig 10a: Post-operative IOPA

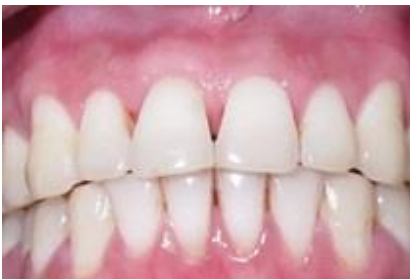

Fig 8a: Postoperative view (6month)

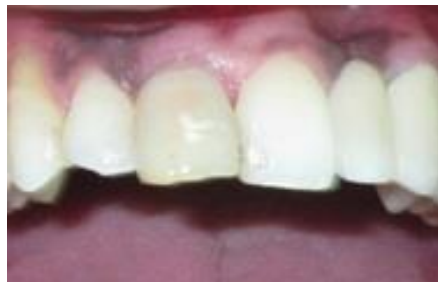

Fig 1b: Preoperative view showing labial and mesial extrusion of right central incisor

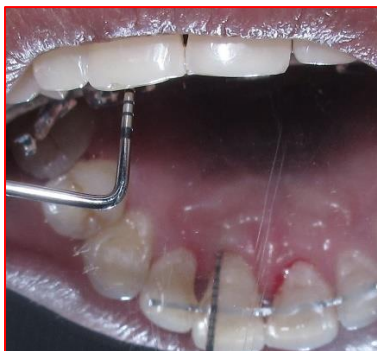

Fig 9(a): Postoperative probing depth



Fig 2b: Preoperative IOPA

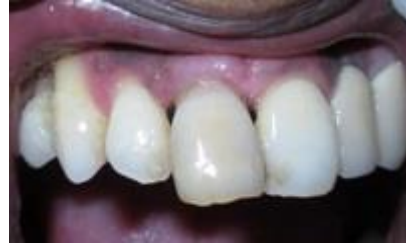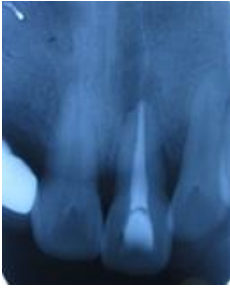


Fig 6b: Postoperative view 1 month after surgery

Fig 3b: Obturation

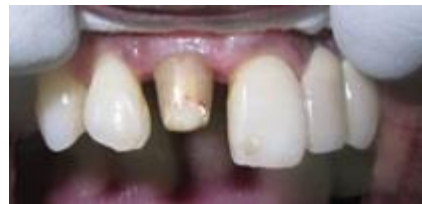
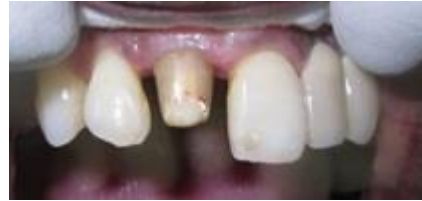
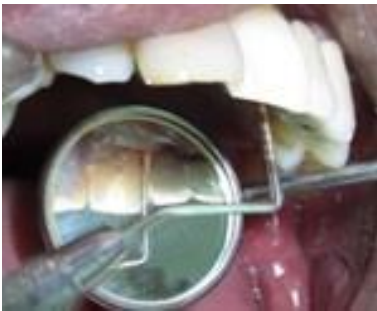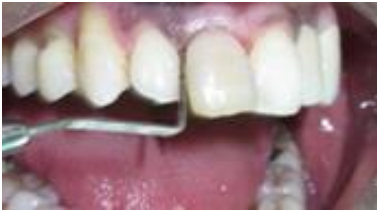Fig 7(b, b'): Crown preparation Right central incisor

Fig 4(b, b'): periodontal probing shows 6mm depth

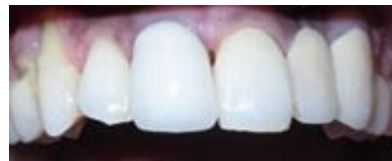
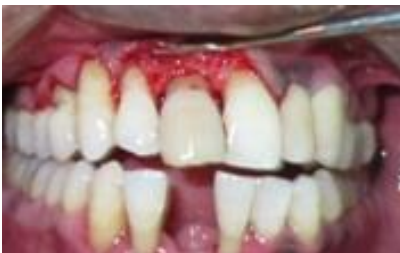
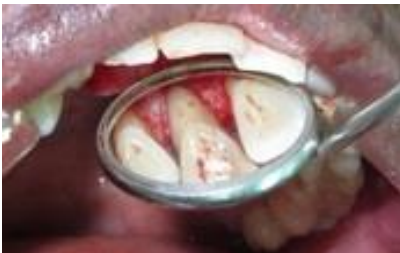Fig 8b: PFM crown placement

Fig 5(b, b'): Modified flap surgery and debridement

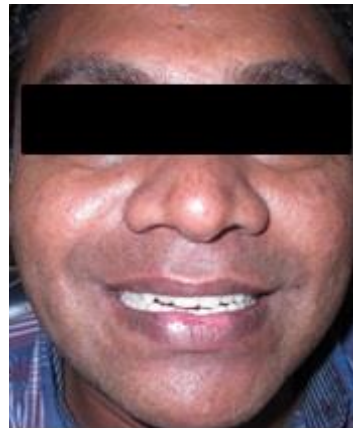

Fig 9b: Post-treatment extraoral photographs

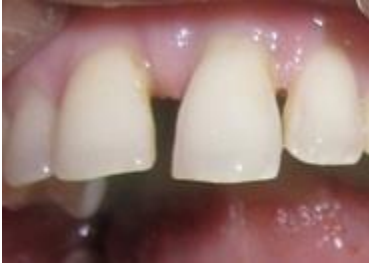
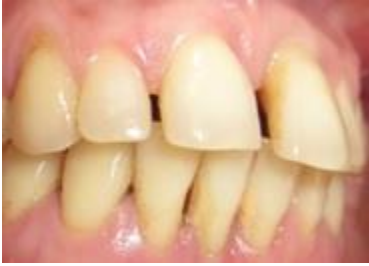
Fig 1(c, c'): Preoperative view

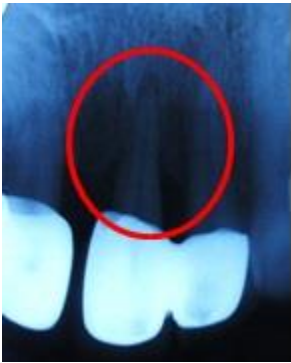

Fig 2c: IOOPA immediately after crown placement

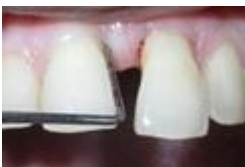
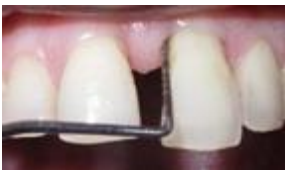
Fig 3(c, c'): Probing pocket depth

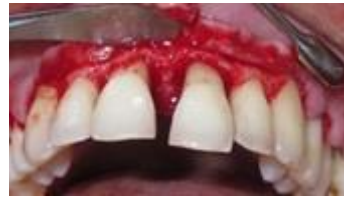
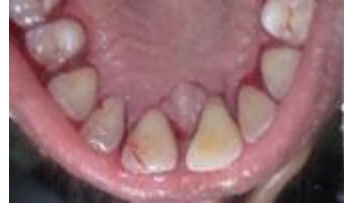
Fig 4(c, c'): papilla preservation flap and debridement

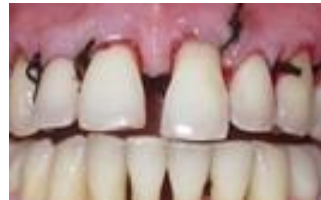
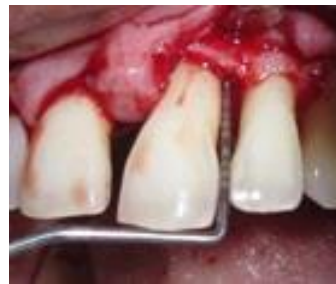
Fig 5(c, c'): bony defect distal to left central incisor and defect filled with DFDB bone graft

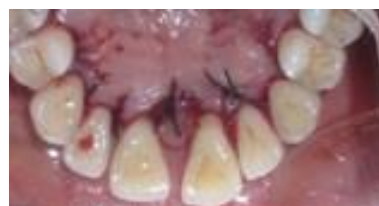
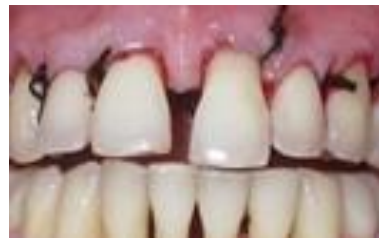
Fig 6(c, c'): Suturing done

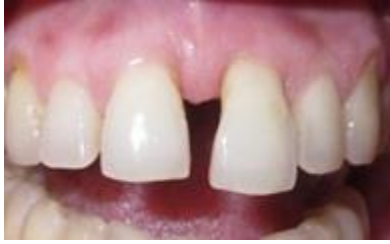

Fig 7c: postoperative view

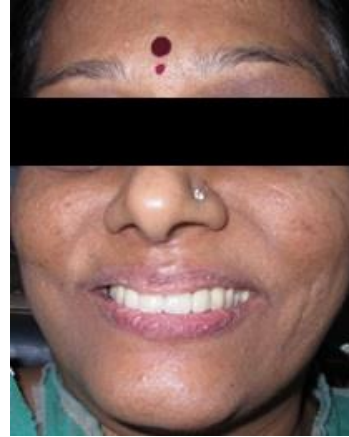

Fig 11c: Post-treatment extraoral photographs

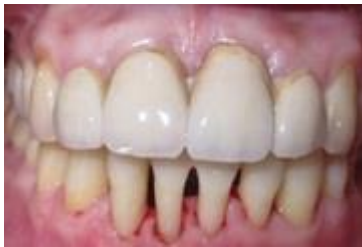

Fig 8c: after prosthodontic treatment

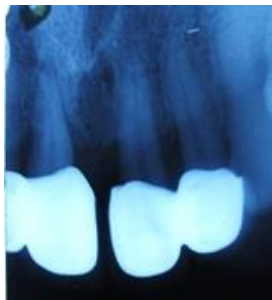

Fig 9c: IOPA after 6month

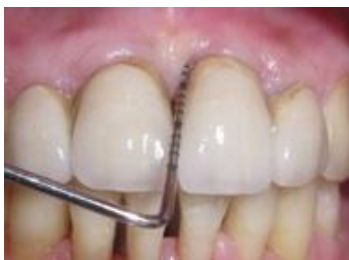

Fig 10c: postoperative probing depth (after 6month)