

DENTAL OPERATOR'S POSTURE AND POSITION

Aruna J. Bhandari¹, Viral H. Gada², Ashwin M. Nanda³, Akshay N. Joshi⁴, Prachi R. Chaudhari⁵, Divya G. Toshniwal⁶

1. Professor and HOD, Dept. Prosthodontics, Rural Dental College, Loni, Ahmednagar.

2,3,4,5,6. Postgraduate students, Dept. Prosthodontics, Rural Dental College, Loni, Ahmednagar.

ABSTRACT:

In dental practice knowledge of patient's and operator's position is important for the health and comfort of both patient and operator. The causes of musculoskeletal disorders in dentistry are multifactorial, ranging from nonergonomic loupes and improper selection of delivery systems, to generic exercise that worsens muscle imbalances. Therefore proper operator positioning techniques help in preventing the progression toward chronic pain or potential injury for the operator.

Keywords: Operator posture and position, Musculoskeletal disorders, Neutral position



INTRODUCTION:

Knowledge of patient's and operator's position is important for the health and comfort of both patient and operator. Adjustment of dental chair is an important consideration when patient is sitting comfortably. Concepts of dental operator seating have changed greatly since seated, 4-handed dentistry was first embraced by the profession in the 1960s. Although move from standing to sitting dentistry promised to reduce the high incidence of work-related pain among dentists, statistics indicate that this goal has not yet been achieved.^[1-5] An average of 2 out of 3 dental professionals experience occupational pain.^[1-12] Nearly one third of dentists who retire early are forced to do so because of a MSD.^[13]

The causes of MSDs in dentistry are multifactorial, ranging from nonergonomic loupes and improper selection of delivery systems, to generic

exercise that worsens muscle imbalances. However, proper operator positioning techniques can go a long way in preventing the progression toward chronic pain or potential injury for the operator.

If operator maintains proper position and posture during treatment, the operator is less likely to get strain, fatigue, be more efficient and less chance of getting musculoskeletal disorders.

Operator's posture and position is a very important aspect in the success of the dental treatment. The correct positioning helps the operator to have a good visibility and accessibility to the oral cavity.

POSITIONS OF DENTAL OPERATOR:

NEUTRAL SITTING POSITION^[14]:

Research indicates that over 80 percent of dentists complain of pain in the upper body and back. This musculoskeletal pain often is the direct result of body positioning and movements made by dental healthcare professionals in their daily work.

Neutral position is the ideal positioning of the body while performing work activities and is associated with decreased risk of musculoskeletal injury. It is generally believed that the more a joint deviates from the neutral position, the greater the risk of injury

NEUTRAL SEATED POSITION (FIG.1)

1. Forearms parallel to the floor.
2. Weight evenly balanced.
3. Thighs parallel to the floor.
4. Hip angle of 90°.
5. Seat height positioned low enough so that you are able to rest the heels of your feet on the floor.
6. When working from clock positions 9-12:00 (or 12-3:00), spread feet apart so that your legs and the chair base form a tripod, somewhat like the legs of a three-legged stool. This tripod formation creates a very stable position from which to work.

AVOID:

positioning your legs under the back of the patient chair. In this position the patient chair will be too high and you will

need to raise your upper arms to reach the patient's mouth

NEUTRAL NECK POSITION (FIG.2)

- Head tilt of 0° to 15°
- The line from your eyes to the treatment area should be as near to vertical as possible

AVOID:

- Head tipped too far forward
- Head tilted to one side

NEUTRAL SHOULDER POSITION (FIG.3)

- Shoulders in horizontal line
- Weight evenly balanced when seated

AVOID:

- Shoulders lifted up toward ears
- Shoulders hunched forward
- Sitting with weight on one hip

NEUTRAL BACK POSITION (FIG.4)

- Leaning forward slightly from the waist or hips
- Trunk flexion of 0° to 20°

AVOID:

- Over flexion of the spine (curved back)

NEUTRAL UPPER ARM POSITION (FIG.5)

- Upper arms hang in a vertical line parallel to long axis of torso

- Elbows at waist level held slightly away from body

AVOID:

- Greater than 20° of abduction of elbows away from the body
- Elbows held above waist level

NEUTRAL FOREARM POSITION (FIG.6)

- Held parallel to the floor
- Raised or lowered, if necessary, by pivoting at the elbow joint

AVOID:

- Angle between forearm and upper arm of less than 60°

NEUTRAL HAND POSITION (FIG.7)

- Little finger-side of palm is slightly lower than thumb-side of palm
- Wrist aligned with forearm

AVOID:

- Thumb-side of palm rotated down so that palm is parallel to floor
- Hand and wrist bent up or down

OPERATING POSITION^[15, 16] (FIG.8)

Operating positions may be described by the location of the operator or by the location of the operator's arms in relation to patient position. For a right-handed operator, there are essentially four positions-right front, right, right rear and direct rear. These are sometimes referred

to as the 7-, 9-, 11 and 12-o'clock positions, respectively.

For left-handed operators, these positions are left front, left and left rear which are referred as 5-, 3- and 1- o'clock positions respectively.

Right Front Position. This right front position facilitates examination and work on mandibular anterior teeth), mandibular posterior teeth (especially on the right side), and maxillary anterior teeth. It is often advantageous to have the patient's head rotated slightly toward the operator.

Right Position. In the right position, the operator is directly to the right of the patient . This position is convenient for operating on the facial surfaces of the maxillary and mandibular right posterior teeth and the occlusal surfaces of the mandibular right posterior teeth.

Right Rear Position. The right rear position is the position of choice for most operations. Most areas of the mouth are accessible and can be viewed directly or indirectly using a mouth mirror. The operator is behind and slightly to the right of the patient. The left arm is positioned around the patient's head. When operating from this position, the lingual and incisal (occlusal) surfaces of the **maxillary teeth** are viewed in the mouth mirror. Direct vision may be used on mandibular teeth, particularly on **the left side**, but the use of a mouth mirror is advocated for light reflection, retraction, and visibility.

Direct Rear Position. The direct rear position has somewhat limited application and is primarily used for operating on the lingual surfaces of mandibular anterior teeth. The operator is located directly behind the patient and looks down over the patient's head.

STANDING OPERATOR'S POSITION^[17]

Operators usually make impressions in standing position and hence proper standing position is equally important for increasing comfort and efficiency.

Patient should be seated upright with head in line with the body and back along with the head rest should be adjusted to give support. (Fig. 9)

Height of the chair should be adjusted according to operating procedures. When making the lower impression, patient's mouth should be on a level with the operator's shoulder and during upper impression the patient's mouth should be on a level with operator's elbow and the

chair may be tilted back a little approximately 20°–30°.

Position of the operator for making lower impression should be in front of the patient and on right side for right handed (7 o'clock) and on left side for left handed (5 o'clock). (Fig.10)

For upper impression, right handed operator should be to the right and a little behind the patient (11 o'clock) and 1 o'clock position for left handed. (Fig.11)

CONCLUSION:

With tight patient schedules, emergencies, and production goals to consider, it is easy to overlook proper operator's posture and positioning. However, taking the time to position the patient, dentist, assistant, and equipment properly can not only have positive ramifications for the operator's posture, comfort, and career longevity—it can also lead to better treatment and increased productivity.

REFERENCES:

1. Shugars D, Miller D, Williams D, et al. Musculoskeletal pain among general dentists. *Gen Dent.* 1987; 35:272-276.
2. Rundcrantz BL, Johnsson B, Moritz U. Cervical pain and discomfort among dentists. Epidemiological, clinical and therapeutic aspects. Part 1. A survey of pain and discomfort. *Swed Dent J.* 1990; 14:71-80.
3. Augustson TE, Morken T. Musculoskeletal problems among dental health personnel. A survey of the public dental health services in Hordaland. *Tidsskr nor Laegeforen.* 1996; 116:2776-2780.
4. Finsen L, Christensen H, Bakke M. Musculoskeletal disorders among dentists and variation in dental work. *Appl Ergon.* 1998; 29:119-125.

5. Chohanadisai S, Kukiattrakoon B, Yamong B, et al. Occupational health problems of dentists in southern Thailand. *Int Dent J.* 2000; 50:36-40.
6. Akesson I, Schütz A, Horstmann V, et al. Musculoskeletal symptoms among dental personnel; lack of association with mercury and selenium status, overweight and smoking. *Swed Dent J.* 2000; 24:23-38.
7. Alexopoulos EC, Stathi IC, Charizani F. Prevalence of musculoskeletal disorders in dentists. *BMC Musculoskelet Disord.* 2004; 5:16.
8. Fish DR, Morris-Allen DM. Musculoskeletal disorders in dentists. *NY State Dent J.* 1998; 64:44-48.
9. Lehto TU, Helenius HY, Alaranta HT. Musculoskeletal symptoms of dentists assessed by a multidisciplinary approach. *Community Dent Oral Epidemiol.* 1991; 19:38-44.
10. Marshall ED, Duncombe LM, Robinson RQ, et al. Musculoskeletal symptoms in New South Wales dentists. *Aust Dent J.* 1997; 42:240-246.
11. Ratzon NZ, Yaros T, Mizlik A, et al. Musculoskeletal symptoms among dentists in relation to work posture. *Work.* 2000; 15:153-158.
12. Rundcrantz BL, Johnsson B, Moritz U. Occupational cervico-brachial disorders among dentists. Analysis of ergonomics and locomotor functions. *Swed Dent J.* 1991; 15:105-115.
13. Burke FJ, Main JR, Freeman R. The practice of dentistry: an assessment of reasons for premature retirement. *Br Dent J.* 1997; 182:250-254.
14. Nield-Gehrig JS. Fundamentals of periodontal instrumentation – 4th Ed, 2000 Lippincott Williams and Wilkins, Philadelphia.
15. Sturdevant's art and science of operative dentistry. 4th edition. Mosby Inc., Philadelphia; 2002
16. Vimal Sikri, Textbook of operative dentistry- 3rd edition, 2014.
17. Wright. PSG: complete denture prosthetics : A clinical and laboratory manual- 2nd edition, 1983.

FIGURES:

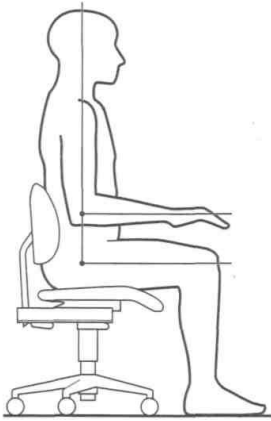


Fig.1 (Neutral Seated Position)

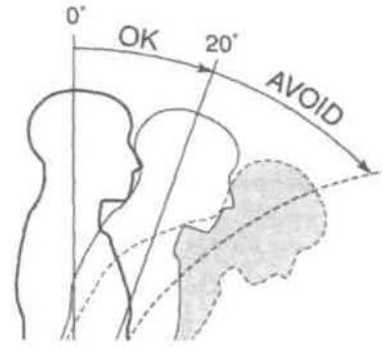


Fig.4 (Neutral back Position)

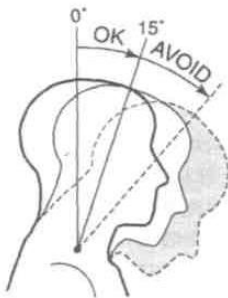


Fig.2 (Neutral neck Position)

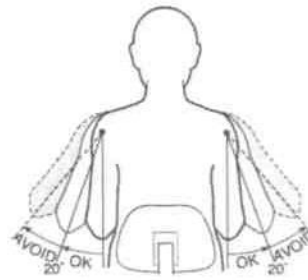


Fig.5 (Neutral Upper Arm Position)

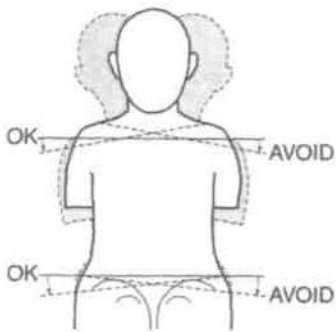


Fig.3 (Neutral shoulder Position)

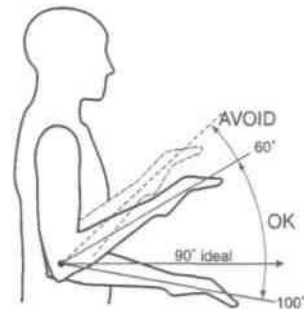


Fig.6 (Neutral forearm Position)

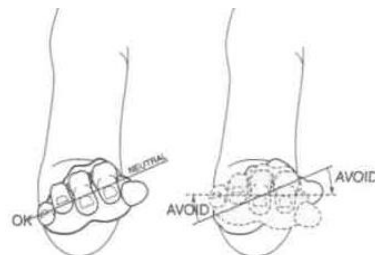


Fig.7 (Neutral hand Position)

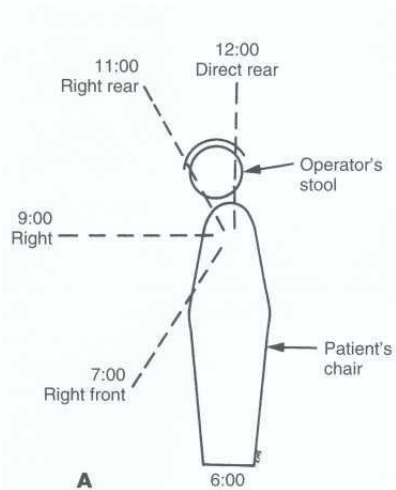


Fig. 8 (operating positions)

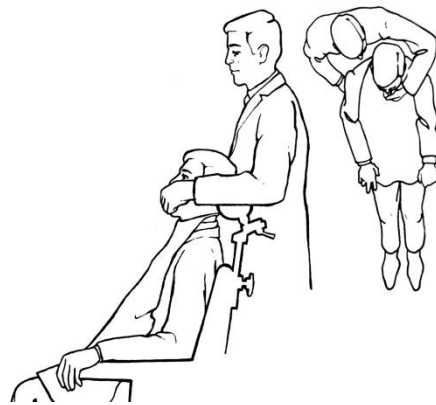


Fig. 10 (Position of the operator for making upper impression)

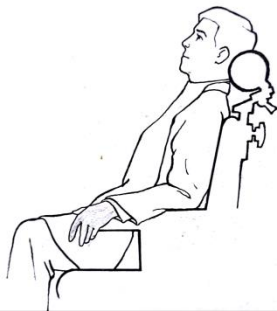


Fig. 9 (Patient seated upright with head in line with the body and back along with the head rest)

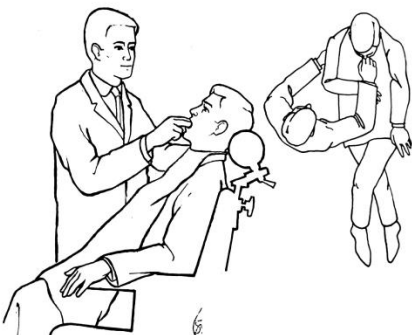


Fig. 10 (Position of the operator for making lower impression)