

# Detection of Malarial Parasite using machine learning

Prabhleen Juneja<sup>1</sup>

<sup>1</sup>Thapar Institute of Engi. & Tech., Patiala  
(E-mail: prabhleenjuneja@gmail.com)

**Abstract**—for global health organizations, Malaria is one of the main burdens these days. Through some rough estimation, there are about 200 million cases of malaria worldwide and more than 420,000 deaths per year. Besides various researches have been done in this field, but these days, a key role in fighting this disease is modern information technology. One of the main hurdles in successful mortality reduction has been inadequate malaria diagnosis in particular. To improve the diagnosis of malaria, image analysis software and machine learning methods have been used in microscopic blood slides. This is the survey paper in which introduction about malaria is done and literature review has been discussed. Various techniques for diagnosing the malaria have also been presented in this paper. Various approaches like image acquisition and machine learning has been the part of the review.

**Keywords**—Malaria; diagnosis of malaria; image acquisition; machine learning.

## I. INTRODUCTION

The main cause of Malaria [3] is because of protozoan a parasite that is transferred by the bites of infected female Anopheles mosquitoes which infects the red blood cells. Many deaths take place because of malaria in Africa, almost every minute a child dies from malaria. According to the survey, an estimated of 3.3 billion people in 95 different territories and countries are in danger of getting infected with malaria. About 214 million cases of malaria are recorded globally in 2016 and about 438,000 malaria deaths are recorded so far [1]. Classic symptoms of malaria comprise of fatigue, headaches, fever and in most of the cases, seizures and coma which finally lead to death of the person.

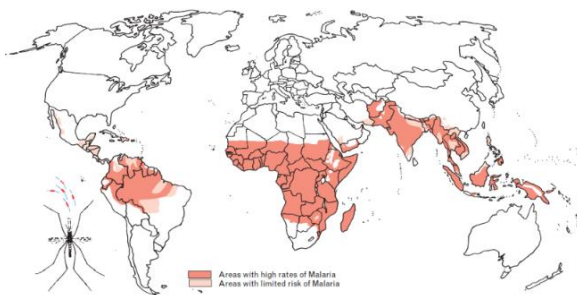


Figure 1: Coverage of malaria in whole world [1]

Every year, millions of blood films are inspected for malaria, which demands for manual counting of infected red

blood cells and parasites with the help of trained microscopist. The parasite count should be accurate not only for diagnosing the malaria, but also for testing for measuring classifying disease severity, drug resistance and drug-effectiveness. The microscopic diagnostics are so much systemized that it totally depends on the skills and the experience of the microscopist [4]. Sometimes, it may lead to incorrect decision diagnostic. For the cases which are false-negative, it may lead to unnecessary use of antibiotics and for false positive cases, a mis diagnosis entails unnecessary use of anti-malaria drugs and for those suffering from their potential side effects like diarrhea, nausea, abdominal pain and many other complications [2].

As compared to manual counting, automatic parasite counting has too many advantages [3, 4].

- It helps in providing a standardized and reliable explanation of blood films
- It helps patients to be served by minimizing the workload of workers who are dealing with this.
- It because a lesser cost for diagnostic

Processing parasitemia automatically [10] involves few steps that should be undertaken. Firstly, digital blood slide images are taken. Secondly, detecting the blood cells or parasites. Thirdly, after cell detection, computation of features is to be done for visual appearance of uninfected and infected blood cells. In the last step, a trained classifier, help in discriminating between infected and uninfected cells. Once we are familiar with total number of infected and uninfected cells, we can easily compute for parasitemia using mathematical equations [5].

## II. MALARIA

Malaria is a contagious disease caused because of Plasmodia parasites [6]. Different parasite species which cause malaria are: Plasmodium ovale, Plasmodium falciparum, Plasmodium vivax Plasmodium knowlesi and Plasmodium malariae. World Health Organization [1] has prioritized malaria as one of the tropical diseases.

Table I: Different types of malaria

Species	Comments
P ovale	P. ovale, host cells are somewhat expanded and are in an oval shape with tufted ends.
P falciparum	P. falciparum mainly present in the peripheral blood. Mostly all stages of malaria present in the peripheral blood.
P vivax	P. vivax, host cells are frequently

	enlarged and their shape is irregular.
P knowlesi	P. knowlesi, red blood cells, which are infected do not appear enlarged. The parasite erythrocytic cycle, which is for 24 hours, shorter than P. falciparum's cycle, which is for 48 hours and much shorter than P. malariae's cycle, which is for 72 hours.
P malariae	P. malariae, host cells are not much enlarged.

Table II: Morphological Feature of Malaria Parasites [7]

Species	stages	Size
P ovale	Schizonts Trophozoites Gametocytes	Enlarged
P falciparum	Trophozoites Gametocytes	Normal
P vivax	Schizonts Trophozoites Gametocytes	Enlarged
P knowlesi	Schizonts Trophozoites Gametocytes	Normal
P malariae	Schizonts Trophozoites Gametocytes	Normal

III. LITERATURE REVIEW

Literature review has been discussed as under.

Table III: Literature review

Author	Comments
KS. Kim et al. [8]	The author presented the study on the analysis images of blood cell for detecting irregularities in the original image with the help of fuzzy measure and labeling of all the cells in the image. The labeled cells were further categorized with the help of some features like size, color and features into white blood cells (WBCs), platelets and red blood cells (RBC) with the help of a hierarchical neural network model.
C. Di Ruberto et al. [3]	The author reported that digital images which were to be achieved from scanning the color photos of stained malarial blood from a microscope uses morphological granulometry for estimating the size distribution of Red blood cells. The author had used HSV color space for analysis of the final result and had used the morphological approach for classifying the parasites

	into mature trophozoites, gametocytes and immature trophozoites.
S. Sio et al. [14]	The author developed a program known as an image analysis for getting valid resolution of parasitemia known as Malaria Count. The four different stages are included in algorithms that are: edge linking, edge detection, parasite detection and clump splitting. For preprocessing adaptive histogram equalization was used.
FB. Tek et al. [5]	The author presented with a method for detecting the malaria parasites using Bayesian pixel classifier which helps in separating the stained and non-stained pixels and after separating both of them, it classified the stained pixels as parasites or non-parasites with the help of distance weighted K-nearest neighbor classifier.
M. Le et al. [10]	The author had reported an approach using semi-automatic image processing for detecting malaria parasites. The author had made a comparison between based approaches which are different solid components in the smears by utilizing the inter associations between different radiometric and observations. The algorithm used for this approach comprises of 6 main steps which are: image decomposition, erythrocyte size estimation, erythrocyte segmentation nucleated component detection, leukocytes and malarial gametocytes identification and lastly the parasitemia estimation.
A. Dempster et al. [2]	The author had provided with an overview of studies of malaria through computer diagnosis and provide with many evaluations for their works. They also had provided a vision for the future work in automated microscopy diagnosis of malaria.

IV. DIAGNOSIS FOR MALARIA

With the availability of various drugs for treatment, Malaria is a curable disease. Yet there exists no such productive vaccine against malaria, but this area is very active in its research and field studies [13]. Once the person got affected, this disease is rapidly progressing, with a high risk for symptoms for P. falciparum infections. So, a prompt identification of malaria is so important. Malaria these days can be diagnosed in different ways as there scope for improvement by various malaria diagnostic tests which may include increasing specificity, improving ease of use and reducing cost [9]. Automated malaria diagnosis is one of the main diagnostic

tests for malaria these days. This diagnostic test is further divided into 2 parts.

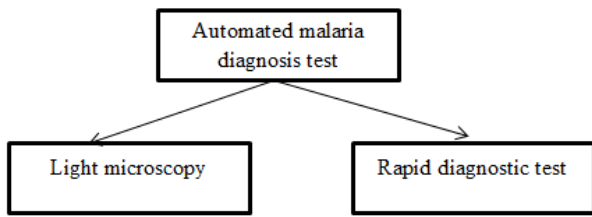


Figure 2: Types of automated malaria test

1) *Light microscopy* [16]: With the help of microscopy, all the species of parasite can be easily detected. It further permits in computing the level of parasitemia and also helps in monitoring the improvement of the person. And this test is cost efficient as compared with other methods which are easily available too [16,17]. The main disadvantage of this test is that it requires extensive training for the microscopist for becoming professionals in reading the malaria slide, the large manual work involved and maintaining skills.

For diagnosing malaria under a microscope, firstly patient’s blood drop is to be applied to a glass slide, which is then submerged in a staining solution for making the parasites visible under a conventional light microscope, usually with a 100× oil objective [14]. Blood smears which are prepared for malaria diagnosis consists of 2 different types. One is thick smear which is used for detecting the presence of parasites in a drop of blood. The detection of parasites in thick smears is 11 times higher than thin smears.

Another one is thin smears which are the outcome of unrolling the drop of blood covering the glass slide. It helps the examiner in identifying the malaria species and recognizes parasite stages more easily.

2) *Rapid diagnostic tests*: This test helps in detecting the evidence of malaria parasites and the process takes about 10–15 minutes. Their sensitivity for detection is much lower as compared with manual microscopy because neither they require any special equipment nor require only training [11].

In high burden areas, RDTs are more expensive than microscopy. A question arises whether RDT can replace by microscopy in the future? According to WHO, in many of the countries microscopy are being used more than RDTs. In rural areas where microscopy is not available there RDTs are much used. Using RDT, about 47% of malaria tests are done.

Some other methods for malaria diagnosis are:

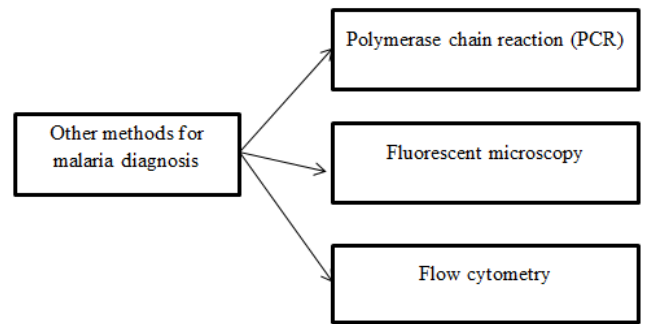


Figure 3: Other methods for malaria diagnosis

V. IMAGE ACQUISITION ALGORITHM USED FOR DETECTING THE MALARIA

Image acquisition is very helpful for detecting the malaria as it helps in providing the proper view of the diseases which can be much helpful in providing the treatment to the infected person. The design consists of an image classification problem and thus requires standard pattern recognition and classification system. Image acquisition [15] algorithm consists of 5 stages:

1. Image Acquisition
2. Extraction of red blood cells
3. Edge Detection
4. Binary Image
5. Counting of red blood cells

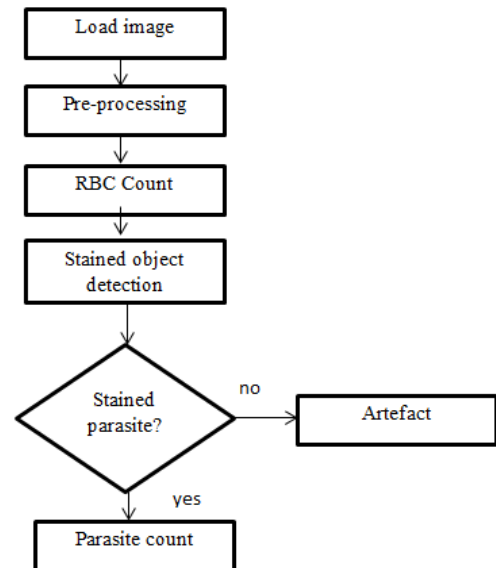


Figure 4: Flowchart for image acquisition algorithm

1) *Image Acquisition*: Is to be done with the help of high resolution Digital Camera.

2) *Preprocessing*: The motivation for preprocessing stage is to detach undesirable noise and object from the image for facilitating image segmentation into meaningful area.

Steps required for preprocessing are:

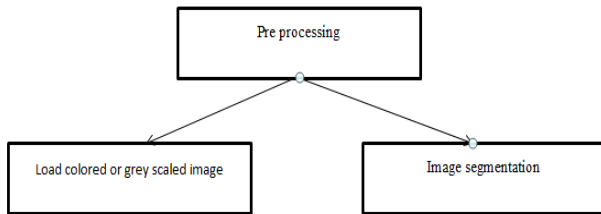


Figure 5: Steps in the preprocessing stage

3) *Counting red blood cells*: Extraction of RBC is one of the prime steps in counting of RBC. Only RBCs need to be extracted, but there is much possibility of other elements to be present in the smear [12]. So extraction of RBC in the proper manner must be on the basis of color RBCs which are to be extracted. Normally RBCs are red in color and their shape is circular. The cells, which are not RBCs are removed from the image. The obtained image will be consisting of only extracted RBCs [16].

4) *Malaria identification*: Now there exists a ring shape malaria parasite on RBCs. These parasites [17] are having a shape like a ring and the ring is generally of blue color.

Various other techniques used for image acquisition for detecting the malaria are as under:

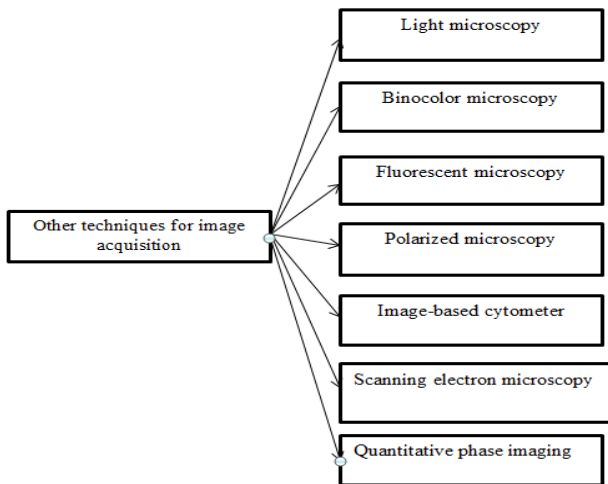


Figure 6: Various other techniques for image acquisition

## VI. MACHINE LEARNING

In machine learning [13] deep learning is one of the latest trending study, which has uplifted the production in many areas which are non-medical. Machine learning can be a supplement for multilayer neural network classifiers which is instructed with back propagation. A large training set are required for deep learning. Medical applications are in urge of adopting deep learning in this field, as an image which is to be trained are remarkably difficult to get because of specialized knowledge requirements and privacy concerns. I. Red et al [7]

published papers for applying deep learning to malaria diagnosis and uses neural networks to differentiate among uninfected and infected cells in thin blood smears. This is an absolute application for deep learning in machine learning as images of red blood cells, which are segmented, are a natural input to a neural network. The biggest advantages of deep learning are that it does not require the design of handcrafted features. Other authors C. Ruberto et al [4] also had applied deep learning to cell segmentation that used neural networks. M. Poostchi et al. [9] who used deep belief networks and recently P. T. Suradkar et al [12] presented an end-to-end framework using faster Region-based Neural Network.

## CONCLUSION

This survey article is based on giving an eye on the latest development which is to be carried out in the field of automated malaria diagnosis with the help of image analysis and machine learning methods. In the last few decades, both these techniques are the most dynamic area of research. However, with the advancement of new deep learning approaches, which have made a deep impression in the field of machine learning is very useful and attracting many researchers to work on it. Machine learning helps in taking the tough task from users and provides them with designing features, because of that, many of the handcrafted features which were used so far have become useless. In addition, machine learning can be used for cell segmentation and not only for cell classification, because of this many of the cell segmentation approaches which are used presented could be outdated soon. Given the wide acceptance to deep learning as a part of machine learning, large annotated data, image repositories for training are easily understandable which help in leading a great support for data acquisition efforts. This will lead to larger test suites on patient level and help in allowing for more standardized evaluations in the field for diagnosis of malaria.

## REFERENCES

- [1] A. Ozcan and E. McLeod, "Lensless Imaging and Sensing," no. January, pp. 77–102, 2016.
- [2] A. Dempster, I. Kale, "Computer vision for microscopy diagnosis of malaria", *Malaria Journal*, pp. 1362–1369, 2017.
- [3] C. Di Ruberto, A. Dempster, S. Khan, B. Jarra, "Automatic thresholding of infected blood images using granulometry and regional extrema". *Proc. of ICPR*, pp. 3445–3448, 2013.
- [4] C. Ruberto, A. Dempster, S. Khan, B. Jarra, "Analysis of infected blood cell images using morphological operators". In *Image and Vision Computing*, pp. 133–146, 2012.
- [5] FB. Tek, I. Kale, "Malaria parasite detection in peripheral blood images", In: *Proc Br Mach Vis Conf. Edinburgh UK*, pp. 456–487, 2015.
- [6] G. Diaz, F. Gonzalez, E. Romero, "Automatic clump splitting for cell quantification in microscopical images", *Journal of Biomedical Informatics*, pp. 296–307, 2017.
- [7] I. Red and B. Cells, "Multispectral Atomic Force Microscopy-Infrared Nano-Imaging of Malaria Infected Red Blood Cells," no. January, 2018.
- [8] KS. Kim, PK. Kim, JJ. Song, YC. Park, "Analyzing blood cell image to distinguish its abnormalities", In: *Proceedings of the Eighth ACM International Conference on Multimedia*, pp. 395–397, 2015.

- [9] M. Poostchi, K. Silamut, R. J. Maude, S. Jaeger, "Image analysis and machine learning for detecting malaria," *Transl. Res.*, vol. 194, pp. 36–55, 2016.
- [10] M. Le, T. Bretschneider, C. Kuss, P. Preiser, "A novel semiautomatic image processing approach to determine *Plasmodium falciparum* parasitemia in Giemsa stained thin blood smears", *BMC Cell Biology*, pp. 9-15, 2008.
- [11] NE. Ross, CJ. Pitchard, DM. Rubin, AG. Duse, "Automated image processing method for the diagnosis and classification of malaria on thin blood smears", *Med Boil Eng Comput.* pp. 427–436, 2016
- [12] P. T. Suradkar, "Detection of Malarial Parasite in Blood Using Image Processing," vol. 2, no. 10, pp. 124–126, 2013.
- [13] S. S. Devi, S. A. Sheikh, R. H. Laskar, "Erythrocyte Features for Malaria Parasite Detection in Microscopic Images of Thin Blood Smear : A Review," no. November, 2016.
- [14] S. Sio, W. Sun, S. Kumar, W. Bin, "Malariacount: an image analysis based program for accurate determination of

