



BASIC

RHYTHM INTERPRETATION

EKG & PHARMACOLOGY

PRE-TEST and NOTES PAGES

!!! NOTE !!!

Students will **NOT** be permitted to stay for the course without manual and a completed pretest

NAME _____ **DATE** _____

BASIC EKG ANSWER SHEET

1 _____

11 _____

2 _____

12 _____

3 _____

13 _____

4 _____

14 _____

5 _____

15 _____

6 _____

16 _____

7 _____

17 _____

8 _____

18 _____

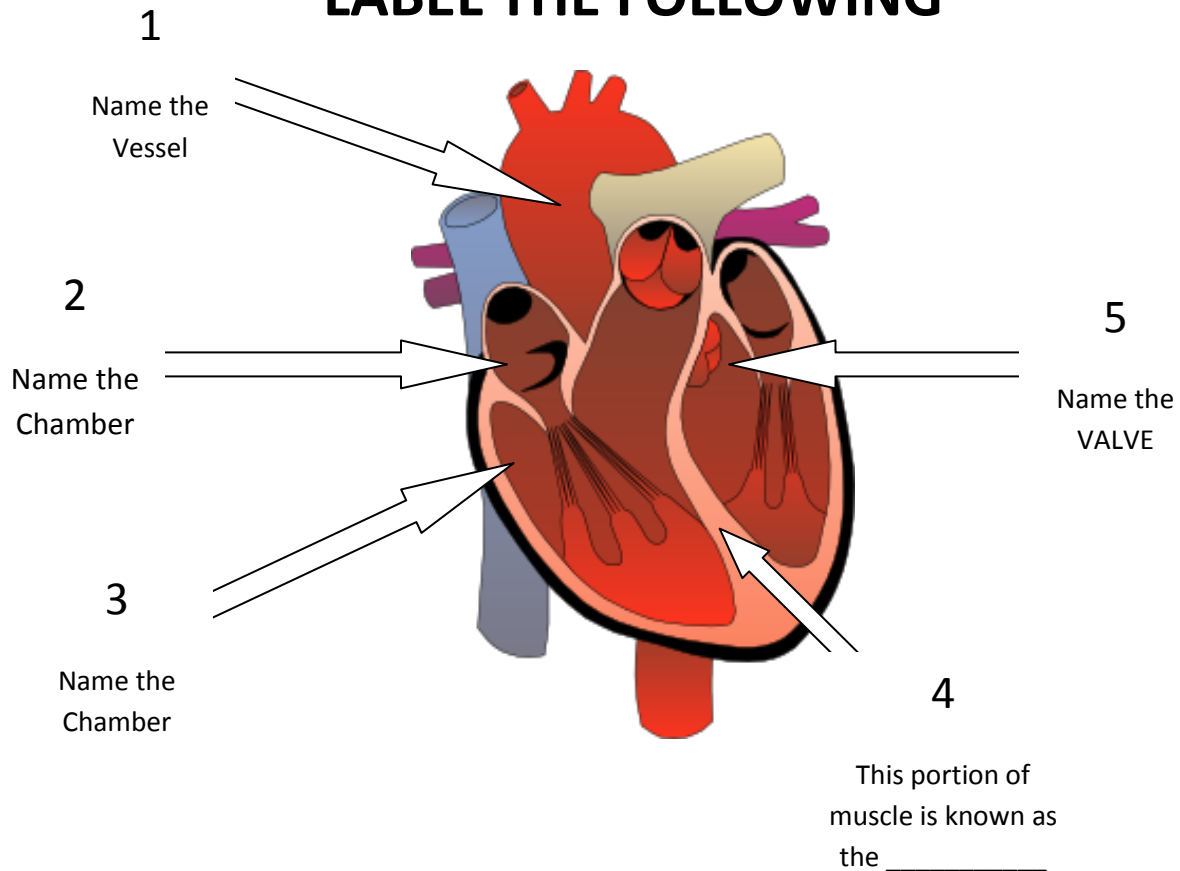
9 _____

19 _____

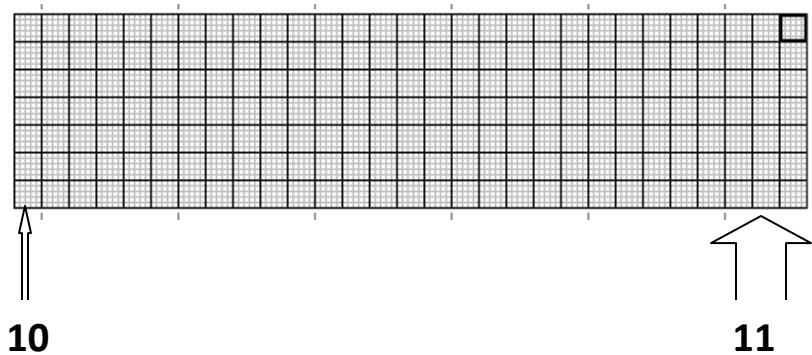
10 _____

20 _____

LABEL THE FOLLOWING



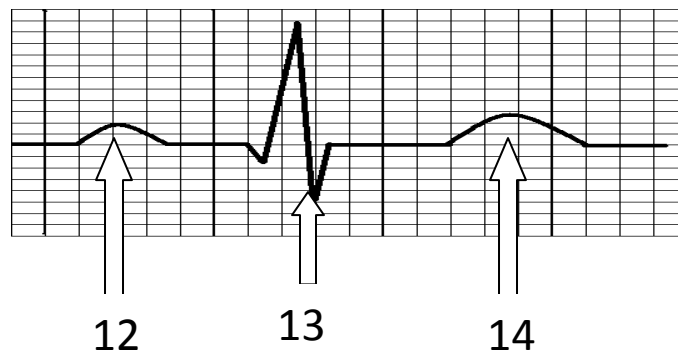
6. 40-60 beats per minute is the normal intrinsic rate for which electrical conducting portion of the heart? _____
7. The R wave on an EKG tracing represents? _____
8. Repolarization of the Ventricles is represented by which wave? _____
9. Which portion of the EKG tracing represents the time it takes an electrical impulse to travel through the SA Node and the Atrium?



How many seconds does one
SMALL box represent ?

How many seconds does one
LARGE box represent ?

12, 13, 14; NAME THE WAVE



15. A normal QRS complex is Less than _____secs.

16. If there were exactly 4 large boxes between two consecutive QRS complexes, what would the heart rate be? _____

17. Based on the information given, identify the rhythm:

The atrial rate is regular at 62 beats a minute

The ventricular rate is regular at 62 beats a minute

There is a P wave for every QRS complex

The PR Interval is 0.18

The QRS complex measures 0.12

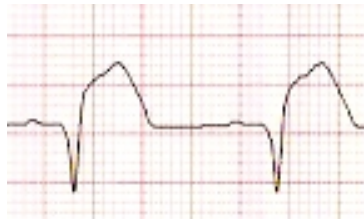
NAME THE RHYTHM _____

18. Cardizem (Diltiazem) is used to control the ventricular rate in

which two atrial rhythms? _____ and _____

19.

Based on the following diagram;



this pt is having which type of Myocardial Infarction?

ST Elevation, ST Depression, T-wave inversion, Non Diagnostic

20. Describe what's happening in the following in the

following EKG tracing;

