Disorders of the Esophagus

ASCENSION ALABAMA WEEKLY CME

SEPTEMBER 17, 2019

TRENT HOWARD, DO

Disclosures

None

Outline

Anatomy

Motility Disorders

Antireflux Surgery

Paraesophageal Hernias

Esophageal Cancer

Esophageal Emergencies

Esophageal Anatomy

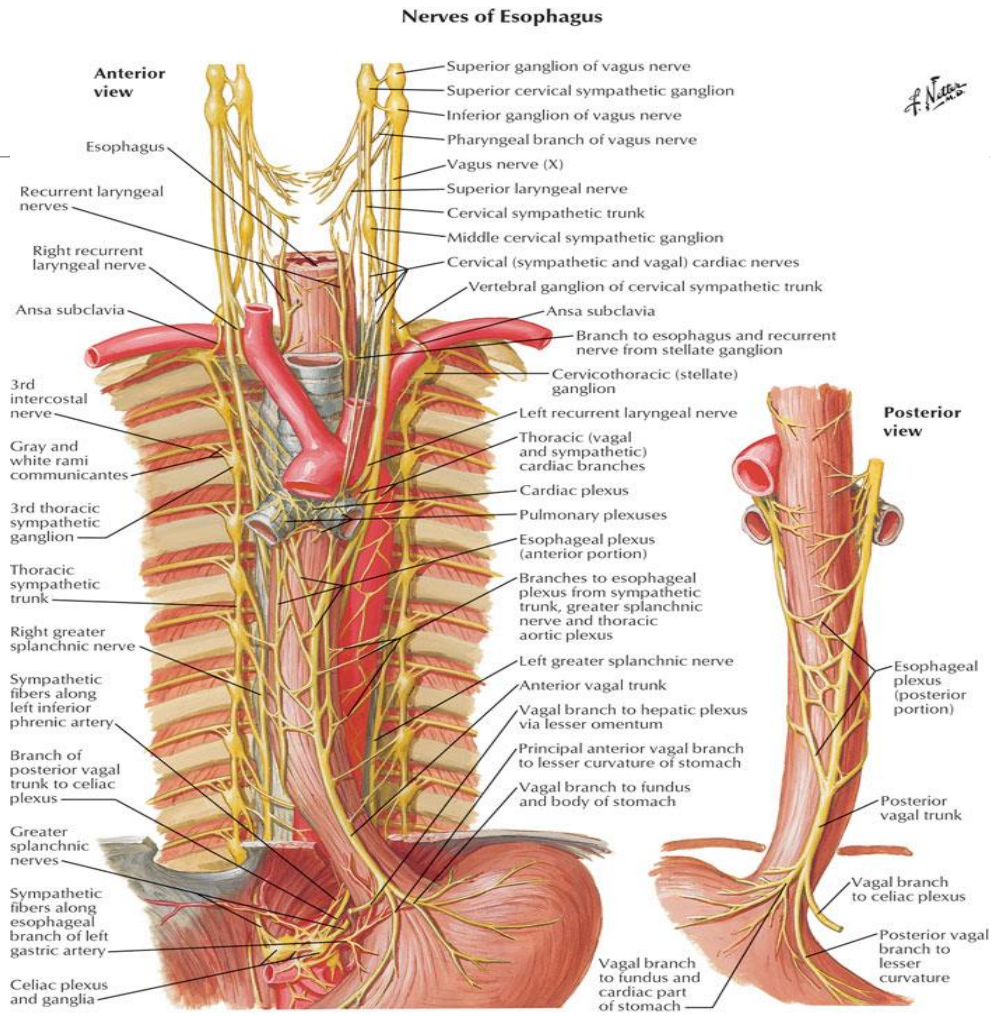

More anatomy

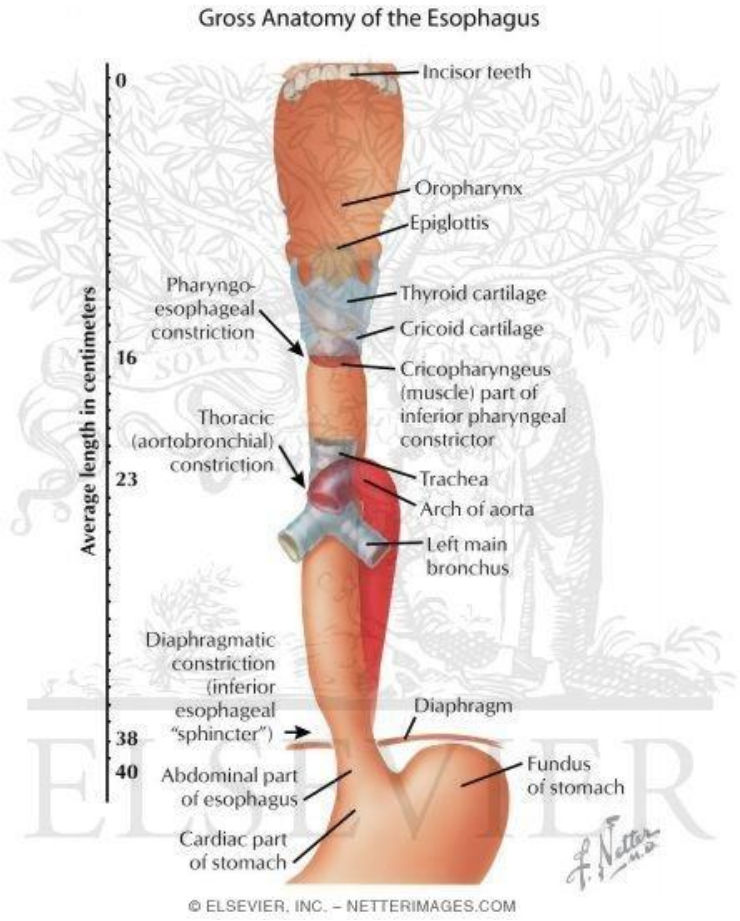

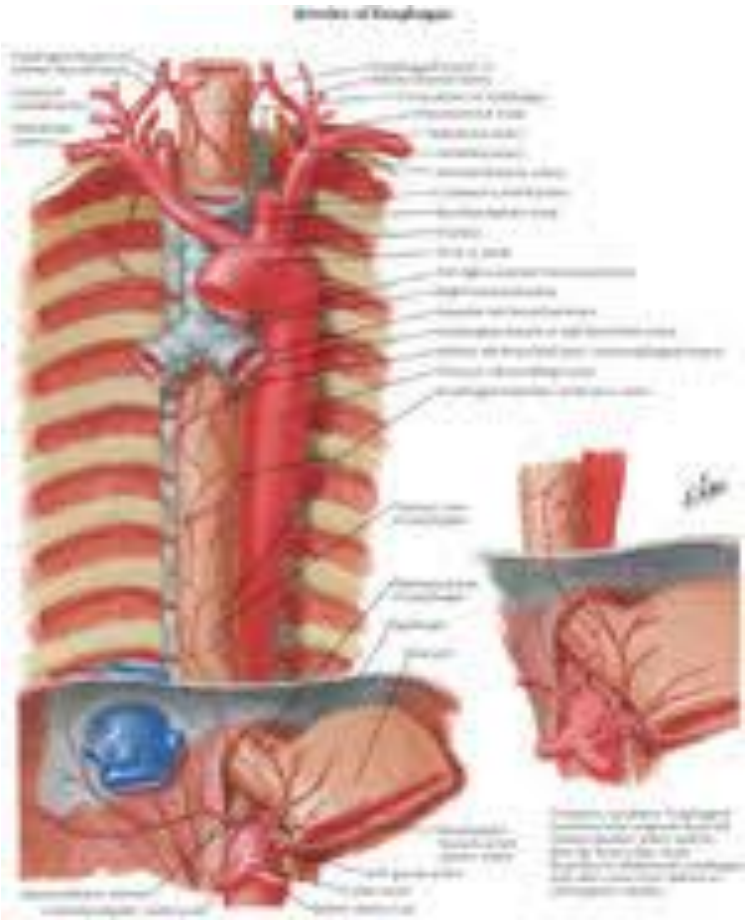

Esophageal Motility Disorders

Achalasia

Hypertensive LES

Nutcracker Esophagus

Esophageal Diverticulum

Secondary:

- Scleroderma
- Diabetes
- Alcohol
- Psychiatric disorders/meds

Achalasia

Loss of ganglion cells; ?etiology

Manometry: diagnostic criteria

- Failure to relax LES/hypertensive LES
- Aperistalsis

Barium swallow

EGD

Treatment progression:

- CCBs, nitrates, botox, balloon dilation
- Surgery: heller, POEM, esophagectomy

Bird's beak
deformity

A
B
C
D

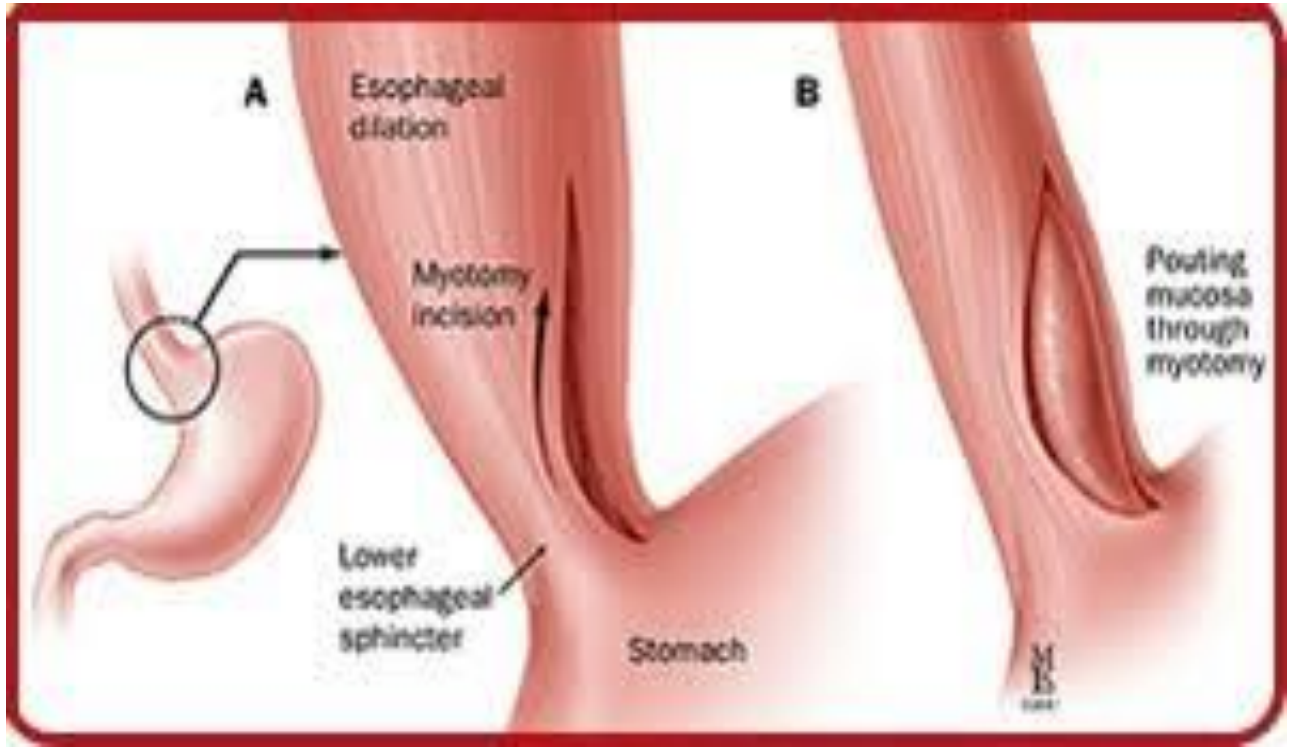
A
Esophageal dilation
Myotomy incision
Lower esophageal sphincter
Stomach
B
Pouting mucosa through myotomy

Hypertensive LES

? Etiology

Treatment often the same as achalasia but usually more successful

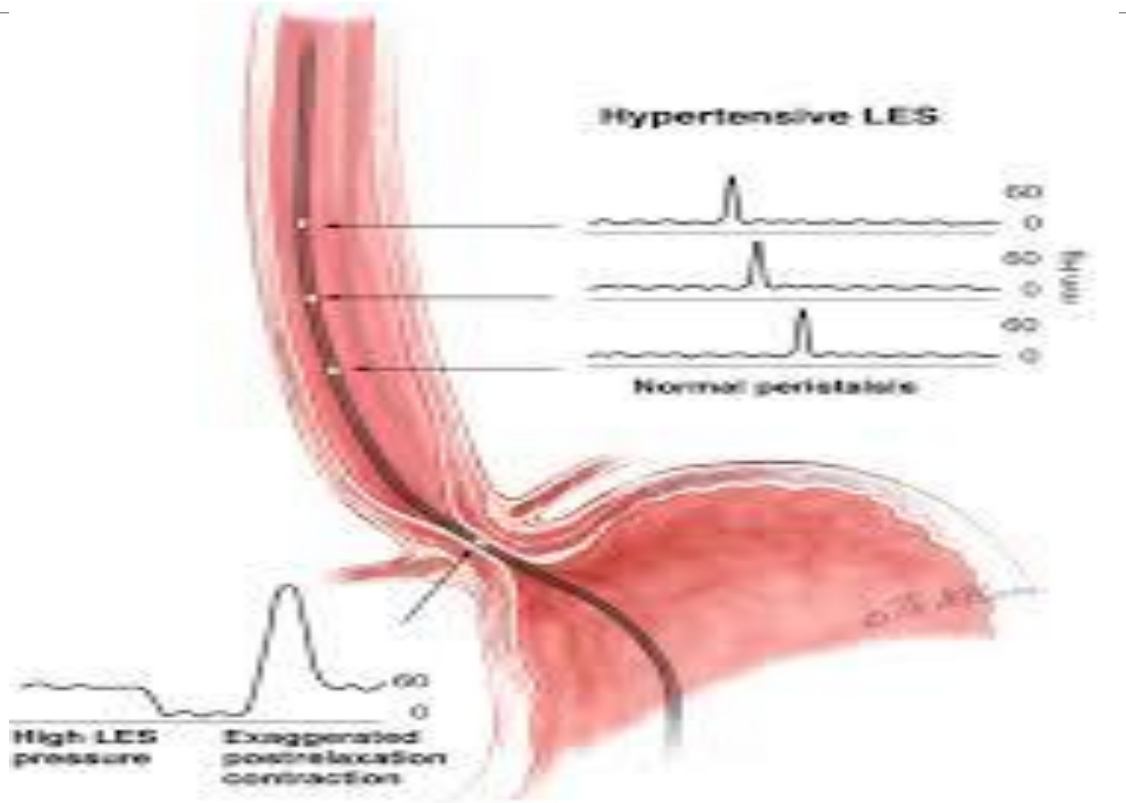
Hypertensive LES
60
0
60
0
60
0
mmHg
Normal peristalsis
60
0
High LES pressure
Exaggerated postrelaxation contraction

Nutcracker Esophagus

? Etiology

Treatment same as other motility disorders but least successful

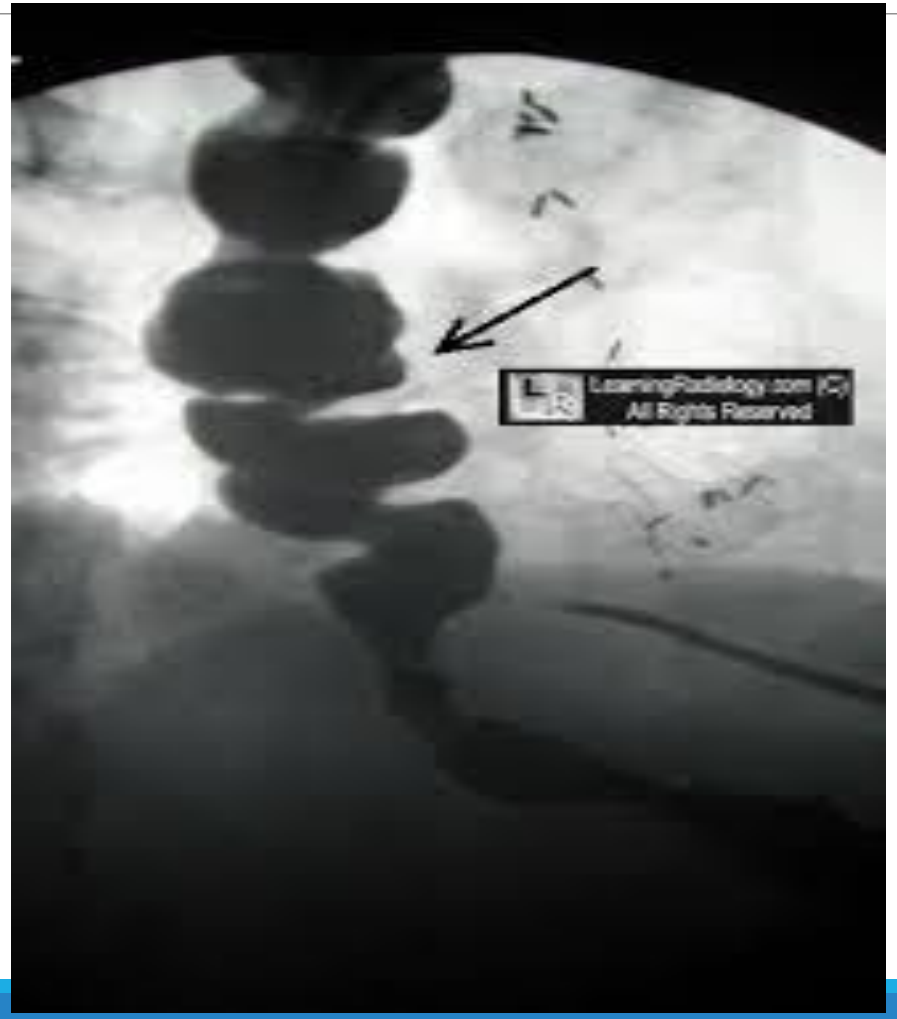
LearningRadiology.com (C)
All Rights Reserved

Manometric features of nutcracker esophagus

Required

Mean distal esophageal peristaltic wave amplitude >180 mm Hg (average amplitude of 10 swallows at 2 recording sites positioned 3 & 8 cm above LES)

Not required:

Peristaltic contractions of long duration found commonly (> 6 sec)

Resting pressure in LES is usually normal but may be elevated

In this case: nutcracker esophagus + hypertensive LES

Esophageal Diverticulum

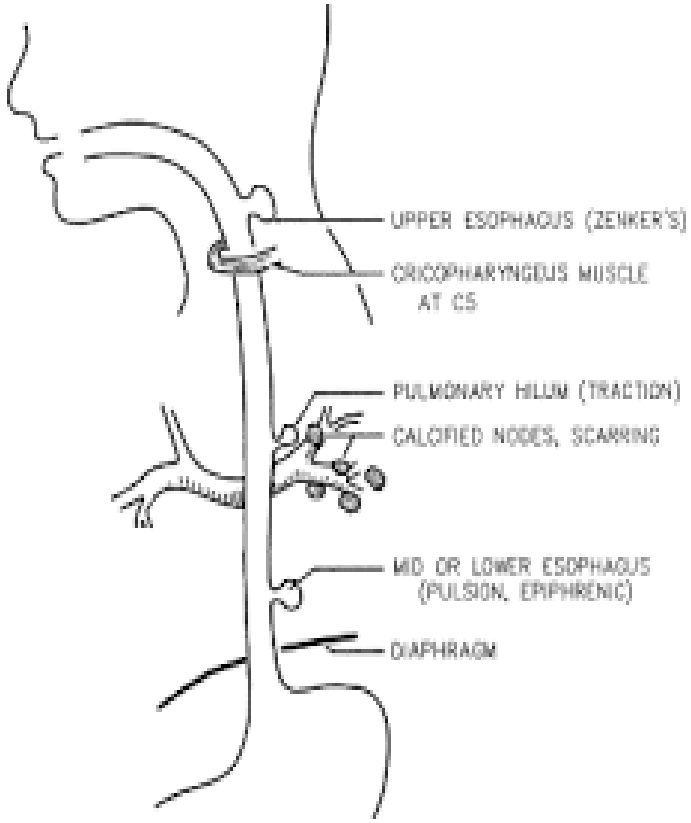

GERD

Typical symptoms:

- Reflux
- Dysphagia
- Heartburn

Atypical Symptoms

- Cough
- Hoarseness
- Sore throat
- Tooth decay
- Otitis media
- Non cardiac chest pain

Testing

- EGD
- Manometry
- 24 hr pH monitoring

Management of GERD

Lifestyle changes

- Weight loss
- Elevation of head of bed
- Avoid alcohol, caffeine, chocolate, peppermint
- Avoid food within 3 hrs of bedtime
- Small frequent meals

Pharmacotherapy

- H2 blockers
- PPIs
- Prokinetic
- Antacids

Surgery for GERD

Medication failure or complications

Young patients

Barrett’s esophagus

Extraesophageal manifestations

Surgical Options

Nissen Fundoplication

Linx system

Belsey Mark IV

Nissen

Linx System

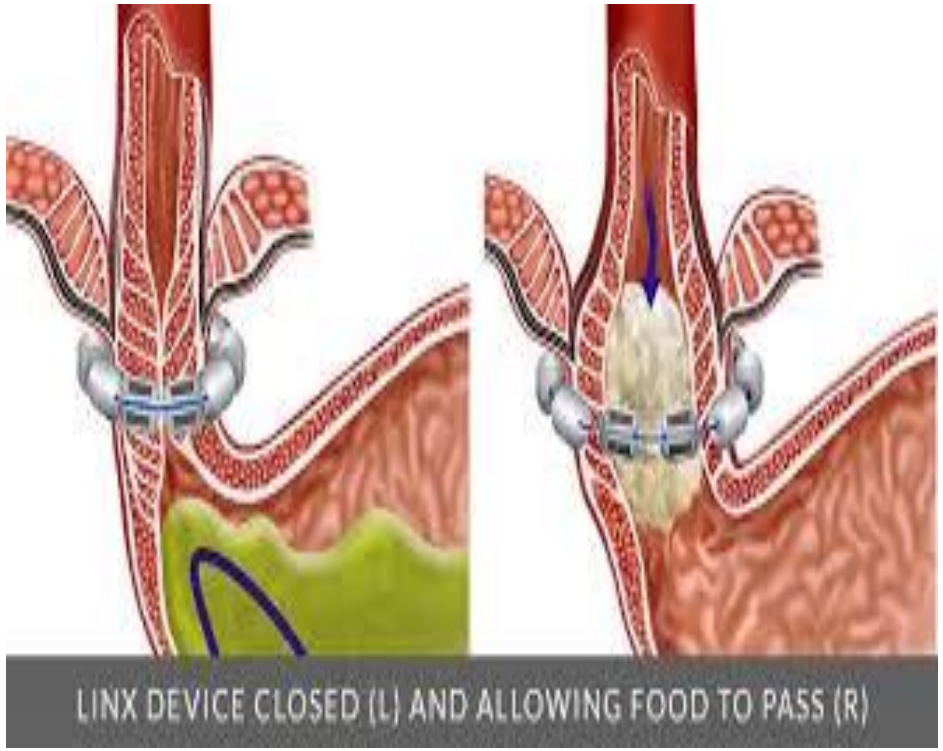

Belsey Mark IV

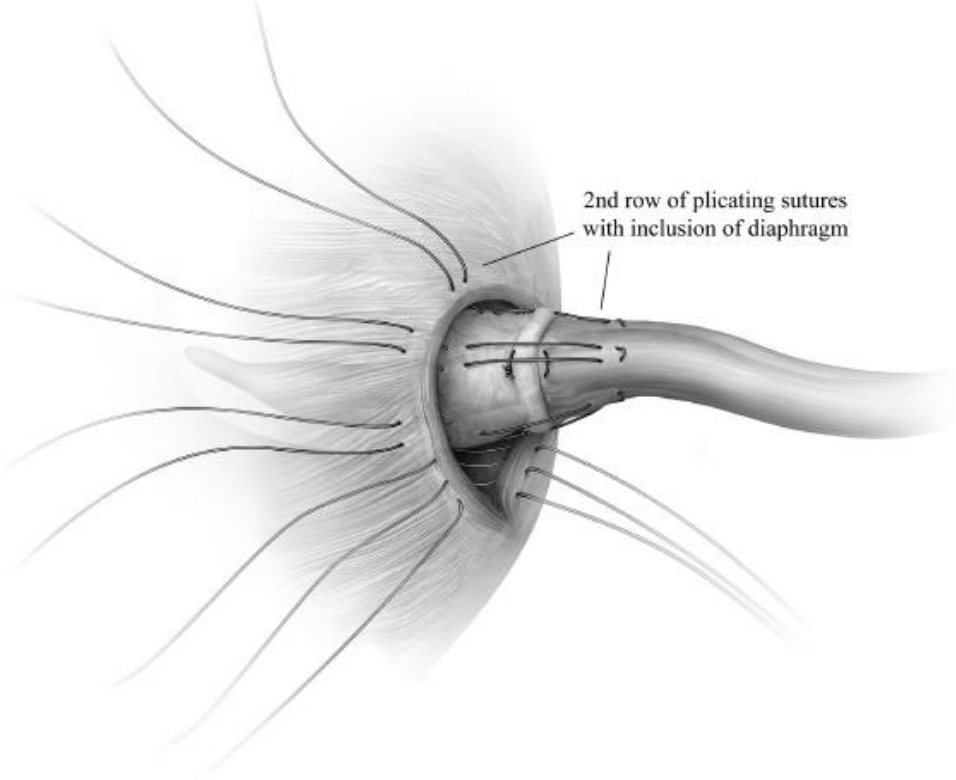

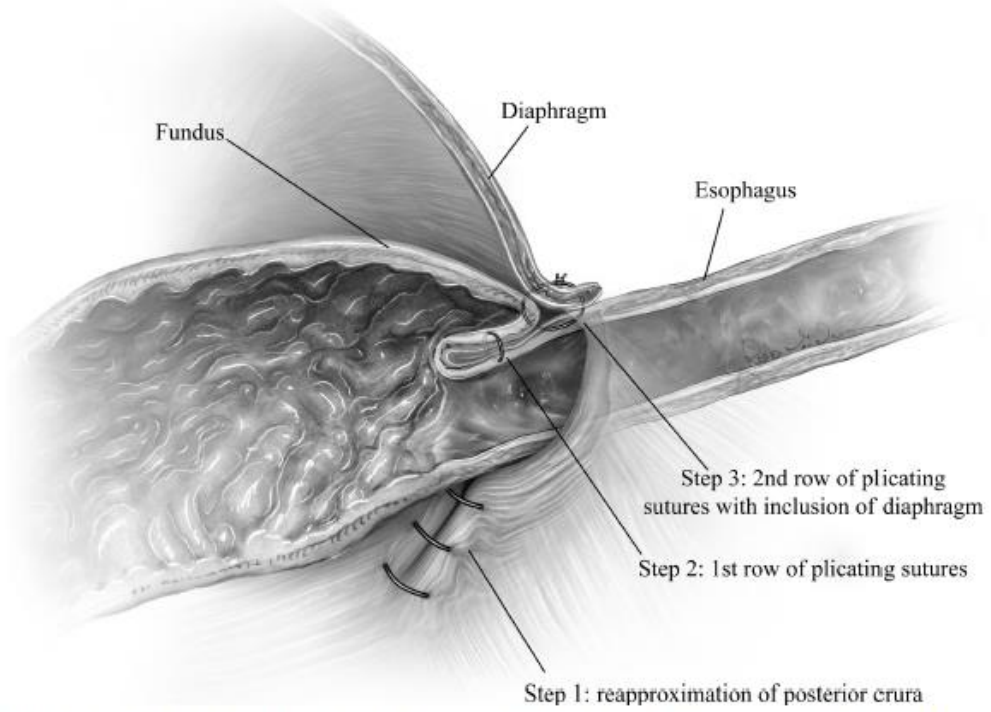

Figure 13 A final sagittal view of the Belsey Mark IV demonstrates the 3 steps of the repair: step 1—narrowing of the esophageal hiatus;

Belsey Mark IV

Beneficial in a relative subset of patients

- Reoperative with prior abdominal approach
- Impaired esophageal motility
- Incarcerated gastric volvulus
- Foreshortened esophagus

Paraesophageal Hernias

Types:

- Type 1: “Sliding”
- Type 2: True paraesophageal hernia
- Type 3: Mixed
- Type 4: Other abdominal contents included.

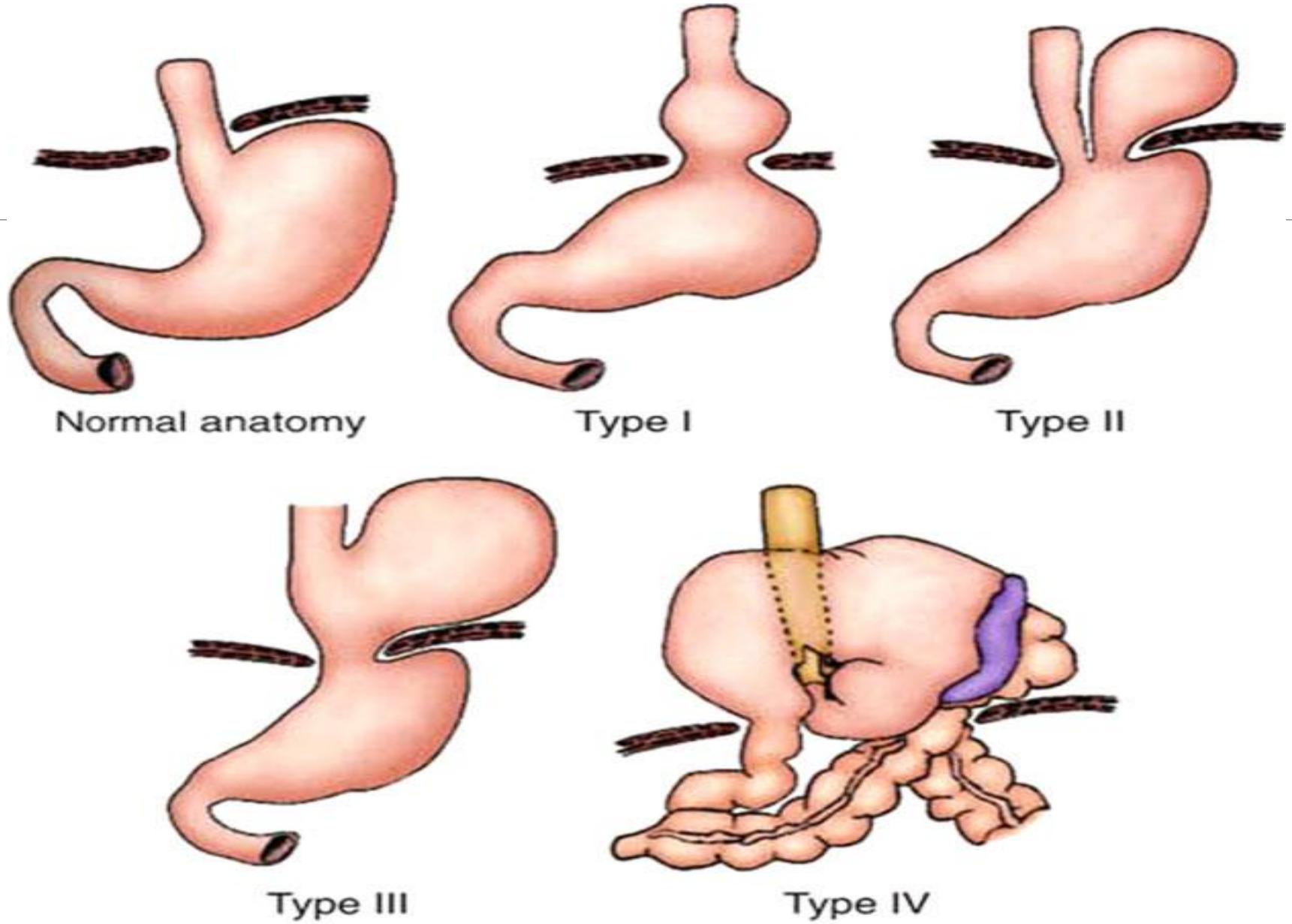
Normal anatomy
Type I
Type II
Type III
Type IV

Goals of Repair

1. Reduce hernia contents into abdomen
2. Complete excision of the hernia sac
3. Obtain intraabdominal length of 3-4cm
4. Repair the hiatal defect
5. Prevent reherniation and reflux

SAGES Guidelines 2013

Guideline 2: Repair of a type I hernia in the absence of reflux disease is not necessary

Guideline 3: All symptomatic paraesophageal hiatal hernias should be repaired particularly those with acute obstructive symptoms or which have undergone volvulus.

Guideline 4: Routine elective repair of completely asymptomatic paraesophageal hernias may not always be indicated. Consideration for surgery should include the patient's age and comorbidities.

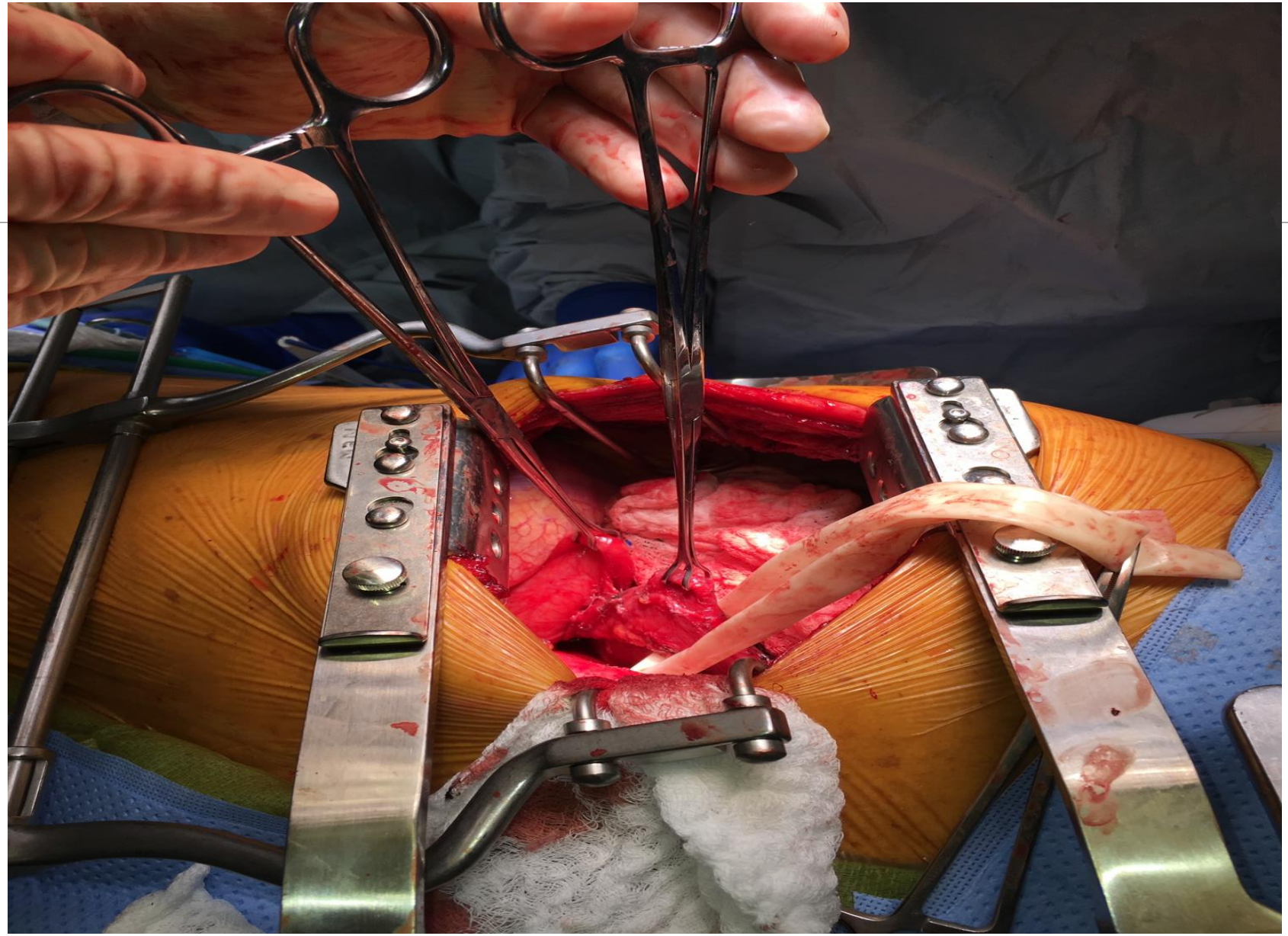

Esophageal Cancer

17650 new cases annually (13750 in men)

7th most common cause of cancer death in men

5 year survival 18%

Until 1970s, squamous cell most common: smoking, alcohol, etc.

Since 1970s, adenocarcinoma most common: obesity, GERD

s/s:

- Dysphagia
- Wt. loss
- UGI bleed
- Pain
- Cough
- Hoarseness
- Often PE is unremarkable unless advanced

Workup

Esophagram??

EGD: gold standard

EUS: for staging

PET/CT

Bronchoscopy

Management:

Stage I-III: Endoscopic versus surgical with neoadjuvant CRT

Indications for surgery:

- HGD with Barrett's that cannot be treated endoscopically
- Any patient who is capable of undergoing resection (stage and functional status)

Contraindications:

- N2 nodes (non regional); celiac, supraclavicular, etc.
- Invasion of airway or vascular structures
- Severe comorbidies
- Distant disease

Staging

T1a: Lamina propria or muscularis mucosae

T1b: Submucosa

T2: Muscularis propria

T3: Adventitia

T4a: Pleura, pericardium, azygos, diaphragm, or peritoneum

T4b: aorta, vertebral body, airway

NCCN Principles of Surgery

Resectable:

- T1a: EMG +/- ablation
- T1b may be treated with esophagectomy
- T1-T3 resectable even with regional nodal metastasis, although bulky multistation involvement is a relative contraindication and should be considered in conjunction with age and performance status
- T4a with pericardium, pleura, or diaphragm involvement are resectable

The type of esophageal resection is dictated by the tumor location, available conduit, and patient and surgeon preference

Acceptable approaches:

- Ivor Lewis (laparotomy/R thoracotomy)
- McKeown (R thoracotomy/laparotomy + cervical anastomosis)
- Minimally invasive Ivor Lewis (laparoscopy + limited R thoracotomy)
- Minimally invasive McKeown (R VATS + limited laparotomy/laparoscopy +cervical anastomosis)
- Transhiatal (laparotomy plus cervical anastomosis)
- Robotic minimally invasive
- Left transthoracic or thoracoabdominal with anastomosis in neck or chest

Acceptable conduits:

- Gastric preferred
- Colon
- Jejunum

Acceptable lymph node dissections:

- Standard
- En-bloc

Without chemoradiation; at least 15 nodes should be removed for adequate nodal staging; optimal after neoadjuvant is unknown although similar nodal numbers are recommended

Transthoracic; Ivor-Lewis and McKeown

Advantages:

- Open surgery
- Good lymph node dissection

Disadvantages

- Morbid (thoracotomy)
- Chest anastomosis (up to debate)
- Not good for upper esophageal cancers (Ivor Lewis)

Transhiatal

Advantages:

- Less morbid
- Good for tumor at any level
- Early survival advantage

Disadvantages:

- Lower lymph node retrieval (maybe)

Minimally invasive approaches

Advantages:

- Decreased morbidity and shorter recovery times

Disadvantages:

- Long operative time; steep learning curve
- No good for large tumors, previous abd surgery, difficulty lymph node dissection, unusable gastric conduit

Anastomosis Location

Neck:

- More extensive resection
- Avoiding thoracotomy possibly
- Less severe reflux
- Less severe sequelae of anastomotic leak

Chest:

- Lower leak rate
- Lower stricture rate
- Lower recurrent nerve injury

https://youtu.be/K2UcLwOtcBc

Esophageal Emergencies

Perforation

Foreign Body

PEH volvulus

Esophageal Perforation

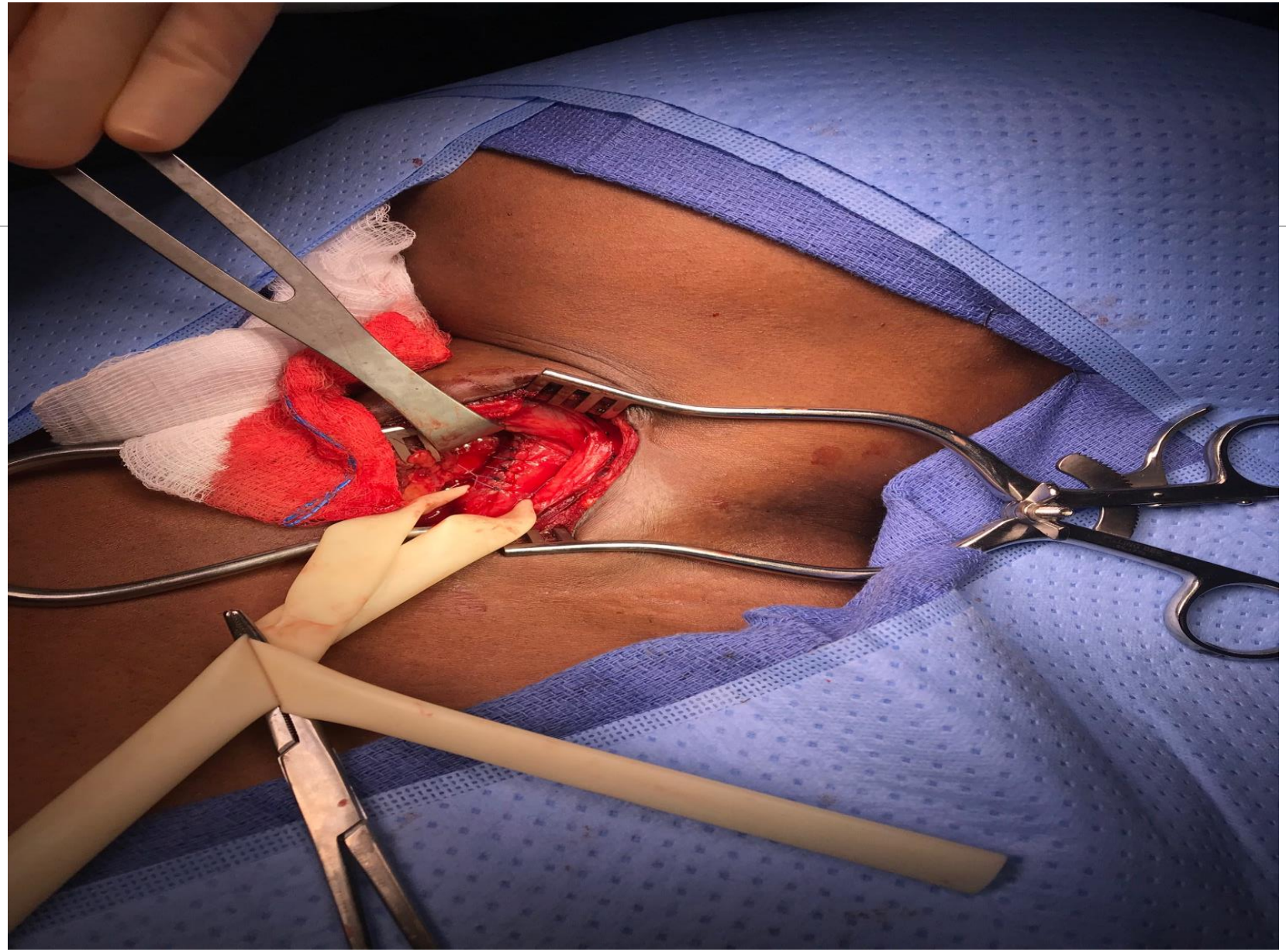

Esophageal Foreign Body

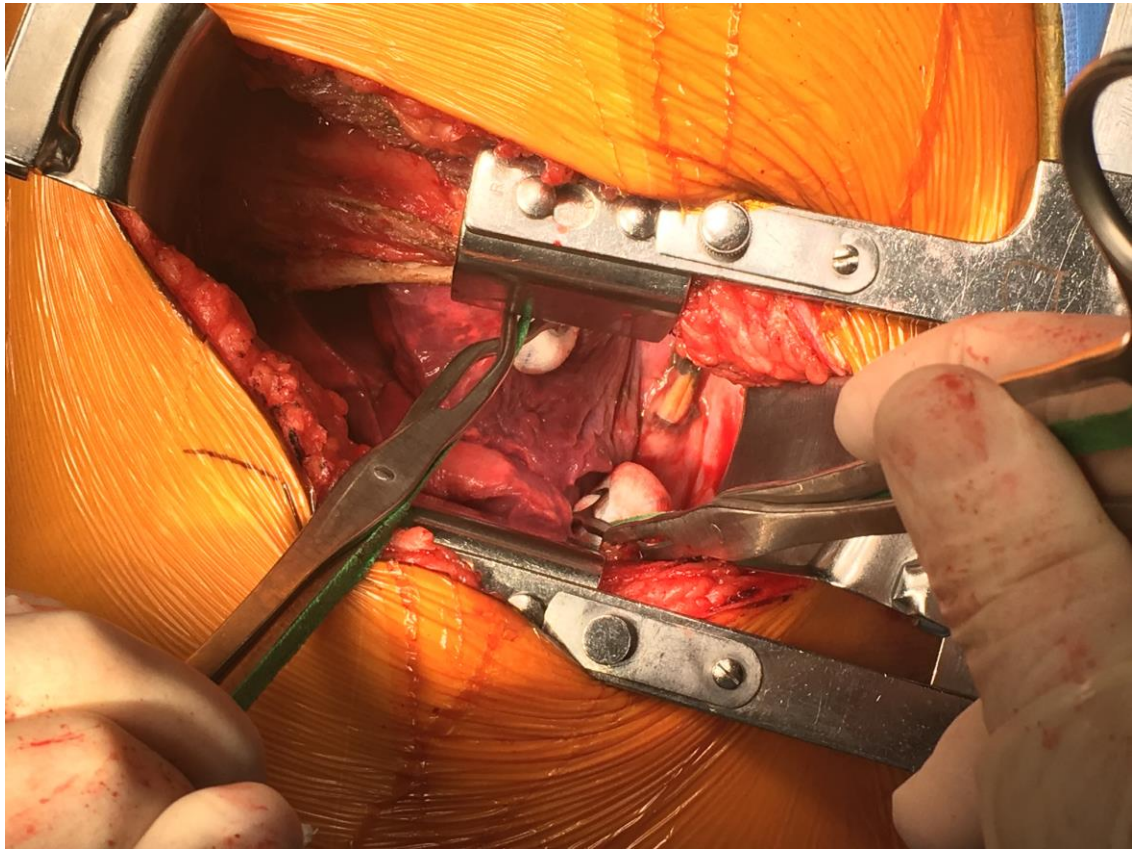

Aspen
Surgical
1-888-364-7004
CM
INCHES

Gastric volvulus

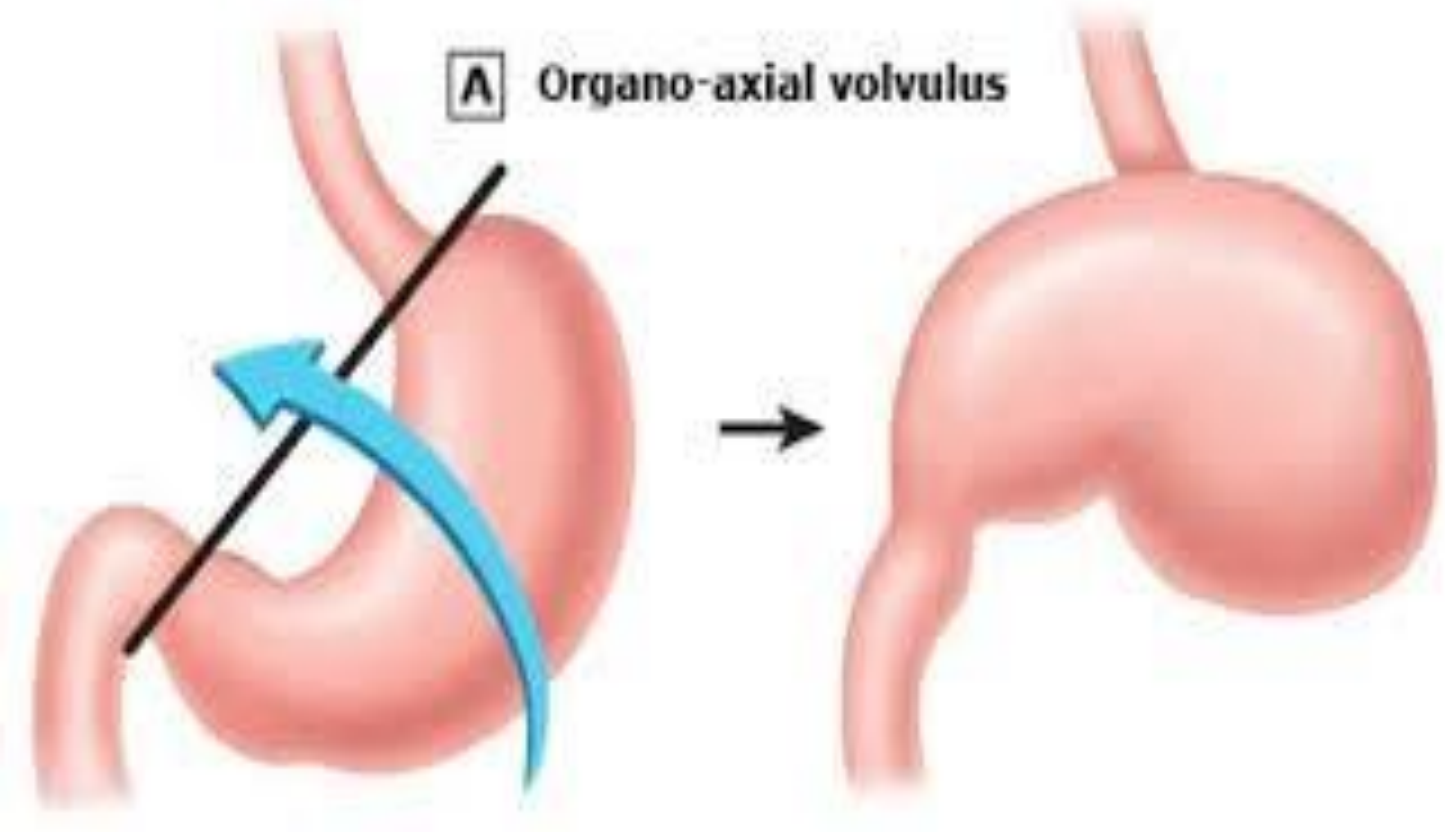
A
Organo-axial volvulus

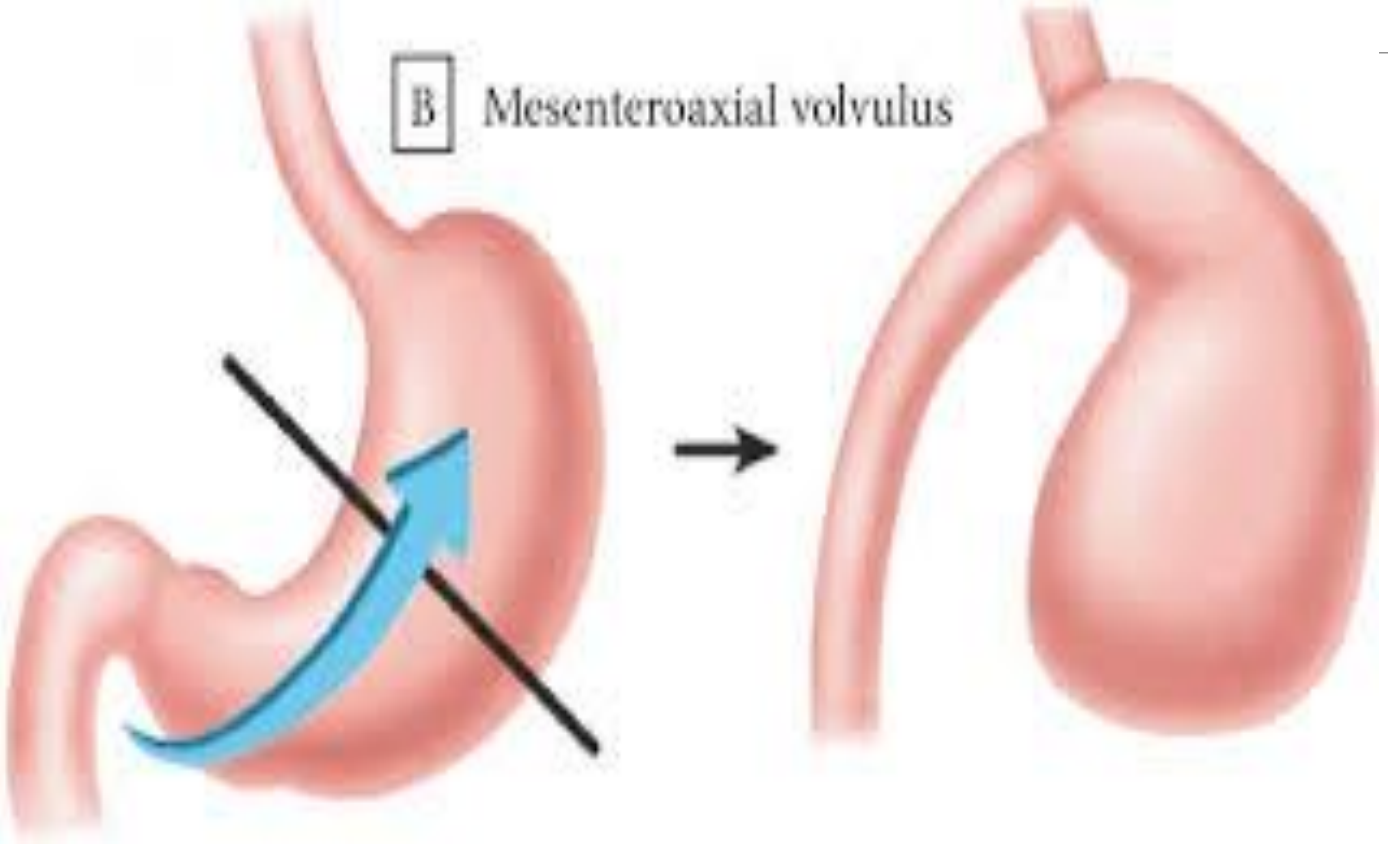
B
Mesenteroaxial volvulus

Causes a closed loop obstruction

Could be a chronic component

Still a surgical entity

Endoscopic decompression could be attempted but ultimately surgery is necessary to prevent recurrence

Appropriate resuscitation is required before surgery

Often these patients are elderly, debilitated, and comorbid

Principles of repair

- Decompression
- Reduction
- +/- Resection
- Prevention of recurrence
  - Repair defect
  - Gastrostomy tube
  - Possible fundoplication

Questions

References

NCCN Clinical Practice Guideline. Esophageal and Esophagogastric junction cancers. Version 2.2019.

Cooke, David T. Belsey Mark IV Repair. Operative Tech in Thorac and Cardiovascular Surgery . 215-230.

Google images

Medscape Diseases and Conditions

National comprehensive cancer network. Esophageal and esophagogastric junction cancers Version 2.2018-May 22, 2018. https://www.nccn.org/professionals/physician_gls/default.aspx#esophageal.

Predina JD, Singhal S. Diaphragmatic Disorders. In: Yuh DD, Vricella LA, Yang SC, Doty JR. eds. *Johns Hopkins Textbook of Cardiothoracic Surgery, Second Edition.* New York, NY: McGraw-Hill; 2014.http://accesssurgery.mhmedical.com/content.aspx?bookid=963&Sectionid=55169342. Accessed January 06, 2015.

Kernstine K.H., Limmer K.K. (2009). Chapter 130. Techniques for Repair of Paraesophageal Hiatal Hernia. In Sugarbaker D.J., Bueno R, Krasna M.J., Mentzer S.J., Zellos L (Eds), *Adult Chest Surgery.* Retrieved January 06, 2015 from http://accesssurgery.mhmedical.com/content.aspx?bookid=427&Sectionid=40372782