

AN INFLAMMATORY ODONTOGENIC CYST PRESENTING WITH A DIAGNOSTIC CHALLENGE

Avisham Ramphul¹, Yong Kho², Patrick Mehanna³, Mark Formby⁴

1.Oral and Maxillofacial Surgery, John Hunter Hospital, Newcastle, NSW , Australia

2.Oral and Maxillofacial Surgery, John Hunter Hospital, Newcastle, NSW , Australia

3.Oral and Maxillofacial Surgery, John Hunter Hospital, Newcastle, NSW , Australia

4.Anatomical Pathology, John Hunter Hospital, Newcastle, NSW Australia

ABSTRACT:

There are histological similarities between radicular and glandular odontogenic cysts. Their management, on the other hand, differ considerably. Atypical presentations of radicular cysts can complicate the diagnostic process by mimicking glandular odontogenic cysts. This case highlights the diagnostic challenges encountered to differentiate between the two and the implications for treatment.

Key Words: Radicular cyst , glandular odontogenic cyst

INTRODUCTION:

Radicular cysts are the most common cysts of the maxillofacial region. There are similarities in histological features between radicular cysts and glandular odontogenic cysts. It is critically important to get the right diagnosis as glandular odontogenic cysts are aggressive lesions and require more radical treatment as compared to radicular cysts.

We present an atypical presentation of a radicular cyst that was initially thought to be glandular odontogenic cyst.

CASE DETAIL:

A 45-year-old male was referred to the Oral and Maxillofacial department for an incidental finding of a large mandibular cyst on OPG.

A large lobulated lucent lesion extending from the first lower right first molar (46) to the first lower left molar (36). It measured 80 x 25 mm in diameter and was well circumscribed from adjacent bone. It appeared unilocular and involved the apices of the lower incisors and the 46. There was no evidence of displacement of teeth. Radiological findings suggested the possibility of a simple bone cyst. (Figure 1)

Clinically there was no significant bony expansion or swelling and no abnormal mobility of teeth. The lesion was asymptomatic. The lower right first incisor was slightly discoloured and cold sensibility testing with Ethyl Chloride was inconclusive. The patient vaguely remembers a history of trauma to this tooth.

The differential diagnosis was that of a keratocyst or a dentigerous cyst.

An incisional punch biopsy was done under local anesthetic via a vestibular incision in the 42-32 area. A bony window was made apical to the apices of the roots and 5 mm punch biopsy of the cyst lining was taken. There was a yellow cystic fluid discharge.

The tissue sample was analyzed by an Anatomical Pathologist and demonstrated a cyst wall with underlying fibrous stroma. The cyst wall was lined by non-keratinizing stratified squamous epithelium with focal mucinous and goblet cell metaplasia. There was focal pseudo-epitheliomatous hyperplasia and the epithelium showed focally heavy infiltration by mixed inflammatory cells with occasional micro abscess formation. A marked mixed plasma cell rich inflammatory infiltrate was present in the underlying stroma. No Rushton bodies were identified and there was no evidence of dysplasia or invasive malignancy. (Figure 2)

The diagnosis was non conclusive. Elements of non-keratinizing squamous epithelium are consistent with both keratocyst and radicular cyst. Radicular cysts are however not usually as large as the one presented in this case. There were also elements of columnar ciliated epithelium, with goblet cells, consistent with Glandular Odontogenic Cyst. The pathologist favored a diagnosis of Glandular Odontogenic cyst given the size of the lesion and the presence of the ciliated epithelium (mucous) cells.

Given the uncertainty surrounding the diagnosis and the possible need for resection of part the mandible if the lesion is a Glandular odontogenic cyst, the decision was made to present this case to the Head and Neck Multi Disciplinary Team meeting. It was eventually decided to seek a second opinion, this time from an Oral and Maxillofacial Pathologist. The Oral and Maxillofacial Pathologist favored a diagnosis of inflamed odontogenic cyst such as keratocyst or a residual radical cyst. He did not think that there were enough diagnostic features of a glandular odontogenic cyst.

The lesion was enucleated under general anesthesia and an iliac crest bone graft was placed in. The final biopsy report after enucleation confirmed a diagnosis of radicular cyst.

The cyst was largely lined by stratified squamous non- keratinizing epithelium with variable thickness. It was inflamed with a moderate chronic inflammatory infiltrate rich in plasma cells with scattered pigment containing macrophages and aggregates of cholesterol granuloma. Neutrophils were also present focally.

DISCUSSION:

The size of the lesion as well as the presence of goblet cells suggested a diagnosis of Glandular Odontogenic cyst. A keratocyst was another possibility. Both of these lesions require aggressive management as compared to a radicular cyst.

A Glandular odontogenic cyst is a relatively rare lesion. It can pose a challenge both in terms of diagnosis and treatment. It is critically important to have a correct diagnosis, as Glandular odontogenic cyst is potentially aggressive. They have a high rate of recurrence, especially when treated conservatively and have a high incidence of cortical perforation.⁽¹⁾

According to Kaplan et al, large glandular cysts should be managed by enucleation with peripheral ostectomy for unilocular cases and marginal or partial jaw resection in multilocular cases. Follow up should be at least 3 years for up to 7 years.⁽²⁾

A set of major and minor histopathological diagnostic criteria has been established for the diagnostic of GOC. A diagnosis of GOC can be made if there is at least focal presence of each one of the major criteria. The minor criteria are only used to support the diagnosis.⁽²⁾

Major criteria

- Squamous epithelial lining, with a flat interface with the connective tissue wall, lacking basal palisading
- Epithelium exhibiting variations in thickness along the cystic lining with or without epithelial “spheres” or “whorls” or focal luminal proliferation
- Mucous (goblet) cells with intraepithelial mucous pools with

or without crypts lined by mucous producing cells

- Intraepithelial glandular, microcystic or duct like structures

Minor criteria

- Papillary proliferation of the lining epithelium
- Ciliated cells
- Multicystic or multi luminal architecture
- Clear or vacuolated cells in the basal or spinous layers

The development of these criteria facilitates the diagnostic process. However, as pointed out by Kaplan et al, a large enough and representative sample need to be collected given the focal presence of some elements.⁽²⁾ Our incisional biopsy sample was most probably too small, hence not giving the pathologist a representative sample to reach to the most accurate of diagnosis. The most important differential diagnosis for a GOC is low-grade mucoepidermoid carcinoma (MEPCa)⁽²⁾ Immunohistochemistry can be used to differentiate between GOC, MEPCa and radicular cyst. Both GOC and MEPCa show significantly higher labelling indices for p53 as compared to radicular cysts.⁽²⁾

Radicular cysts are the most common cysts of the maxillofacial area. They are classified as odontogenic inflammatory cysts.⁽³⁾

Santos et al have identified the following common features in a review of 73 biopsies of radicular cysts: exocytosis, acanthosis, atrophic epithelium and apoptotic bodies. Less common findings included foamy macrophages, Russel bodies, cholesterol crystals and glandular like odontogenic epithelial rests.⁽⁴⁾

Mucous cells have also been described in radicular cysts. Takeda et al have described mucous metaplasia of epithelia lining in radicular, dentigerous and primordial cysts with an incidence of 20.8% and ciliated cells in 11.4%.⁽⁵⁾ Other authors have also attributed the presence of mucous cells in odontogenic cysts to the process of metaplasia.⁽⁶⁾

The average size of radicular cysts is 19.4 mm.⁽⁴⁾ The lesion in the case we present was 80 mm in length. Santos et al examined a series of 73 radicular cysts and the largest cyst measured 7.6 cm.⁽⁴⁾

CONCLUSION:

This case highlights the fact that radicular cyst can present in large sizes and can have atypical features such a mucous epithelium cells. The large size and atypical histological features mimic more aggressive lesions. Due to varying treatment modalities among jaw cysts, varying from conservative management to jaw resection, it is critical to have a confirmed diagnosis before initiating treatment. A large enough and representative biopsy

sample is required to assist the pathologist in the diagnostic process. This case also highlights the benefits multidisciplinary teams with collaborative effort from both surgical team and Anatomical and Oral and Maxillofacial Pathologist in the diagnosis of head and neck lesions.

REFERENCES:

1. Mohs RC, Doody RS, Morris JC, Ieni JR, Rogers SL, Perdomo CA, et al. A 1-year, placebo-controlled preservation of function survival study of donepezil in AD patients. *Neurology*. 2001;57(3):481-8.
2. Kaplan I, Gal G, Anavi Y, Manor R, Calderon S. Glandular odontogenic cyst: treatment and recurrence. *Journal of oral and maxillofacial surgery : official journal of the American Association of Oral and Maxillofacial Surgeons*. 2005;63(4):435-41.
3. Shear M SP. *Radicular cyst and residual cyst*. 4th ed. Munksgaard OB, editor 2007.
4. Santos LCS, Vilas Bôas DS, Oliveira GQV, Ramos EAG, Gurgel CAS, Santos JND. Histopathological study of radicular cysts diagnosed in a Brazilian population. *Brazilian Dental Journal*. 2011;22(6):449-54.
5. Takeda Y, Oikawa Y, Furuya I, Satoh M, Yamamoto H. Mucous and ciliated cell metaplasia in epithelial linings of odontogenic inflammatory and developmental cysts. *Journal of Oral Science*. 2005;47(2):77-81.
6. Nair PN, Pajarola G, Luder HU. Ciliated epithelium-lined radicular cysts. *Oral Surg Oral Med Oral Pathol Oral Radiol Endod*. 2002;94(4):485-93.

FIGURES:

Figure 1:

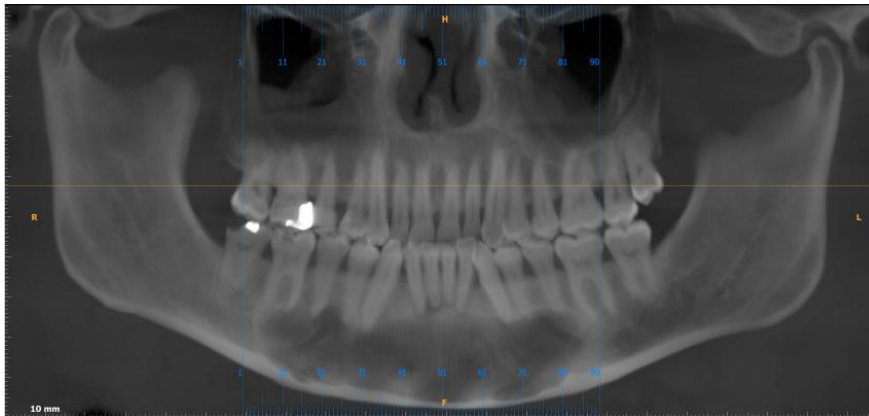


Figure 2:

