

Bilateral Operation of Lumbar Degenerative Central Spinal Stenosis in Full-endoscopic Interlaminar Technique With Unilateral Approach

Prospective 2-year Results of 74 Patients

Martin Komp, MD,* Patrick Hahn, MD,* Harry Merk, MD,† Georgios Godolias, MD,‡ and Sebastian Ruetten, MD*

Study Design: Prospective study of the patients with degenerative spinal central stenosis, operated bilateral in a full-endoscopic unilateral technique.

Objective: The objective of this prospective study was to examine the technical possibilities of full-endoscopic interlaminar bilateral technique with unilateral approach in degenerative lumbar central spinal stenosis and predominant leg symptoms using new designed endoscopes and instruments.

Summary of Background Data: Extensive decompression with laminectomy where appropriate, is often still described as the method of choice in the operation of degenerative lumbar spinal stenosis. Nonetheless, tissue-sparing procedures are becoming more common. Endoscopic techniques have become the standard in many areas because of the advantages they offer in surgical technique and in rehabilitation. At the spine, 1 essential point was the developing of the instruments for sufficient bone resection under continuous visual control. This enabled the use in the operation of spinal canal stenoses.

Methods: A total of 72 patients with lumbar central spinal stenosis full-endoscopic unilateral decompression were followed for 2 years. In addition to general and specific parameters, these measuring instruments were used: VAS, German version North American Spine Society Instrument, Oswestry Low-back Pain Disability Questionnaire.

Results: The results show that 70.8% no longer have leg pain or it was nearly completely reduced and 22.2% have occasional pain. The decompression results were equal to those of

conventional procedures. The complication rate was low. The full-endoscopic techniques brought advantages in these areas: operation, complications, traumatization, and rehabilitation.

Conclusions: The recorded results show that the full-endoscopic interlaminar bilateral decompression with unilateral approach is a sufficient and safe supplement and alternative to conventional procedures when the indication criteria are fulfilled. At the same time, it offers the advantages of a minimally invasive intervention.

Key Words: spinal stenosis, central stenosis, neurogenic claudication, spinal decompression, endoscopic spinal decompression, minimally invasive spine surgery

(*J Spinal Disord Tech* 2011;24:281–287)

Degenerative lumbar stenosis is owing to bony, discal, capsular, or ligamentary structures. The compression may lead to the classical, clinical symptoms of neurogenic claudication with radicular signs. Back pains are more likely attributable to the degenerative secondary phenomena, such as segment instabilities or deformities. There are various hypotheses to explain the onset of pain associated with spinal stenosis and they include mechanical neural and vascular, inflammatory, and biomechanical components.^{1–4} There is no unequivocal correlation between the extent of stenosis observed in imaging procedures and the clinical symptoms.^{1,5}

Therapeutically, the surgical intervention can be considered in the cases of decompensation or intolerable persistence. In this respect, decompression, fusion, or combination of the 2 procedures are to be considered owing to the possible leg and back symptoms. Numerous surgical procedures have been described, some of which are still a matter of controversial discussion.^{1,6–15} Overall, there seems to be a trend over the past years away from more aggressive to more selective techniques. The tendency at present in predominant leg symptoms, without signs of segment instability and deformity and the use of stability-preserving decompression techniques is to dispense with fusion. But there are no clear-cut

Received for publication July 17, 2010; accepted August 28, 2010.

From the *Department of Spine Surgery and Pain Therapy, Center for Orthopaedics and Traumatology, St. Anna-Hospital Herne, University of Witten/Herdecke, Herne; †Clinic for Orthopaedics and Orthopaedic Surgery, Ernst Moritz Arndt University Greifswald, Greifswald, Germany; and ‡Center for Orthopaedics and Traumatology, St. Anna-Hospital Herne, University of Witten/Herdecke, Herne.

Sources of Support: No.

Reprints: Martin Komp, MD, Vice-Head Department of Spine Surgery and Pain Therapy, Center for Orthopaedics and Traumatology, St. Anna-Hospital Herne, Hospitalstrasse 19, 44649 Herne, Germany (e-mail: komp@annahospital.de).

Copyright © 2011 by Lippincott Williams & Wilkins

definitions of these criteria. These days it seems, according to EBM-criteria, that decompression can improve neurogenic claudication and neurologic deficits. The required extent of decompression and the circumstances in which additional fusion is necessary remain unclear.

One operative consequence of surgery is scarring of the epidural space,^{16–19} which may become clinically symptomatic in 10% or more of cases^{17–19} and makes revision surgery more difficult. An analysis of study results in decompression showed the occurrence of operation-induced destabilization owing to the necessary resection of spinal canal structures.^{20–26} The point of access influences the stabilization and coordination system in the innervation area of the dorsal nerve roots of the spinal nerves.^{27–29} The use of microsurgical techniques has reduced tissue damage and its consequences.^{30–32}

The goal of new procedures must be to achieve results and commensurate with current results of standard techniques while minimizing traumatization and its negative long-term consequences. A focal point of technical developments in spinal surgery has been and remains optimization of the intraoperative vision and light conditions. Referring to this, endoscopic operations have become standard in various areas, such as arthroscopy or laparoscopy. These days, herniated discs and stenoses of the lumbar and cervical spine can also be operated full-endoscopically using various accesses and techniques.^{33–39}

The goal of this prospective study was to examine the technical possibilities of full-endoscopic bilateral interlaminar decompression with unilateral approach in the treatment of degenerative lumbar central spinal stenosis using new designed endoscopes and instruments. The focus was on the question of sufficient decompression, possible effects of reduced traumatization, possible specific complications, and the technical performance of the access depending on the pathologic and anatomic correlates.

PATIENTS OR MATERIALS AND METHODS

Patients Characteristics and Study Group

Ninety patients (49 f, 41 m) who were operated in 2005/2006 in full-endoscopic bilateral interlaminar technique with unilateral approach for degenerative lumbar central spinal stenosis were included in the prospective study. The age ranged from 43 to 81 years (mean 61 y). The duration of symptoms ranged from 5 months to more than 5 years (mean 15). All the patients had received a mean of 13 months conservative treatment. The walking time possible averaged less than 20 minutes. Five operations were done at the L5-S1 level, 48 at L4 to 5, 31 at L3 to 4, and 6 at L2 to 3. The indication for surgery was defined according to present-day standards based on radicular pain symptoms or neurogenic claudication and existing neurologic deficits.^{40,41} All the operations were carried out by 2 surgeons, who have many years of experience in both the techniques.

Inclusion Criteria

These inclusion criteria applied: predominant leg symptomatic; neurogenic claudication with or without paresis; back pain max. 20/100 on the VAS; conservative therapy exhausted or no longer indicated owing to the symptoms; monosegmental central stenosis. Exclusion criteria were: predominant back pain; foraminal stenosis in the lower level; disc herniation; degenerative spondylolisthesis more than Meyerding Grade I; multidirectional rotation slide; Scoliosis more than 20 degrees; prior surgery in the same segment; cauda equina syndrome. In summary, an attempt was made to define inclusion criteria that do not represent a clear indication for additional fusion, also taking clinical symptoms into account.

Full-endoscopic Instruments

The working sheaths, which are inserted bluntly using a dilator, have an outer diameter of 10 mm and a beveled opening, which enable creation of visual and working fields in an area without clear anatomically preformed cavity. The optic has an outer diameter of 9.5 mm and is inserted through the working sheath. The optic contains an intraendoscopic, excentric working canal with a diameter of 5.7 mm, the light conductor system, a canal for continuous irrigation and the rod lens system. The angle of vision is 20 degrees. Various instruments including drills up to 5.5 mm in diameter can be used (Fig. 1). All of the operating instruments and optics were products supplied by WOLF (Richard Wolf GmbH, Knittlingen, Germany).

Operative Technique

The full-endoscopic interlaminar operation was carried out bilateral through a unilateral access in the sense of an “undercutting technique.” After making a ca. 9-mm long paramedian skin incision, blunt insertion of a dilator toward the interlaminar window. Insertion of



FIGURE 1. Optic for the full-endoscopic interlaminar decompression with dilator and working sheath, and optic with inserted drill.

the operation sheath through the dilatator with the beveled opening toward medial in the direction of the ligamentum flavum. Thereafter, the procedure is carried out under visual control and constant irrigation. Depending on the pathology, first performance of ipsilateral decompression by means of cranial and caudal laminotomy, partial facetectomy, and flavum resection. Then entry to the contralateral side dorsal to the Dura. The ligamentum flavum is initially left in as far as possible as protection for the Dura and bony decompression is carried out again by means of cranial and caudal laminotomy and partial facetectomy. Subsequently, the ligamentum flavum is completely resected. The decompression is concluded when the Dura and spinal nerves are visibly clearly decompressed on both sides (Fig. 2).

The operation was carried out under general anesthesia and radiographic control with the patient supine. No drainage is required. There was no opening of the anulus for performance of intradiscal nucleotomy. All the patients are given a lumbar brace for 8 weeks.

Follow-up

Follow-up examinations were conducted at Day 1 (90 patients) and at months 3 (86 patients), 6 (83 patients), 12 (81 patients), and 24 (74 patients) after surgery. All patients received the appropriate questionnaire by mail 4 working days in advance. They came personally to the clinic for follow-up examination. The examinations were done by 2 doctors in the clinic, who were not involved in the operations. In addition to general parameters, other information was obtained using these instruments: a VAS for back and leg pain, the German version of the North American Spine Society Instrument (NASS),^{42,43} and the Oswestry Low-Back Pain Disability Questionnaire (ODI).⁴⁴ All the patients underwent functional x-rays after the end of the follow-up period.

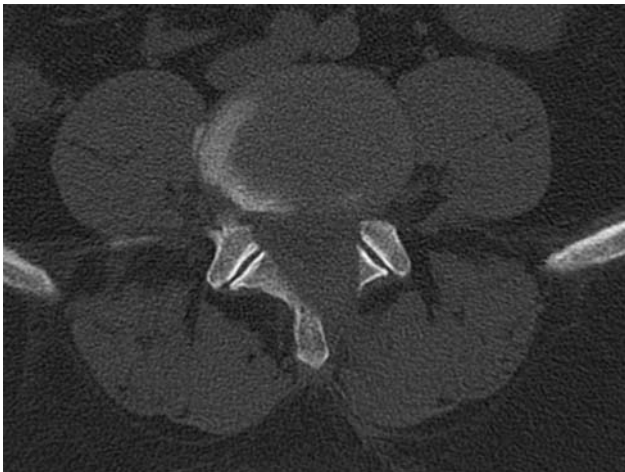

FIGURE 2. Postoperative CT-scan after full-endoscopic bilateral decompression.

Statistical Analysis

The Wilcoxon rank-sum test and the Mann-Whitney *U* test were applied for the comparison of preoperative and postoperative global results and comparison of results in the MI versus the FI group at various times. The McNemar Test was used to compare the characteristics of the groups.

The descriptive assessments and analytical statistics were carried out depending on the group characteristics with the program package SPSS. A positive significance level was assumed at probability of less than 0.05.

RESULTS

Baseline Characteristics

A total of 74 (82.2%) patients were included in follow-up after 2 years. The remaining cases were lost for these reasons: 1 operation-unrelated deaths (14 months postoperative), 2 patients moved away and left no forwarding address, 13 patients did not respond to letters or telephone calls. Overall, there were no differences in results in dependence on the individual surgeons.

Operative Technique

The mean operating time was 44 minutes (35 to 61). There was no measurable blood loss. There was no hindrance owing to intraoperative bleeding thanks to continuous lavage and the possibility of radiofrequent, bipolar preparation, and coagulation. No drainage was required. Measurement of the lavage fluid inflow and outflow showed maximal 15 ml remaining intracorporal. The operation was technically feasible in all patients. An intraoperative switch to a conventional procedure was not made in any case. The patients were mobilized directly postoperative, depending on the effects of anesthesia.

Perioperative Complications and Revisions

These complications occurred: 5 times transient postoperative dysesthesia; 2 times transient urinary retention; 2 times Dura injuries; 1 time increase in preoperatively-existing foot dorsiflexion paresis. There were no other complications such as hematoma, delayed wound healing, soft-tissue infection, spondylodiscitis, Cauda-equina syndrome, or thrombosis. Apart from transient dysesthesia and transient urinary retention, the complication rate was 3.3%.

Two patients (2.7%) required revision surgery with additional fusion owing to persistent leg pain and/or progradient back pain. All revision operations were carried out during the follow-up observation period, the earliest after 7 months.

Radiologic Findings

All patients were examined at the end of the follow-up period using functional x-rays (72 patients without fusion). Nine patients (12.5%) showed progradient disc degeneration in the operated level that had existed preoperative. Three patients (4.2%) presented with an increase in the kyphosis angle in the operated segment.

The height of the intervertebral space decreased in 8 patients (11.1%). There was 1 case of increased spondylolisthesis from grade I to grade II after surgery. Apart from these patients, there was no increased instability in the functional examinations. There was no significant dependence between kyphosis, height of intervertebral space, radiologic instability, and the clinical outcome.

Clinical Outcome

Excluding the patients revised by fusion, 72 patients remained after 2 years. Figure 3 shows the course of leg and back pain, rated using the VAS scale. There is a significant reduction of radicular pain symptoms. A similar result was obtained in evaluating the ODI score (Fig. 3). Figure 4 shows the values of the NASS score, which also illustrates equal pain reduction. Overall, the measuring instruments show constant and significant ($P < 0.001$) improvement in leg pain and daily activities. Figure 5 shows the complete depiction of the leg pain status after 2 years. Fifty-one patients (70.8%) no longer had leg pain or it was nearly complete reduced, 16 (22.2%) had pain occasionally or the pain was greatly reduced and 5 (6.9%) experienced no essential improvement. Walking time proved from on average less than 15 minutes to more than 45 minutes. In general, there was slight deterioration in the follow-up period between the first and second years, but it was not significant. One patient suffered progradient back pain.

Overall, 2 patients (2.7%) underwent revision with decompression and additional fusion. Overall, 7 patients (9.5%) had a poor result in terms of no leg pain reduction or had to undergo conventional revision surgery later for persistent pain. Sixty-four patients (86.5%) reported subjective satisfaction and would undergo the operation again. Neurologic deficits were significantly ($P < 0.001$) reduced when the patient's history of weakness was less than 8 weeks. Overall, the clinical results were significantly better ($P < 0.01$) if the general anamnesis time was less than 1.3 years.

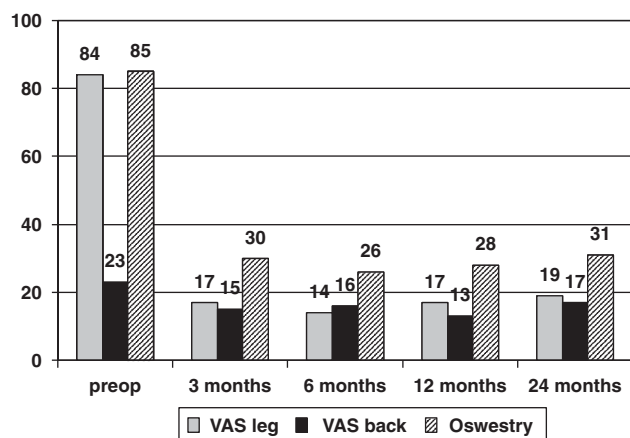


FIGURE 3. Mean values of VAS leg and back and Oswestry Low-back Pain Disability Questionnaire (ODI).

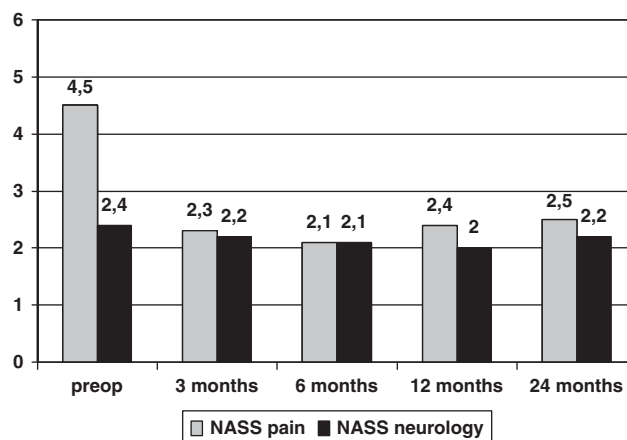


FIGURE 4. Mean values of North American Spine Society Instrument (NASS) pain and neurology.

No operation-related pain medication was required. Mobilization was made immediately depending on the narcosis. Rehabilitative measures were not necessary except in existing pareses. All results were independent of general parameters, such as sex, age, height, weight, occupation, or secondary illnesses. The maximum time in hospital was 8 days in the MI group and 3 days in the FI group.

DISCUSSION

Conventional decompression of degenerative lumbar stenosis with laminectomy or extensive resection has been and is still frequently described as the technique of choice.^{6,7,11,14,45} Scarring of the epidural space can be problematical,^{16–19,28,46} which may become clinically symptomatic,^{17–19} make revisions more difficult, and may lead to “tethering” of the Cauda equina owing to the postoperative connection between the epidural space and paravertebral musculature.^{14,47–49} The resection of stability-preserving structures may promote operation-induced segmental instability.^{20–26} The route of access in the innervation area of the dorsal branch of the spinal

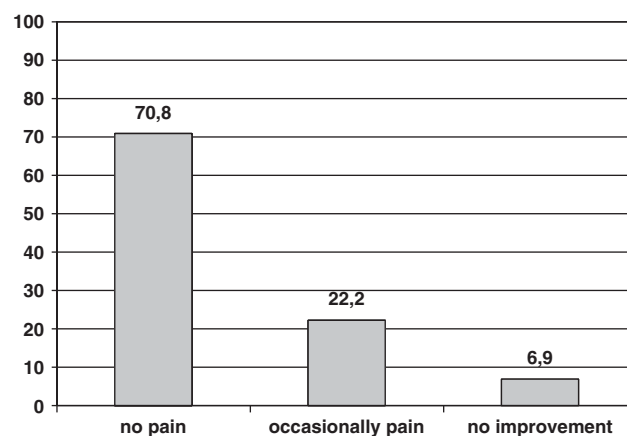


FIGURE 5. Clinical results in percent after 2 years.

nerves may have a negative influence on the stabilization and coordination system.^{27–29} Resection of joint and soft tissue structures in the lateral and ventral area is also especially often required for decompression of degenerative stenosis. This is possible with more tissue-sparing techniques that are finding increasing use^{8,12,14,15,50–53} and are also used in other indications.

Technical advances have been made in the operation of disc herniations in the cervical and lumbar spine which these days enable a full-endoscopic procedure under continuous irrigation which can provide the advantages of a truly minimally-invasive procedure.^{33,35–39} One essential point was the possibility of sufficient bone resection under continuous visual control.^{33–38} This also enabled use in the operation of spinal canal stenoses.³⁴

The clinical results of decompressions without fusion described in the literature could be achieved in our study by means of the full-endoscopic technique.^{6–8,12,14,15,45,48,50–56} This has been taken as the minimum prerequisite for new techniques. A significant improvement was achieved after 2 years without significant differences. A slow deterioration in surgical results over time has been described.^{55,57–60} When resection of spinal canal structures is avoided or the extent reduced, a minimally traumatic procedure seems capable of reducing operation-induced consequences.^{19,25,45,61–66} The results of these parameters in a literature comparison also favor the full-endoscopic technique.^{67–71} The rate of complications, operating time, and necessity of resection stabilizing structures was reduced.^{6–8,12,14,15,45,48,51–53,55,72,73} The reduction in operation time, traumatization, and operation-related sequelae using a full-endoscopic technique is also found in comparison with the literature in discectomies.^{34–37,69,71,74} The full-endoscopic procedure was technically feasible in all cases in a short operation time. Surgery under continuous fluid flow is known to reduce intraoperative bleeding and enables very good vision in combination with the 25 degrees-optics. No blood loss was observed in the FI-group, no drainage was required.

To date, it remains difficult to define generally applicable, clear parameters according to EBM-criteria that require fusion in addition to decompression. The tendency at present in predominant leg symptoms, without signs of segment instability and deformity, and the use of stability-preserving decompression techniques is to dispense with fusion. In the study conducted, no significant parameter with reference to operation-induced instability had occurred after 2 years. Overall, there was no significant dependence between kyphosis, height of intervertebral space, radiologic instability, and the clinical outcome. In the indication monosegmental central stenosis with predominant leg pain on which this study was based, it seems that additional fusion can be dispensed with a stability-preserving surgical technique as long as there are no clear-cut signs of instability or axis deviations preoperatively.

The goal of surgical treatment of lumbar stenosis is sufficient decompression with minimization of operation-induced traumatization and its consecutive sequelae. This prospective study shows that predictable sufficient

decompression can be achieved by full-endoscopic bilateral interlaminar decompression with unilateral approach under continuous visualization in a short operation time taking the described inclusion criteria into account. The clinical results of the standard procedure are achieved; whereas the advantages of a minimally invasive procedure are given. The instruments enable the technical performance of the operation.

The full-endoscopic bilateral operation with unilateral approach of lumbar degenerative central stenosis is a sufficient and safe supplementation and alternative. This is a minimally invasive surgical technique for spinal decompression, which has long been a validated and established standard procedure. In our opinion, these advantages are offered: facilitation for the operator owing to excellent visualization, good illumination, and expanded field of vision with 25 degrees optics; cost-effective procedure because of short operating time, rapid rehabilitation, and low-postoperative costs of care; reduced anatomic trauma; monitor image as training basis for assistants. These must be considered disadvantages: limited possibility of extending the approach in the event of unforeseen hindrances; and difficult learning curve.

REFERENCES

- Benini A. Lumbar spinal stenosis. An overview 50 years following initial description. *Orthopaede*. 1993;6:461–472.
- Cinotti G, Postachini F, Fassari F, et al. Predisposing factors in degenerative spondylolisthesis. A radiographic and CT study. *Int Orthopaed*. 1997;21:337–342.
- Rydevik B. Neurophysiology of cauda equina compression. *Acta Orthop Scand*. 1993;64:52–55.
- Takahashi K, Miyazaki T, Takino T, et al. Epidural pressure measurement. Relationship between epidural pressure and posture in patients with lumbar spinal stenosis. *Spine*. 1995;20:650–653.
- Torgerson WR, Dotter WE. Comparative roentgenographic study of the asymptomatic and symptomatic lumbar spine. *J Bone J Surg*. 1976;58:850–853.
- Caputy AJ, Luessenhop AJ. Long-term evaluation of decompressive surgery for degenerative lumbar stenosis. *J Neurosurg*. 1992;7:669–676.
- Fox MW, Onofrio BM, Hanssen AD. Clinical outcomes and radiological instability following decompressive lumbar laminectomy for degenerative spinal stenosis: a comparison of patients undergoing concomitant arthrodesis versus decompression alone. *J Neurosurg*. 1996;85:793–802.
- Getty CJM, Johnson JR, Kirwan E, et al. Partial undercutting facetectomy for bony entrapment of the lumbar nerve root. *J Bone J Surg Br*. 1981;63:330–335.
- Herkowitz HN. Degenerative lumbar spondylolisthesis with spinal stenosis. *J Bone J Surg*. 1991;73:802–808.
- Herno A, Airaksinen O, Saari T. Long-term results of surgical treatment of lumbar stenosis. *Spine*. 1993;17:1471–1474.
- Katz JN, Lipson SJ, Lew RA, et al. Lumbar laminectomy alone or with instrumented or noninstrumented arthrodesis in degenerative lumbar spinal stenosis. *Spine*. 1997;22:1123–1131.
- Mayer HM, List J, Korge A, Wiechert K. Microsurgery of acquired degenerative lumbar spinal stenosis. Bilateral over-the-top decompression through unilateral approach. *Orthopaede*. 2003;32:889–895.
- Quint U, Wilke HJ, Loer F, et al. Functional sequelae of surgical decompression of the lumbar spine—a biomechanical study in vitro. *Z Orthop*. 1998;136:350–357.
- Ragab AA, Fye MA, Bohlmann HH. Surgery of the lumbar spine for spinal stenosis in 118 patients 70 years of age or older. *Spine*. 2003;28:348–353.

15. Sanderson PL, Getty CJM. Long-term results of partial undercutting facetectomy for lumbar lateral recess stenosis. *Spine*. 1996;21:1352–1356.
16. Annerzt M, Jonsson B, Stromqvist B, et al. No relationship between epidural fibrosis and sciatica in the lumbar postdiscectomy syndrome. A study with contrast-enhanced magnetic resonance imaging in symptomatic and asymptomatic patients. *Spine*. 1995;20:449–453.
17. Fritsch EW, Heisel J, Rupp S. The failed back surgery syndrome: reasons, intraoperative findings and long term results: a report of 182 operative treatments. *Spine*. 1996;21:626–633.
18. Kraemer J. *Intervertebral Disk Diseases*. Stuttgart: Thieme; 1990.
19. Schoeggl A, Maier H, Saringer W, et al. Outcome after chronic sciatica as the only reason for lumbar microdiscectomy. *J Spinal Disord Tech*. 2002;15:415–419.
20. Abumi K, Panjabi MM, Kramer KM, et al. Biomechanical evaluation of lumbar spinal stability after graded facetectomies. *Spine*. 1990;15:1142–1147.
21. Maher TR, O'Brien M, Dryer JW, et al. The role of the lumbar facet joints in spinal stability. Identification of alternative paths of loading. *Spine*. 1994;19:2667–2670.
22. Hopp E, Tsou PM. Postdecompression lumbar instability. *Clin Orthop*. 1988;227:143–151.
23. Kaigle AM, Holm SH, Hansson TH. Experimental instability in the lumbar spine. *Spine*. 1995;20:421–430.
24. Kato Y, Panjabi MM, Nibu K. Biomechanical Study of lumbar spinal stability after osteoplastic laminectomy. *J Spinal Disord*. 1998;11:146–150.
25. Kotilainen E, Valtonen S. Clinical instability of the lumbar spine after microdiscectomy. *Acta Neurochir*. 1993;125:120–126.
26. Sharma M, Langrana NA, Rodrigues J. Role of ligaments and facets in lumbar spinal stability. *Spine*. 1995;20:887–900.
27. Cooper R, Mitchell W, Illingworth K, et al. The role of epidural fibrosis and defective fibrinolysis in the persistence of postlaminectomy back pain. *Spine*. 1991;16:1044–1048.
28. Lewis PJ, Weir BKA, Broad RW, et al. Long term prospective study of lumbosacral discectomy. *J Neurosurg*. 1987;67:49–54.
29. Waddell G, Reilly S, Torsney B, et al. Assessment of the outcome of low back surgery. *J Bone Jt Surg Br*. 1988;70:723–727.
30. Parke WW. The significance of venous return in ischemic radiculopathy and myelopathy. *Orthop Clin North Am*. 1991;22:213–220.
31. Schick U, Doehner J, Richter A, et al. Microendoscopic lumbar discectomy versus open surgery: an intraoperative EMG study. *Eur Spine*. 2002;11:20–26.
32. Weber BR, Grob D, Dvorak J, et al. Posterior surgical approach to the lumbar spine and its effect on the multifidus muscle. *Spine*. 1997;22:1765–1772.
33. Ruetten S, Komp M, Merk H, et al. Full-endoscopic anterior operation of cervical disc herniations using a new designed endoscope: prospective 2-year results of 62 patients. *Minim Invas Neurosurg*. 2009. In press.
34. Ruetten S, Komp M, Merk H, et al. Surgical treatment for lumbar lateral recess stenosis with the full-endoscopic interlaminar and transforaminal approach versus conventional microsurgical technique: a prospective, randomized, controlled study. *J Neurosurg Spine*. 2008;10:476–485.
35. Ruetten S, Komp M, Merk H, et al. Recurrent lumbar disc herniation following conventional discectomy: a prospective, randomized study comparing full-endoscopic interlaminar and transforaminal versus microsurgical revision. *J Spinal Disord Tech*. 2009;22:122–129.
36. Ruetten S, Komp M, Merk H, et al. Full-endoscopic cervical posterior foraminotomy for the operation of lateral disc herniations using 5.9-mm endoscopes: a prospective, randomized, controlled study. *Spine*. 2008;33:940–948.
37. Ruetten S, Komp M, Merk H, et al. Full-endoscopic interlaminar and transforaminal lumbar discectomy versus conventional microsurgical technique: a prospective, randomized, controlled study. *Spine*. 2008;33:931–939.
38. Ruetten S, Komp M, Merk H, et al. Use of newly developed instruments and endoscopes: full-endoscopic resection of lumbar disc herniations via the interlaminar and lateral transforaminal approach. *J Neurosurg Spine*. 2007;6:521–530.
39. Ruetten S, Komp M, Godolias G. An extreme lateral access for the surgery of lumbar disc herniations inside the spinal canal using the full-endoscopic uniportal transforaminal approach.—Technique and prospective results of 463 patients. *Spine*. 2005;30:2570–2578.
40. Andersson GBJ, Brown MD, Dvorak J, et al. Consensus summary on the diagnosis and treatment of lumbar disc herniation. *Spine*. 1996;21:75–78.
41. McCulloch JA. Focus issue on lumbar disc herniation: macro- and microdiscectomy. *Spine*. 1996;21:45–56.
42. Daltroy LH, Cats-Baril WL, Katz JN, et al. The North American Spine Society (NASS) Lumbar Spine Outcome Instrument: reliability and validity tests. *Spine*. 1996;21:741–749.
43. Pose B, Sangha O, Peters A, et al. Validation of the North American Spine Society Instrument for assessment of health status in patients with chronic backache. *Z Orthop*. 1999;137:437–441.
44. Fairbank JCT, Couper J, Davies JB, et al. The Oswestry low back pain questionnaire. *Physiotherapy*. 1980;66:271–273.
45. Johnsson KE, Redlund-Johnell I, Uden A, et al. Preoperative and postoperative instability in lumbar spinal stenosis. *Spine*. 1989;14:591–593.
46. Ruetten S, Meyer O, Godolias G. Epiduroscopic diagnosis and treatment of epidural adhesions at chronic back pain syndrome of patients with previous surgical treatment: first results of 26 interventions. *Z Orthop*. 2002;140:171–175.
47. Katz JN, Lipson SJ, Larson MG, et al. The outcome of decompressive laminectomy for degenerative lumbar stenosis. *J Bone J Surg Am*. 1991;73:809–816.
48. LaRocca H, MacNab I. The laminectomy membrane. Studies in its evaluation, characteristics, effects and prophylaxis in dogs. *J Bone J Surg Br*. 1974;56:545–550.
49. Markwalder TM. Surgical management of neurogenic claudication in 100 patients with lumbar spinal stenosis due to degenerative spondylolisthesis. *Acta Neurochir*. 1993;120:136–142.
50. Frank EH, Hsu FP. An endoscopic dural retractor for spinal stenosis surgery. *Minim Invasive Neurosurg*. 2002;45:136–138.
51. Guiot BH, Khoo LT, Fessler RG. A minimally invasive technique for decompression of the lumbar spine. *Spine*. 2002;27:432–438.
52. Khoo LT, Fessler RG. Microendoscopic decompressive laminotomy for the treatment of lumbar stenosis. *Neurosurgery*. 2002;51:146–154.
53. Young S, Veerapen R, O'aoire SA. Relief of lumbar canal stenosis using multilevel subarticular fenestration as an alternative to wide laminectomy: a preliminary report. *Neurosurgery*. 1988;23:628–633.
54. Ashraf AR, Mark AF, Henry HB. Surgery of the lumbar spine for spinal stenosis in 118 patients 70 years of age or older. *Spine*. 2003;28:348–353.
55. Katz JN, Lipson SJ, Chang LC, et al. Seven- to 10-year outcome of decompressive surgery for degenerative lumbar spinal stenosis. *Spine*. 1996;21:92–98.
56. Yamashita K, Ohzono K, Hiroshima K. Five-year outcomes of surgical treatment for degenerative lumbar spinal stenosis. *Spine*. 2006;31:1484–1490.
57. Airaksinen O, Herno A, Turunen V, et al. Surgical outcome of 438 patients treated surgically for lumbar spinal stenosis. *Spine*. 1997;22:2278–2282.
58. Atlas SJ, Keller RB, Robson D, et al. Surgical and nonsurgical management of lumbar spinal stenosis: four-year outcomes from the Maine Lumbar Spine Study. *Spine*. 2000;25:556–562.
59. Atlas SJ, Keller RB, Wu YA, et al. Long-term outcomes of surgical and nonsurgical management of lumbar spinal stenosis: 8 to 10 year results from the Maine Lumbar Spine Study. *Spine*. 2005;30:936–943.
60. Cornefjord M, Byroed G, Brisby H, et al. A long-term (4- to 12-year) follow-up study of surgical treatment of lumbar spinal stenosis. *Eur Spine J*. 2000;9:563–570.
61. Ebara S, Harada T, Hosono N, et al. Intraoperative measurement of lumbar spinal instability. *Spine*. 1992;17:44–50.
62. Goel VK, Nishiyama K, Weinstein JN, et al. Mechanical properties of lumbar spinal motion segments as affected by partial disc removal. *Spine*. 1986;11:1008–1012.
63. Iida Y, Kataoka O, Sho T, et al. Postoperative lumbar spinal instability occurring or progressing secondary to laminectomy. *Spine*. 1990;15:1186–1189.

64. Kambin P, Cohen L, Brooks ML, et al. Development of degenerative spondylosis of the lumbar spine after partial discectomy: comparison of laminotomy, discectomy and posterolateral discectomy. *Spine*. 1994;20:599–507.
65. Natarajan RN, Andersson GB, Padwardhan AG, et al. Study on effect of graded facetectomy on change in lumbar motion segment torsional flexibility using three-dimensional continuum contact representation for facet joints. *J Biomech Eng*. 1999; 121:215–221.
66. Zander T, Rohlmann A, Klockner C, et al. Influence of graded facetectomy and laminectomy on spinal biomechanics. *Eur Spine J*. 2003;12:427–434.
67. Caspar W, Campbell B, Barbier DD, et al. The Caspar microsurgical discectomy and comparison with a conventional standard lumbar disc procedure. *Neurosurgery*. 1991;28:78–87.
68. Mochida J, Nishimura K, Nomura T, et al. The importance of preserving disc structure in surgical approaches to lumbar disc herniation. *Spine*. 1996;21:1556–1564.
69. Rantanen J, Hurme M, Falck B, et al. The lumbar multifidus muscle five year after surgery for a lumbar intervertebral disc herniation. *Spine*. 1993;18:568–574.
70. Ross JS, Robertson JT, Frederickson RC, et al. Association between peridural scar and recurrent radicular pain after lumbar discectomy: magnetic resonance evaluation. *Neurosurgery*. 1996;38:861–863.
71. Stolke D, Sollmann WP, Seifert V. Intra- and postoperative complications in lumbar disc surgery. *Spine*. 1989;14:56–59.
72. Malmivaara A, Sletis P, Heliovaara M, et al. Surgical or nonoperative treatment for lumbar spinal stenosis? A randomized controlled trial. *Spine*. 2007;32:1–8.
73. Podichetty VK, Spears J, Isaacs RE, et al. Complications associated with minimally invasive decompression for lumbar spinal stenosis. *J Spinal Disord Tech*. 2006;19:161–166.
74. Caspar W. A new surgical procedure for lumbar disc herniation causing less tissue damaging through a microsurgical approach. In: Wuellenweber R, Brock M, eds. *Advances in Neurosurgery*. Berlin: Springer Verlag; 1977;4:74–77.