

EVALUATION OF HALLER'S CELLS PREVALENCE AND CHARACTERISTICS USING ORTHOPANTOMOGRAPHY

Sabahat H. Khan¹, Salman Ansari², Purushottam Joshi³

1. Sr. Lecturer, Department of Oral Medicine and Radiology, Dr. Rajesh Ramdasji. Kambe Dental College and Hospital, Akola
2. Associate Professor, Department Periodontics, Swargiya Dadasaheb Kalmegh Smruti Dental College and Hospital, Nagpur.
3. Oral Medicine and Radiology, Sr. Dental Practitioner

ABSTRACT:

Aim: To determine the prevalence and characteristics of Haller's cells on panoramic radiographs and to observe its role in differential diagnosis of orofacial pain.

Materials and methods: The study group comprised 250 healthy adults of both genders with an age range of 18–60 years. One panoramic radiograph for each of the patients was made and interpreted for the presence of Haller's cells. The clinical history of the patients was taken for orofacial pain originating in paranasal sinuses. The data collected were subjected to statistical analysis: Frequencies/percentages, χ^2 test and Pearson correlation coefficient using SPSS ver. 11.5 to obtain the results.

Results: Haller's cells were noted in 68 patients, accounting for a prevalence of 32.38% with p value of 0.01. Of these patients, 29.4% were unilateral while 70.5% were bilateral. Among 68 cases, a total of 154 cells were found. The majority of the cells were round or ovoid in shape. 73.5% of patients with Haller's cells were symptomatic with a p value of 0.00. The number of symptomatic patients with Haller's cells was statistically significant.

Conclusion: This study has attempted to study the prevalence and characteristics of Haller's cells on panoramic radiographs and the number of cases with Haller's cells which are symptomatic. A description of Haller's cells on these radiographs may prove vital in enumerating the differential diagnosis for patients afflicted with intractable orofacial pain and will also prevent any untoward intraoperative complications during endonasal procedures.

Keywords: Haller's Cells, Orthopantomography, orofacial pain, panoramic radiographs.

INTRODUCTION:

Haller's cells are defined as air cells situated beneath the ethmoid bulla along the roof of the maxillary sinus and the most inferior portion of the lamina papyracea, including air cells located within the ethmoid infundibulum.^[1] These cells are clinically significant as they are related to different disease processes and symptoms originating in the ethmoidal air cells which include orofacial pain, chronic sinusitis, headache of sinusoidal origin and

mucocoeles.^[2] The aim of our study was to determine the prevalence and characteristics of Haller's cells on panoramic radiography and to observe its role in differential diagnosis of orofacial pain originating in associated structures (paranasal sinuses).^[3] Dental professionals should be aware of this anatomic variation and should consider this in the differential diagnosis of orofacial pain.

MATERIALS AND METHODS:

The study group comprised 250 healthy adults of both genders with an age range of 18–60 years who were selected by simple random sampling. Patients with a history of Headache associated with cranial structures, ears, eyes, neck and trauma involving the maxillofacial region, Migraine, Tension type headache, Cluster headache, Headache related to vascular and nonvascular disorders, Headache attributed to infection and disorders of haemostasis were excluded from the study.^[4] Patients with Orofacial pain originating in associated structures like eyes, ears, throat, lymph nodes, salivary glands and neck, Intracranial pain disorders, Neurogenic pain disorders, Intra oral pain and Temporomandibular disorders were also excluded.^[3] Patients with systemic diseases affecting growth and clinical or radiographic evidence of developmental anomalies/pathologies affecting the maxillofacial region were also excluded from the study.

The institutional ethical clearance was obtained prior to conducting the study. History pertaining to headache of sinusoidal origin, chronic maxillary sinusitis and intractable orofacial pain originating in paranasal sinuses was obtained from the patients. Following clinical examination, one Digital Panoramic radiograph for each of the patients was taken using ORTHOPHOS XG x-ray system from Sirona, Germany with a CCD based sensor.

The radiographs obtained were serially interpreted for the presence of Haller's cells under ideal viewing conditions. The recognition of Haller's cells was made if an anatomical variation fulfilled the criteria suggested by Ahmad et al.^[5]

- 1) Well-defined round, oval, or tear-drop shaped radiolucency, single or multiple, unilocular or multilocular, with a smooth border, which may or may not appear corticated.
- 2) Located medial to infraorbital foramen.
- 3) All or most of the border of the entity in the panoramic section is visible.
- 4) The inferior border of the orbit lacks cortication or remains indistinguishable in areas superimposed by this entity.

Figure 1: Section of Panoramic Radiograph with arrows pointing towards the location and outline of Haller's cells. Unilateral (left side), Unilocular, Oval, Multiple Haller's cells can be seen.

Figure 2: Section of Panoramic Radiograph with arrows pointing towards the location and outline of Haller's cells. Bilateral, Unilocular, Oval, Multiple Haller's cells can be seen.

The observations pertaining to the radiographic appearance of Haller's cells and the clinical history pertaining to the Orofacial Pain and headache originating in associated structures (paranasal sinuses) were entered in the subjects' proformas. The data collected were

tabulated and subjected to statistical analysis, namely frequencies/percentages, χ^2 test and Pearson correlation coefficient using SPSS for Windows.

RESULTS:

The total sample size of the study was 250. Out of the 250 panoramic radiographs evaluated, 40 were excluded from the study as they did not show the floor of the orbit, or were diagnostically unacceptable in the orbital regions.

Thus sample size of the study was now 210, consisting of 103 males and 107 females. Of the 210 patients, Haller's cells were found in 68. The overall prevalence of Haller's cells was 32.38% which was statistically significant (Table 1).

The overall mean age of subjects with Haller's cells was 29.12 years. The overall mean age of male and female patients with Haller's cells was 26.89 years and 31.84 years, respectively. Of the 68 patients with Haller's cells, 36 (35.29%) were patients aged 18–30 years, 22 (29.72%) were patients aged 31–45 years and 10 (29.41%) were patients aged 46–60 years (Table 2). The distribution of Haller's cells with respect to age was not statistically significant.

Among the 68 patients with Haller's cells, 24 (27.18%) were male and 44 (37.38%) were female which was not statistically significant (Table 3). Among the 68 patients with Haller's cells, the cells occurred unilaterally in 20 (29.4%) and bilaterally in 48 (70.5%). Among the 20 patients with unilateral Haller's cells,

the cells in 8 (40%) were localized on the right side and the cells in 12 (60%) were localized on the left side.

Among 68 patients with Haller's cells, 50 patients (73.5%) were symptomatic, 18 were asymptomatic (26.47%). Amongst 50 symptomatic patients, 35 had a history of headache which is unrelated to maxillary or frontal sinusitis, 13 patients were diagnosed with maxillary sinusitis and 2 patients with chronic cough and maxillary sinusitis. However 17 patients who were symptomatic did not show presence of Haller's cells.

Among the 68 patients with Haller's cells, in 20 the cells were unilateral unilocular (29.41%), in 44 (64.70%) they were bilateral unilocular and in 4 (5.88%) they were of a bilateral mixed pattern, i.e. both unilocular and multilocular patterns were noted on the right and left side (Table 4). Among the 68 patients with Haller's cells, a total of 154 cells were found. Of these, 150 were unilocular while 4 were multilocular. Majority of the Haller's cells were round or ovoid in shape with only 2 cases depicting a tear drop shape.

DISCUSSION:

On a panoramic radiograph, infraorbital ethmoid cells can be confirmed by their location, that is, well-defined radiolucency situated medial to the inferior orbital canal. On CT examination, the diagnosis of infraorbital ethmoid cells is made if the air cells are present along the roof of maxillary sinus, below

the ethmoid bulla, or on the inferior most part of lamina papyracea.^[2]

Ahmad et al ^[5] and Raina et al ^[6] evaluated the prevalence of Haller's cells by using panoramic radiographs. Ahmad et al ^[5] observed Haller's cells in 60 out of 173 evaluated samples (38.2%) that this result was in the range of our results. In Raina et al's study ^[6] 16% of 600 subjects showed Haller's cells and the difference between unilateral and bilateral cells was significant.

Several investigators have studied the prevalence of infraorbital ethmoid cells using CT images. A wide range of prevalence (4.7–45.1%) of infraorbital ethmoid cells using CT images has been reported in the literature.^[1,7-9] Although this study examined panoramic radiographs, the prevalence (38.2 %) falls within the range of these previous studies. Because infraorbital ethmoid cells are anatomic variations, we did not find any justification to obtain CT images on our subjects to confirm our diagnosis.

The results of several studies emphasize to the clinical importance of Haller's cells because even if infraorbital ethmoid cells are not diseased, their presence may narrow the ethmoid infundibulum or the ostium of the maxillary sinus.^[3] Such anatomic limitation can cause constant Rhino sinusitis.^[10] Anatomic obstruction of the infundibulum with the presence of huge Haller's cells can cause blockage in the transmission of fluids.

Alkire and Bhattacharyya evaluated the effects of septum deviation, chonchae

bullusa and Haller's cells on the occurrence of acute rhinosinusitis, and their results showed that just obstruction caused by Haller's cells can lead to the disease.^[11] A review article has also reported about headache related to Haller's cells ^[12] and it has been said that Haller cells may also cause sinus disease such as mucocele.^[13] Sebrechts et al acknowledged that Haller cell inflammation can be a potential reason of orbital unilateral edema.^[14]

On the other hand, some studies suggested that the presence of Haller's cells automatically doesn't predispose an individual to the sinus disease.^[2,15] Even Ahmad et al in his study did not report any symptoms of these diseases.^[5]

However, in our study 73.5% of the patients with Haller's cells were found to be symptomatic and the cause of the pain or headache cannot be attributed to any other known causes of orofacial pain and headache.

CONCLUSION

The results of this study suggest that Panoramic radiographs can depict and provide a clear delineation of Haller's cells in a considerable number of cases. Such a description of the infraorbital ethmoid cells may prove useful in clear identification of these entities and aid in charting out the differential diagnosis for patients suffering from intractable orofacial pain or headache, thereby avoiding other expensive and invasive diagnostic modalities. Detection of

Haller's cells may also forewarn the surgeons prior to endonasal procedures, thus preventing any untoward intraoperative complications.

As to our knowledge till now, no study has compared Panoramic radiography and CT scan for detection of Haller's cells. CT also being used for imaging these cells, it is recommended that

studies be conducted to compare the ability of these two methods for detection of this landmark and to see the development of any disease process in Haller's cells which can further aid in specifically diagnosing the cause of orofacial pain or headache. .

REFERENCES:

1. Basic N, Basic V, Jukic T, Basic M, Jelic M, Hat J. Computed tomographic imaging to determine the frequency of anatomical variations in pneumatization of the ethmoid bone. *Eur Arch Otorhinolaryngol* 1999; 256: 69–71.
2. Bolger WE, Butzin CA, Parsons DS. Paranasal sinus bony anatomic variations and mucosal abnormalities: CT analysis for endoscopic sinus surgery. *Laryngoscope* 1991;101:56-64.
3. Bruce Blasberg, Martin Greenberg, *Orofacial Pain - Textbook of Oral Medicine, Diagnosis and Treatment*, Burket's Eleventh Edition, 257-288.
4. Headache Classification Subcommittee of the International Headache Society. "The International Classification of Headache Disorders, 2nd Edition". *Cephalgia* 2004;24Suppl 1: 9-160.
5. Ahmad M, Khurana N, Jaber J, Sampair C, Kuba RK. Prevalence of infraorbital ethmoid (Haller's cells) on panoramic radiographs. *Oral Surg Oral Med Oral Pathol Oral Radiol Oral Endod* 2006; 101: 658–661.
6. Raina A, Guledgud MV, Patil K. Infraorbitalethmoid (Haller's) cells: a panoramic radiographic study. *DentomaxillofacRadiol*. 2012;41(4):3058.
7. Kantarci M, Karasen RM, Alper F, Onbas O, Okur A, Karaman A. Remarkable anatomic variations in paranasal sinus region and their clinical importance. *Eur J Radiol* 2004; 50: 296–302.
8. Tatli MM, San I, Karaoglanoglu M. Paranasal sinus computed tomographic findings of children with chronic cough. *Int J PediatrOtorhinolaryngol* 2001; 60: 213–217.
9. Wanamaker HH. Role of Haller's cell in headache and sinus disease: a case report. *Otolaryngol Head Neck Surg* 1996; 114: 324–327.
10. Braun H, Stammberger H. Pneumatization of turbinates. *Laryngoscope* 2003;113:668-72.
11. Alkire BC, Bhattacharyya N. An assessment of sinonasal anatomic variants potentially associated with

recurrent acute rhinosinusitis. Laryngoscope. 2010;120(3):631-4.

12. Marks, S. C., and W. A. Loechel. Nasal and Sinus Surgery. Philadelphia: W. B. Saunders Co., 2000. Chp 3:46.

13. Luxenberger W, Anderhuber W, Stammberger H. Mucocele in an orbitoethmoidal (Haller’s) cell (accidentally combined with acute contralateral dacryocystitis). Rhinology 1999;37:37-9.

14. Sebrechts H, Vlaminck S, Casselman J. Orbital edema resulting from Haller's cell pathology: 3 case reports and review of literature. ActaOtorhinolaryngol Belg. 2000;54(1):39-43.

15. Yanagisawa E, Marotta JC, Yanagisawa K. Endoscopic view of a mucocele in an infraorbital ethmoid cell (Haller cell). Ear Nose Throat J 2001;80:364, 368.

TABLES:

Table 1: Prevalence of Haller’s cells

Absent	142	67.62%
Present	68	32.38%
Total	210	100%

$\chi^2 = 298.3$, $p = 0.00$ (< 0.05)

Table 2: Distribution of Haller’s cells with respect to age (number of patients)

18–30 years (102)	35.29%
31–45 years (74)	29.72%
46–60 years (34)	29.41%

Correlation coefficient (R value) - 0.125, p value = 0.071 (>0.05)

Table 3: Distribution of Haller’s cells with respect to gender (number of patients)

Male (103)	27.18%
Female (107)	37.38%

Correlation Coefficient (R value) – 0.113, P value = 0.081 (>0.05)

Table 4: Distribution of Haller's cells with respect to type

Unilocular (Unilateral)	20 (29.41%)
Unilocular (Bilateral)	44 (64.70%)
Uni & Multilocular (Bilateral)	4 (5.88%)

FIGURES:

Figure 1: Section of Panoramic Radiograph with arrows pointing towards the location and outline of Haller's cells. Unilateral (left side), Unilocular, Oval, Multiple Haller's cells can be seen.

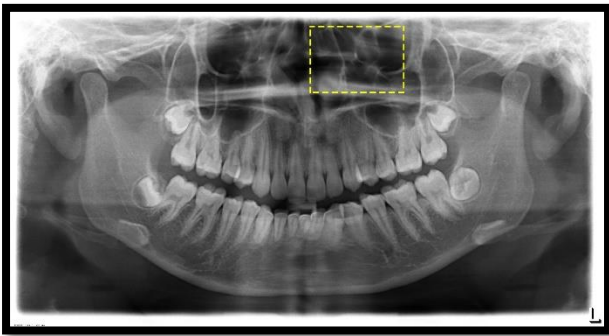


Figure 2: Section of Panoramic Radiograph with arrows pointing towards the location and outline of Haller's cells. Bilateral, Unilocular, Oval, Multiple Haller's cells can be seen.

