

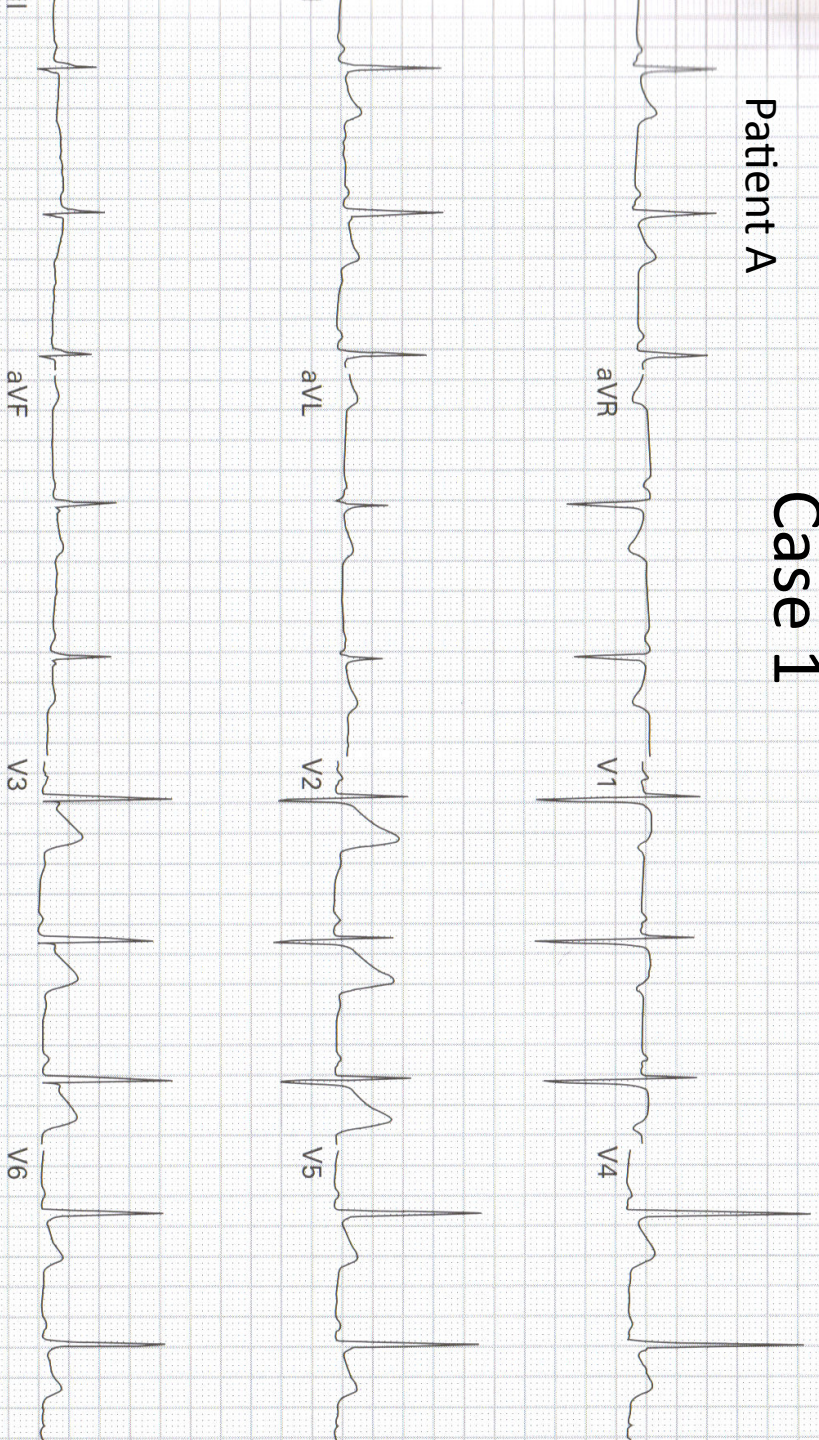
Appropriate Activation of the Cath Lab: EKG Cases

Jason Mansour, MD

Broward Health Medical Center

Case 1

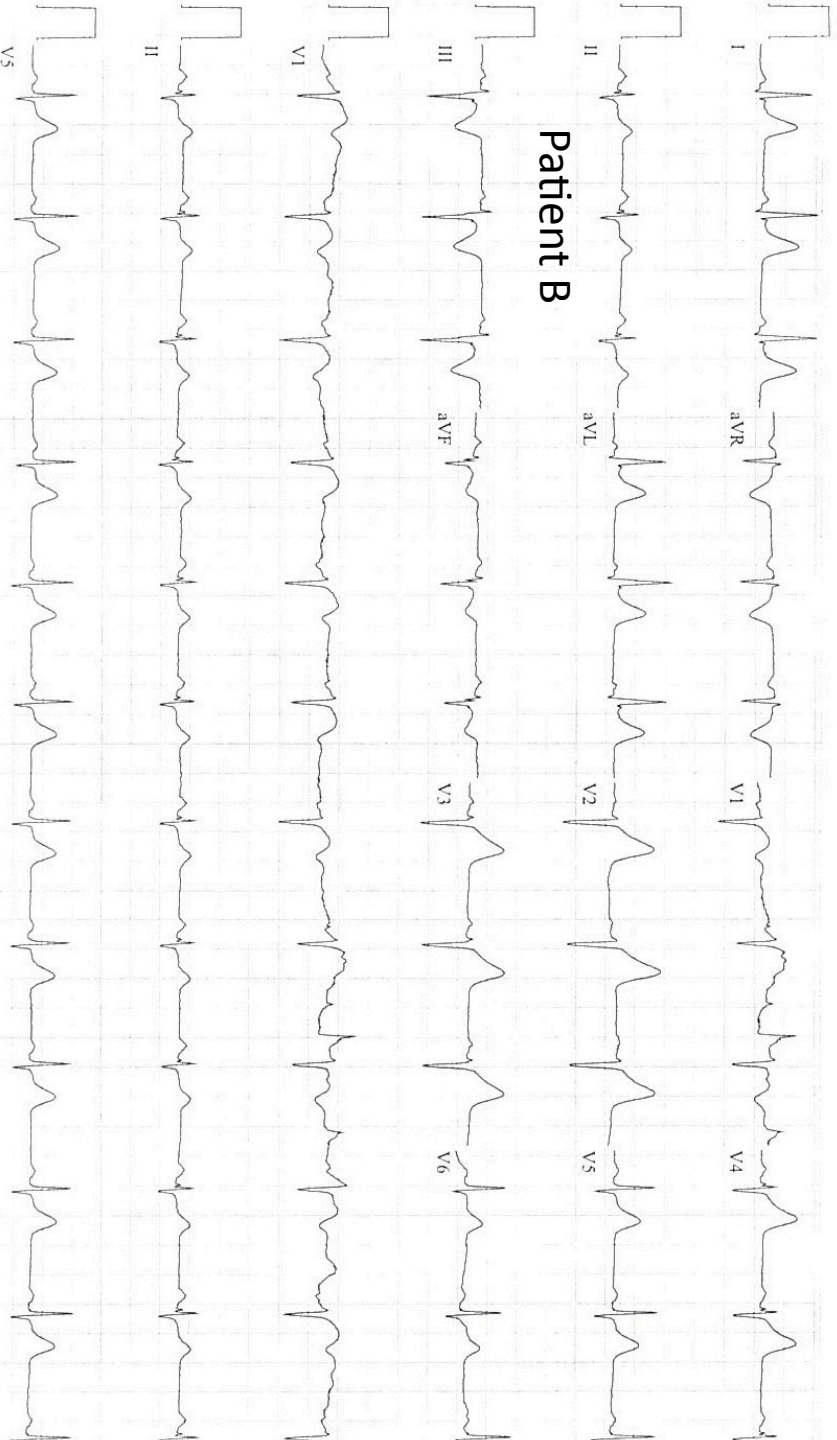
Patient A

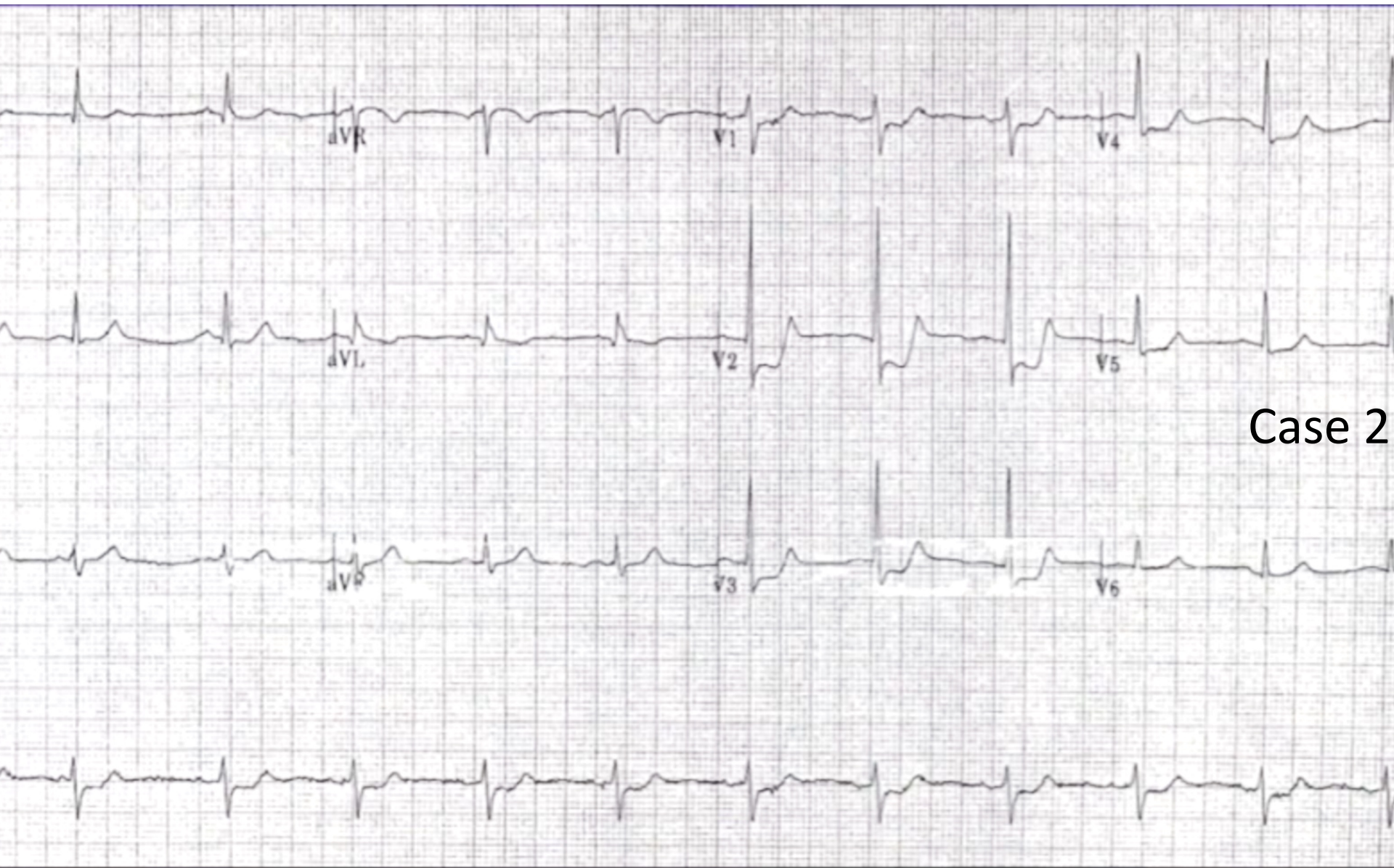


Referred by: ED

Confirmed By: JEAN-PAUL SORONDO

Patient B

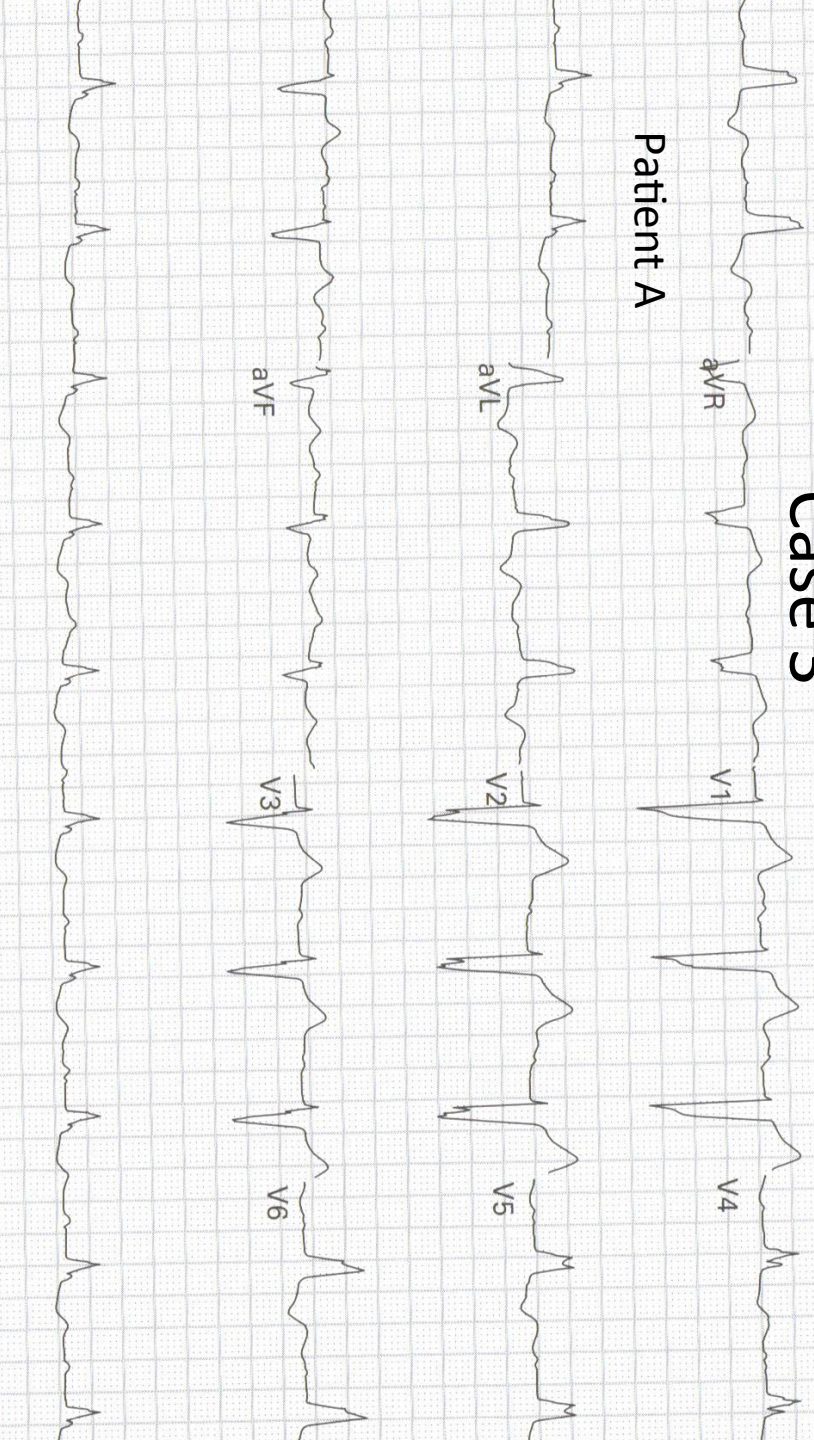




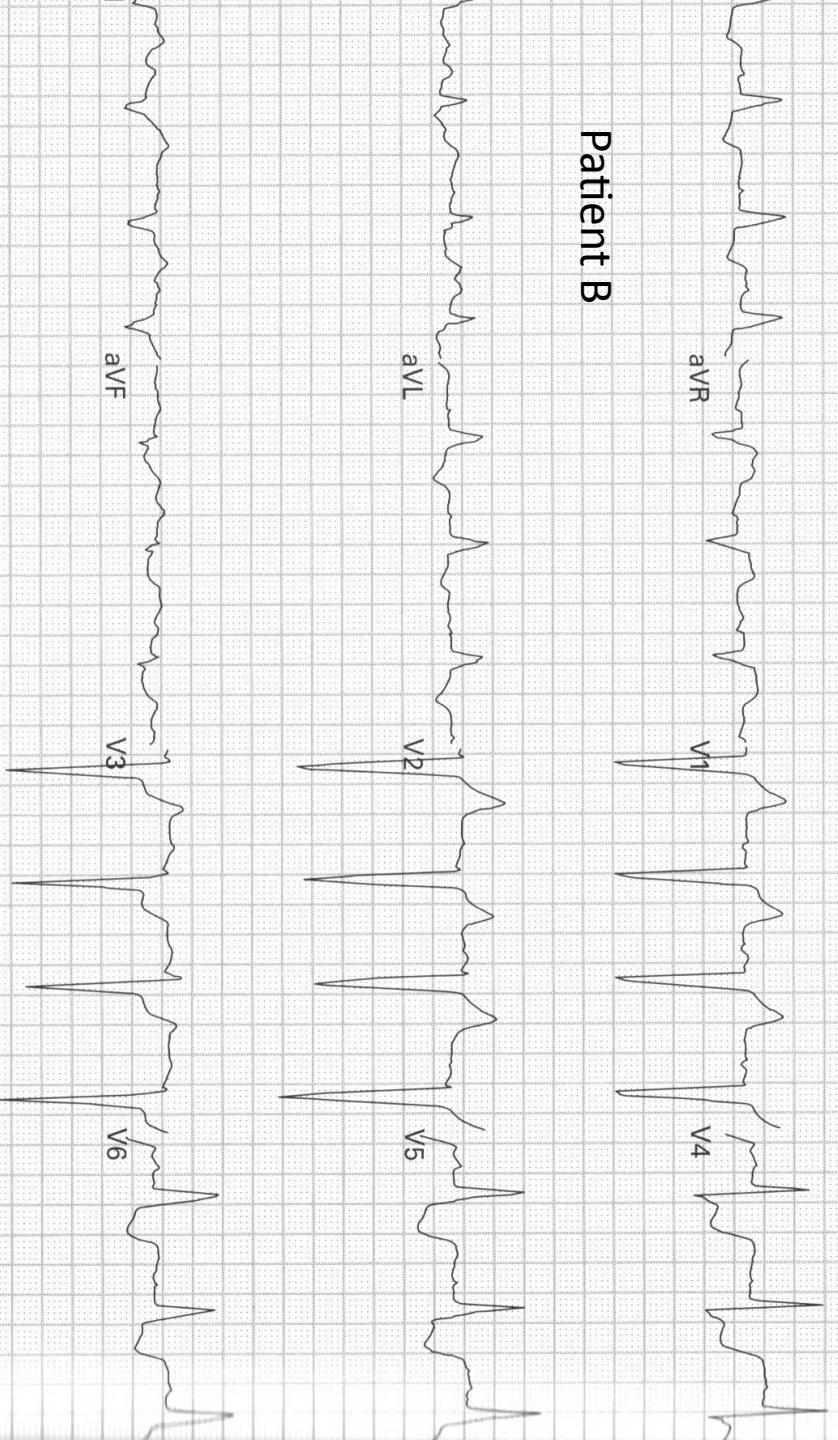
Case 2

Case 3

Patient A

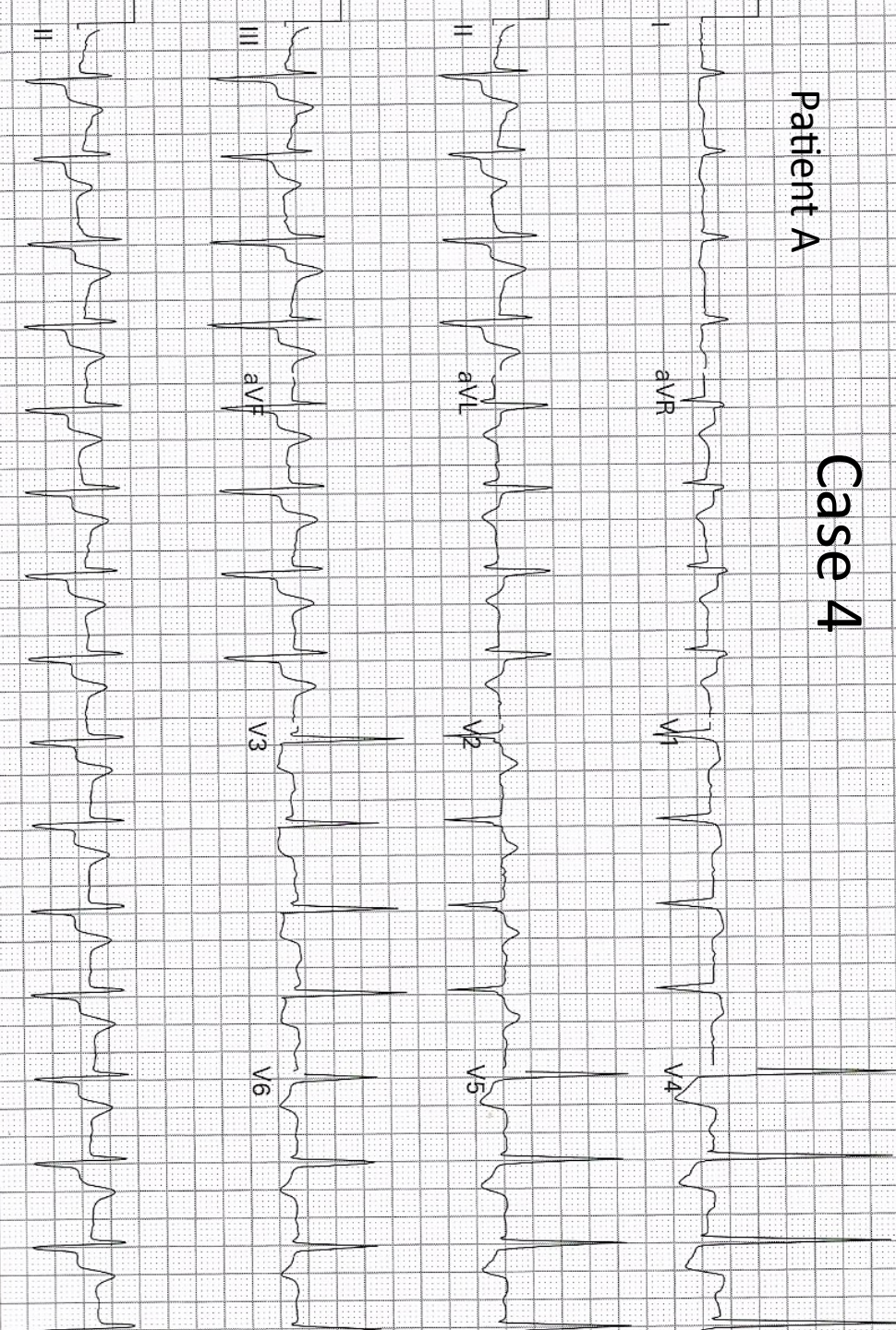


Patient B

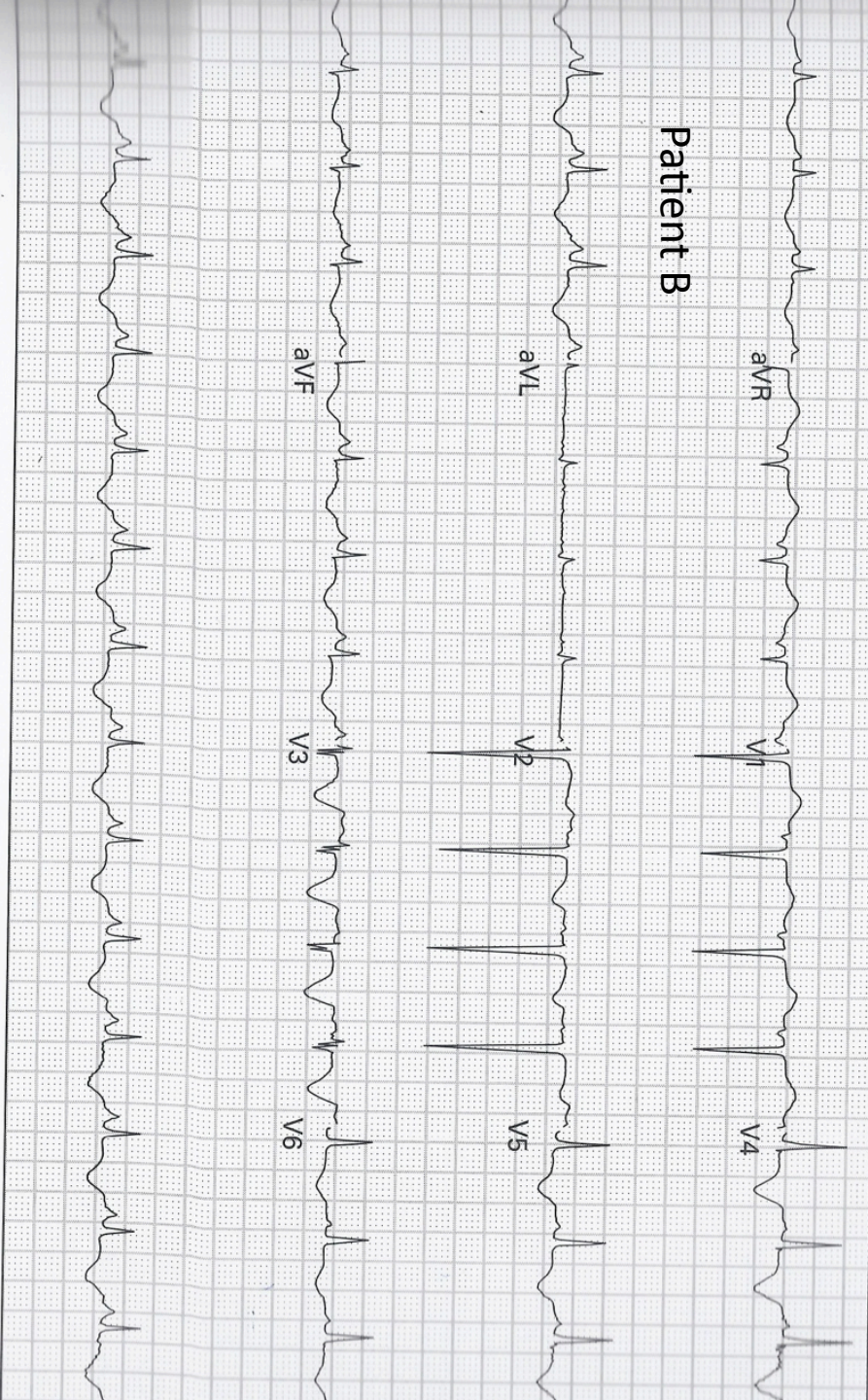


Patient A

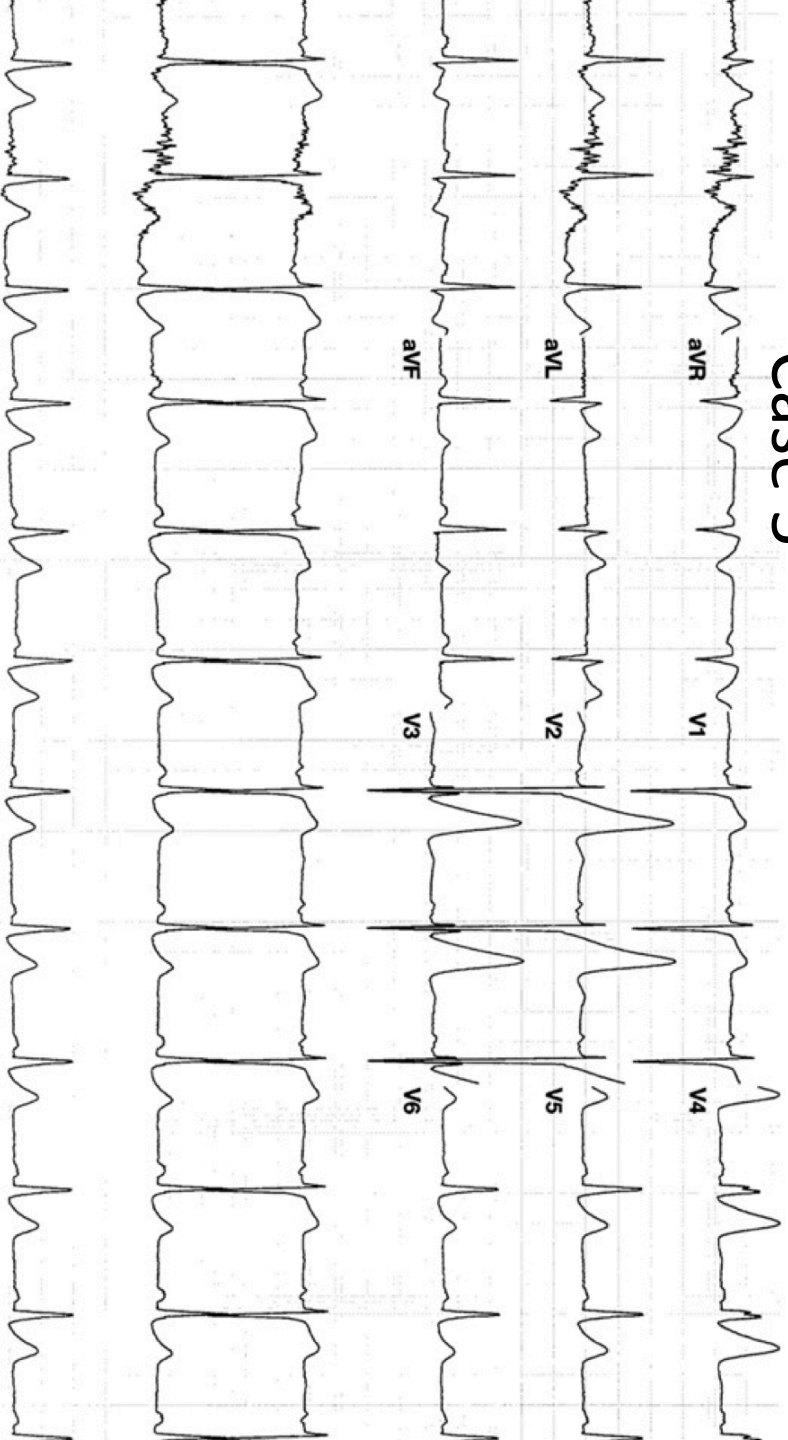Case 4



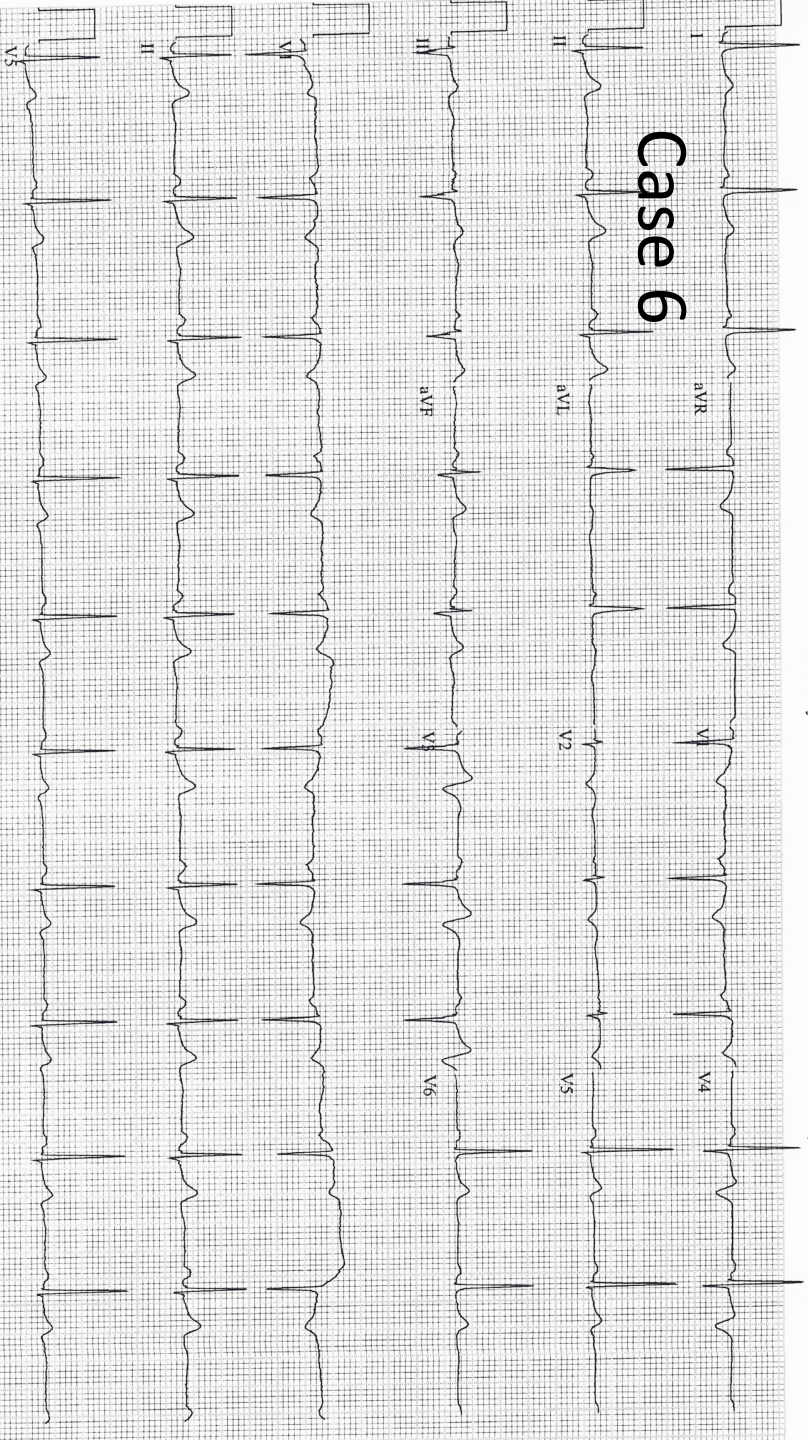
Patient B



Case 5

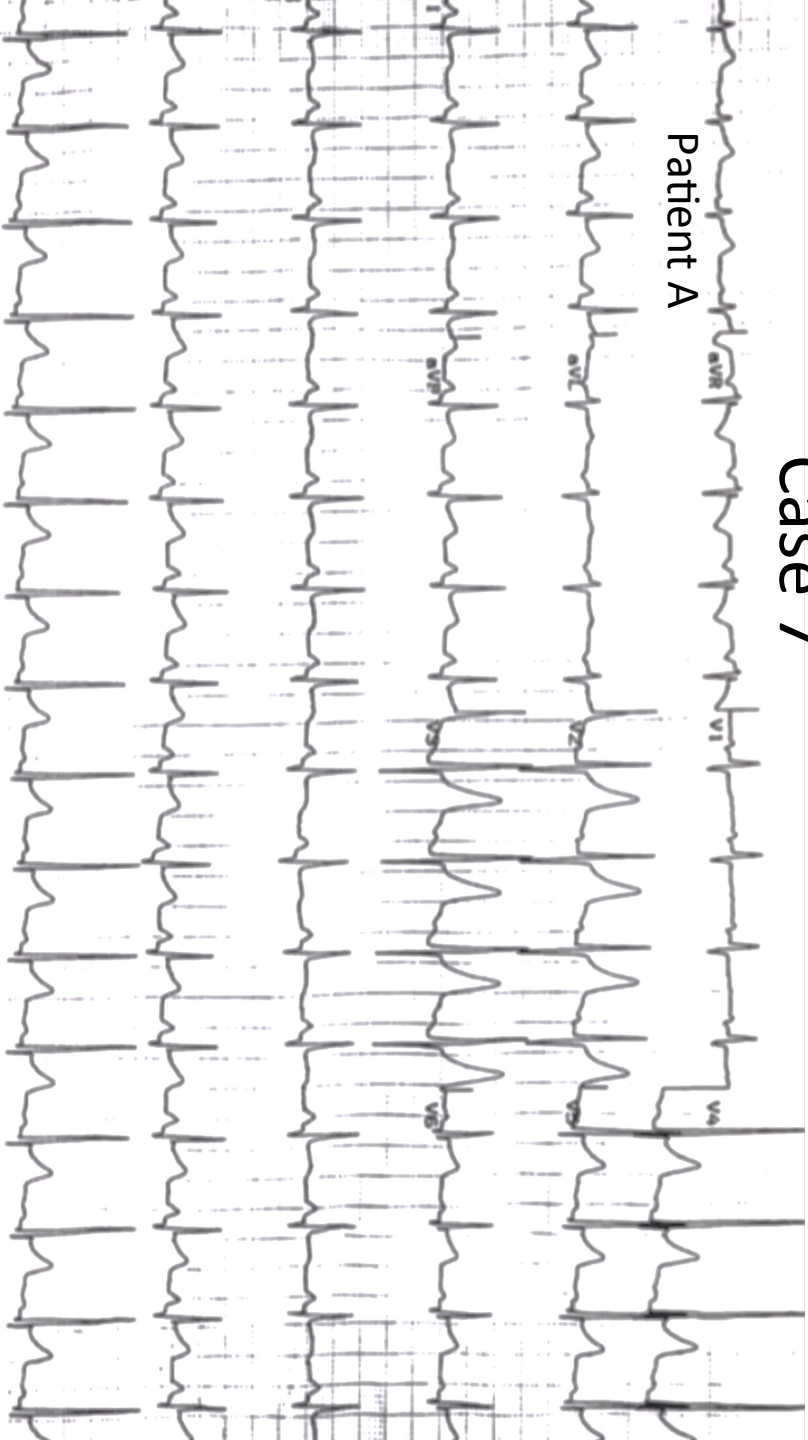


Case 6

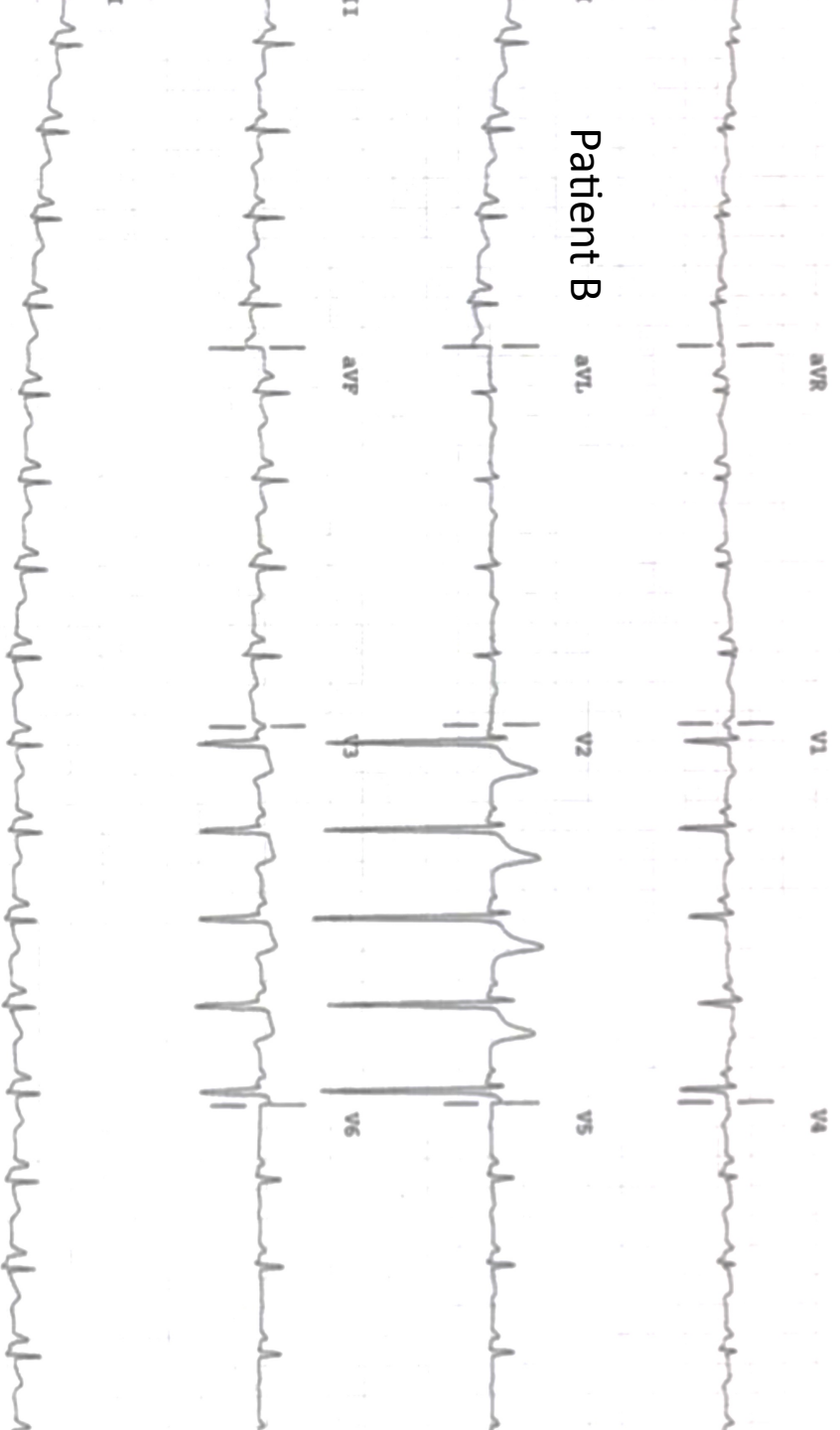


Case 7

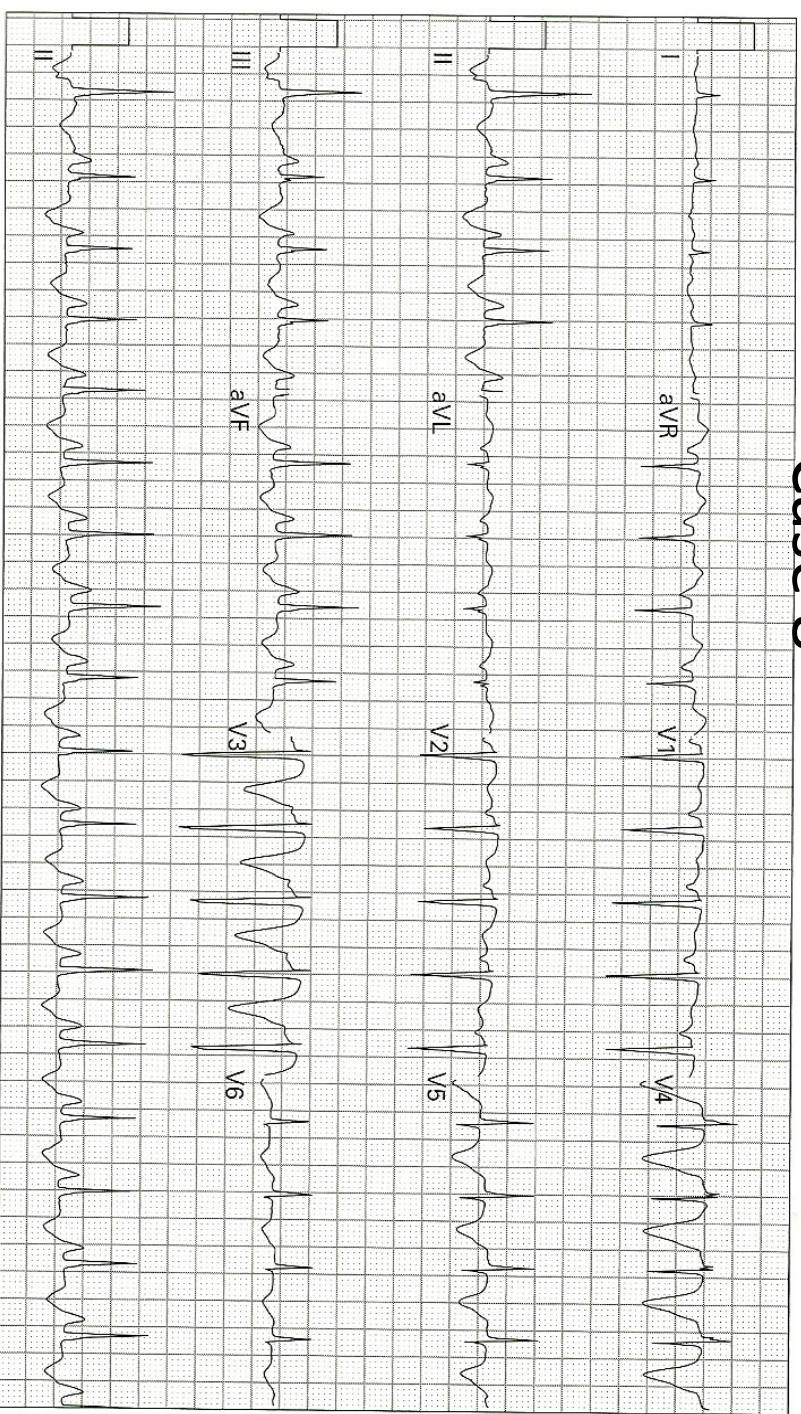
Patient A



Patient B

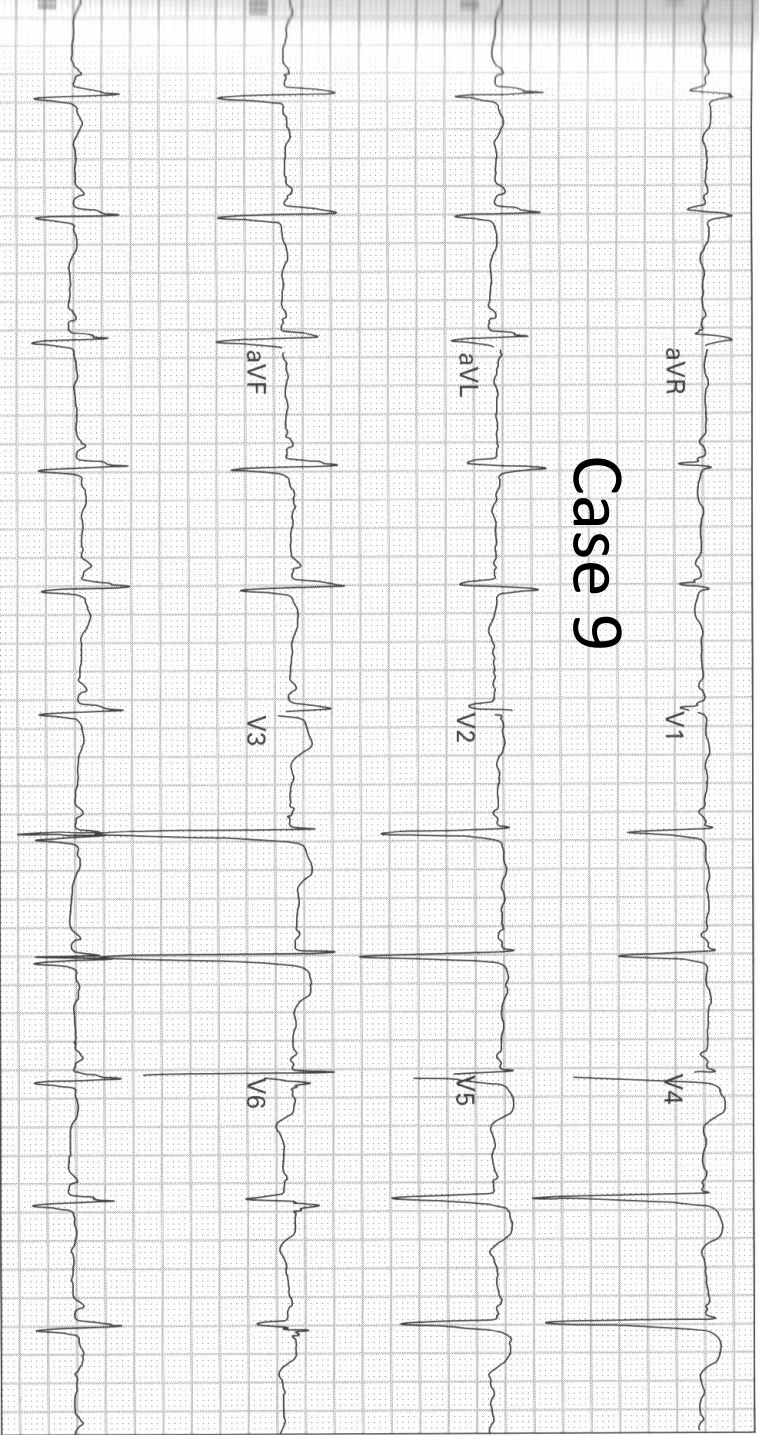


Case 8



33. 61 year old man presents with a decreased level of consciousness

Case 9



25. 56 year old woman with a history of a prior MI gets a pre-admission ECG; she is being admitted for cellulitis of the leg; she has no cardiopulmonary symptoms