

## IMAGE ANALYSIS WITH COMPUTED TOMOGRAPHY AND INVASIVE CORONARY ANGIOGRAPHY CORRELATION

### *Notes for Image Analysis*

Adjust the window level to optimize delineation between contrast from left side of the heart, right side of the heart, and possible calcified plaque if present with the surrounding structures.

Use zoom and pan to maximize the viewing angle.

Axial images are the cornerstone of chest CT interpretation. Left main (LM), proximal and mid left anterior descending (LAD) are best viewed with axial images. Coronal images are helpful for vessels that travel vertically, i.e. mid right coronary artery (RCA).

Being able to recognize the visual presentation in patients with coronary artery bypass graft (CABG) is important. These patients have multivessel disease. An important goal for using chest CT is to be able to recognize patients with undiagnosed coronary artery disease (CAD) with the same calcification pattern. They will have the highest chance of having obstructive CAD.

On the other hand, the lack of calcified or noncalcified plaque with normal anatomy can be a helpful sign that there is no obstructive CAD.

### *Notes for Reporting*

Describe the coronary anatomy and grade the severity based on the level of obstruction and the stage of atherosclerosis with the risk class stratification system. This information can be very helpful for the referring providers (Table 1 and 2).

TABLE 1. CHEST CT AND INVASIVE CORONARY ANGIOGRAPHY SCORING SYSTEM

Luminal Diameter	CHEST CT SCORE	INVASIVE CORONARY ANGIOGRAPHY SCORE
Normal	0	0
1-49%	1	1
50-69%	2	2
70-99%	3	3
100%	3	4

TABLE 2. RISK CLASS STRATIFICATION SYSTEM

RISK CLASS	Risk Level	Description	Examples
A	Normal	Healthy - At Risk	No plaque or stenosis
B	Minimal Risk	Mild Atherosclerosis- No High-Risk Plaque Features	Mild disease in 1-2 vessels
C	Moderate Risk	High Risk Non-Obstructive Atherosclerosis	1-2 segment with moderate disease OR 3 vessels with mild disease OR high-risk plaque
D	High Risk	Obstructive CAD or Multivessel Nonobstructive Plaque	1 vessel with severe obstructive disease OR 2-3 vessels with moderate disease
E	Very High Risk	Multivessel Obstructive CAD	Multivessel severe obstructive disease

On reporting, being able to comment on whether the patient has CAD is important. If the assessment is uncertain, quantifying the level of uncertainty is important. One option for quantifying the level uncertainty is to phrase in the conclusion the probability that the patient might have obstructive CAD. (Table 3).

TABLE 3. ASSESSMENT OF CONFIDENCE LEVEL

Probability	Confidence Level
0-20%	Highly unlikely
21-49%	Possibly, but not likely/ There is a chance.
50%	50%/ Equivocal/ Can't tell one way or another.
51-79%	Likely or probably
80-100%	Highly likely

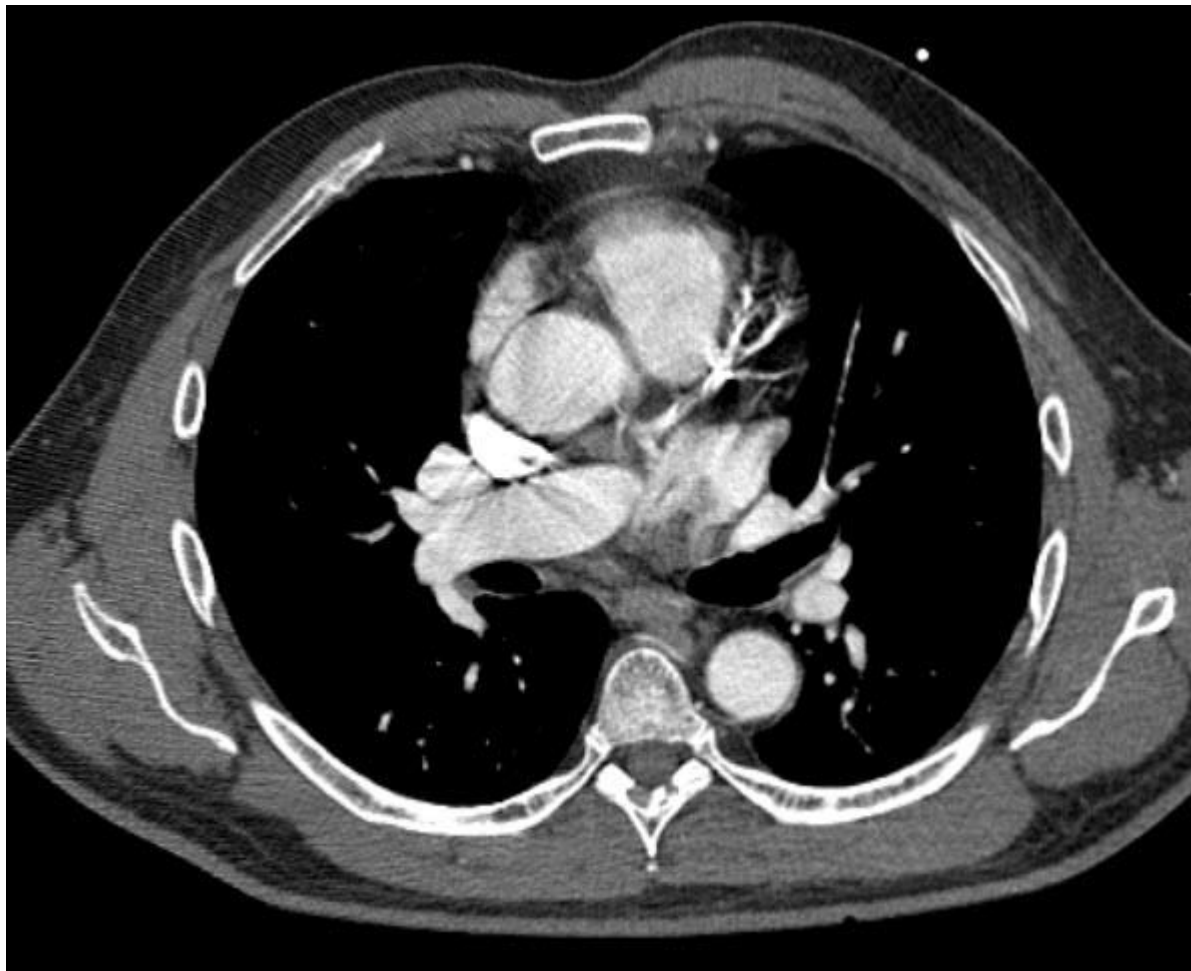For example:

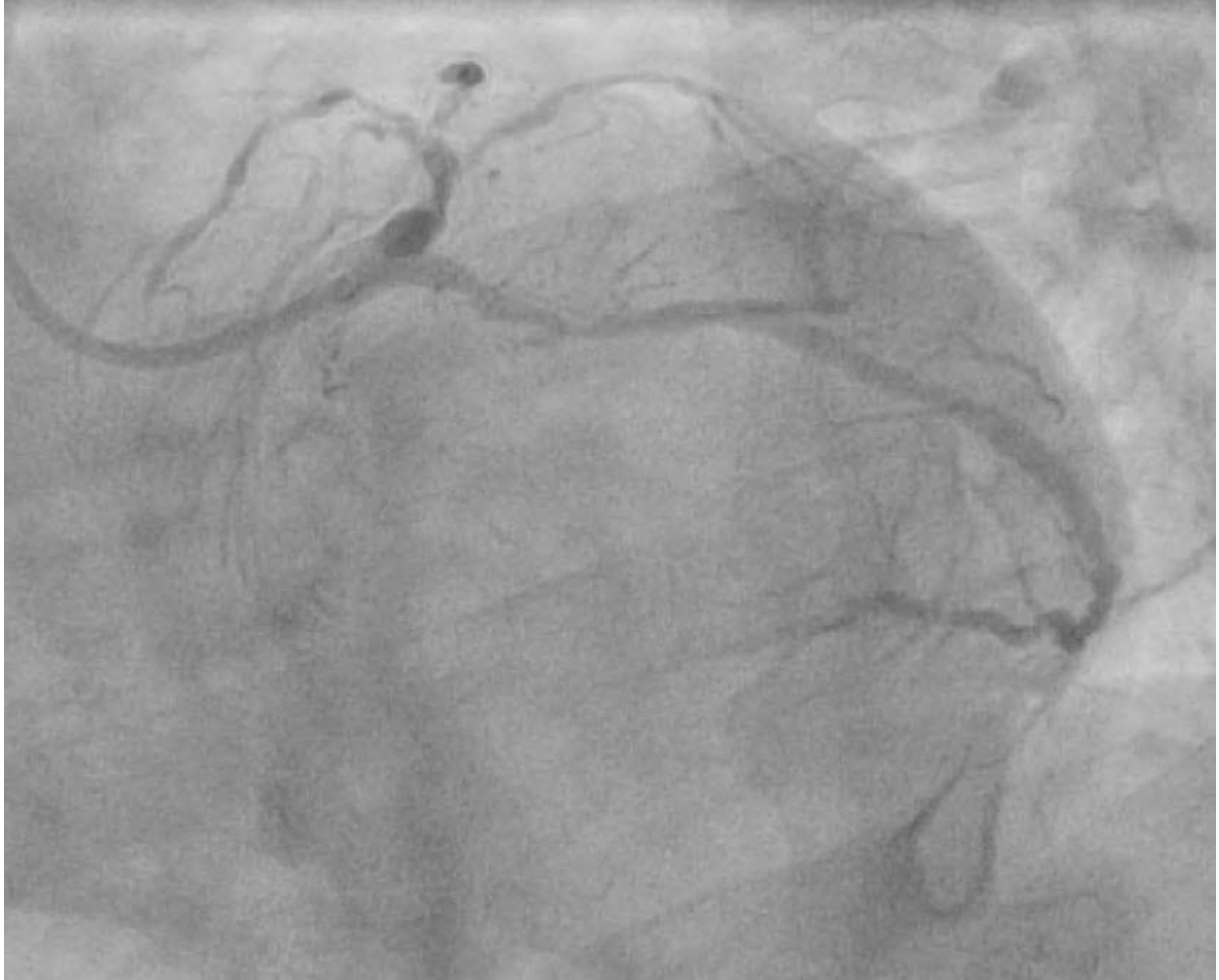
1. This patient has no evidence of coronary artery calcification. It is highly unlikely that this patient has obstructive CAD.
2. This patient has severe calcification in multiple vessels. This patient probably has obstructive CAD.

## CASE 1

Chest CT findings: Chest CT was performed four days before invasive coronary angiography (ICA). LAD has diffuse disease. Chest CT score: 3 (severe). Risk Class: E (multivessel obstructive disease).

ICA findings: LAD has diffuse disease. Proximal left circumflex artery (LCX) has an obstructive lesion. ICA score 3.

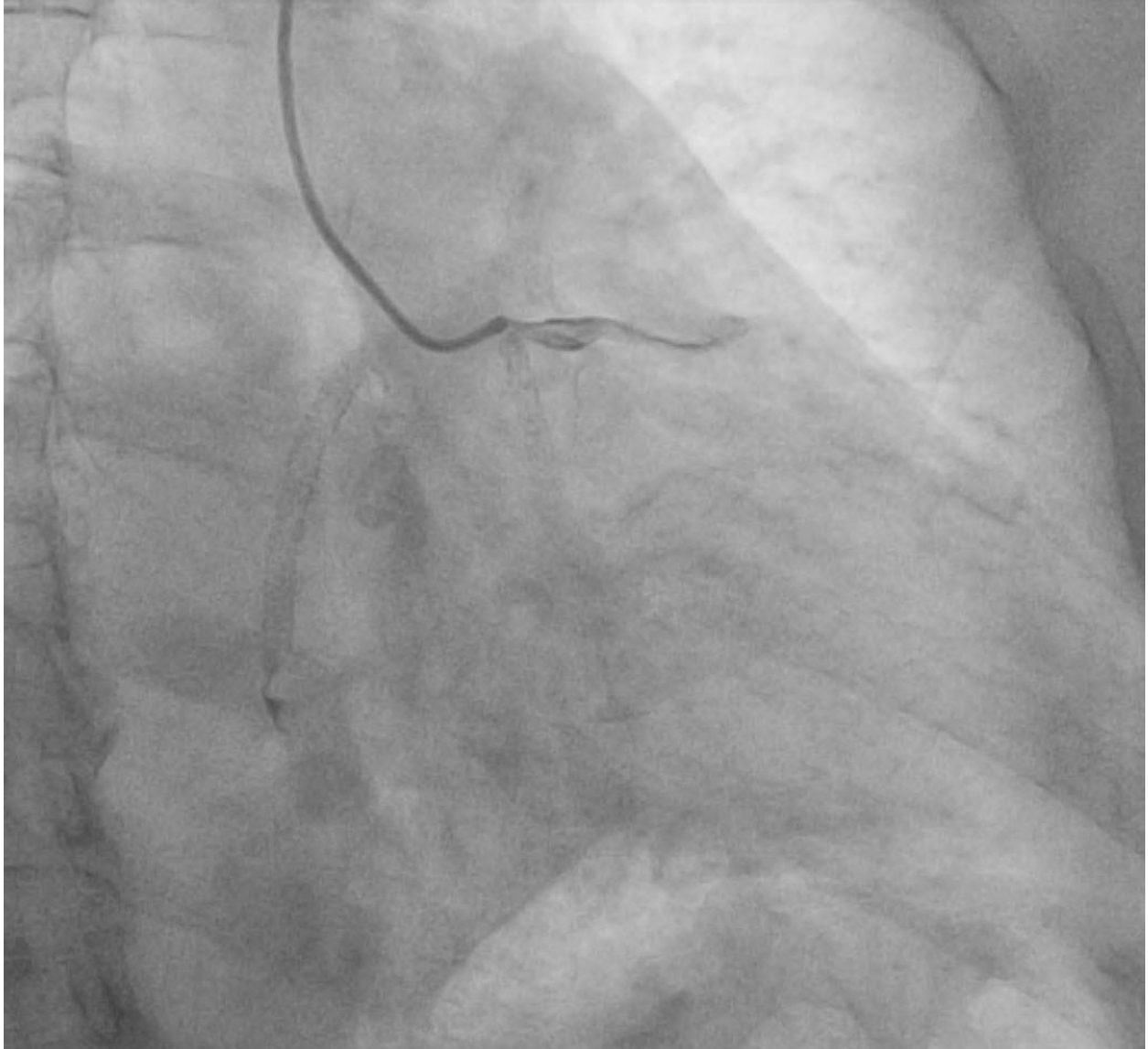


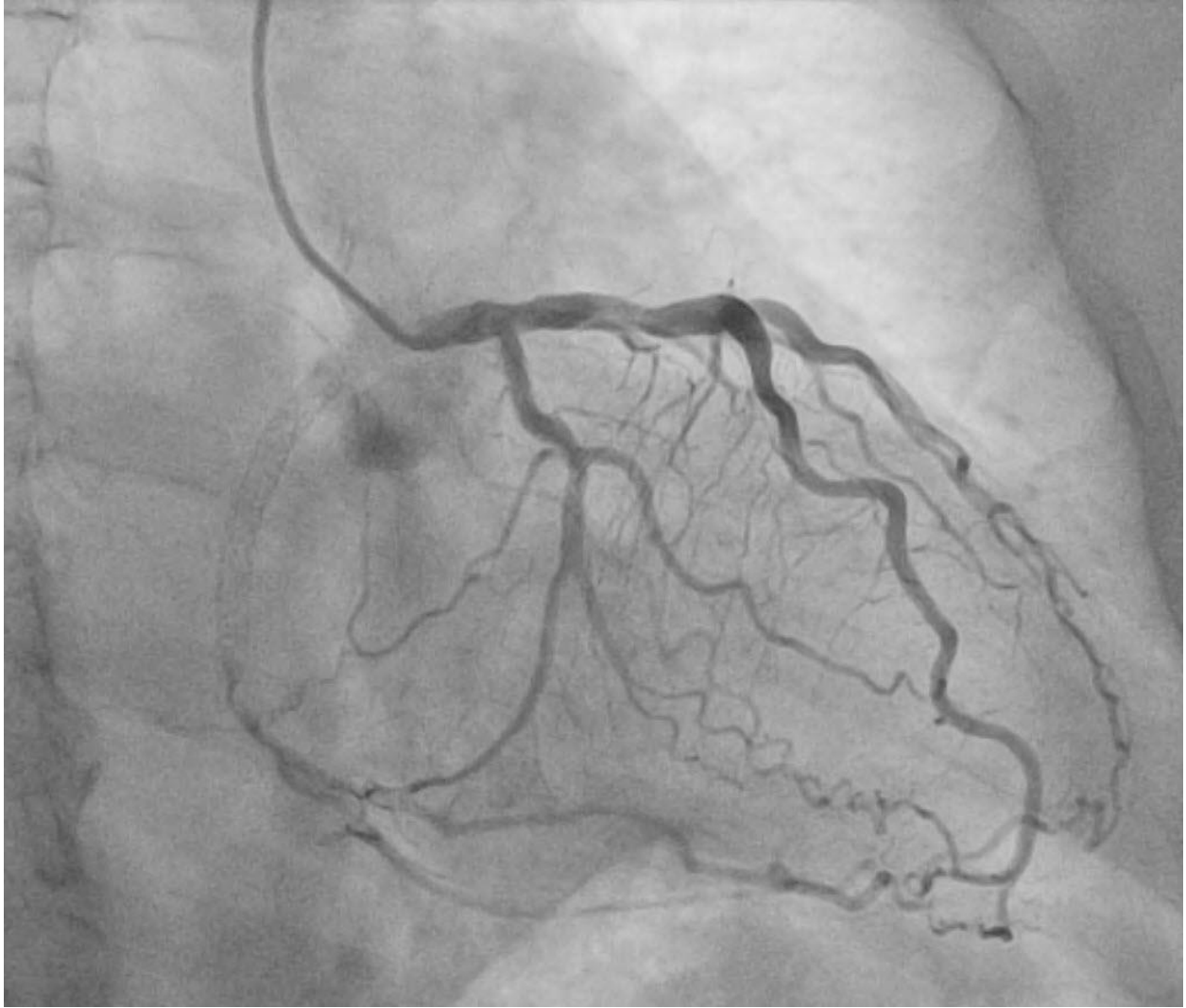


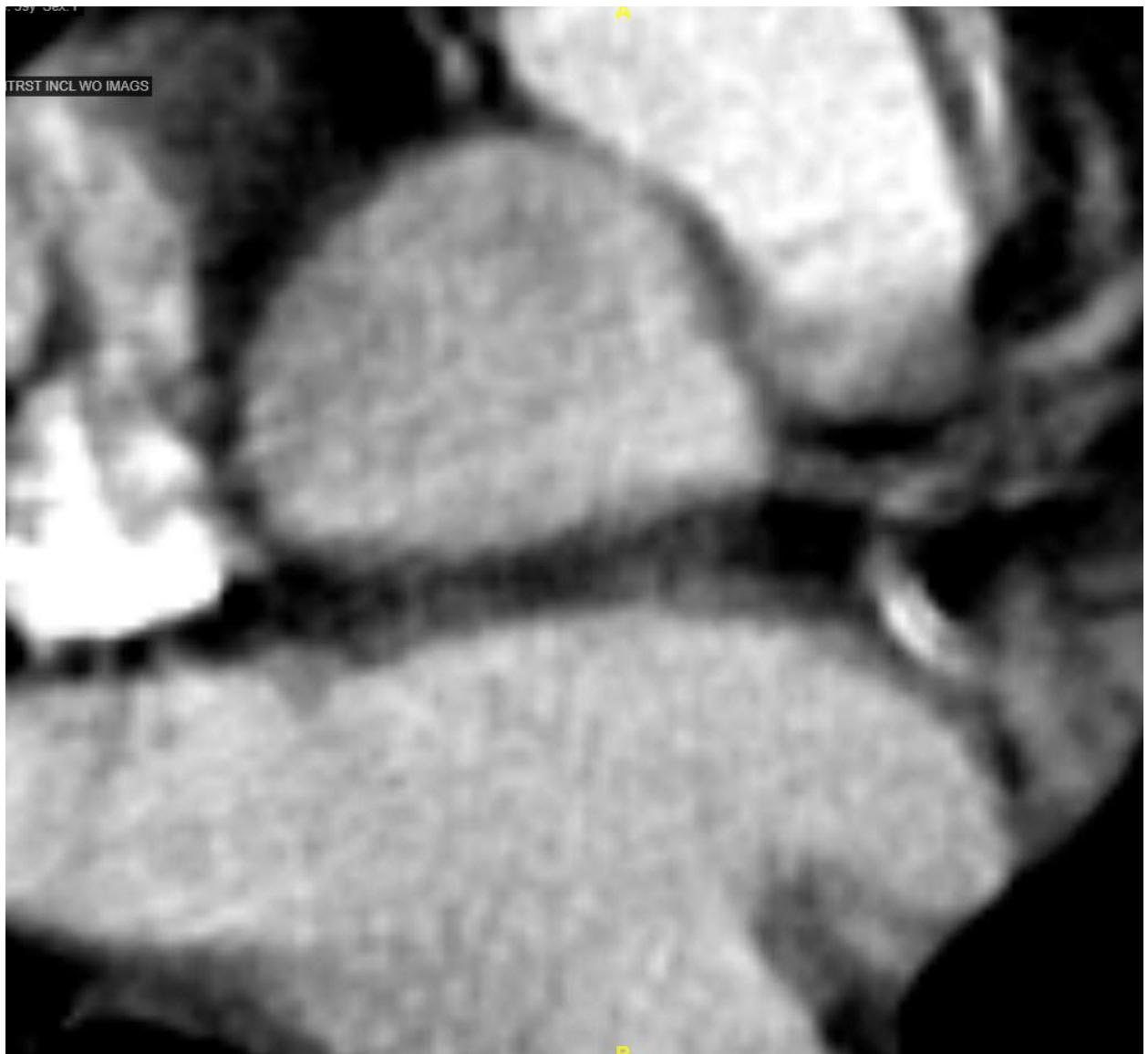## CASE 2

ICA findings: ICA was performed one year prior to chest CT. There is a stent in the LCX that is patent. Proximal and mid RCA segments are occluded. Distal RCA gets collateral from the left side. ICA score: 4.

CT findings: There is a stent in the proximal LCX. Note the stent has a metallic crisscrossed pattern. It is not possible for chest CT to assess for patency. Chest CT score: 3. Risk Class: E.



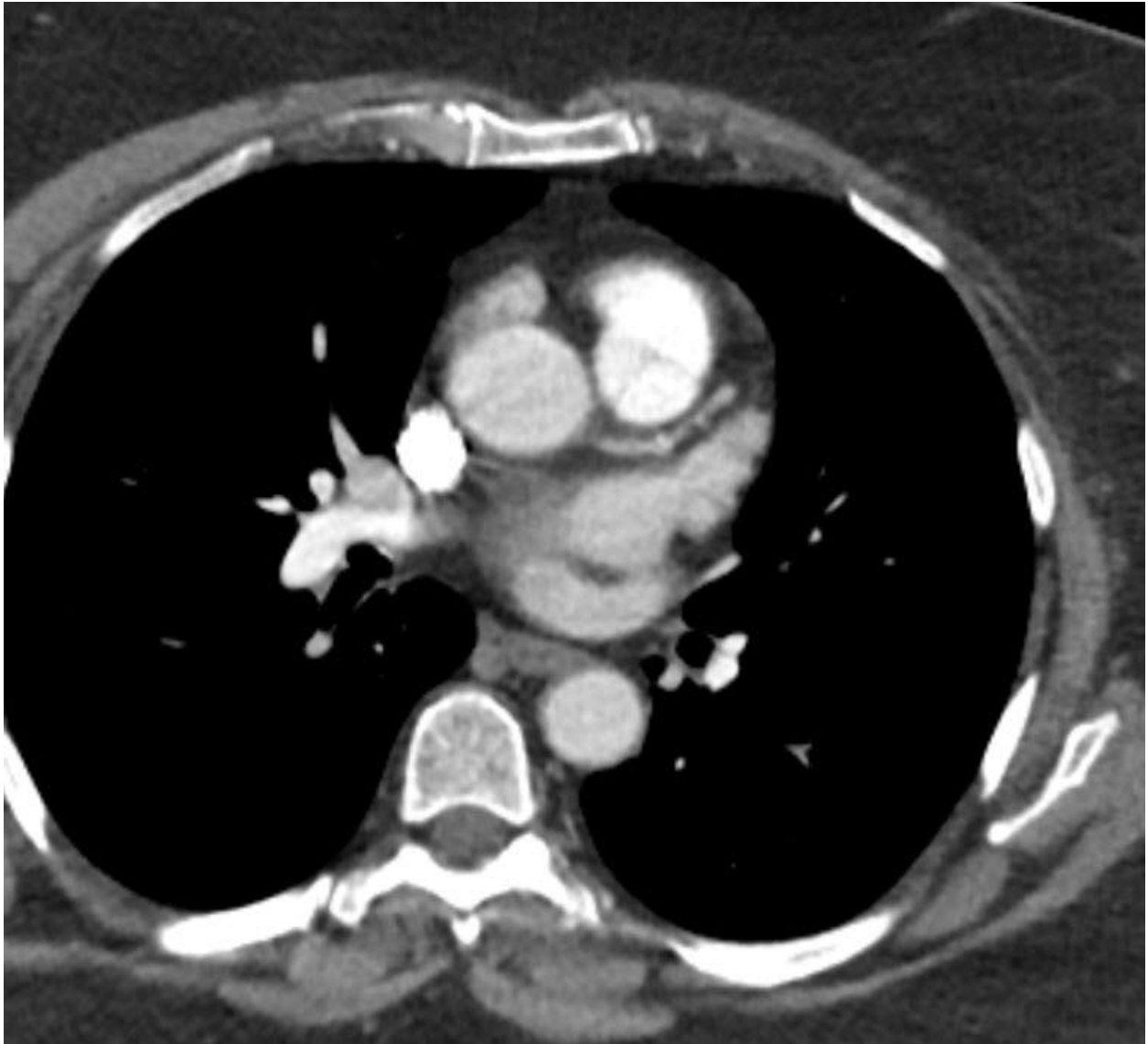




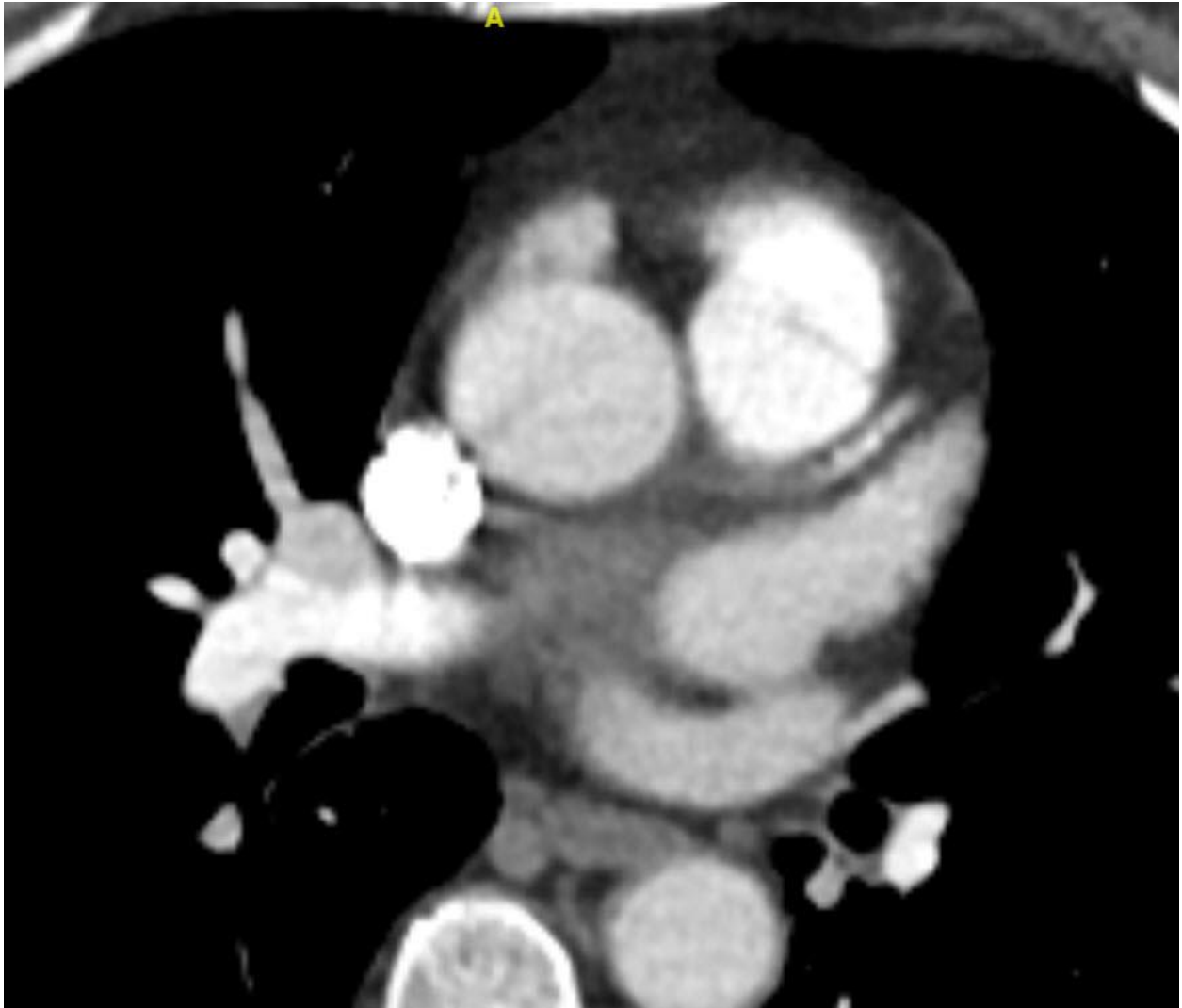### CASE 3

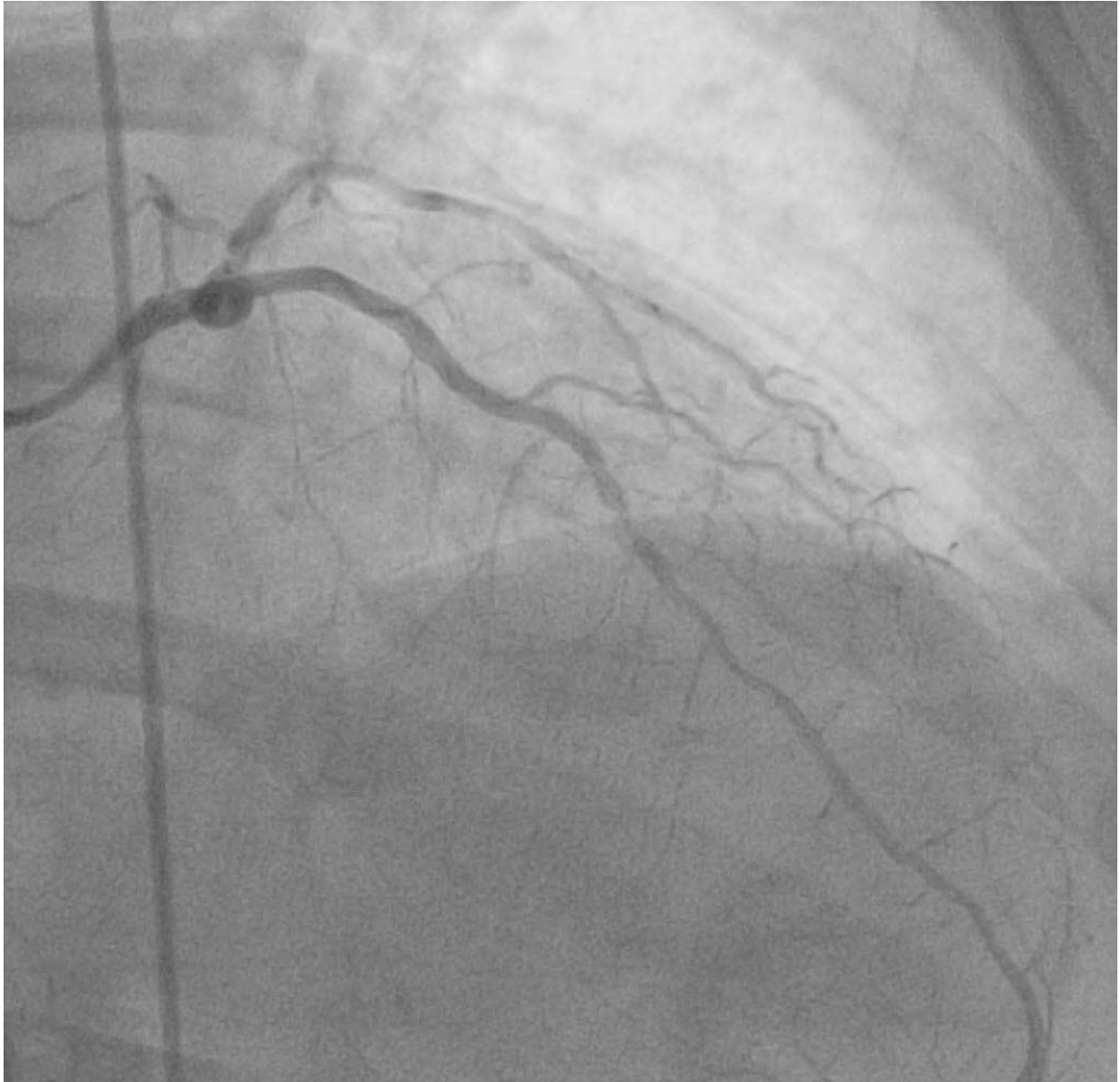Chest CT findings: Chest CT was performed four days before ICA. There is a discrete single lesion of mixed calcific and noncalcific plaque in the mid LAD. There is evidence of positive remodeling. CT score: 3. Risk Class: D.

ICA findings: Patient had ICA for abnormal stress testing and angina. There is a mid LAD stenosis and patient received stenting. ICA score: 3.





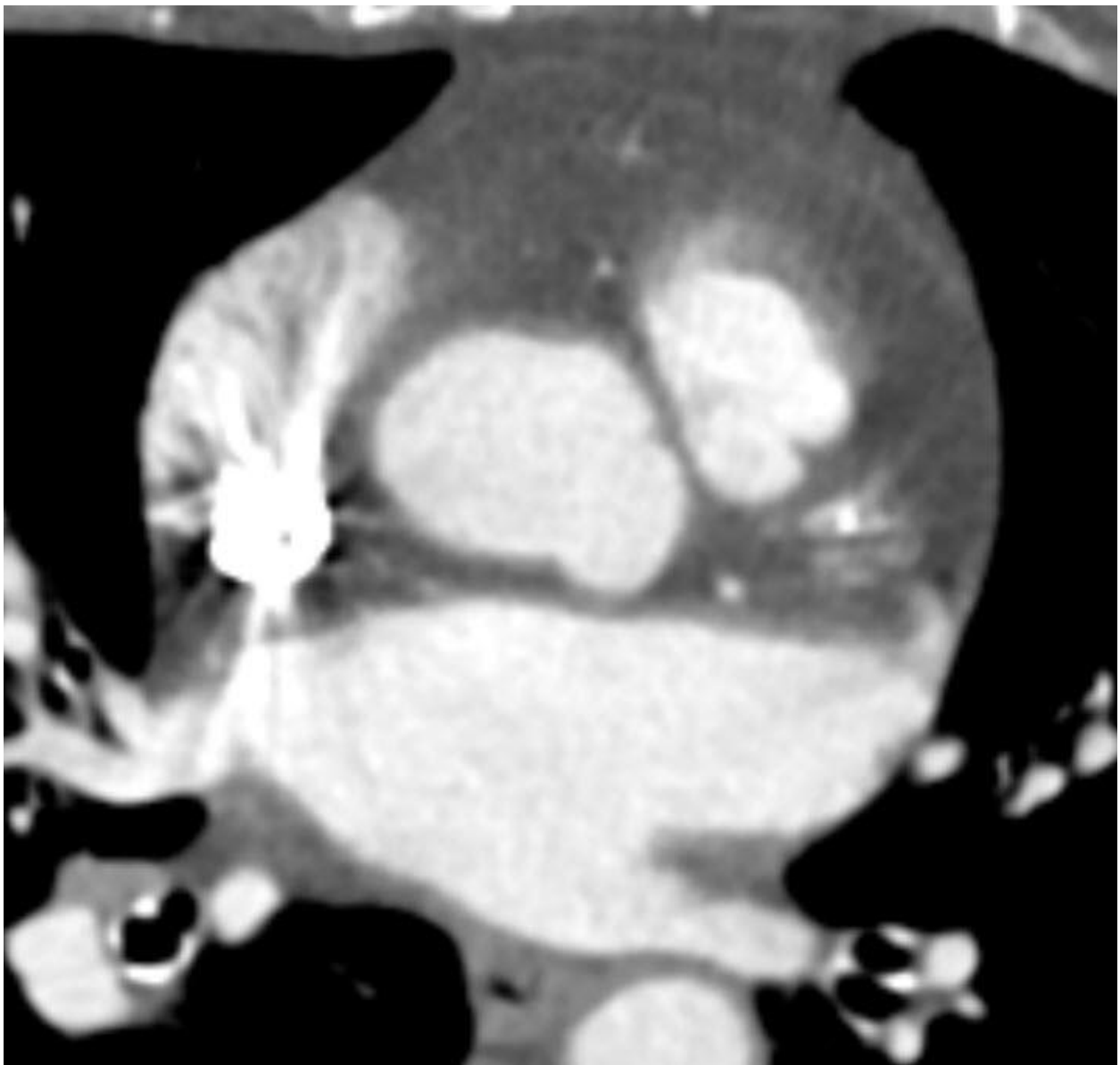


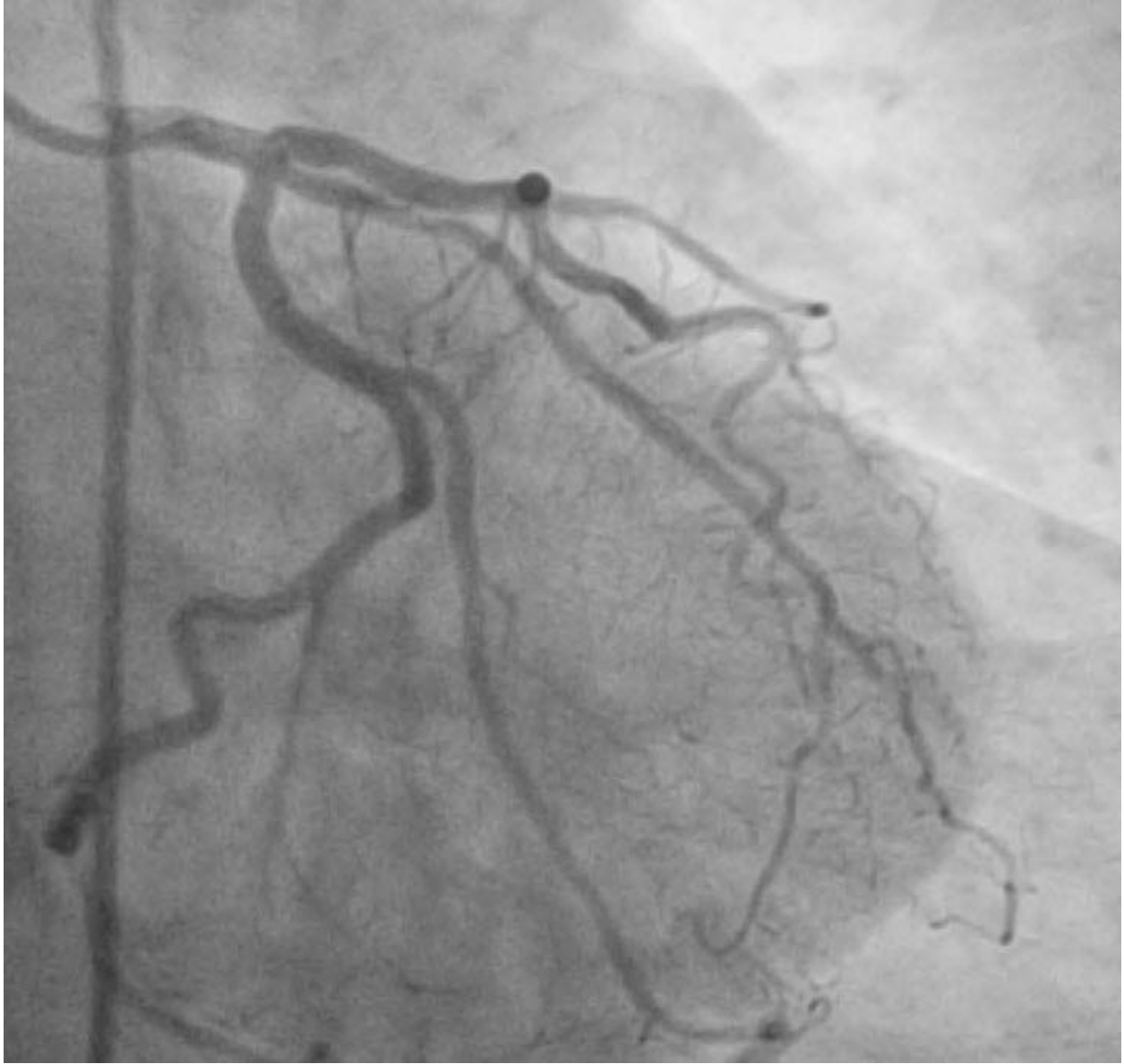

#### CASE 4

Chest CT finding: CT was performed eight months prior to cath. There is obstructive disease of ramus. CT score 3. Risk Class: D.

ICA findings. There is obstructive ramus and patient received stenting. ICA score 3.

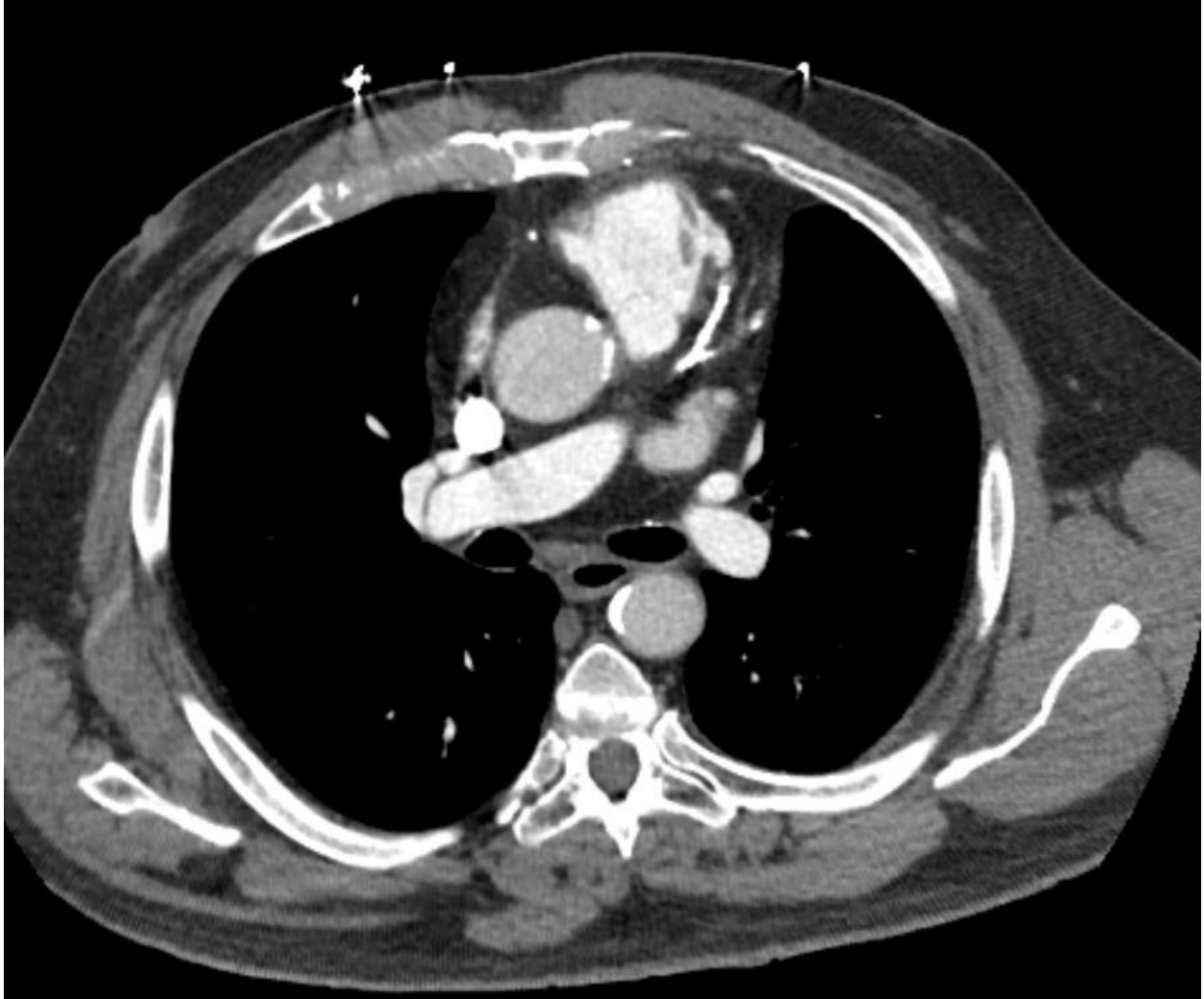


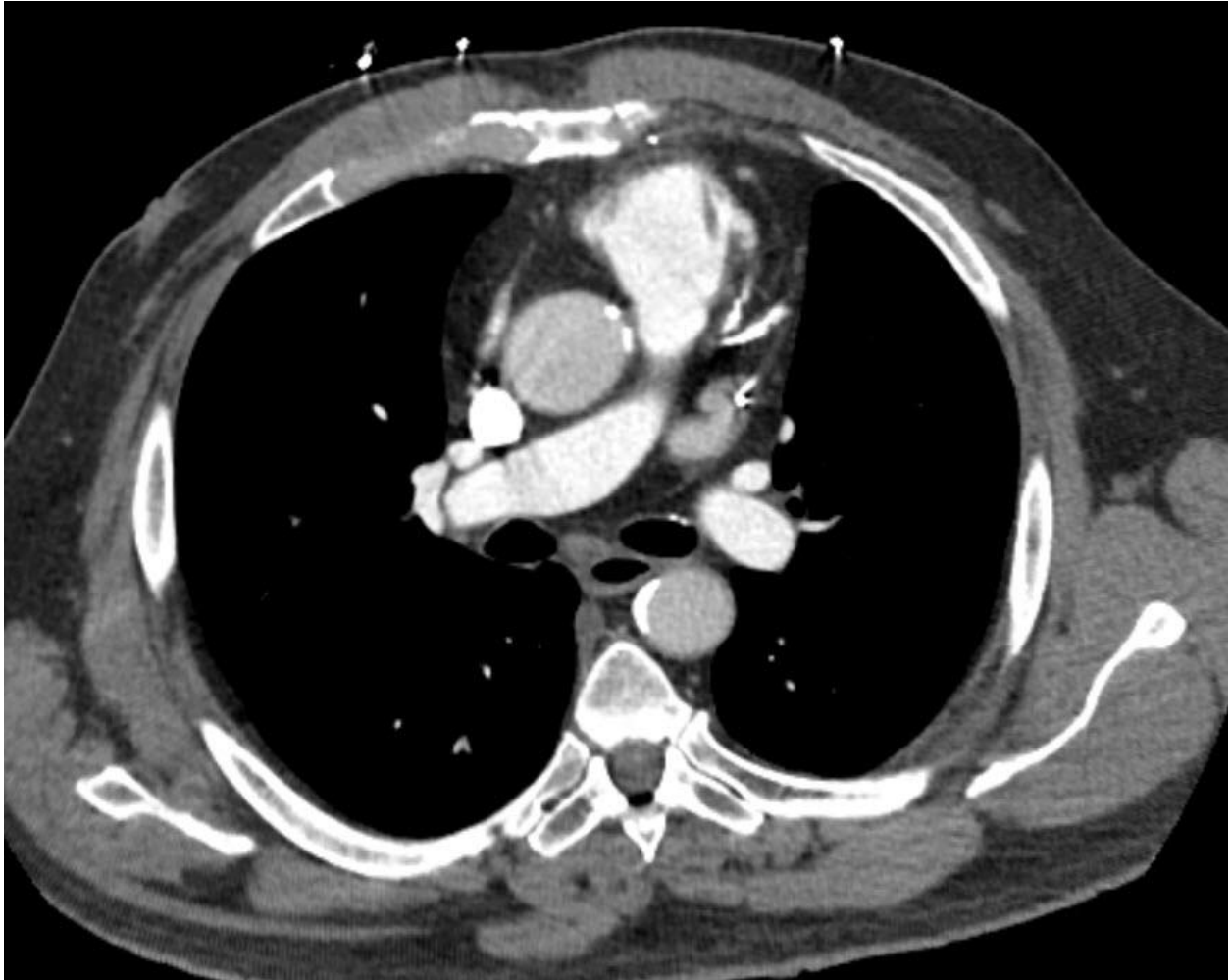

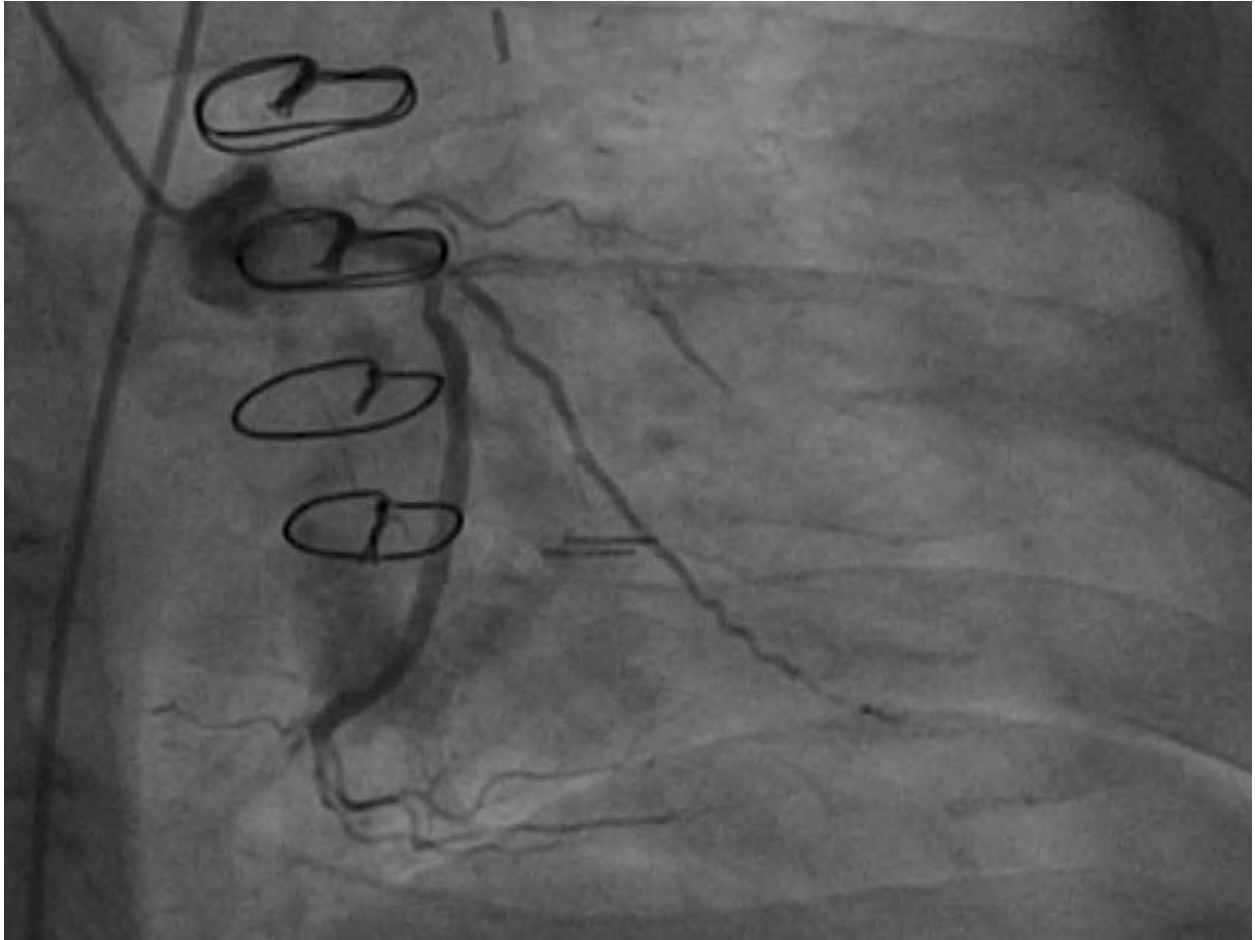
Case 5

Chest CT: CT was performed one year prior to cath. Patient had CABG history. Multivessel disease. Chest CT score: 3. Risk Class: E

ICA: Multivessel disease. ICA score: 4.



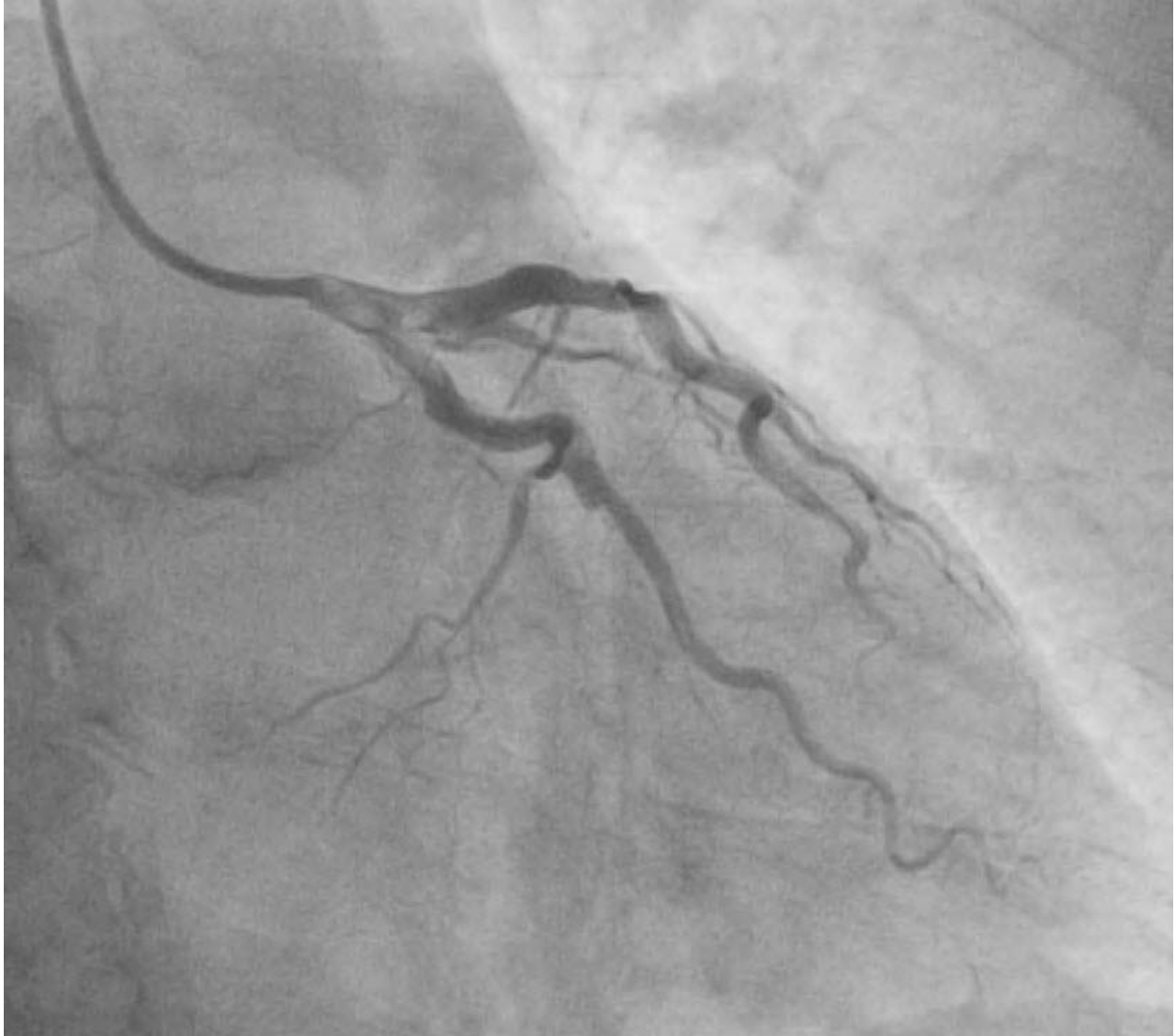



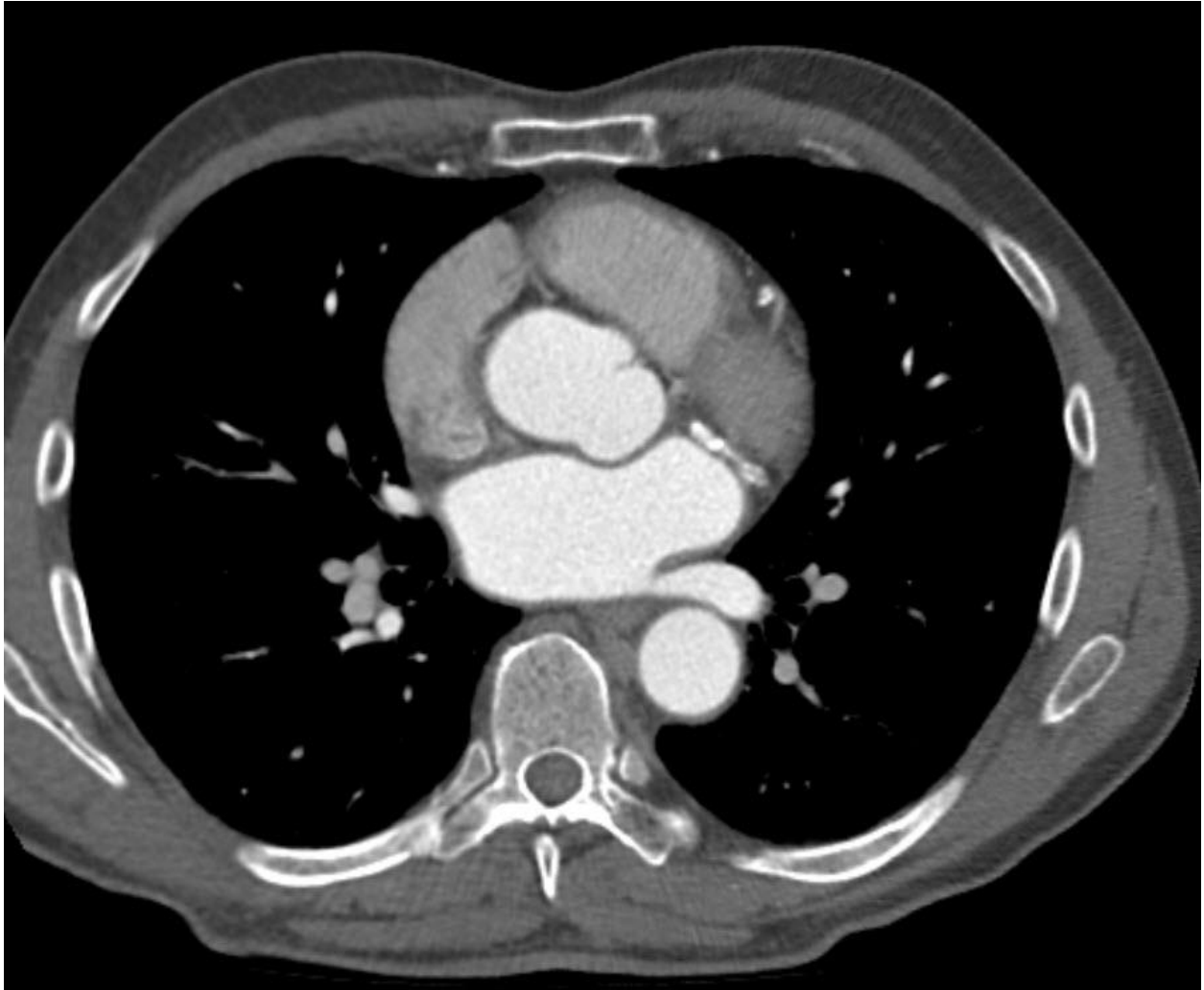
Case 6

ICA findings: ICA was performed 24 days before chest CT. There is a LCX that is 100% occluded. ICA score 4.

Chest CT findings: There is obstructive disease of LCX. ICA 3. Risk Class: D.



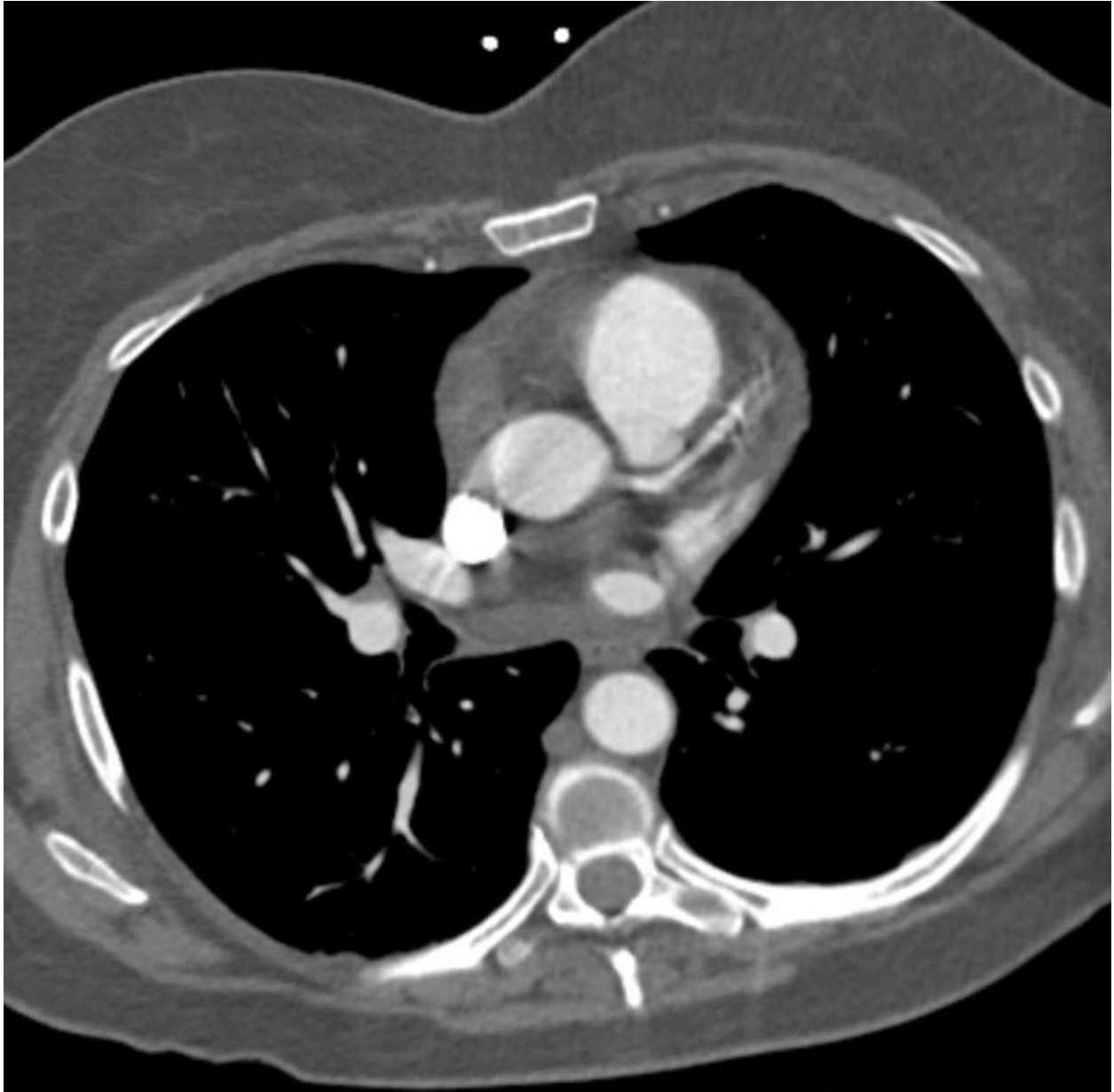


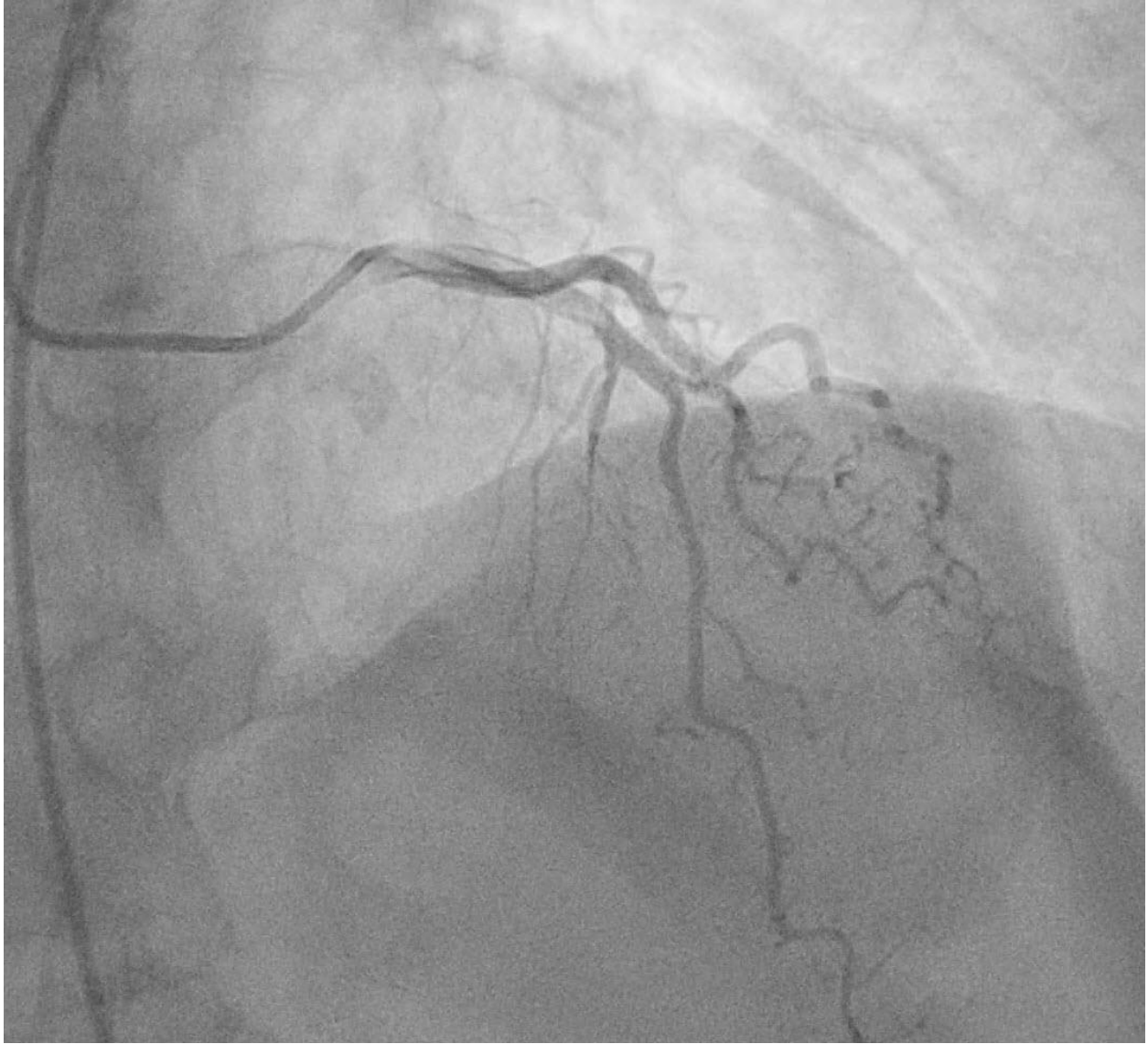

Case 7

Chest CT findings: Chest CT was performed two days prior to ICA. There is blooming artifact in the mid LAD. Chest CT score: 1. Risk Class: B.

ICA finding: Normal coronary anatomy. ICA score: 0.

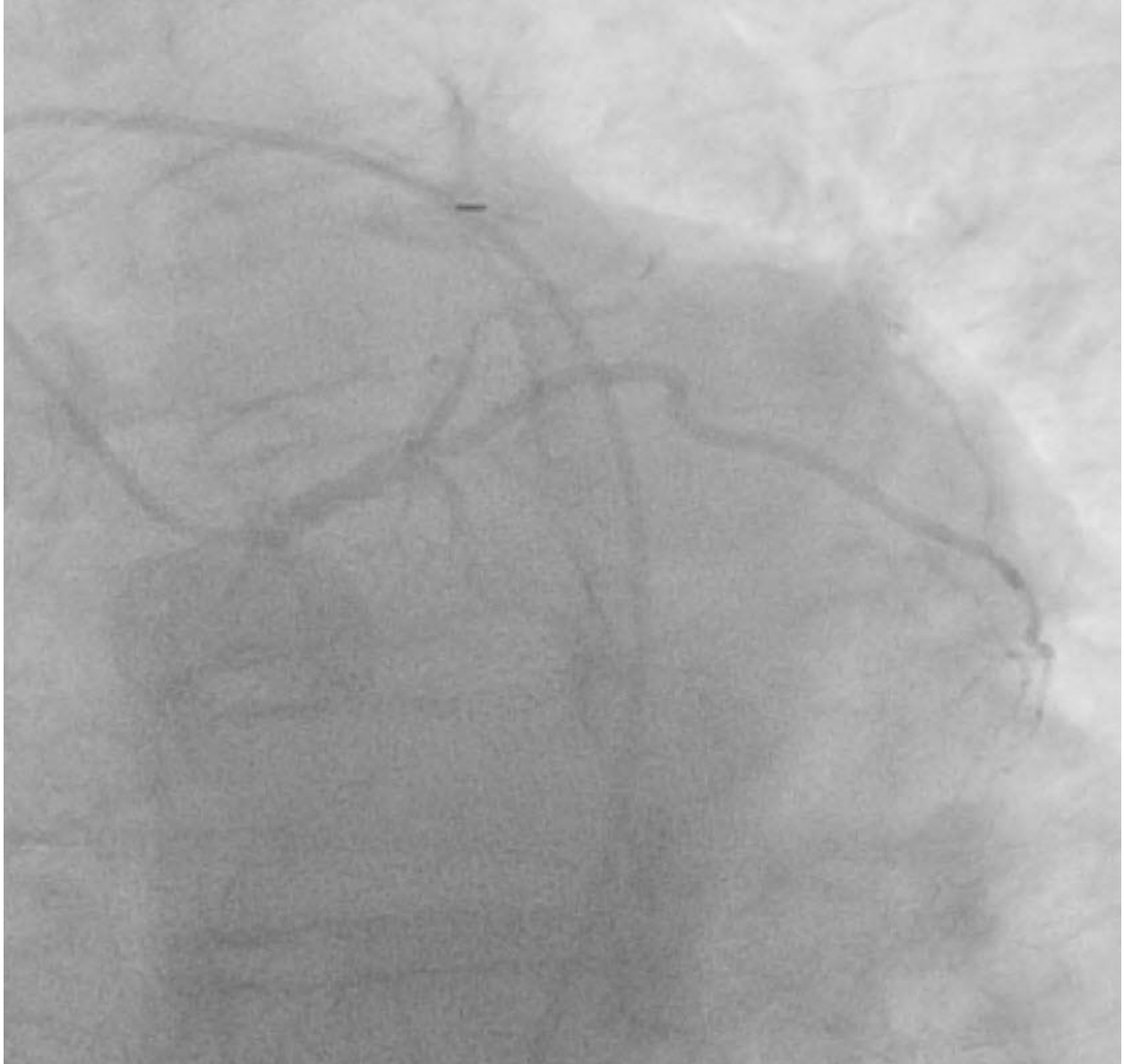


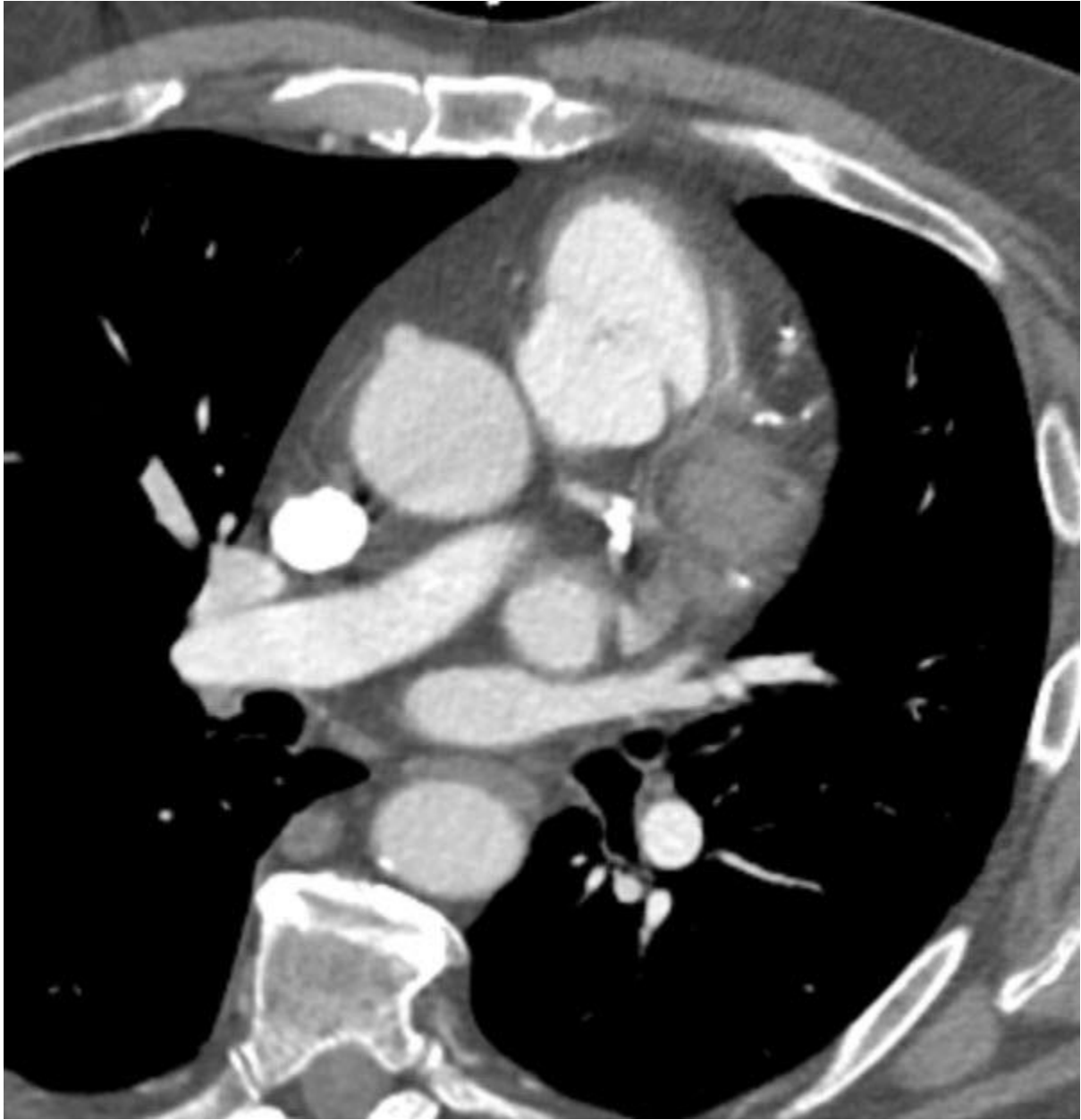

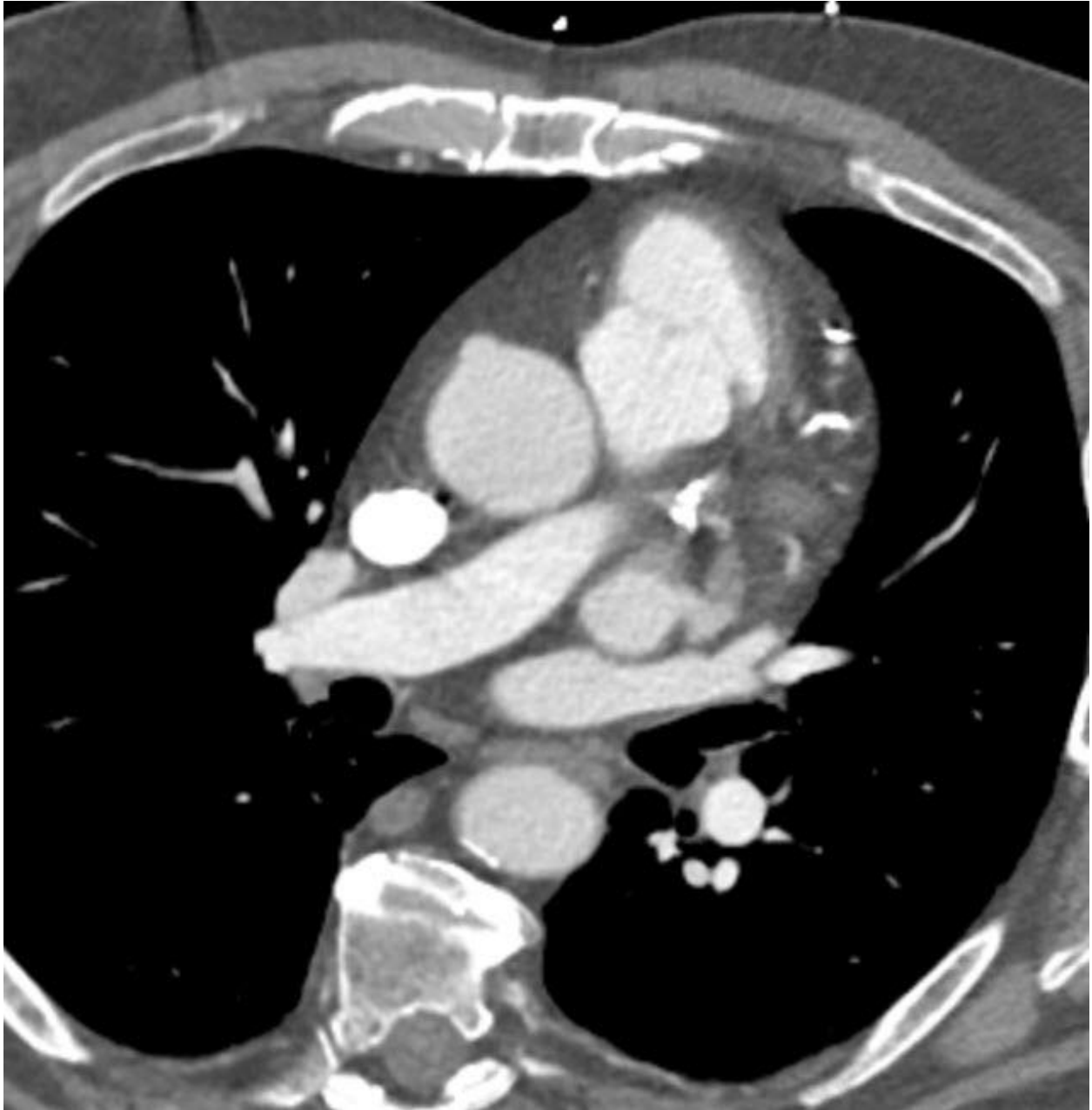
Case 8

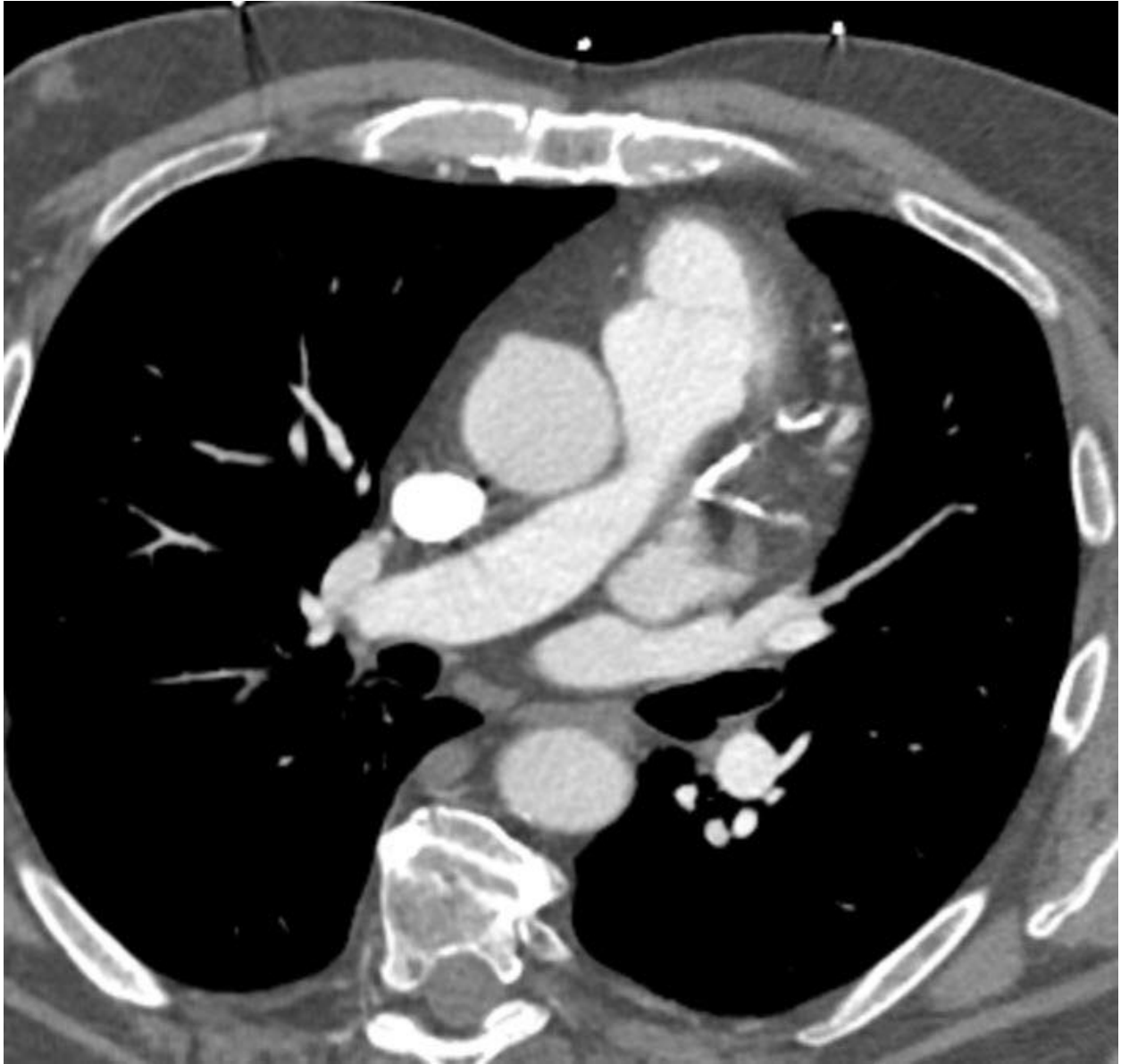ICA findings: ICA was performed six months prior to Chest CT. Patient has CABG with multivessel disease. ICA score: 4

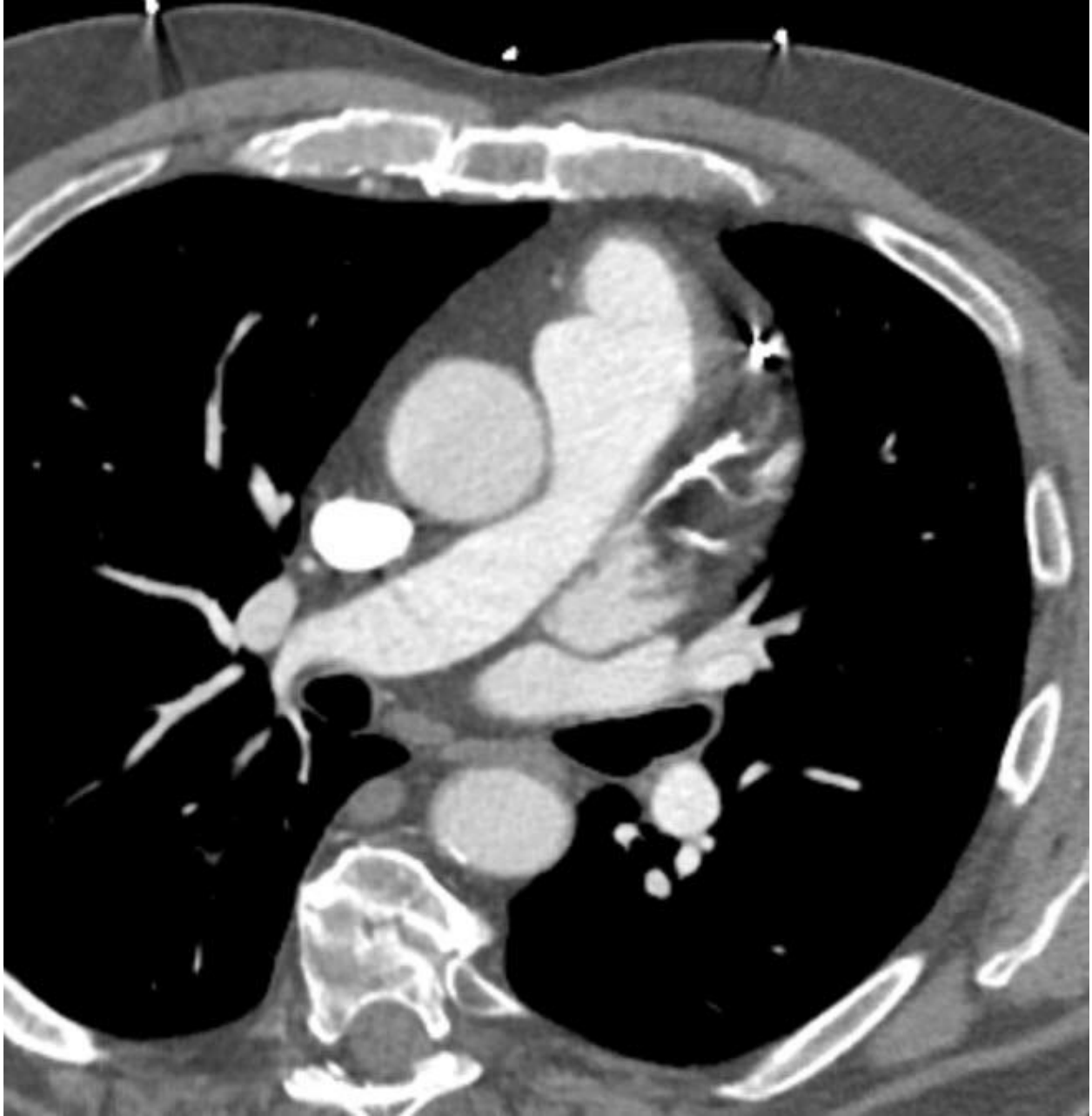
Chest CT findings: Multivessel disease. Chest CT score: 3. Risk Class: E.









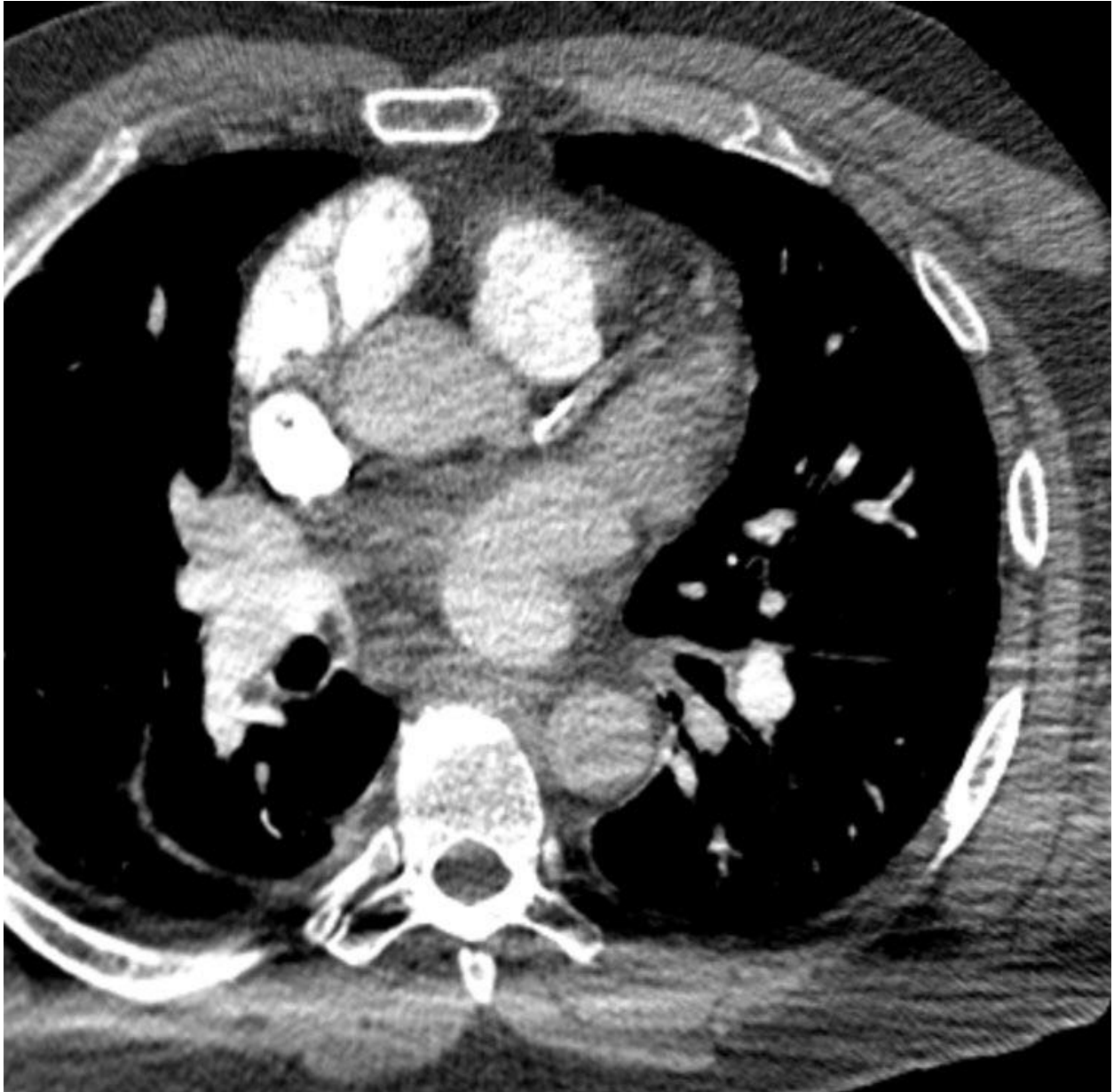


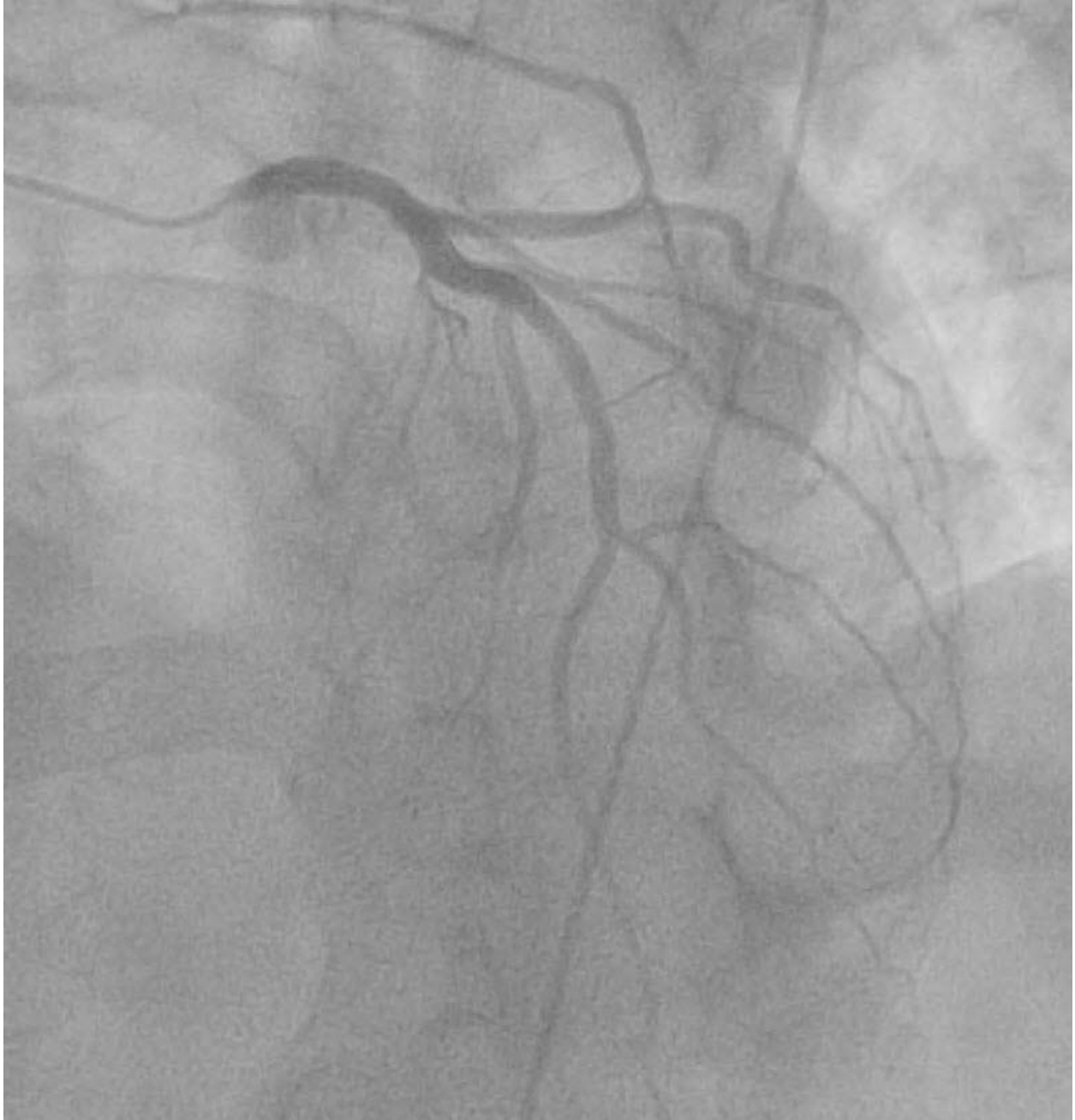


Case 9

Chest CT findings: Chest CT was performed on the same day of the ICA. This is a mild calcific plaque in the proximal LAD. Chest CT score: 1. Risk Class B.

ICA findings. Normal. ICA score: 0.

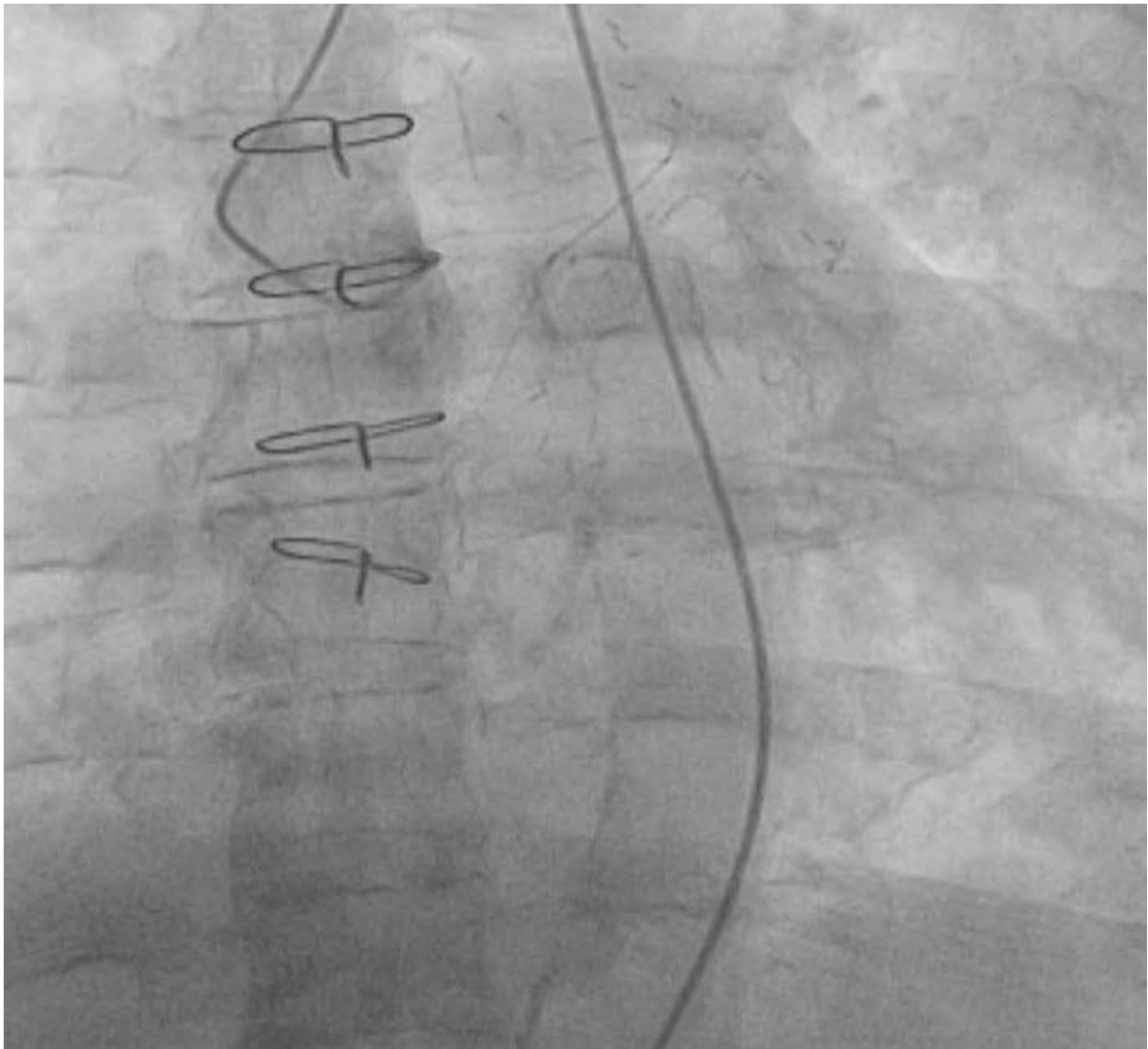


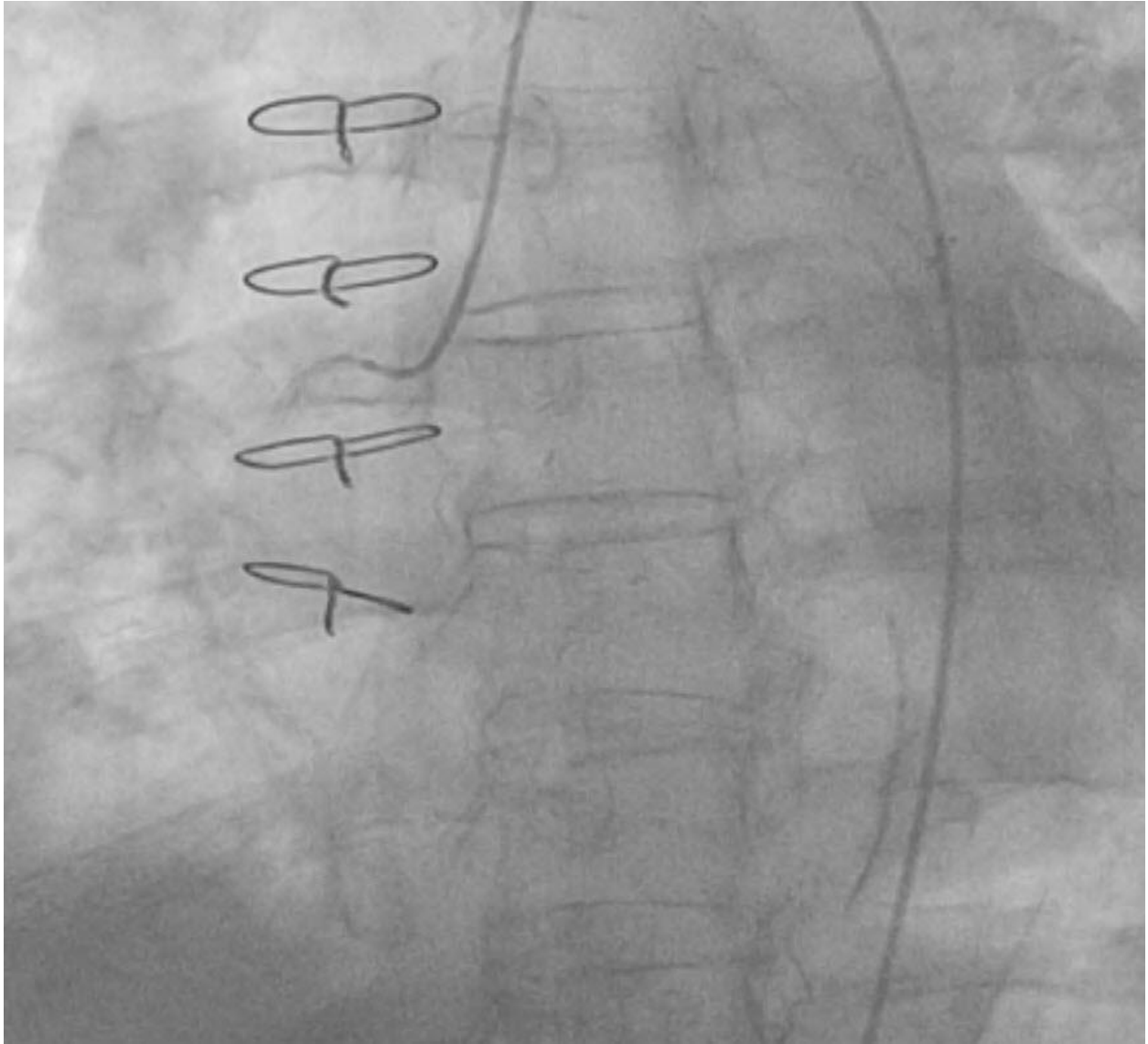


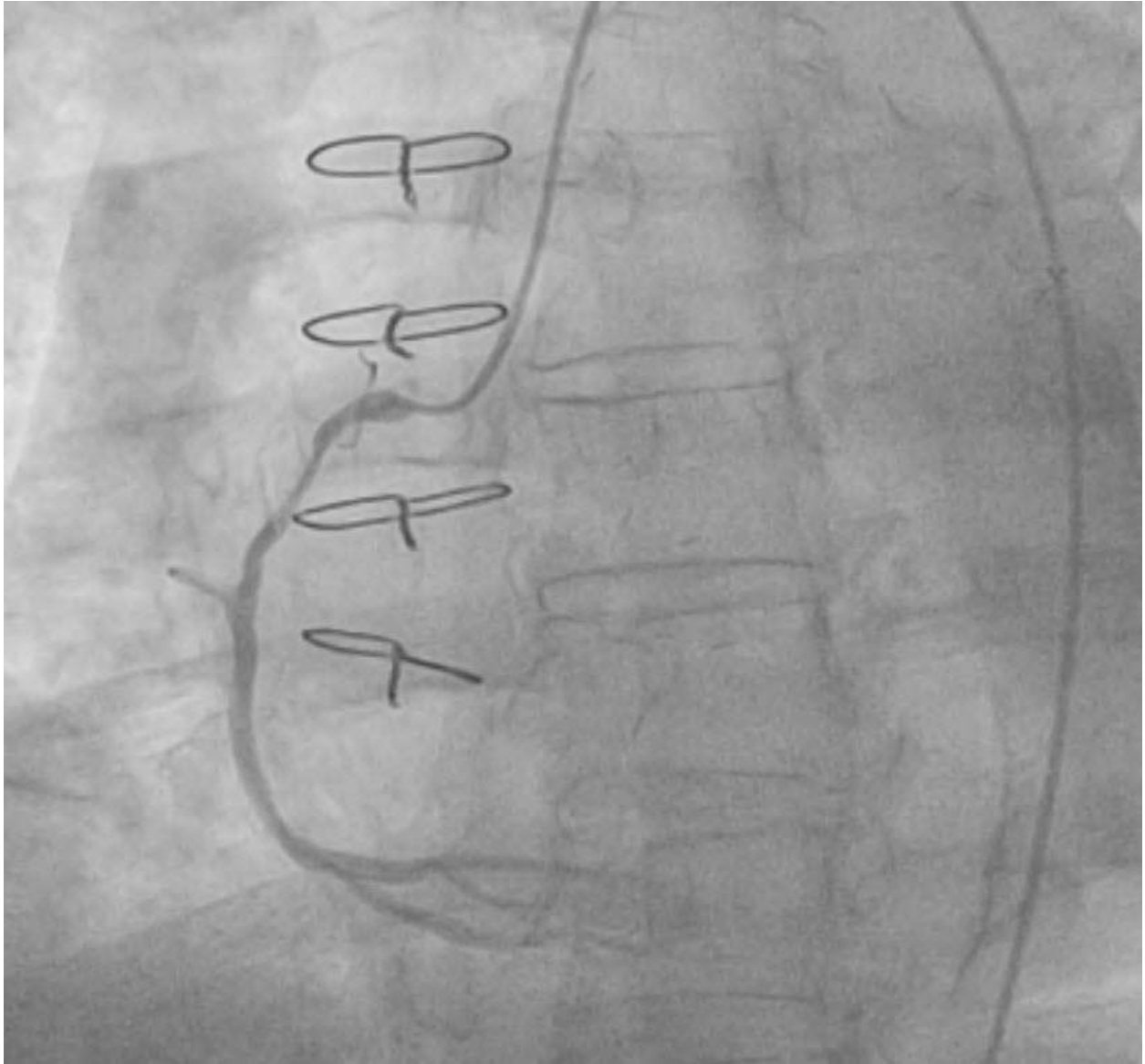
Case 10

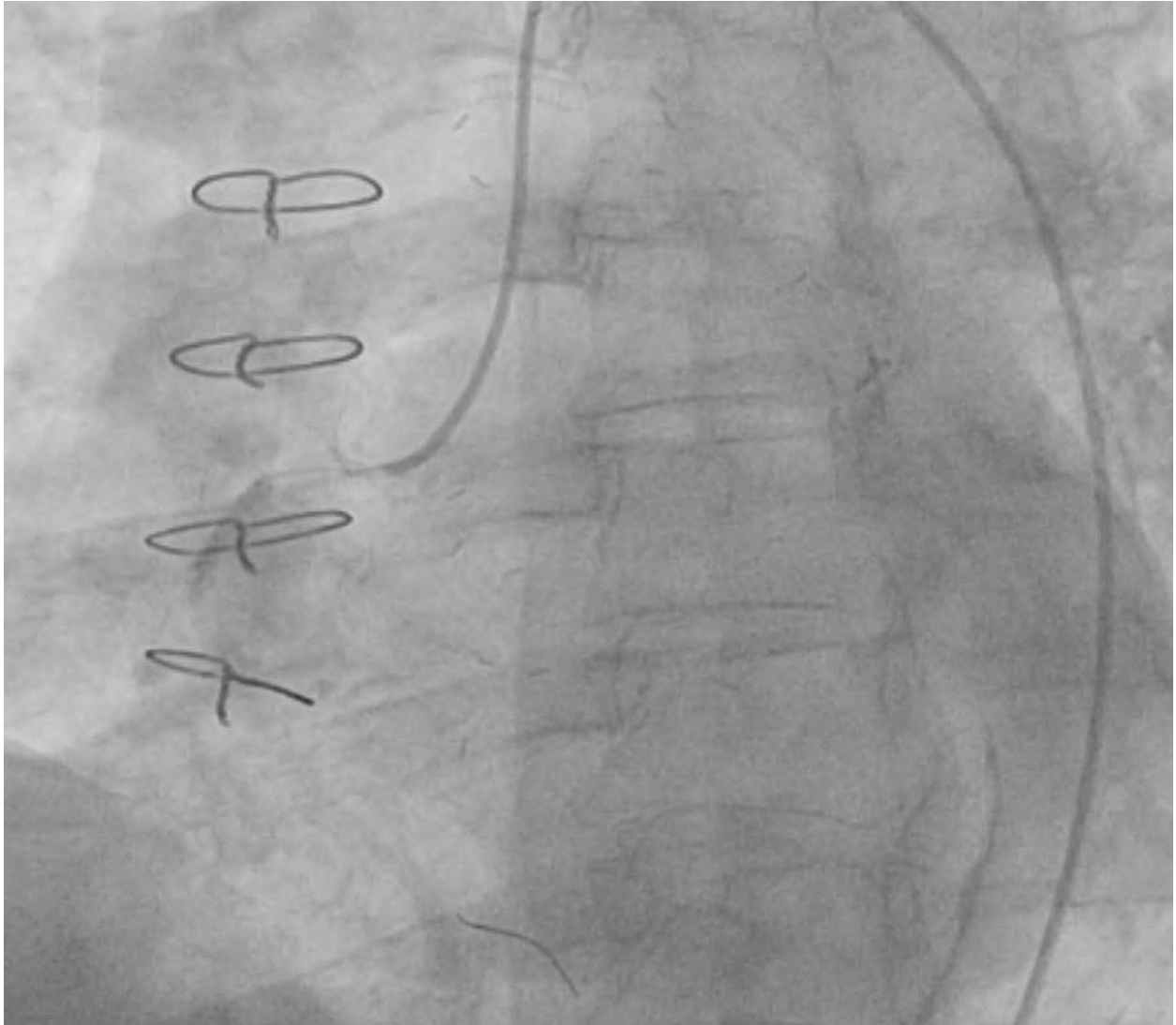
ICA findings: ICA was performed four years before the Chest CT. Patient has a CABG and cardiac stenting history. There is 80% stenosis of the RCA and patient had stenting. Left coronary anatomy is completely obstructed. ICA score 4.

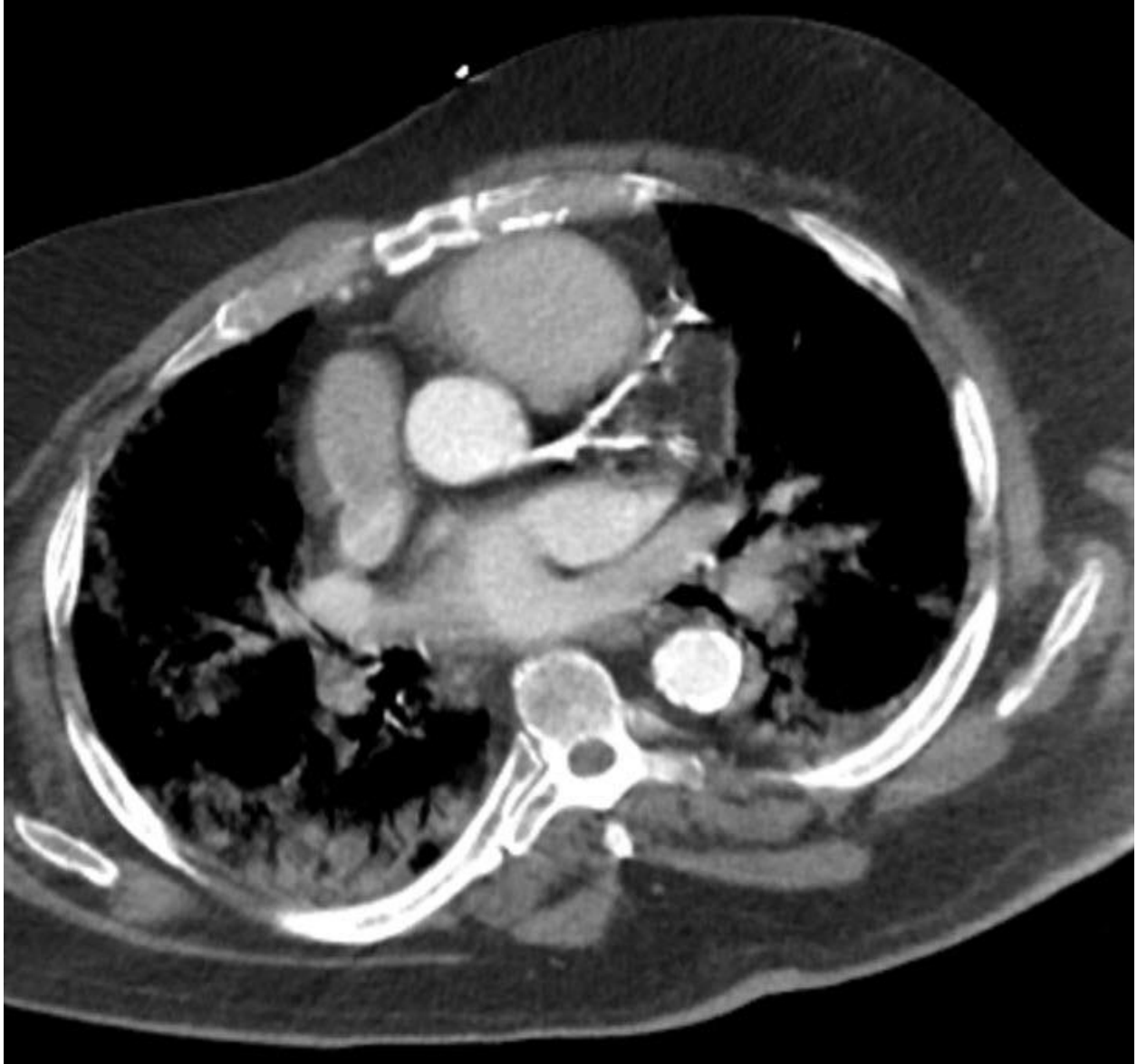Chest CT findings. Diffuse disease of LM, LAD and LCX. There is a stent in RCA. Please note that Chest CT cannot assess for stent patency. Chest CT score 3. Risk Class: E.



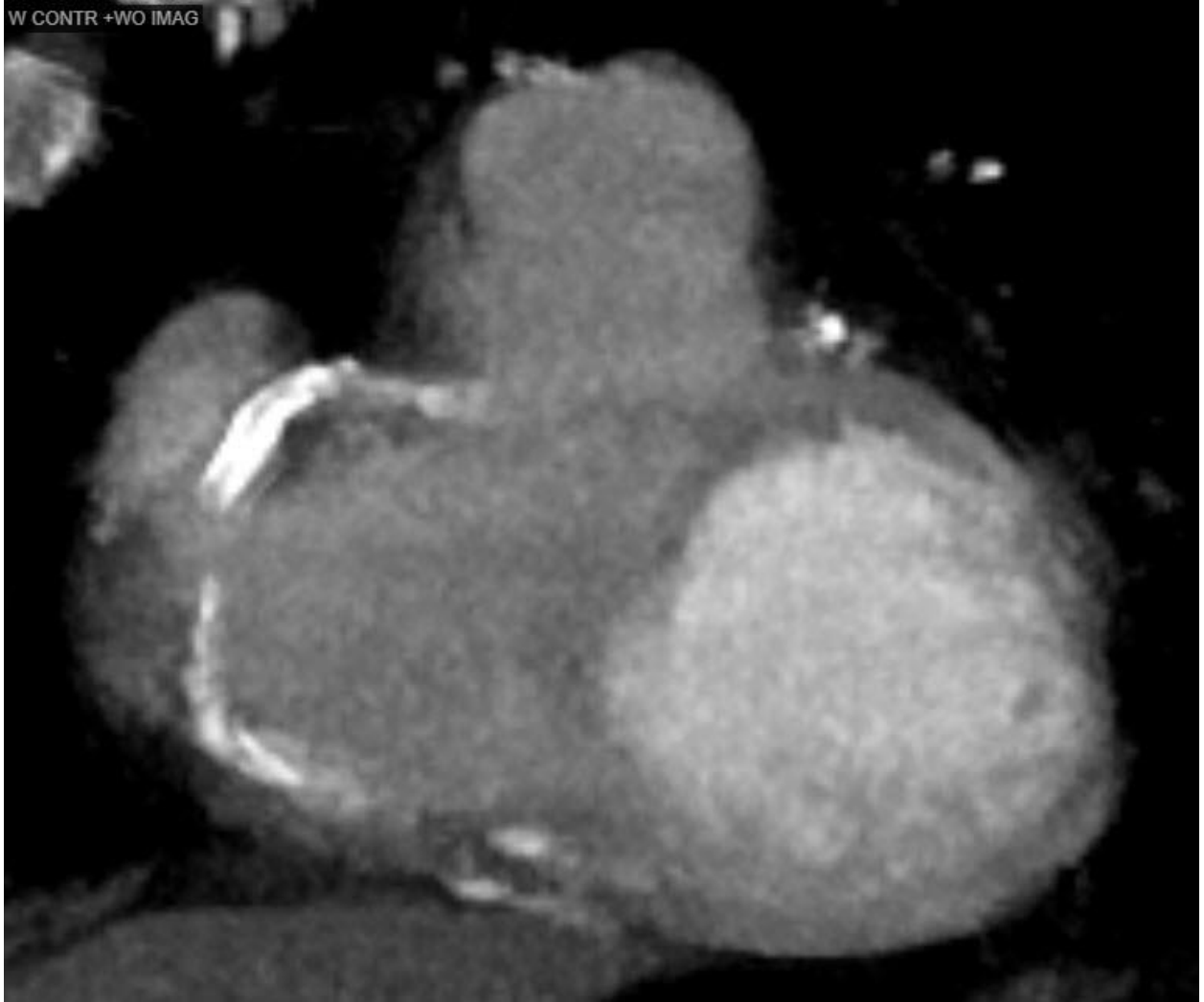








W CONTR +WO IMAG

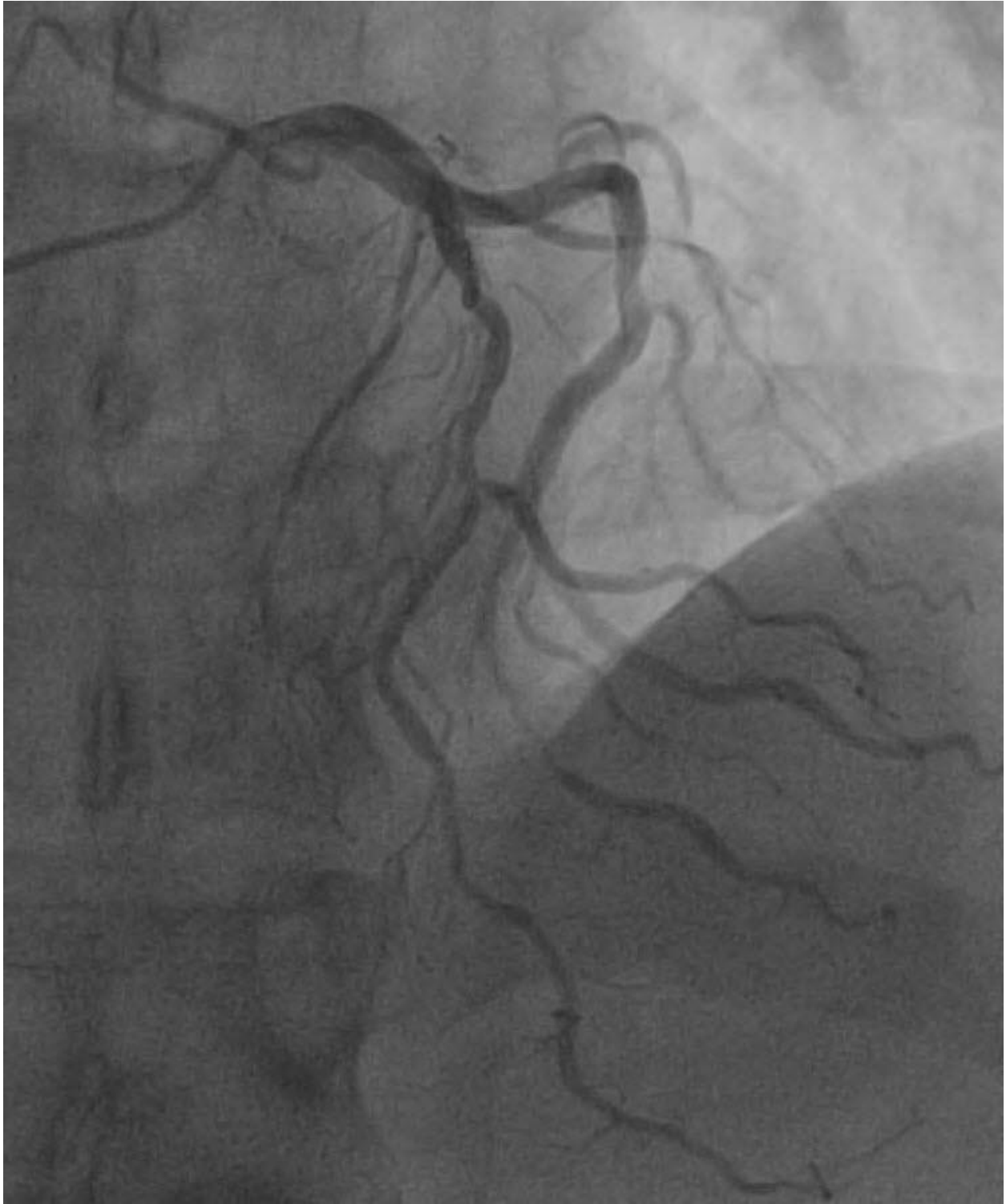

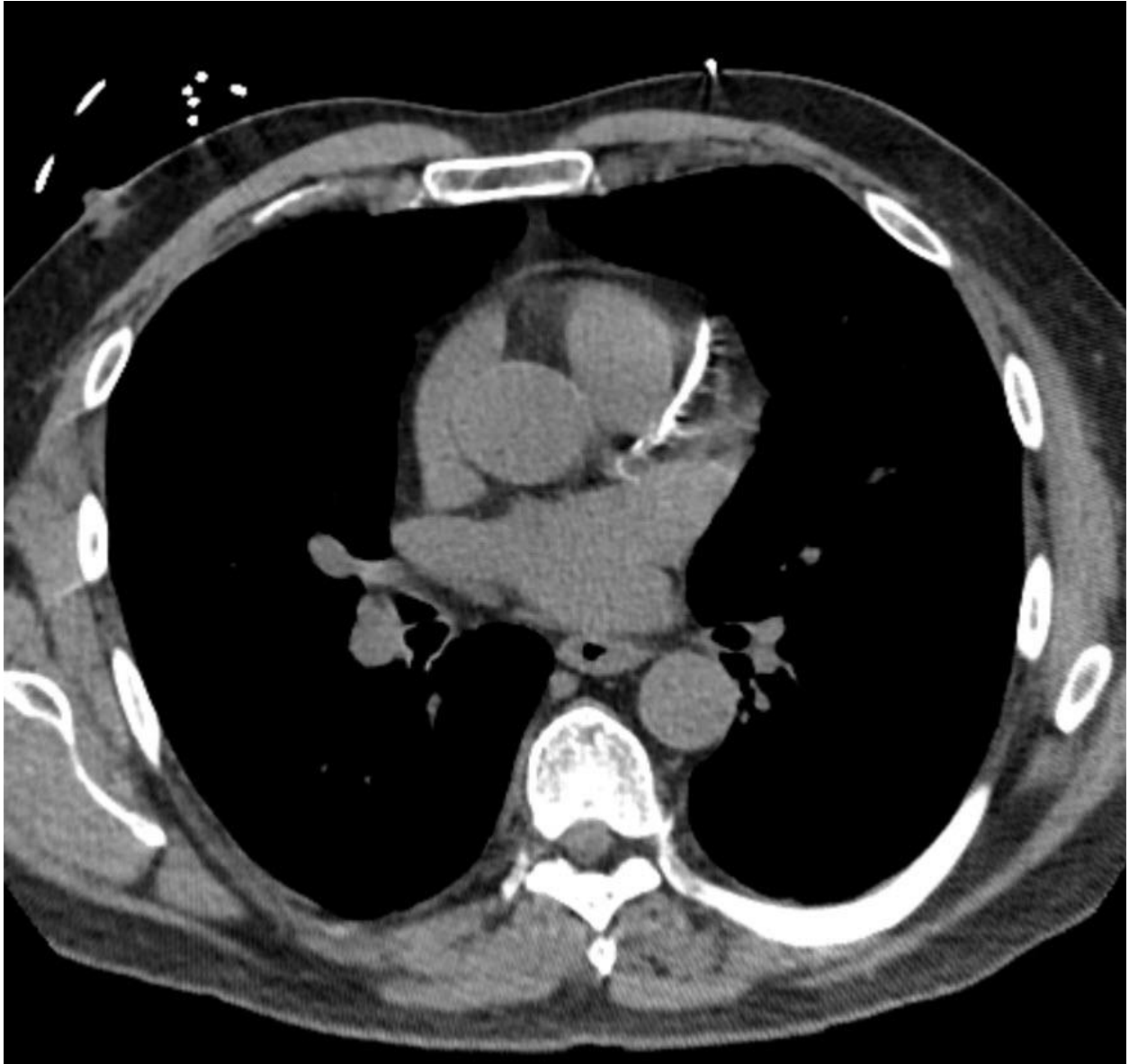


## Case 12

ICA findings: ICA was performed two days before Chest CT. Mid LAD is tortuous and has moderate disease. ICA score: 2.

Chest CT: Heavy calcification of mid LAD. Chest CT score: 2. Risk D. It may not be possible to distinguish visually moderate from severe obstructive disease. The best clue that a patient might have obstructive disease is the high number of segments involved. If there is only one suspicious calcified plaque, it is possible but not likely that the patient has obstructive CAD.





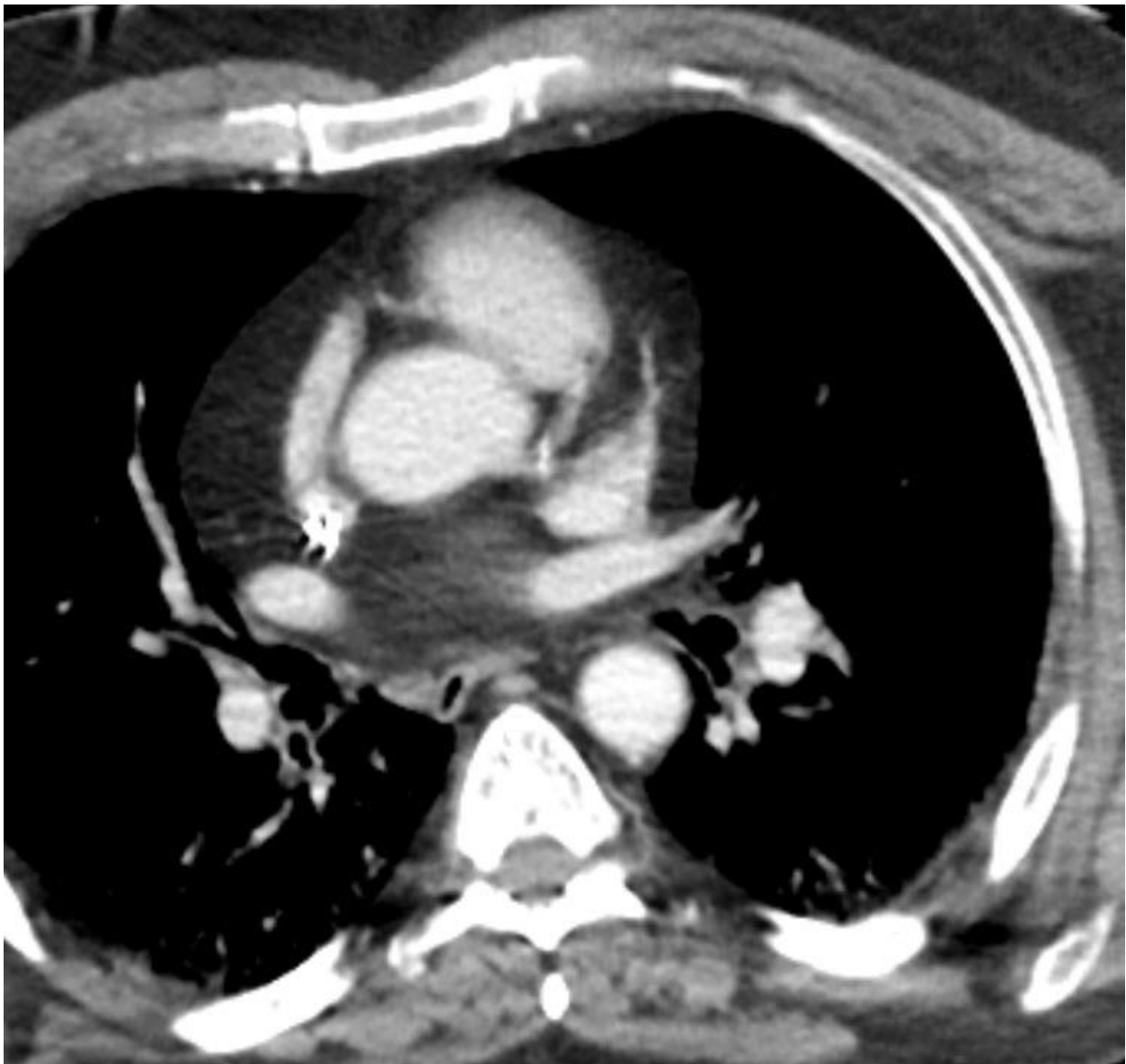
Case 13

Chest CT findings: Multiple CTs done before the ICA show multiple possible manifestations due to motion artifact and the presence of contrast on the same patient. Mild disease of LAD. Chest CT score: 1. Risk Class: B.

ICA findings: Mild disease of LAD. ICA score 1.

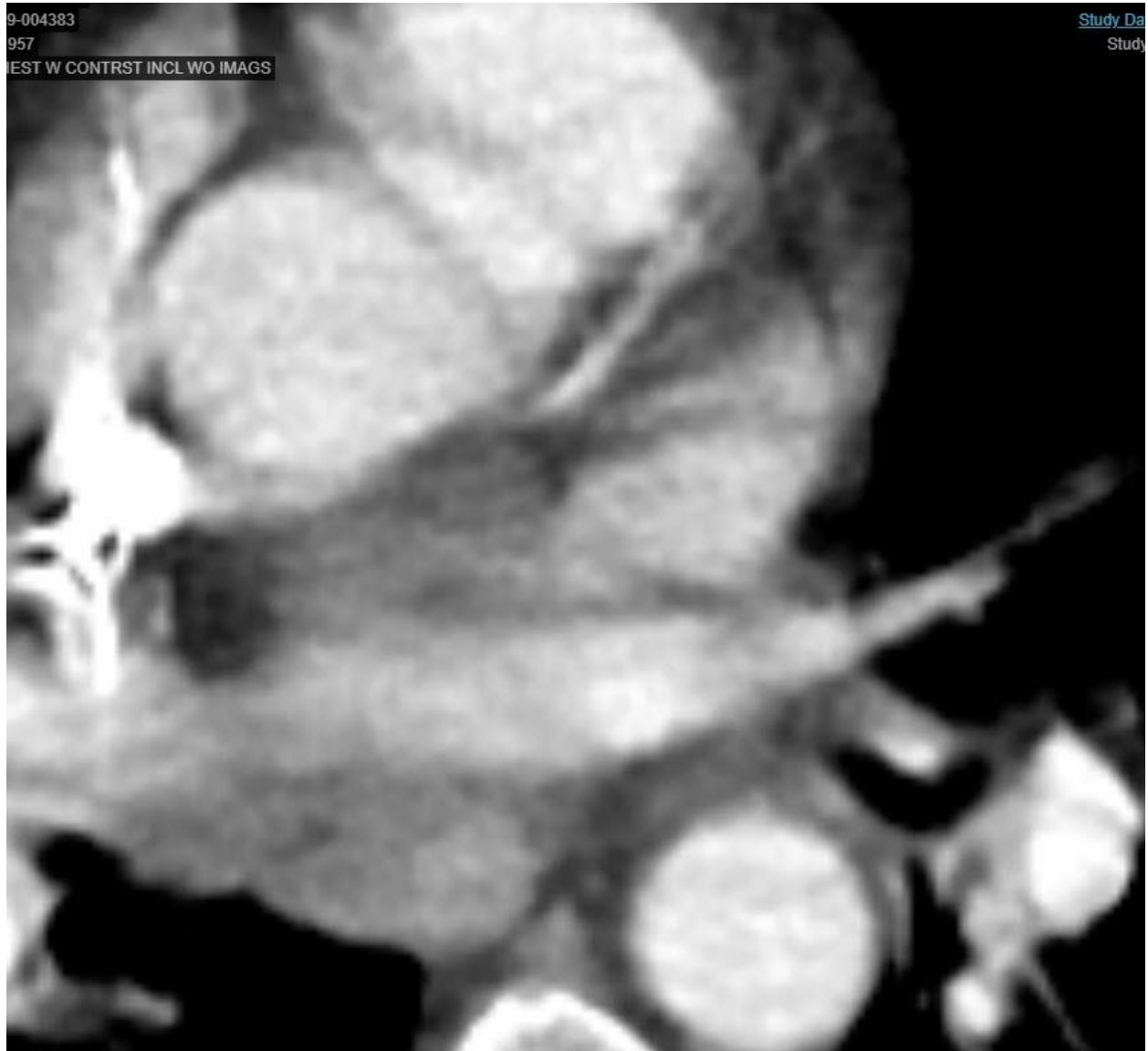Chest CT case 13.1

9 months before ICA. Contrast images.



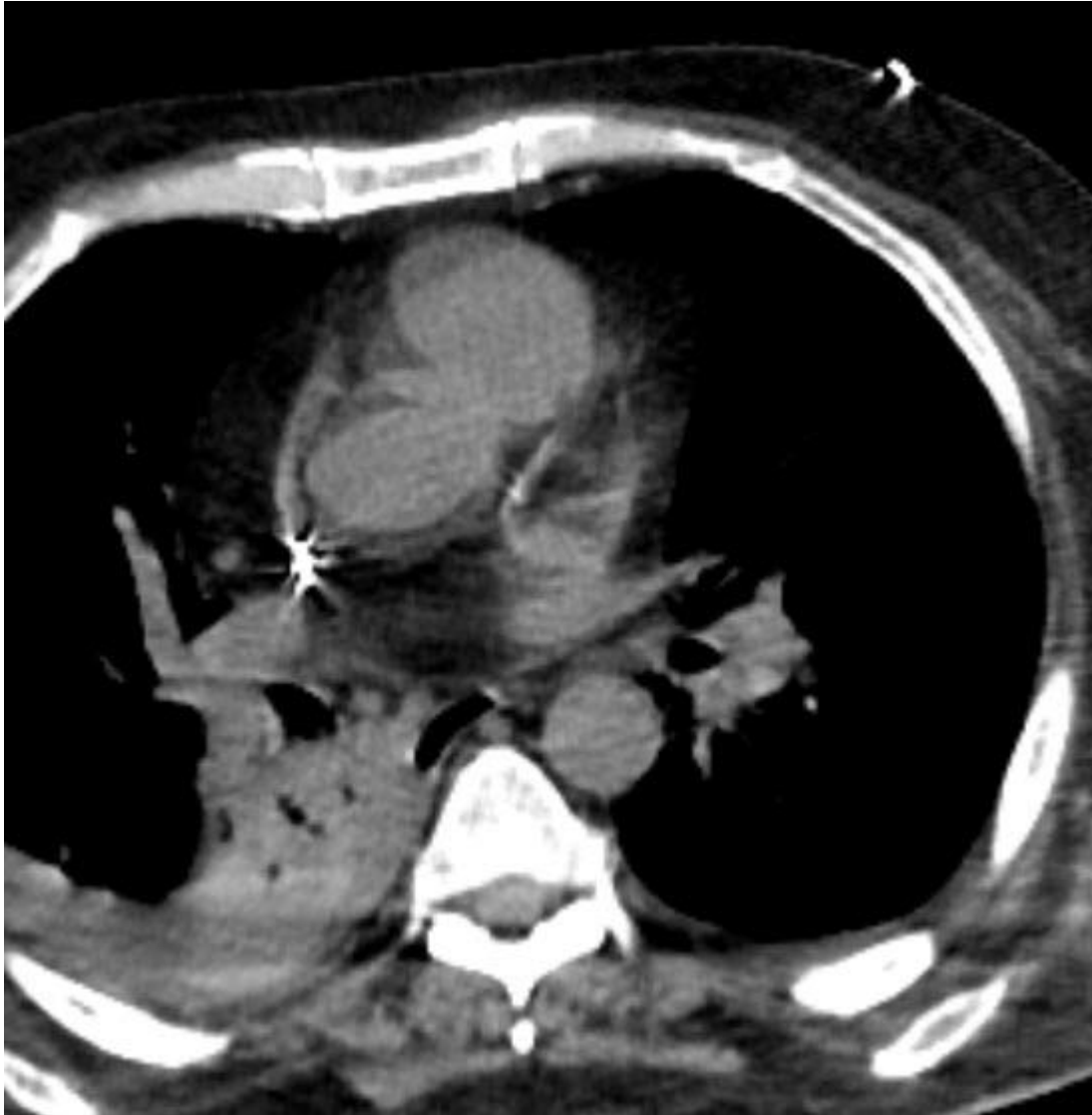Chest CT case 13.2

Nine months before ICA. Images are poor in quality due to motion artifact. Whether there is a presence of calcified plaque is not obvious.



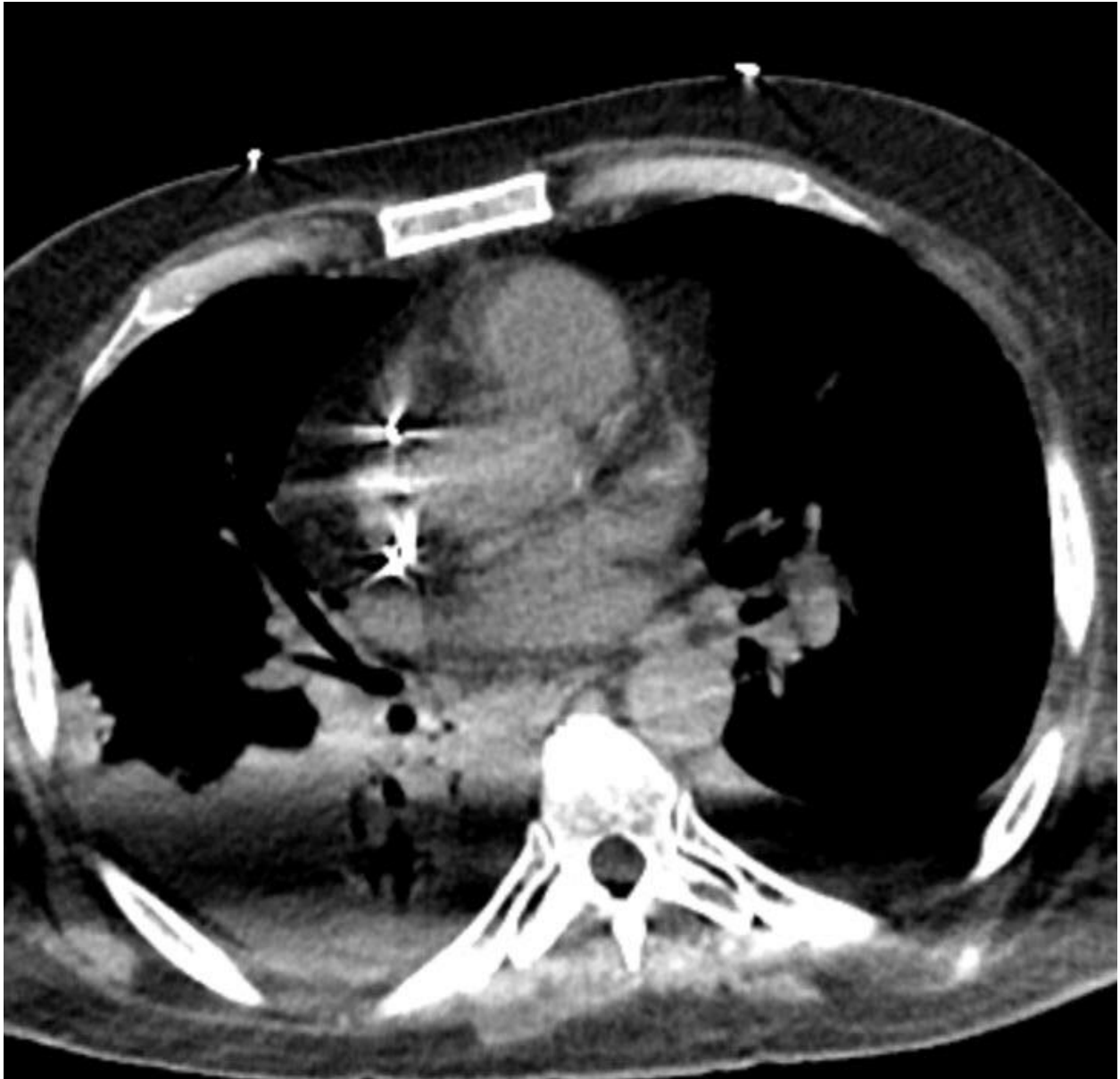Chest CT case 13.3

Eight months before ICA. Non contrast images.



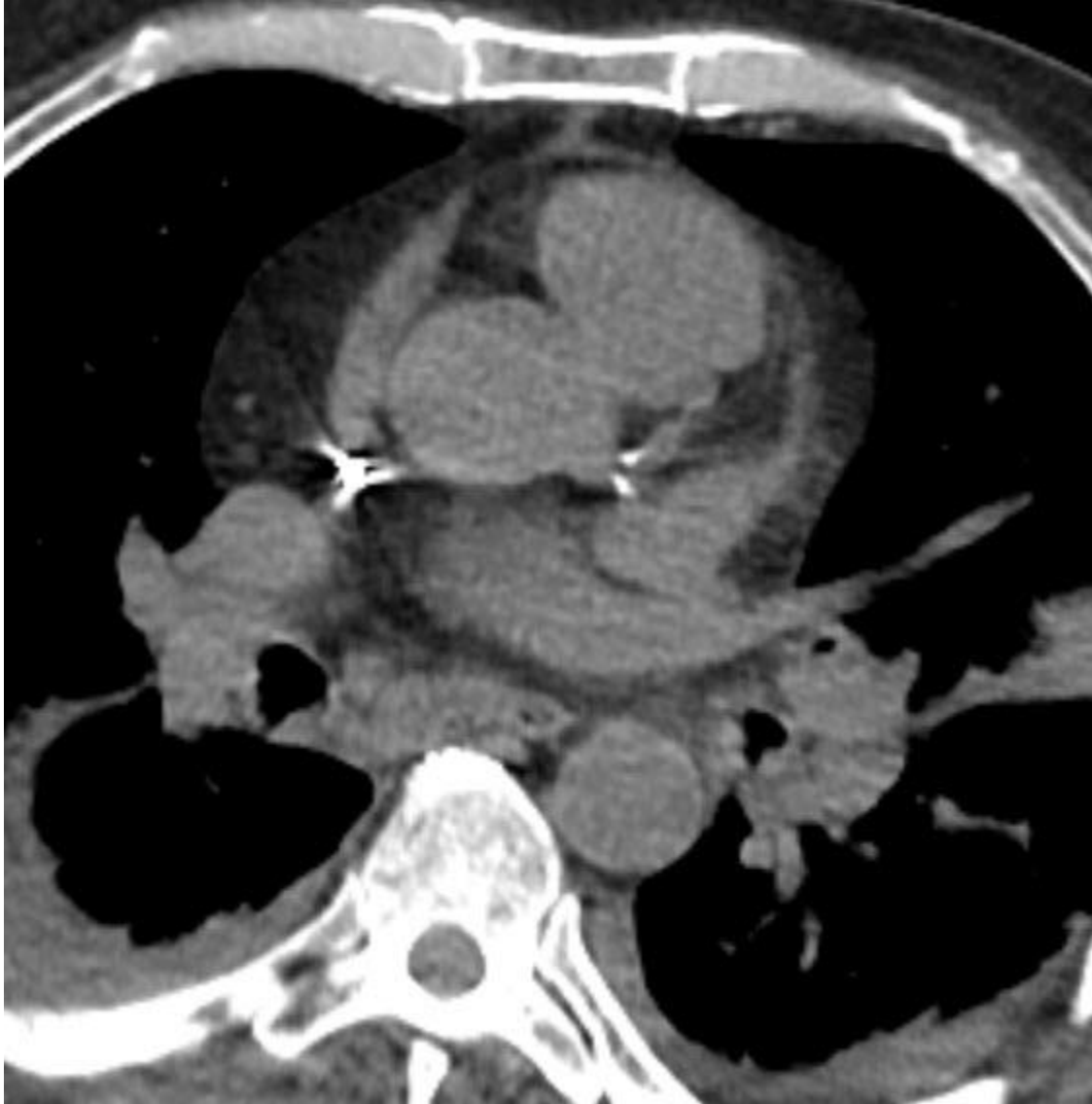Chest CT case 13.4

Seven months before ICA. Non contrast images.

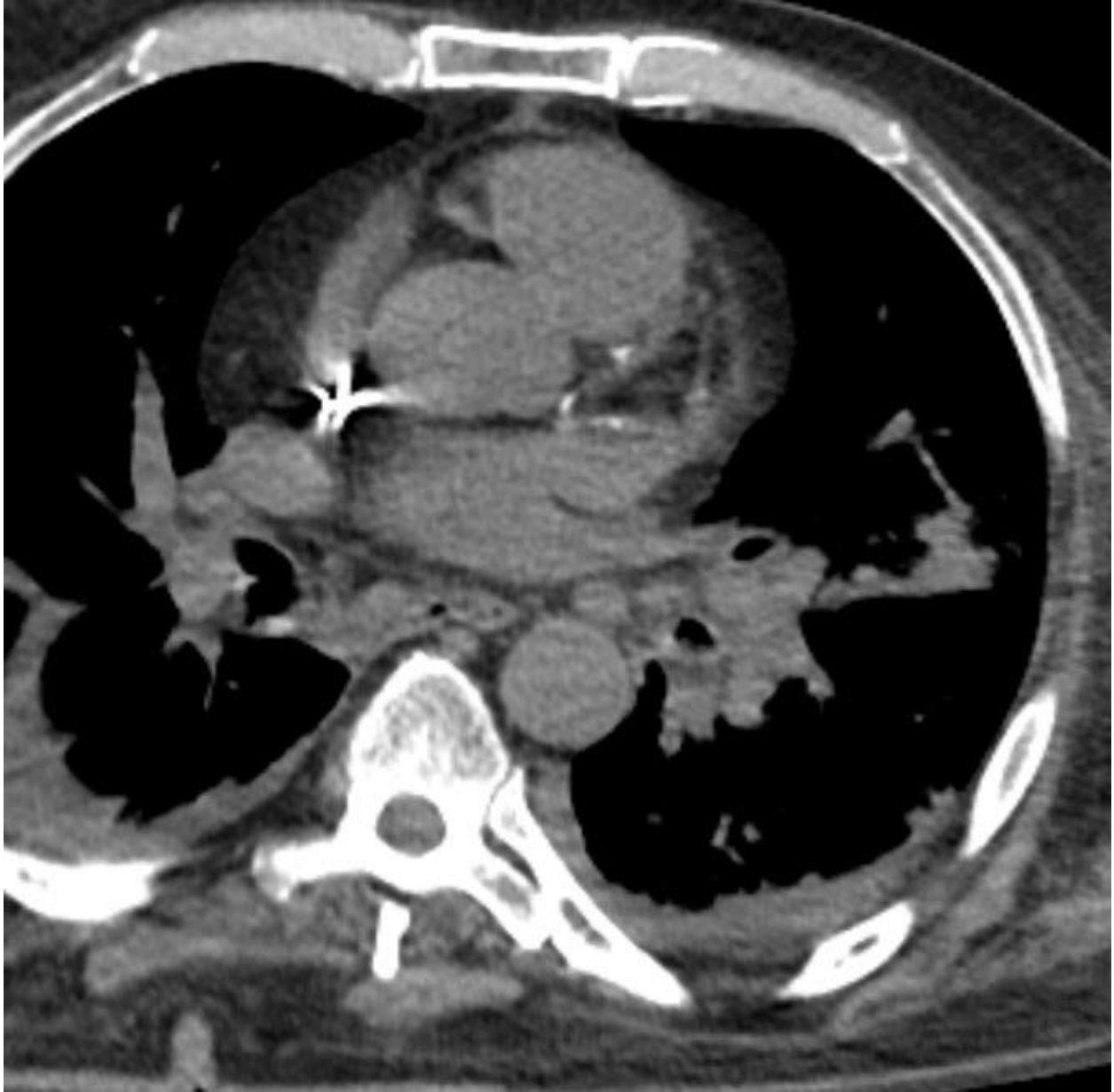


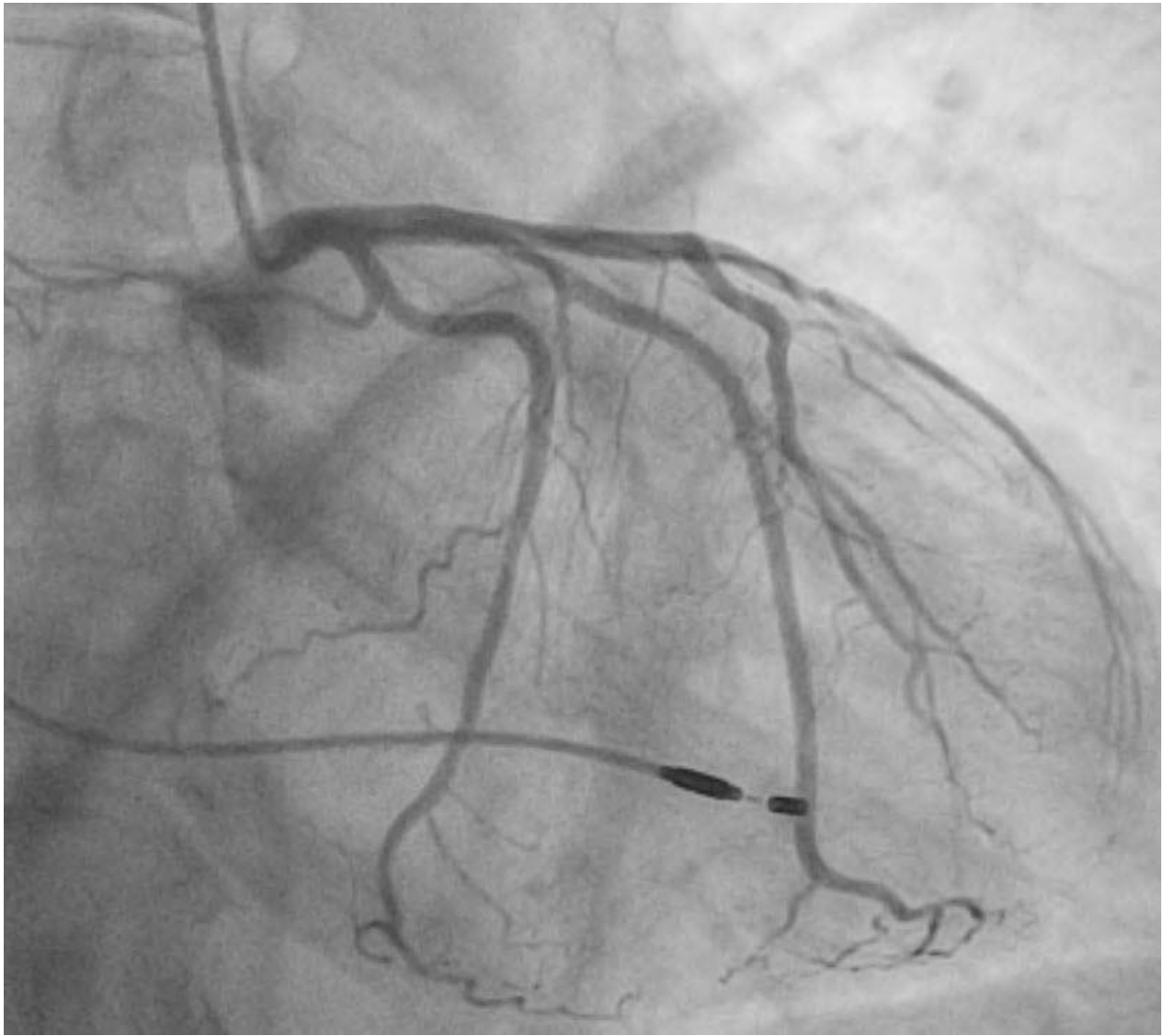
Chest CT case 13.5 A and B

Same month as ICA. Noncontrast images. These images are the best in terms of having the least motion artifact.





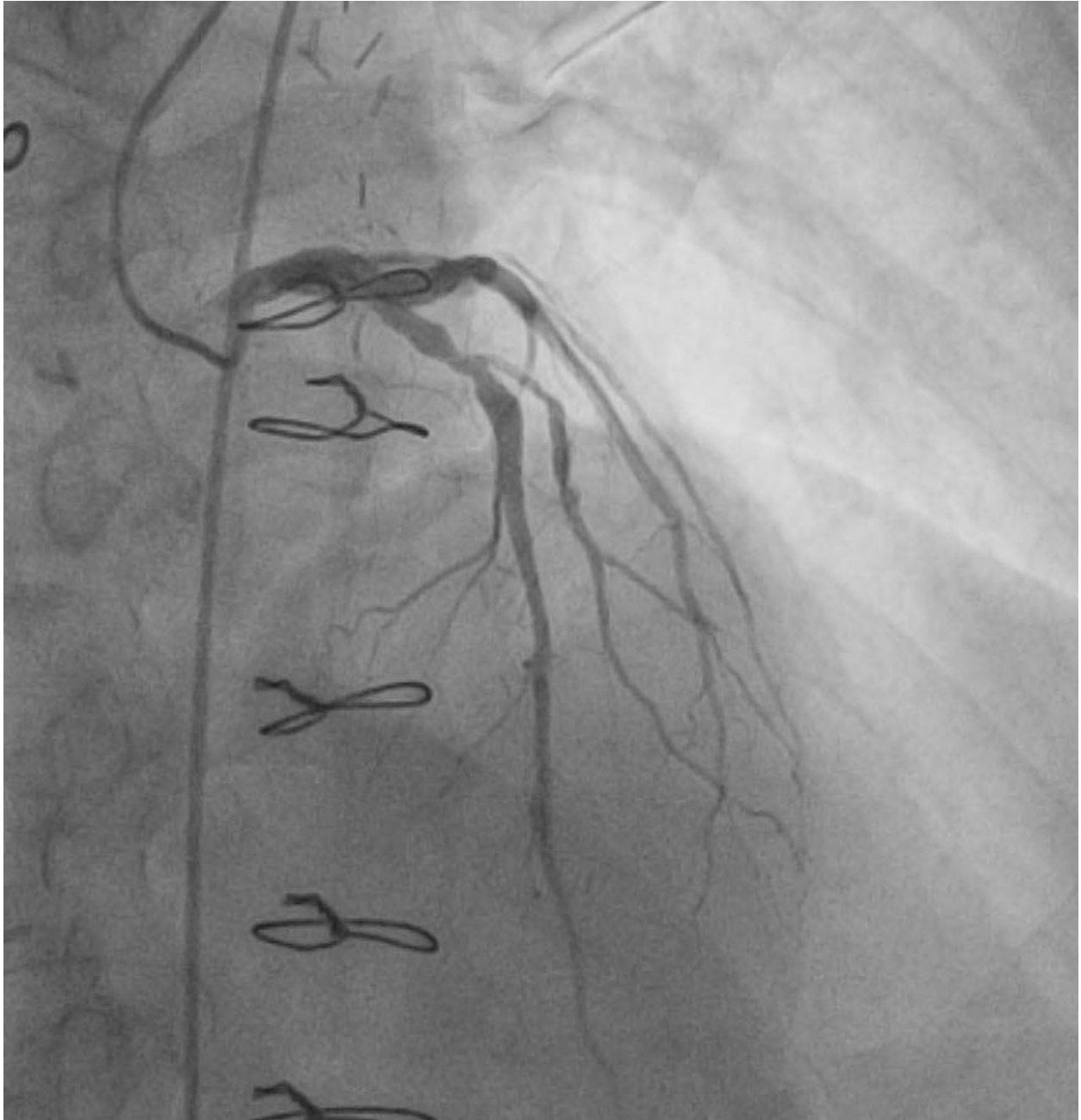


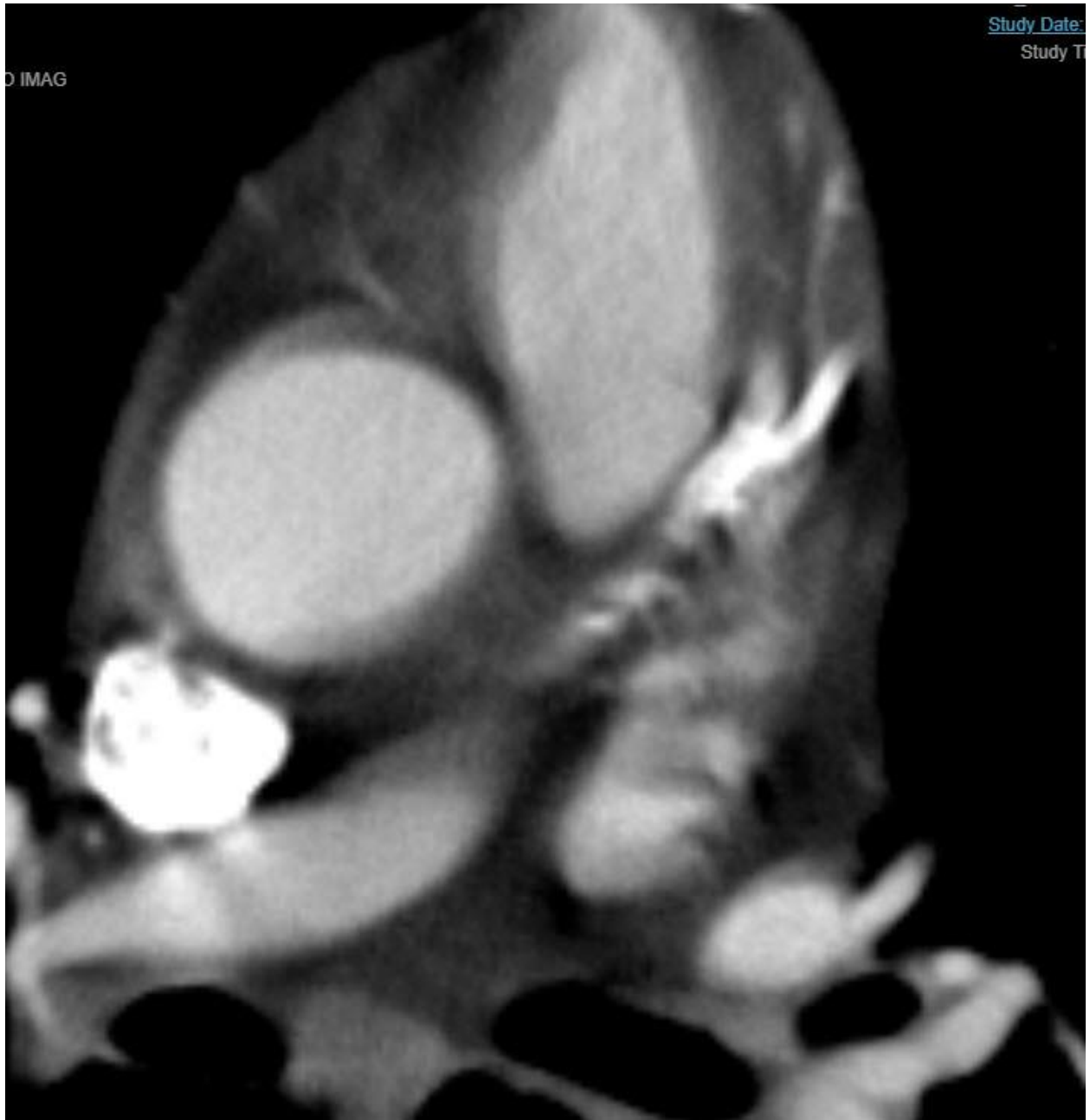


Case 14

ICA findings: ICA was performed one year prior to Chest CT. This is a CABG patient. Moderate disease of proximal and mid LAD and ostial D1. ICA score 2.

Chest CT findings: Heavy calcification of LAD and diagonal. CT score 3. Risk class: E.

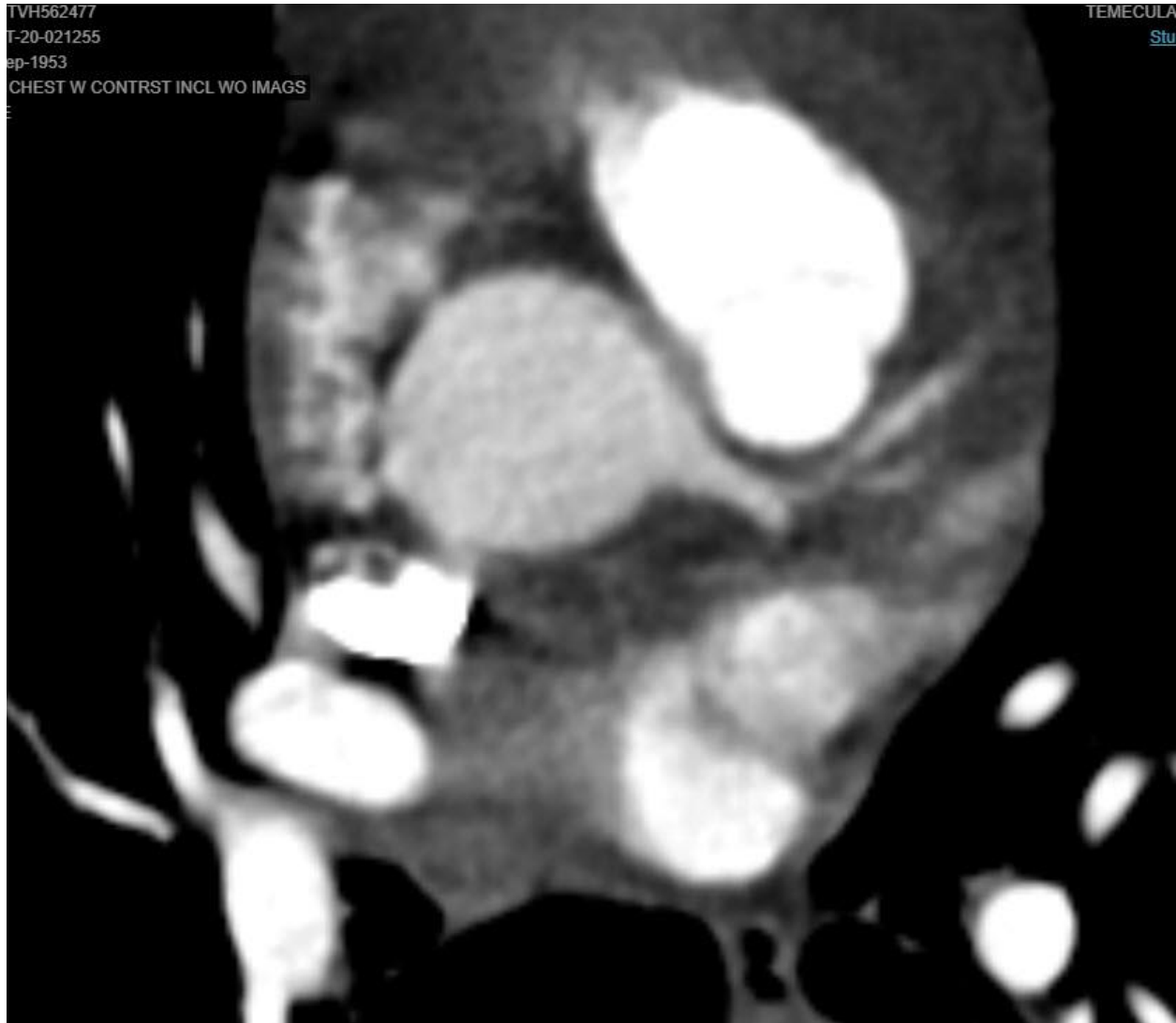

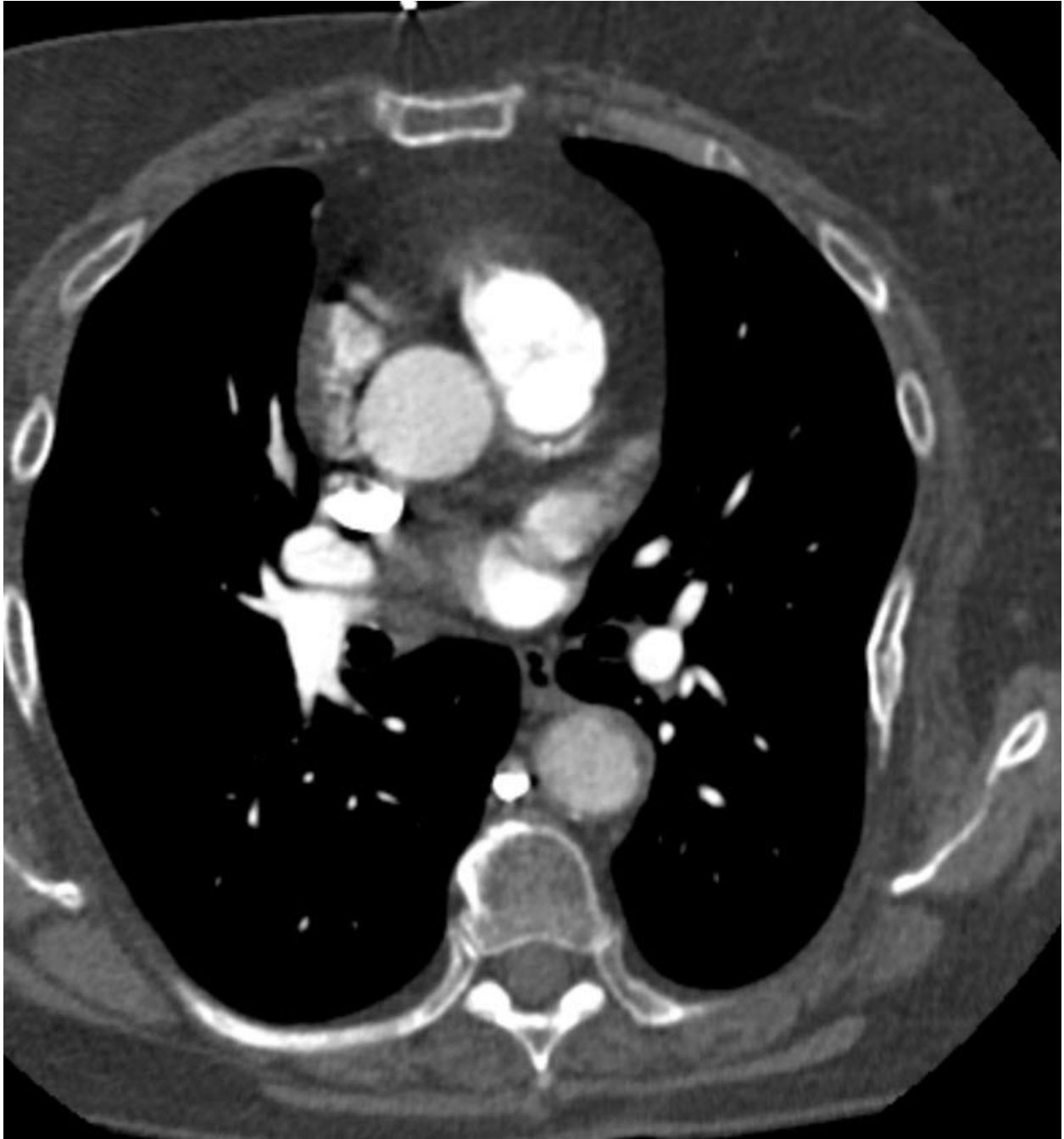


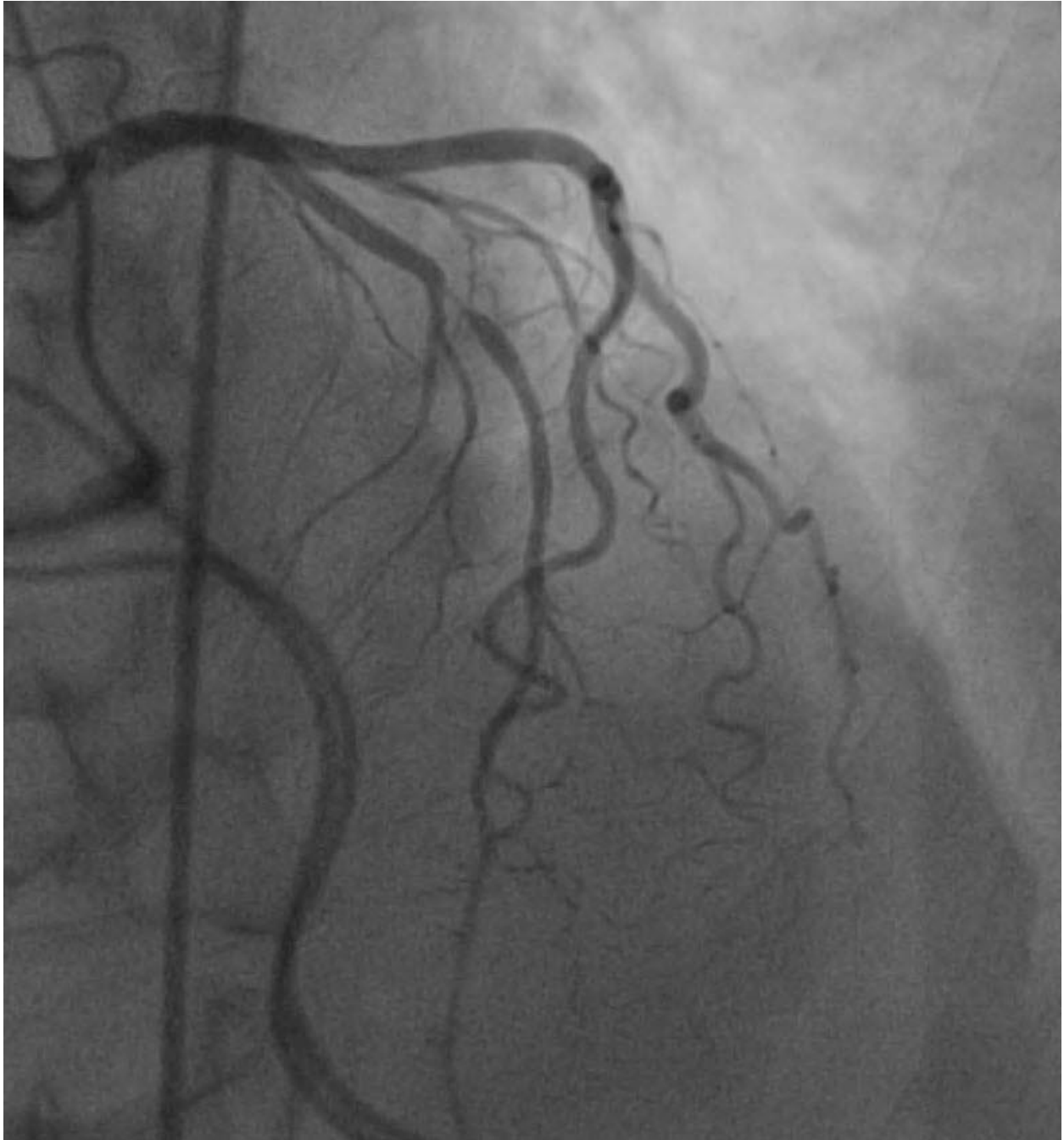
Case 15

Chest CT findings: CT was performed 14 months before ICA. Moderate mixed plaque disease in proximal and mid LAD. There is positive remodeling. Chest CT score 2. Risk Class: D.

ICA finding: Obstructive disease of mid LAD. ICA score: 3.



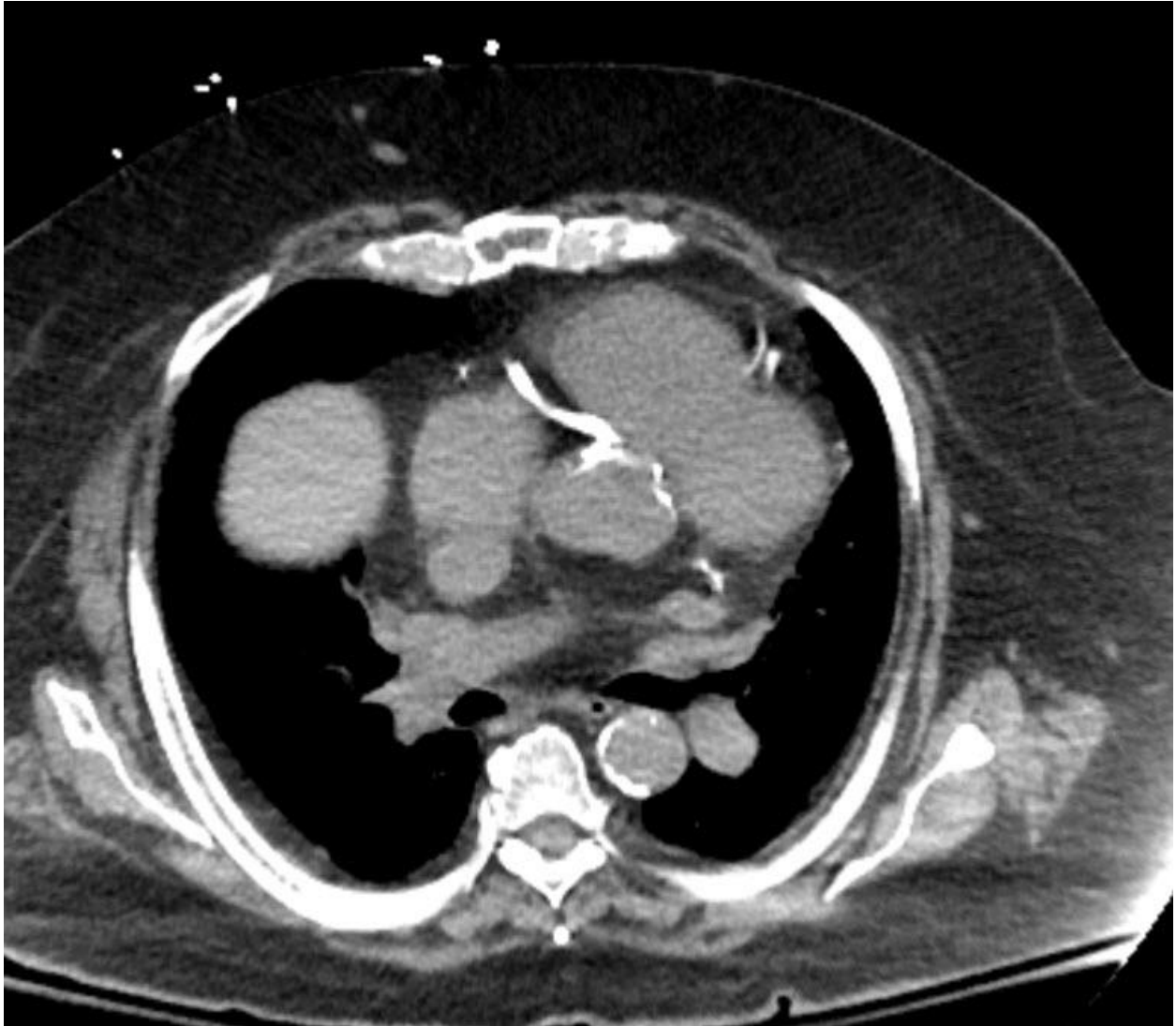



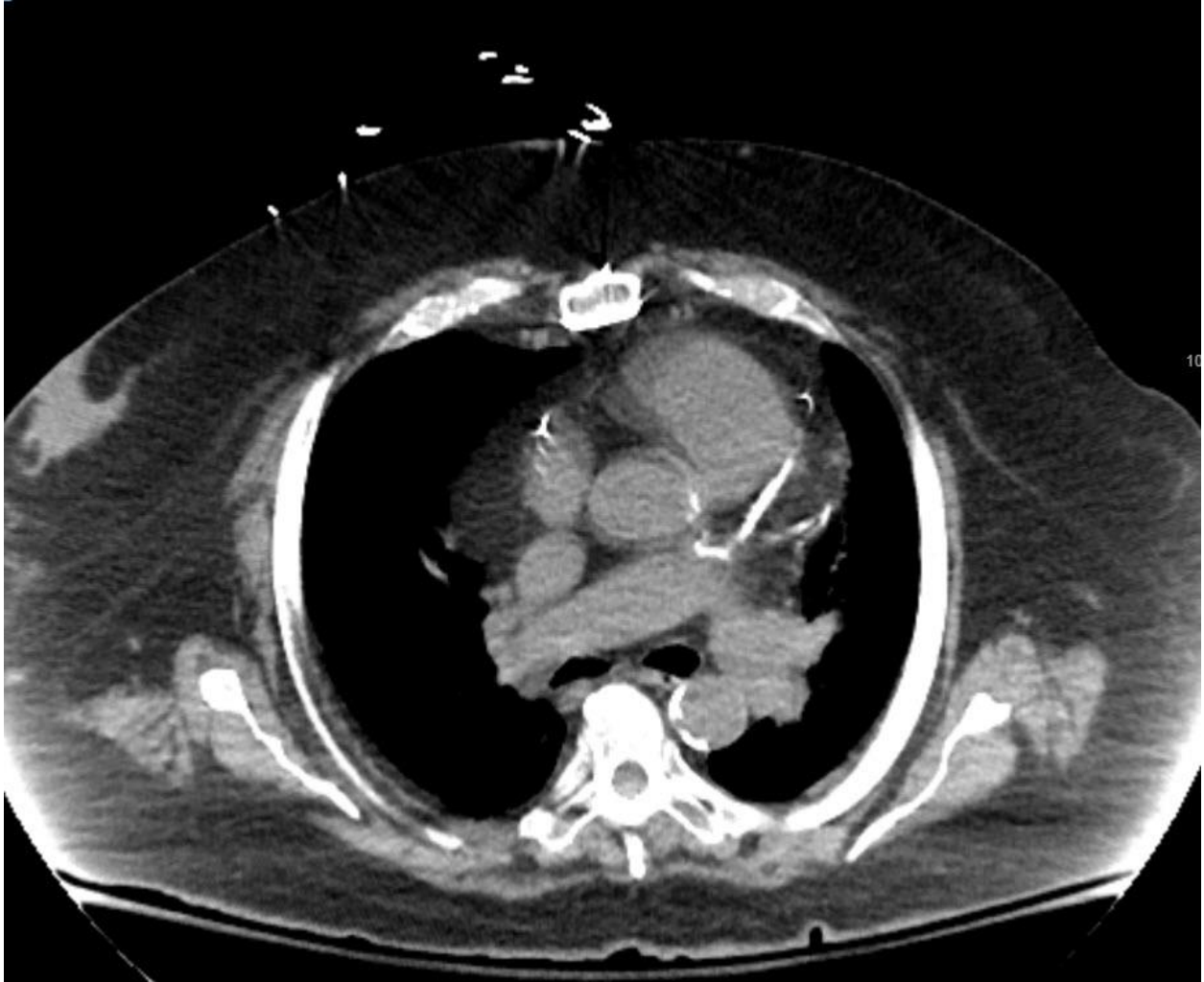Case 16

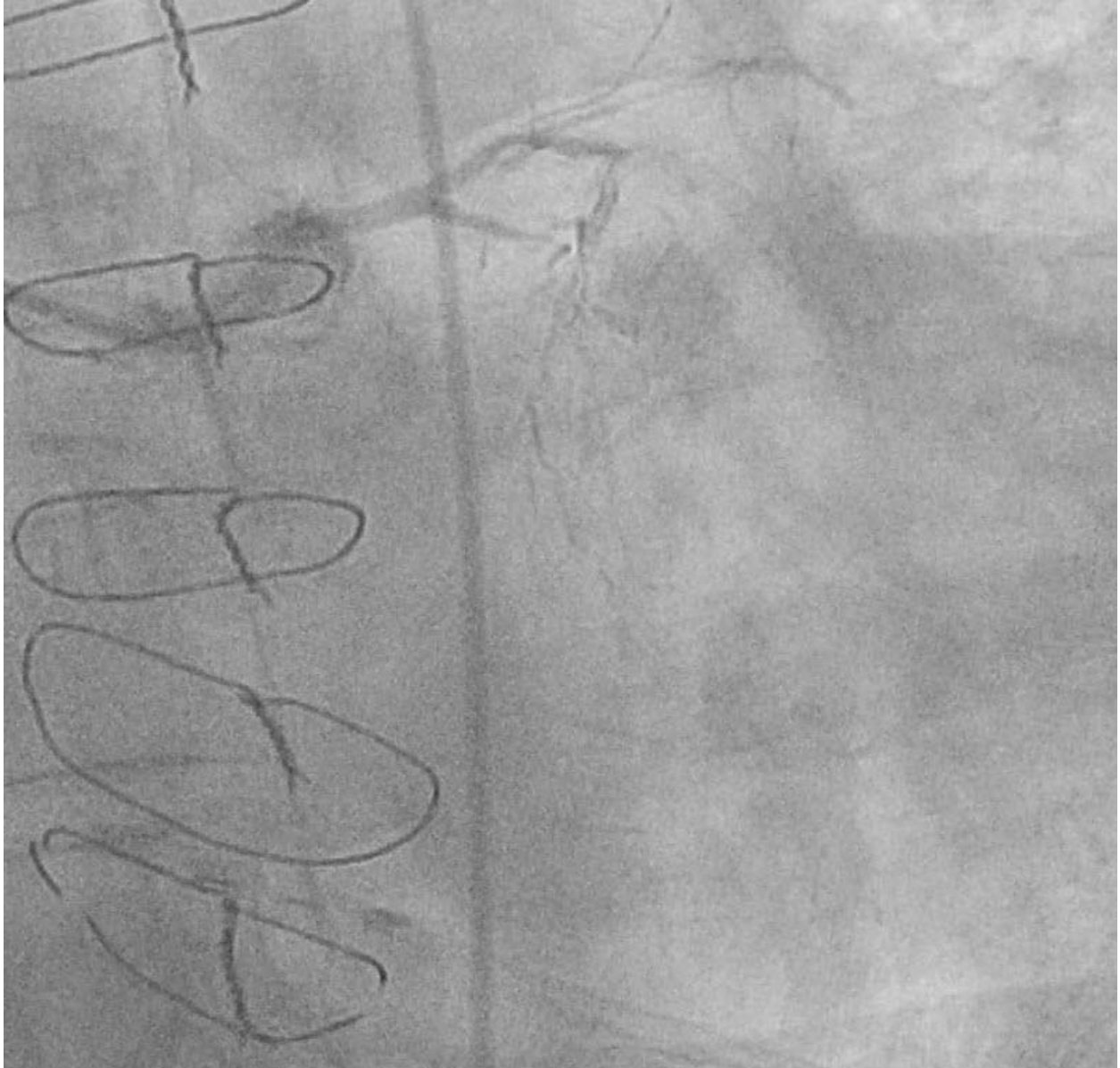Chest CT findings: Chest CT was performed one month before ICA. This is a CABG patient. Chest CT score: 3. Risk Class: E.

ICA findings: Multivessel disease. ICA score: 4.





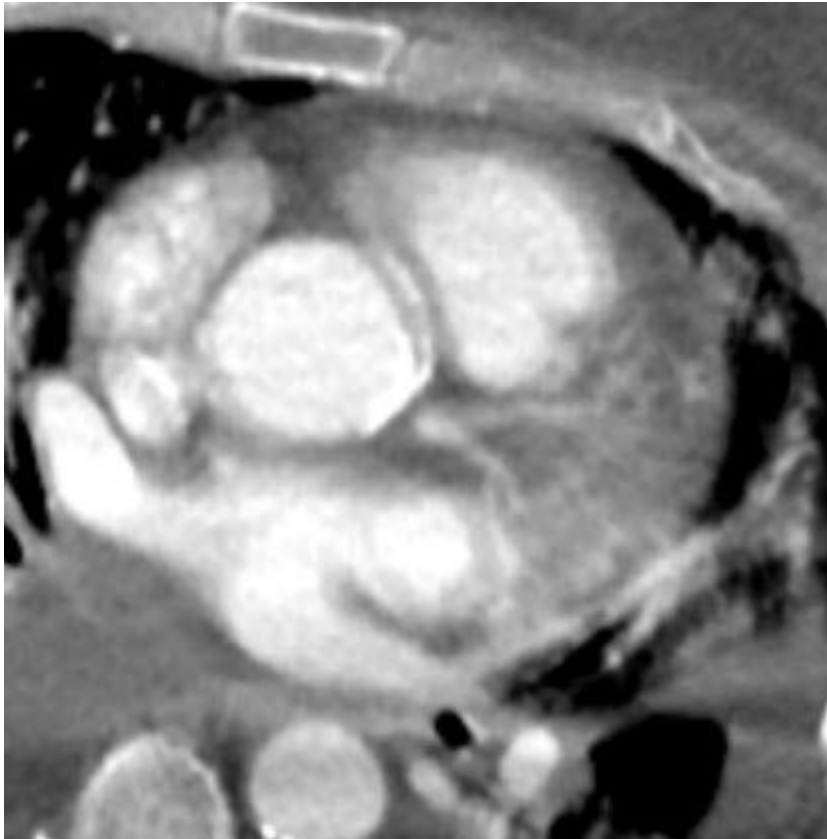


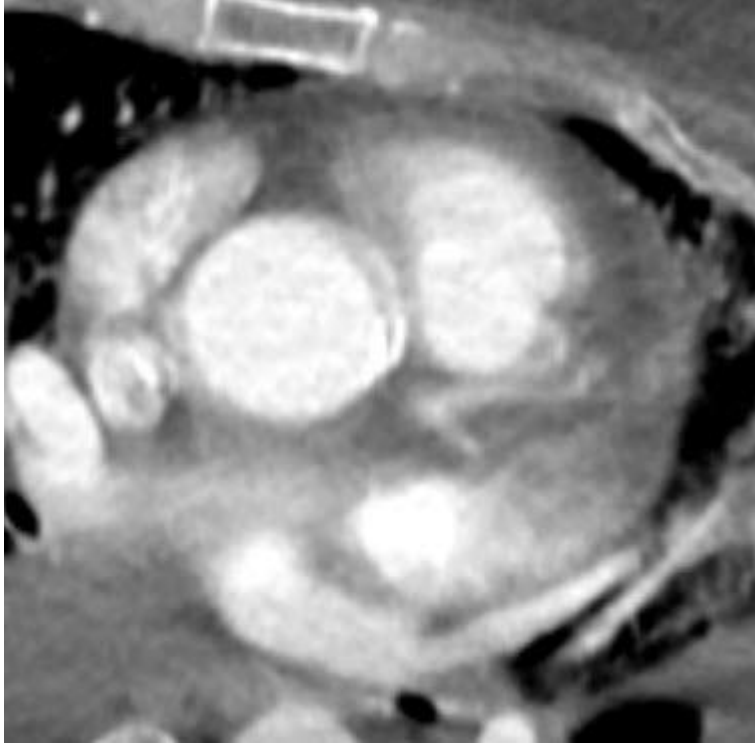


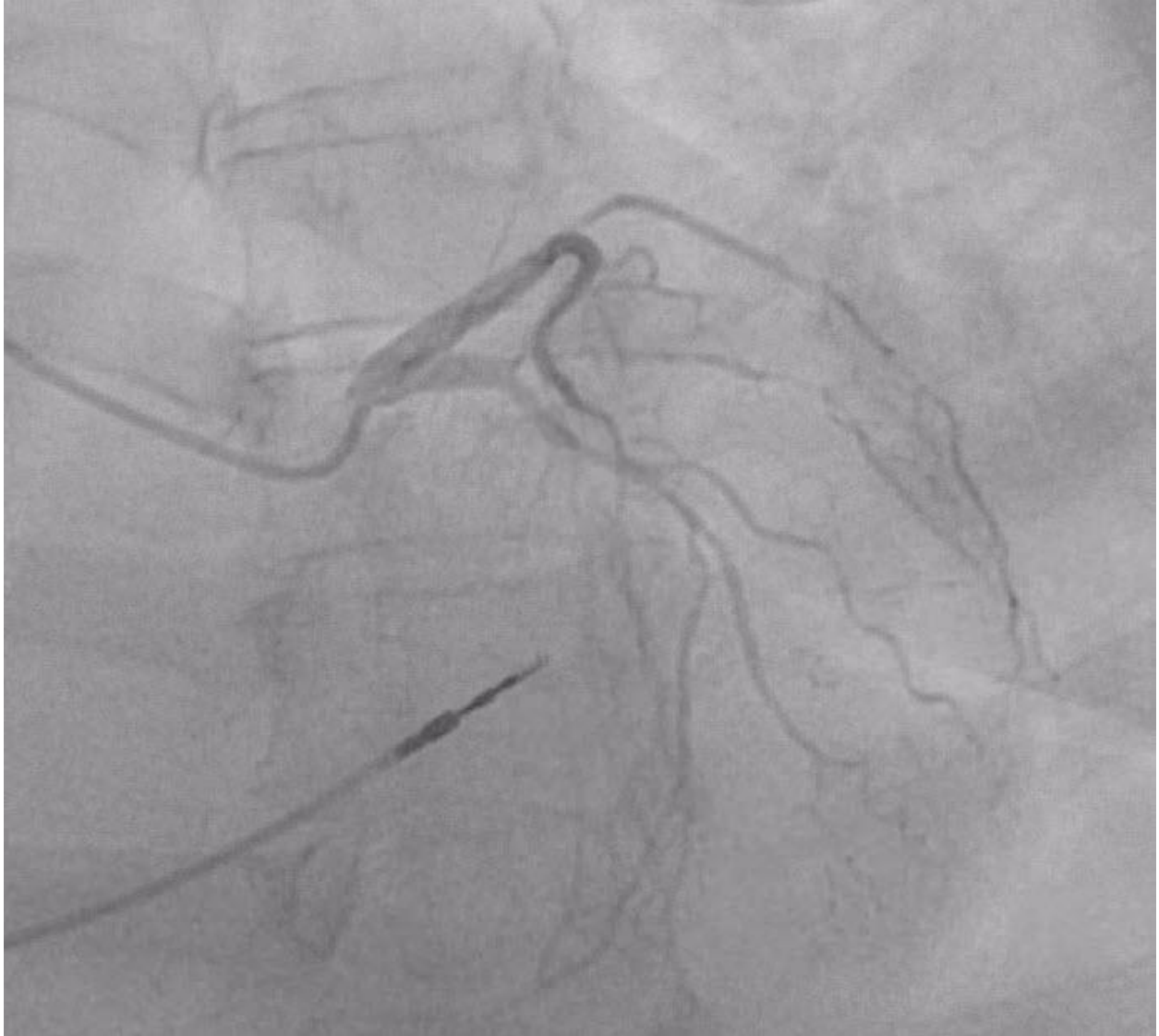Case 17

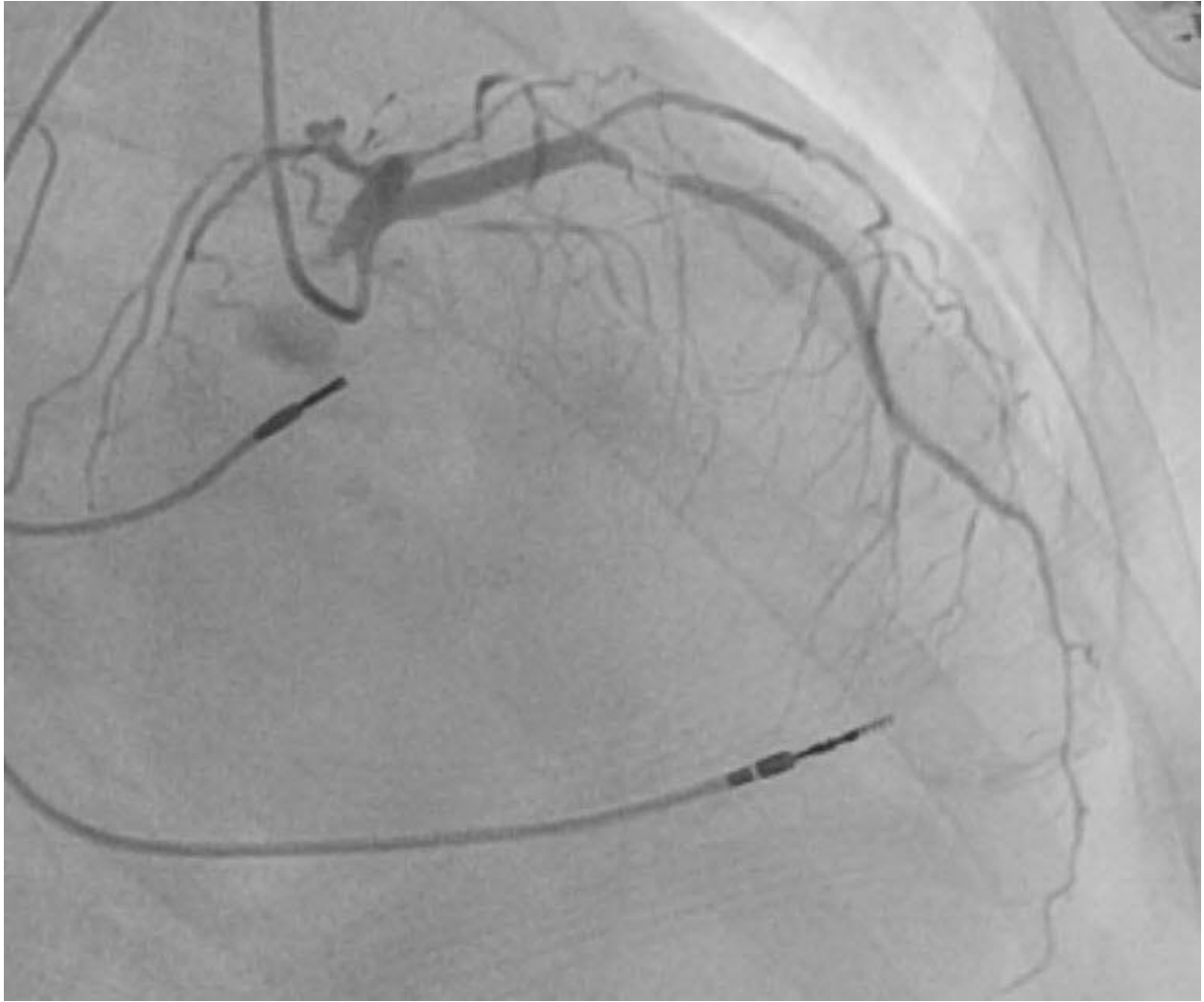
Chest CT findings: Chest CT performed two months before ICA. Patient has diabetes, hypertension, hypercholesterolemia, and HFpEF but no history of CAD. Small vessel disease of LAD and LCX. Chest CT score 3. Risk Class: E.

ICA findings: Diffuse small vessel disease of LAD and LCX. Obstructive disease of mid LAD and received stenting. ICA score: 3.





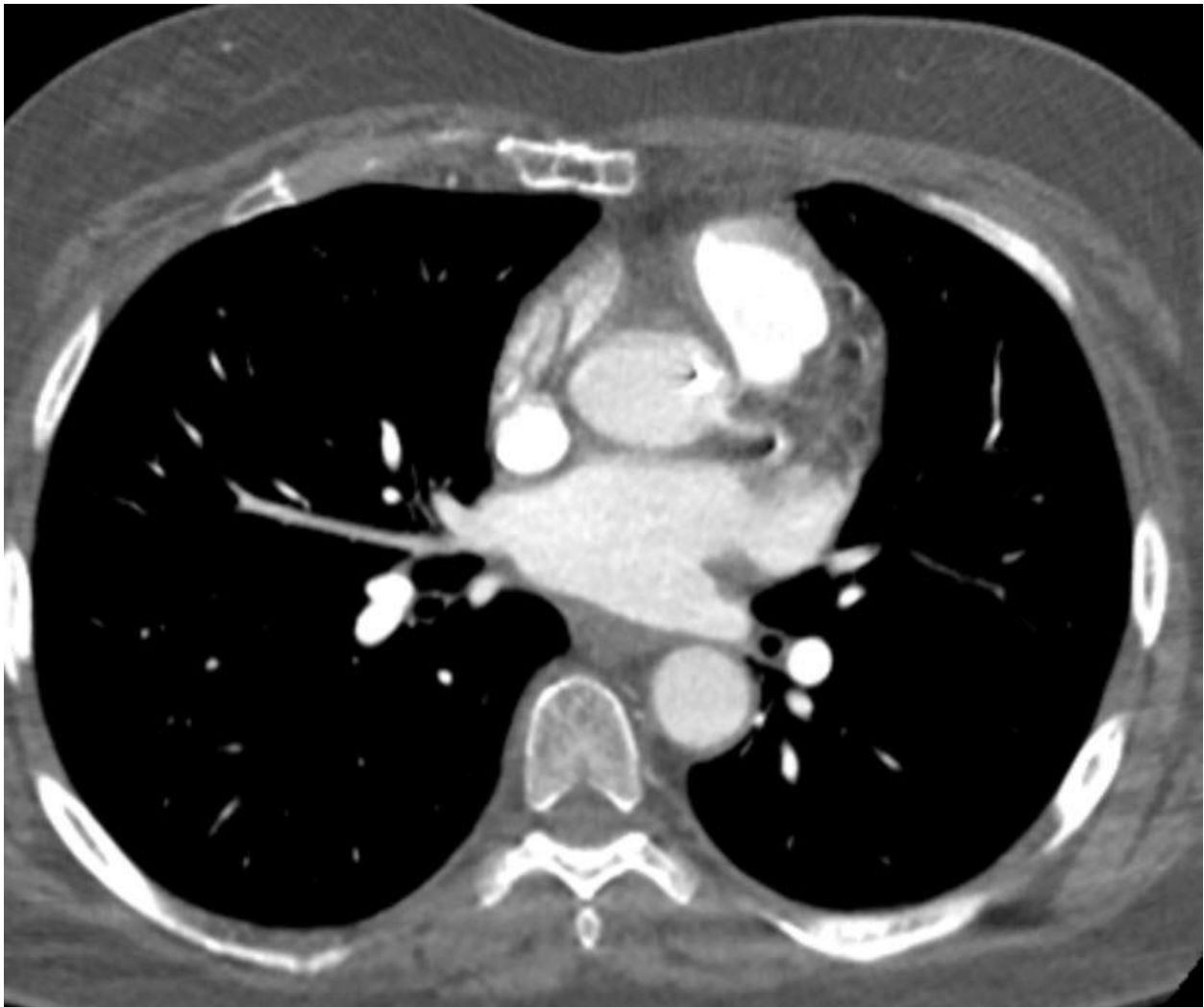


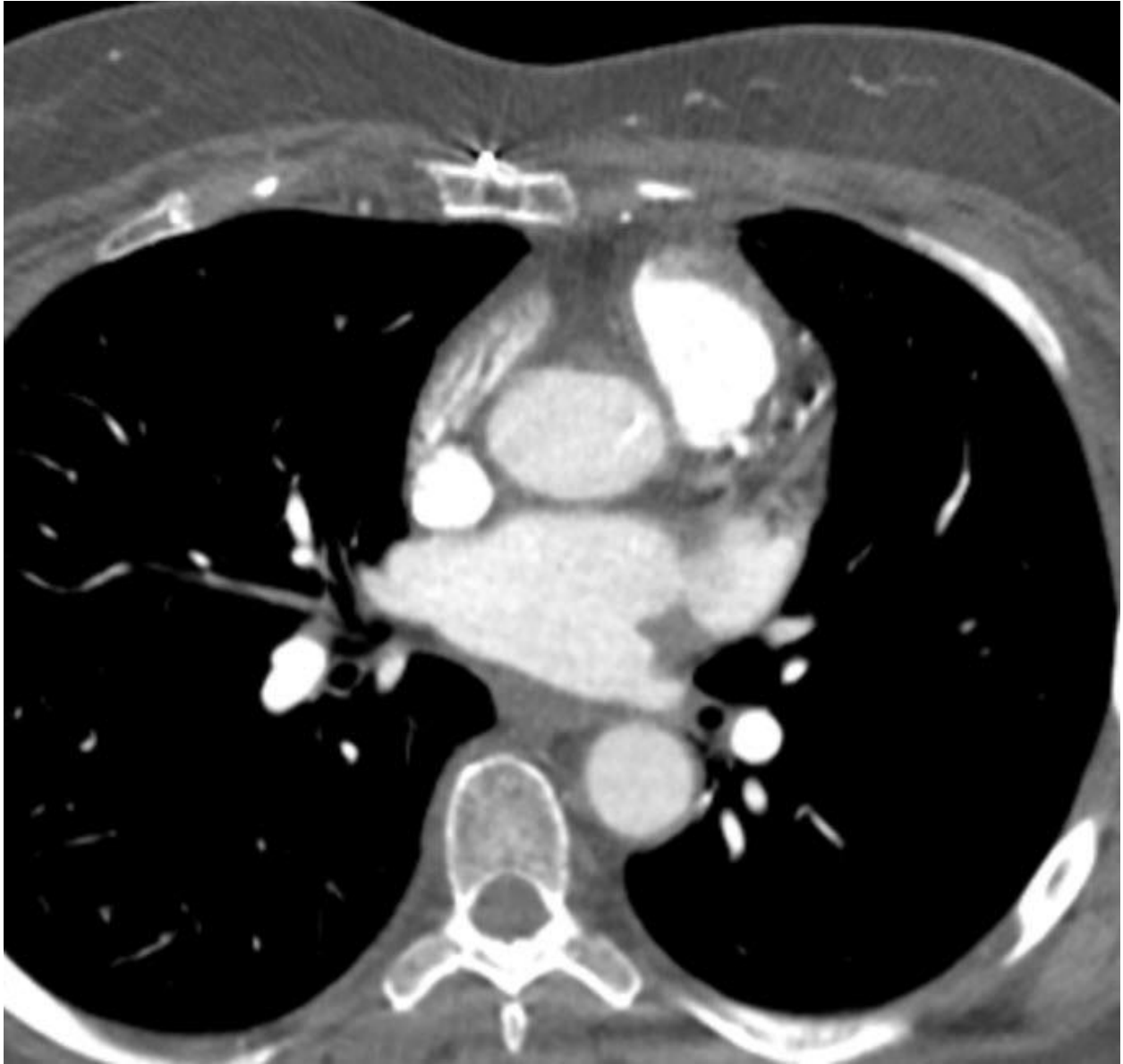


Case 18

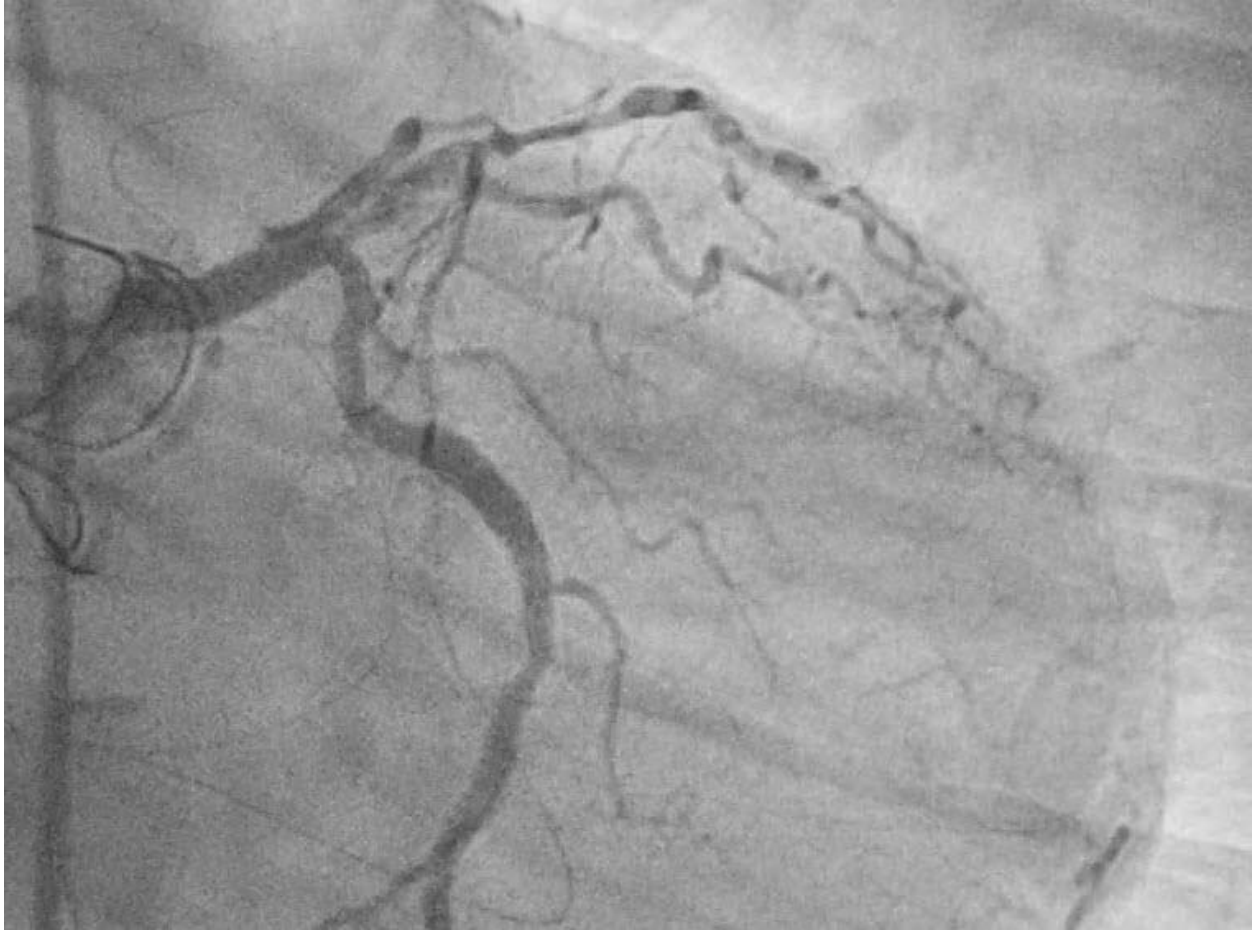Chest CT findings: CT was performed two days before ICA. Patient had CABG. LM appears patent. There are no arteries distal to LM despite adequate contrast opacification and there is no motion artifact. Chest CT score: 3. Risk Class: E.

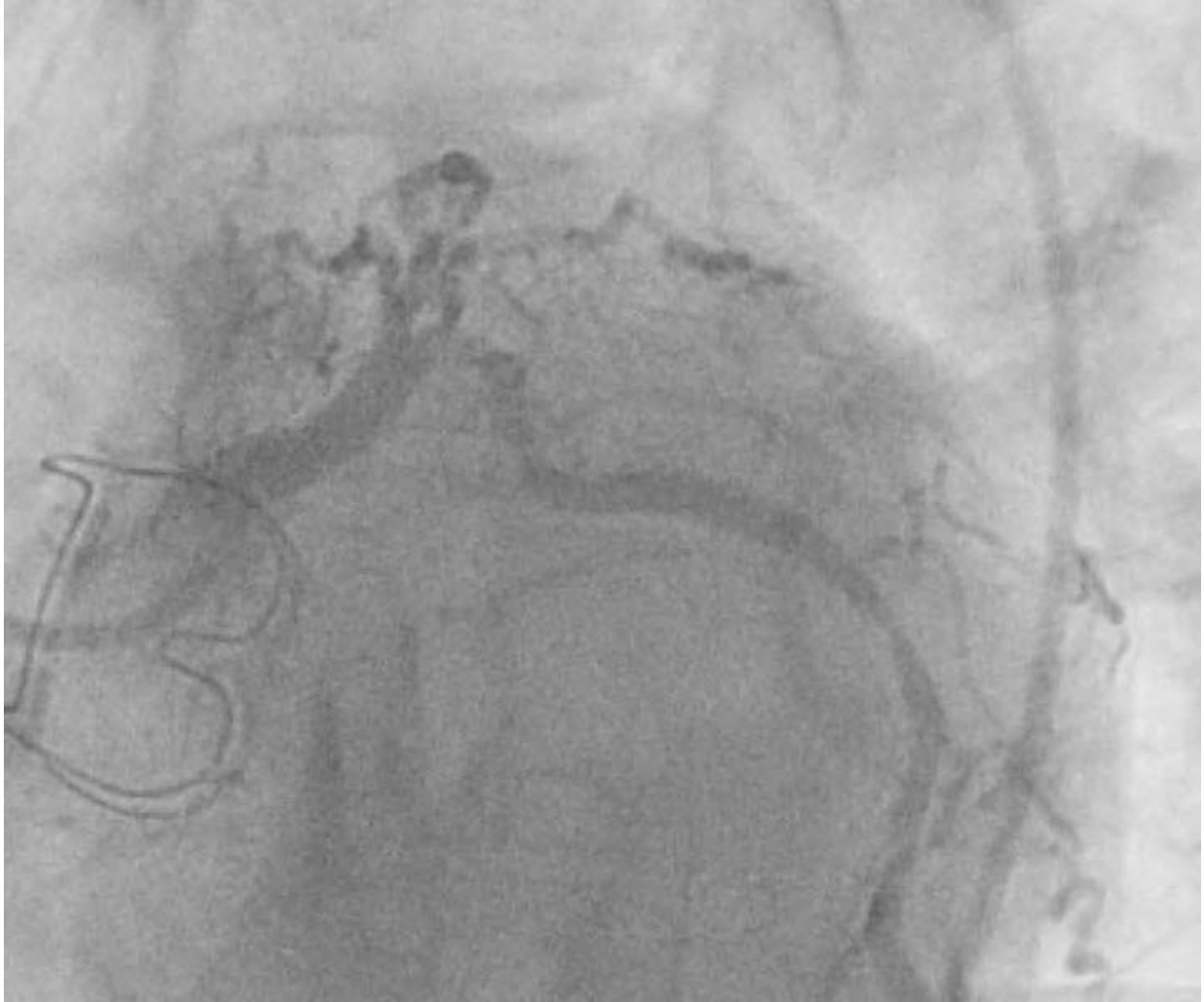ICA findings: There is LAD CTO and obstructive mid LCX. ICA score: 4.







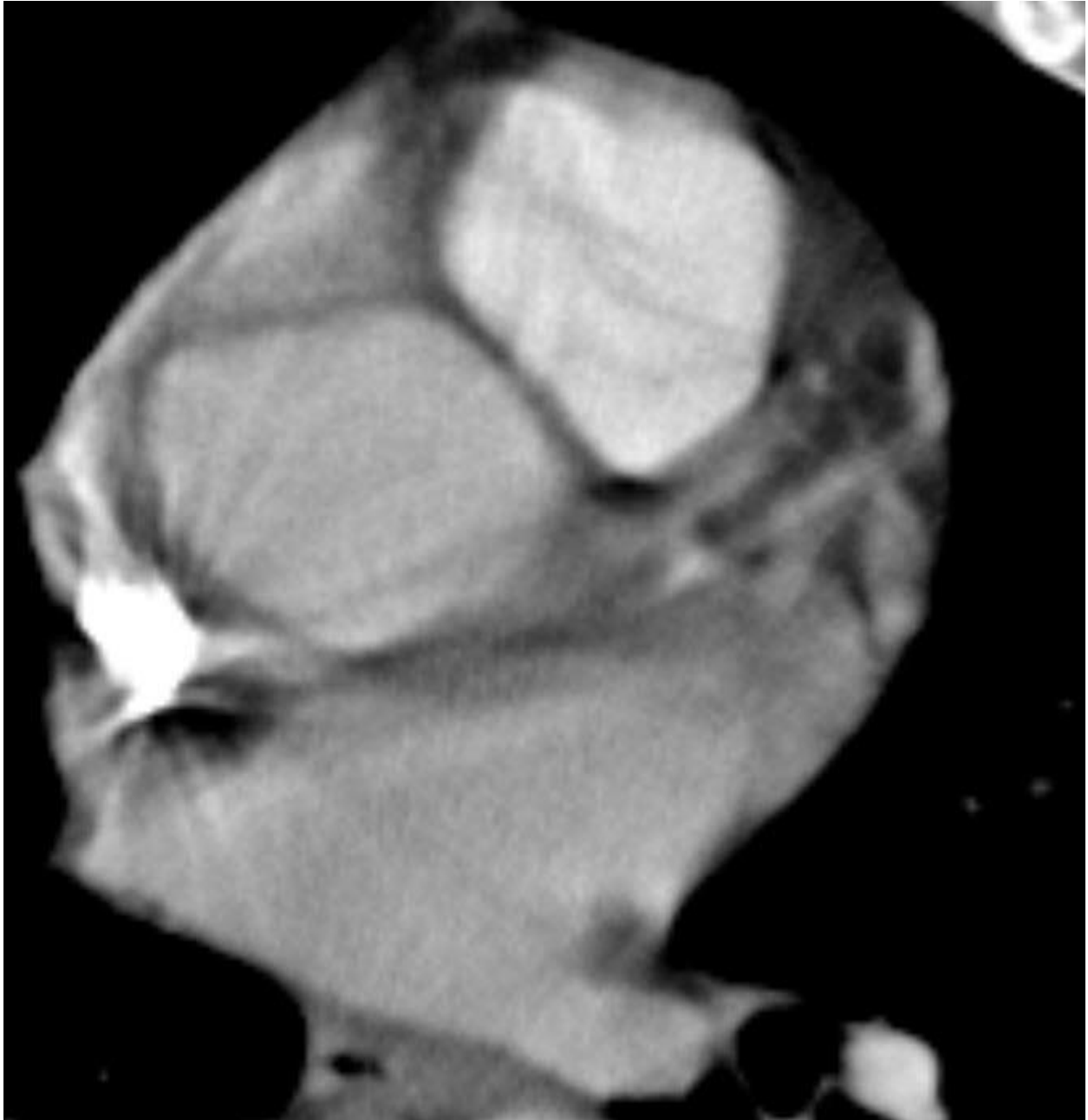


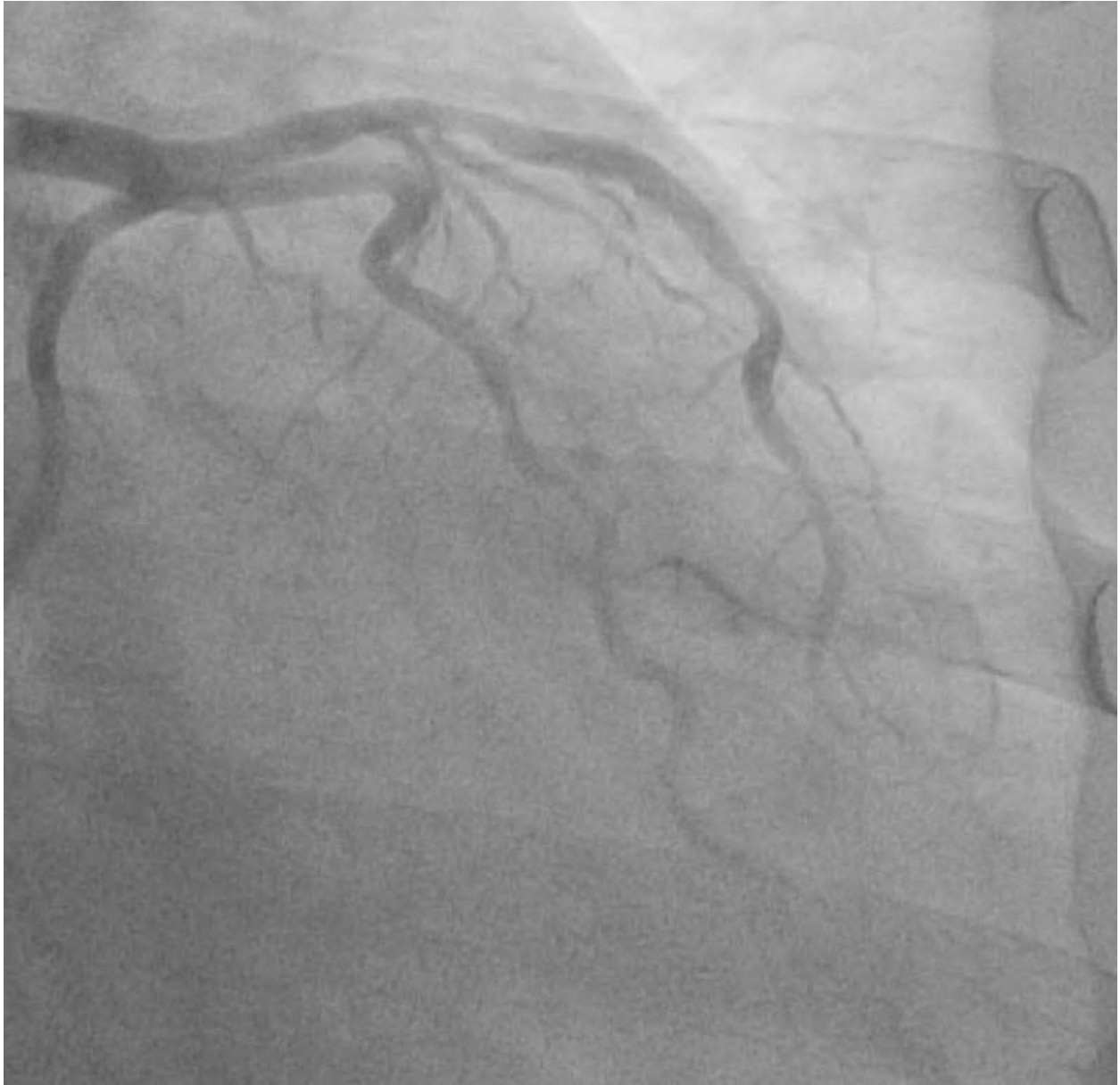

Case 19

Chest CT findings: Chest CT was performed three months before ICA. There is an obstructive noncalcific plaque in the mid LAD. Chest CT score: 3. Risk Class: D

ICA findings: There is an obstructive mid LAD and patient received stenting. ICA score: 3.

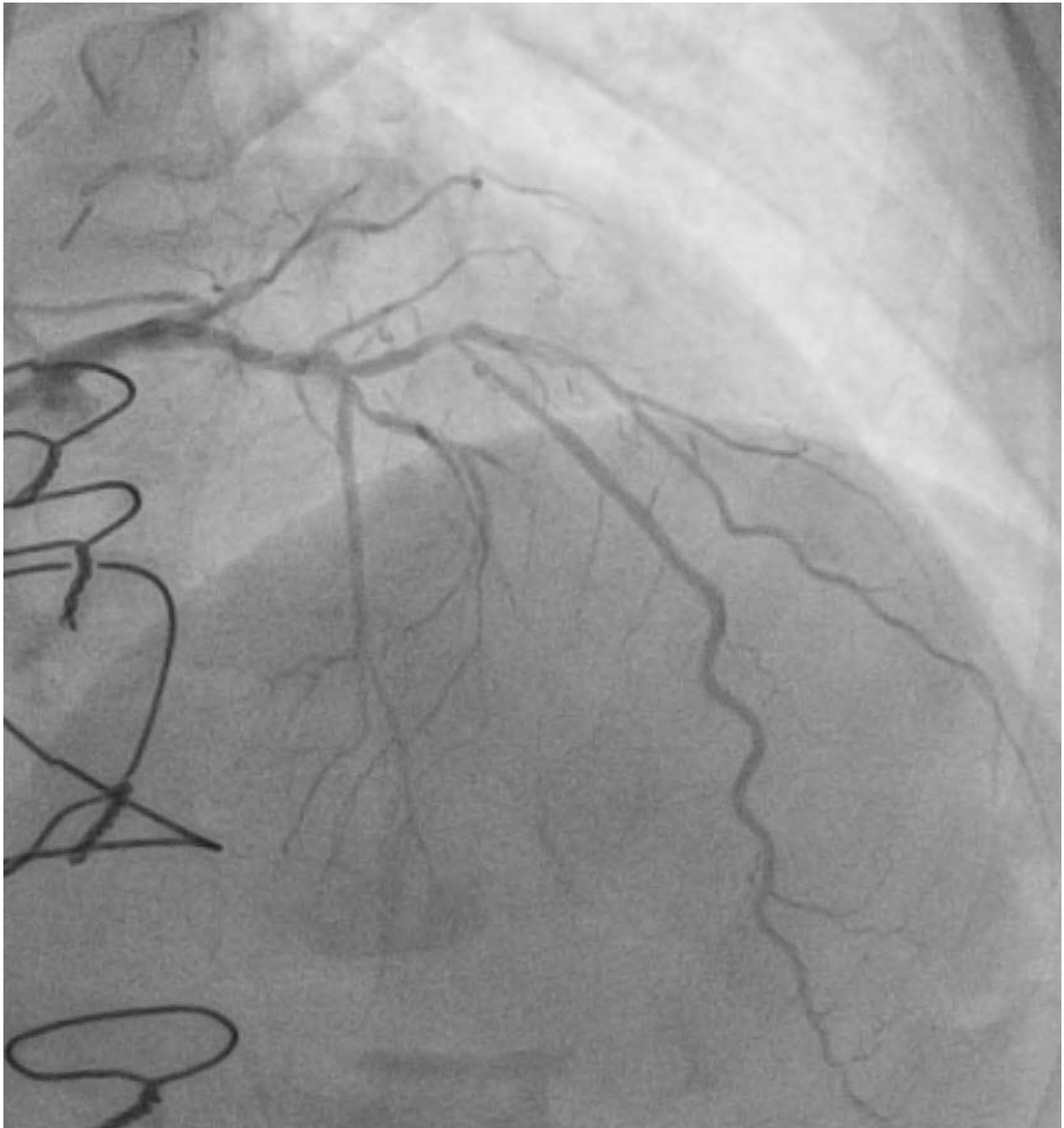


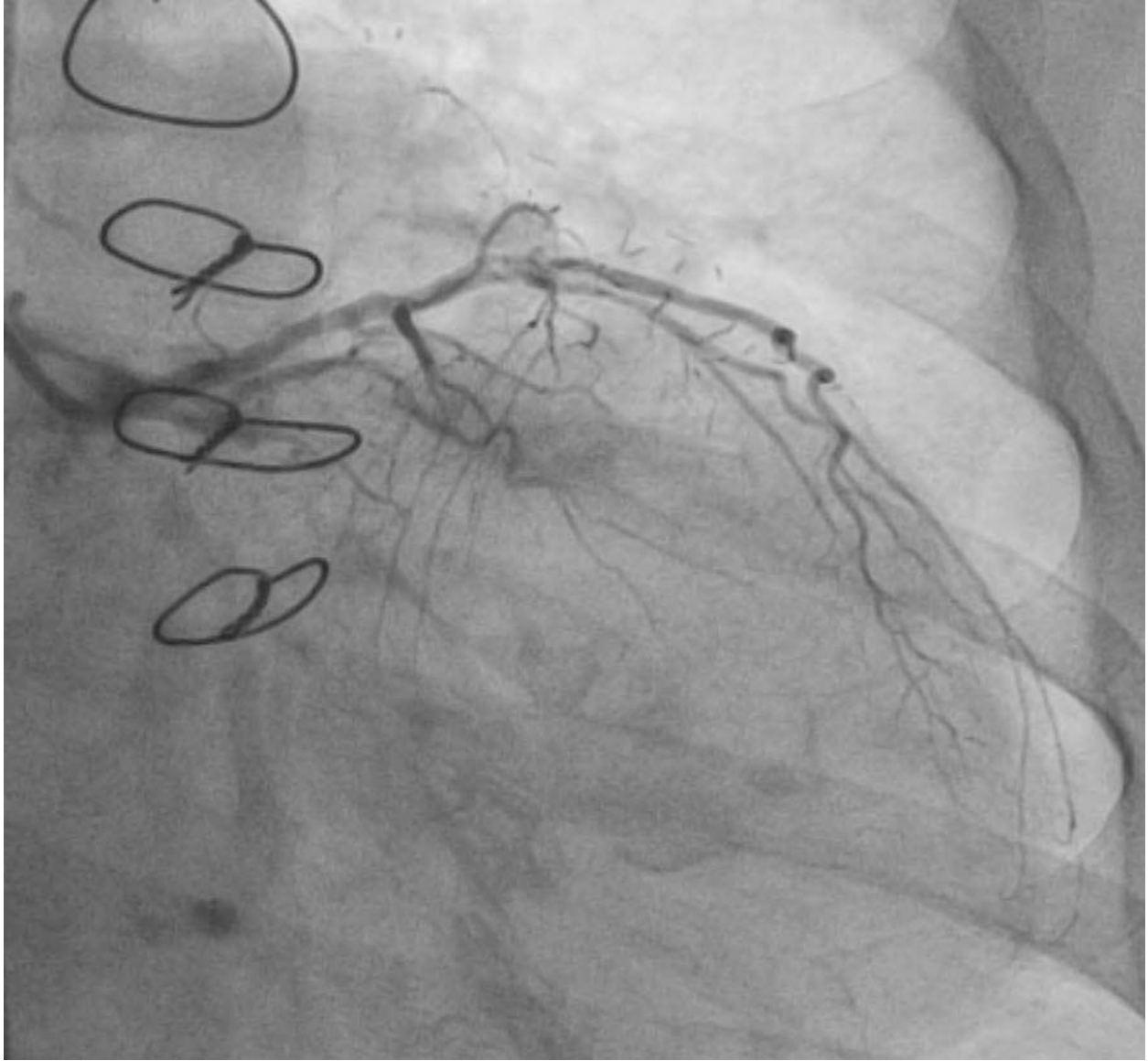


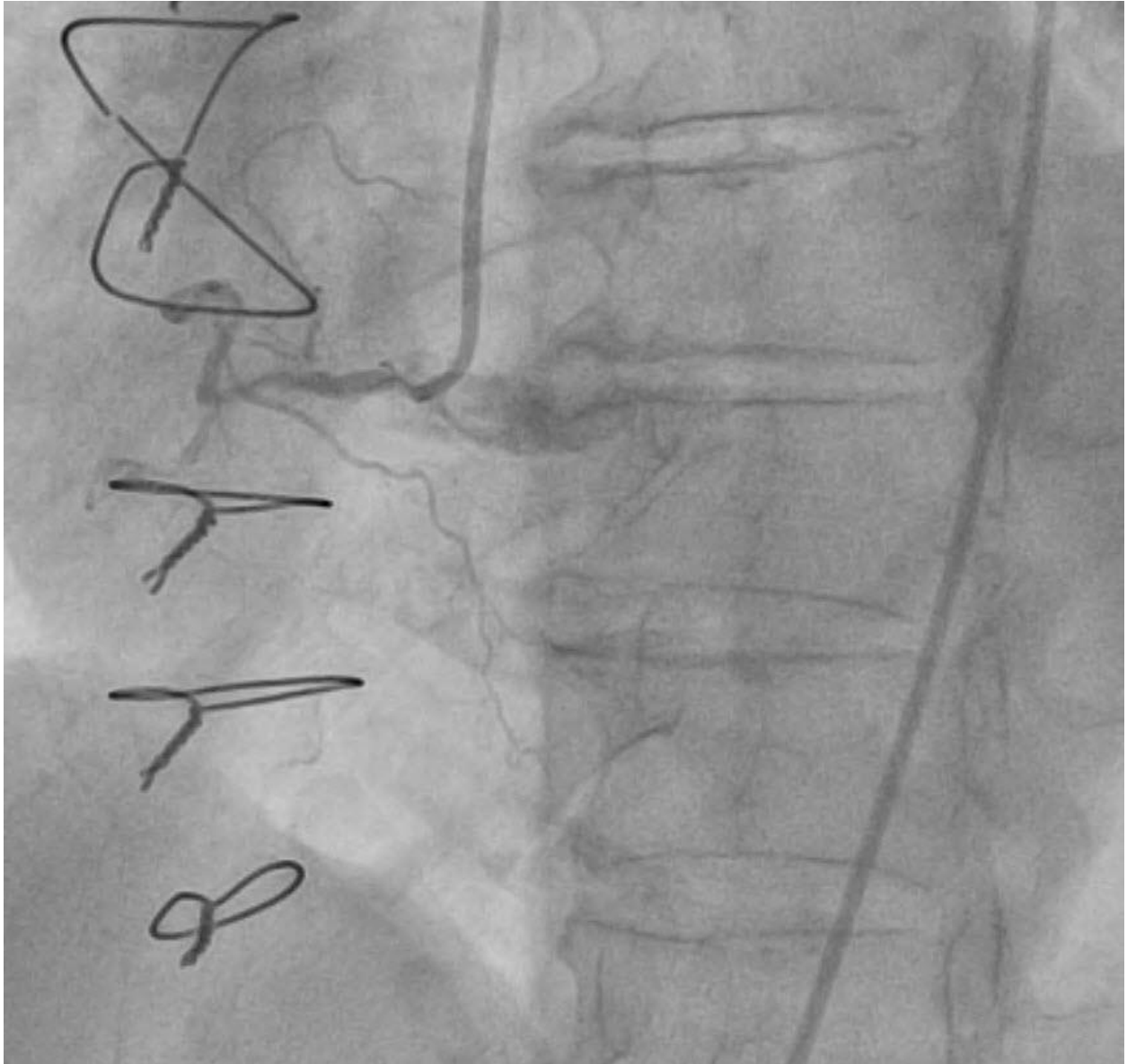
Case 20

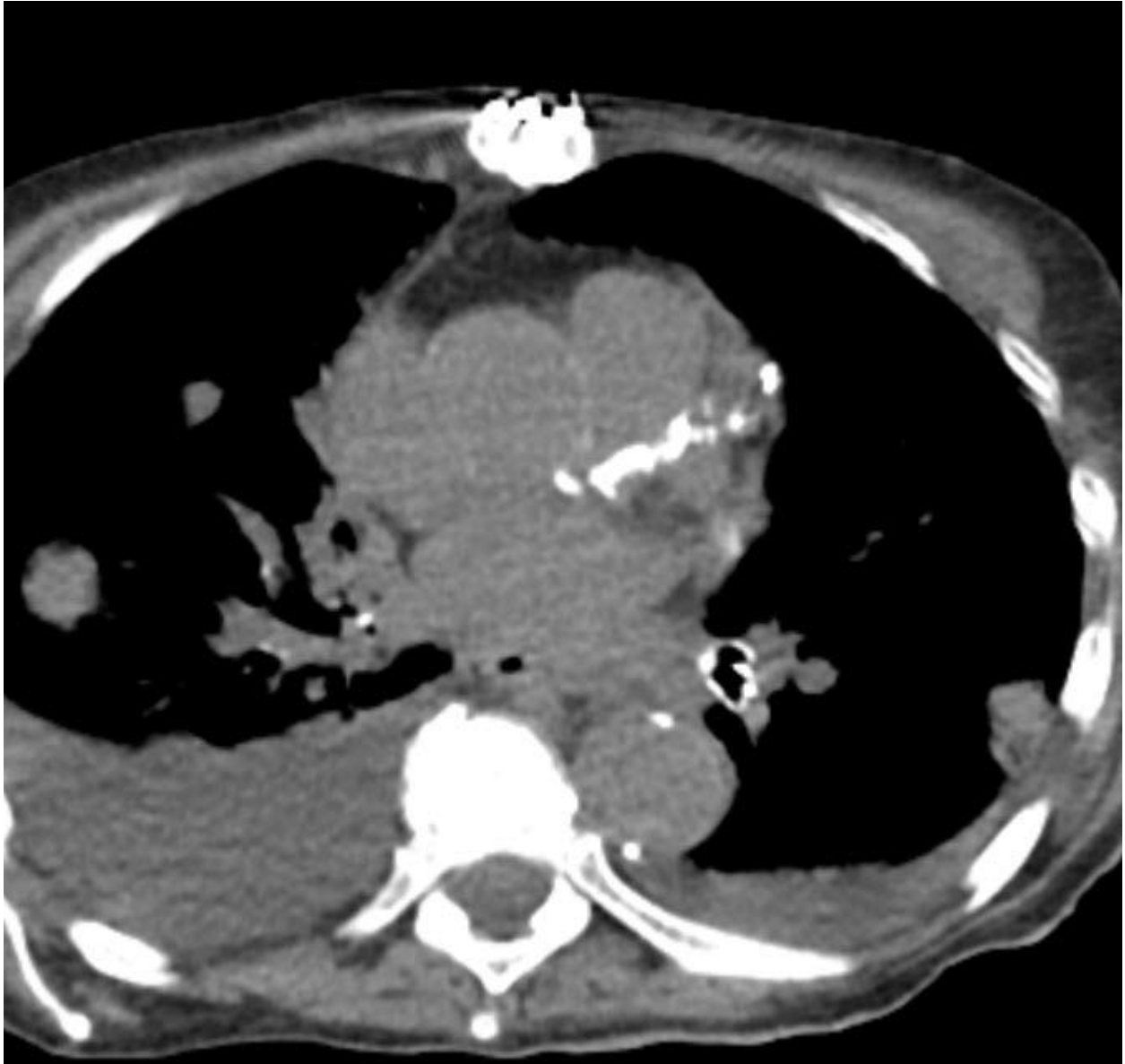
ICA findings: ICA was performed four years before chest CT. Patient had CABG. There is LAD CTO. Obstructive LCX/ OM and diagonal. RCA is occluded. ICA score: 4.

Chest CT findings: Noncontrast images. Severe in LAD, LCX and RCA. Chest CT score 4. Risk Class: E.

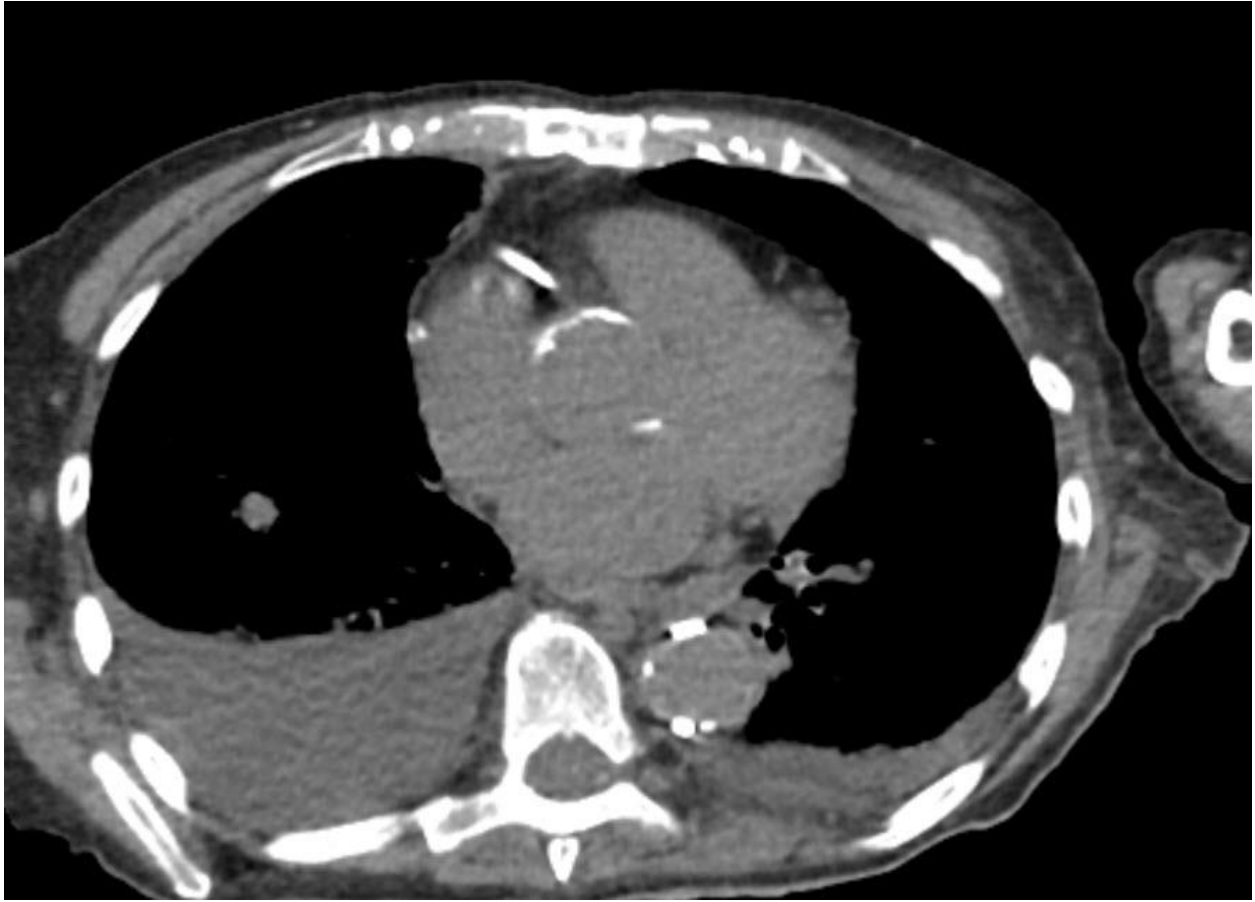








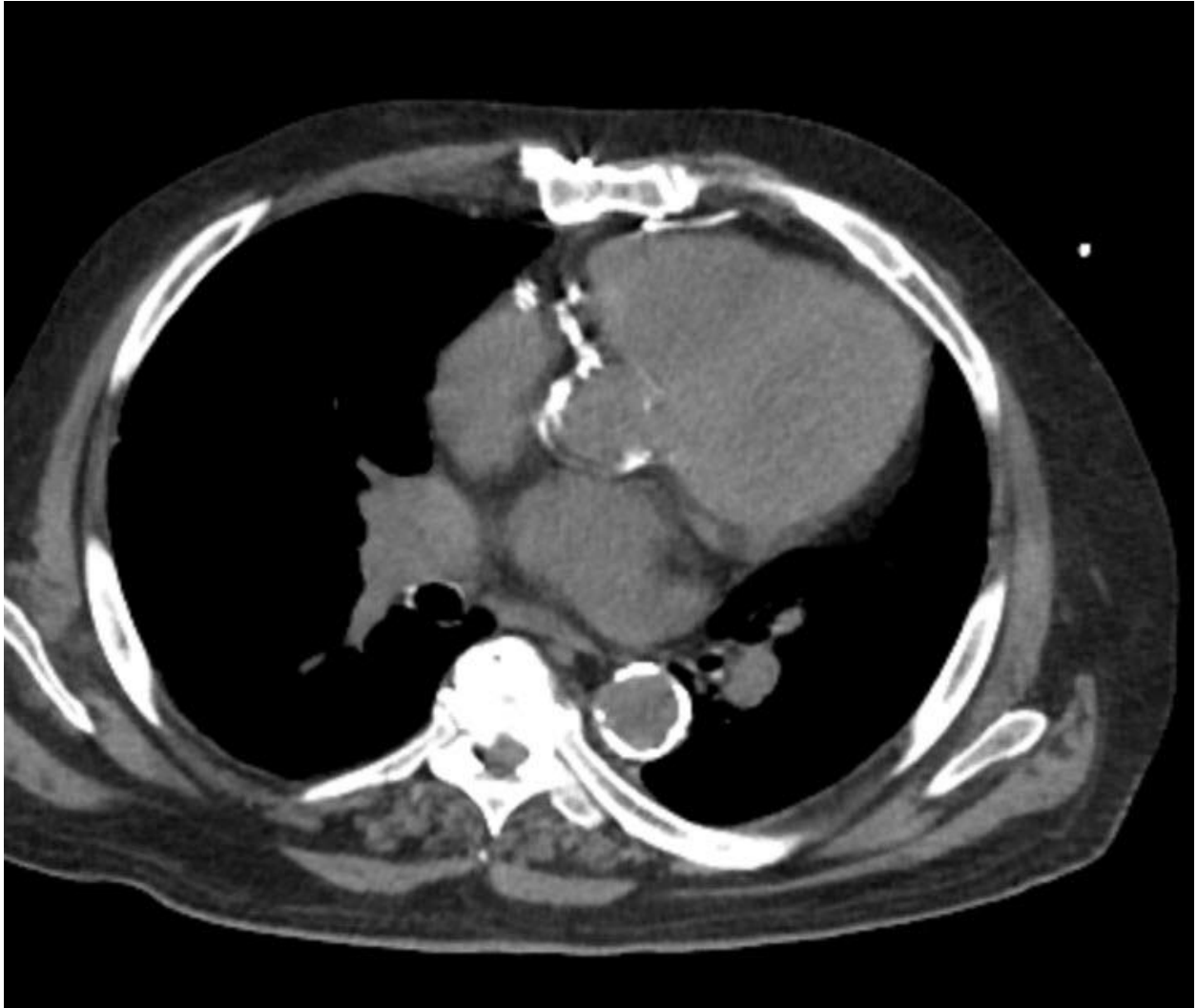
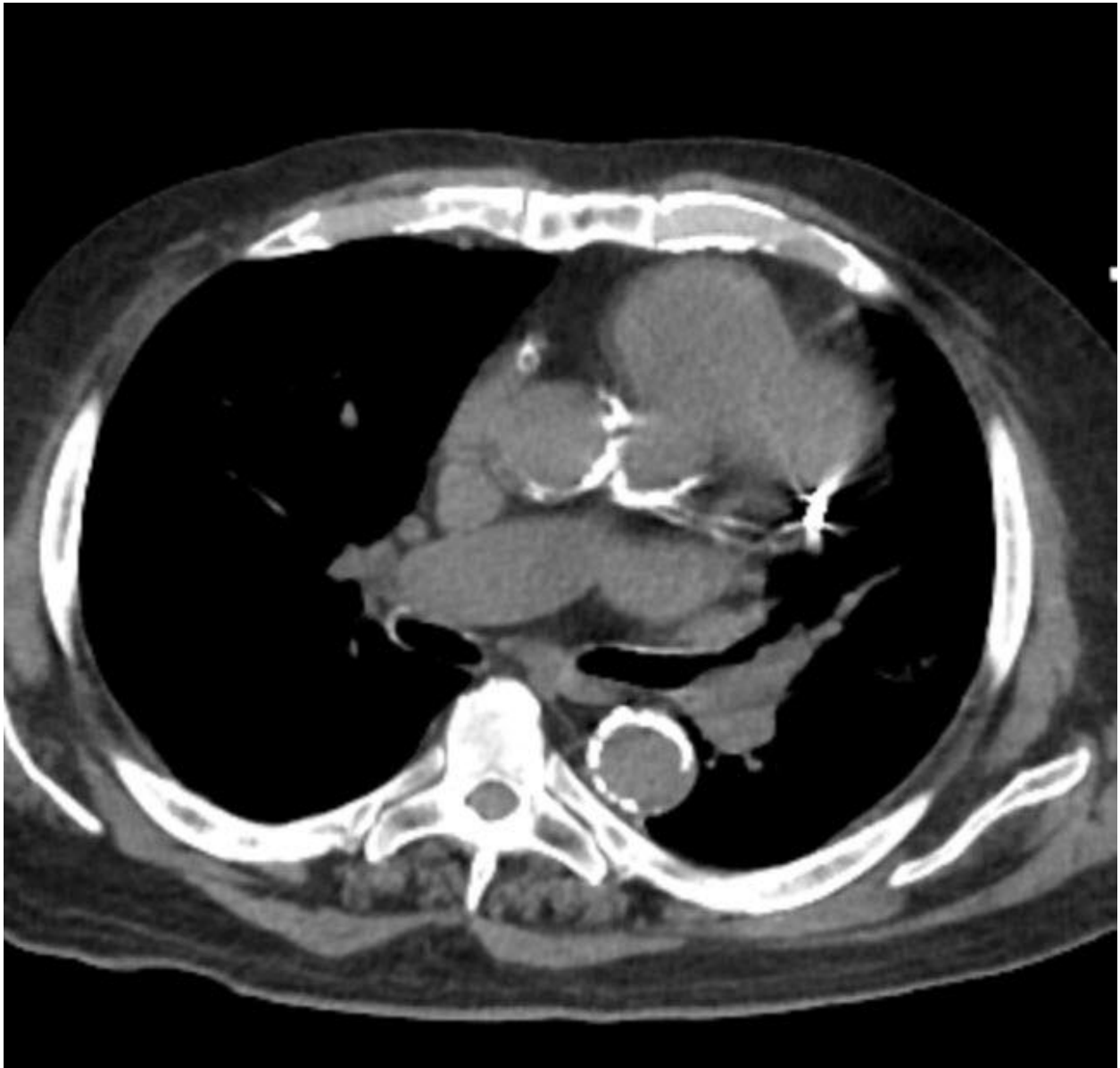


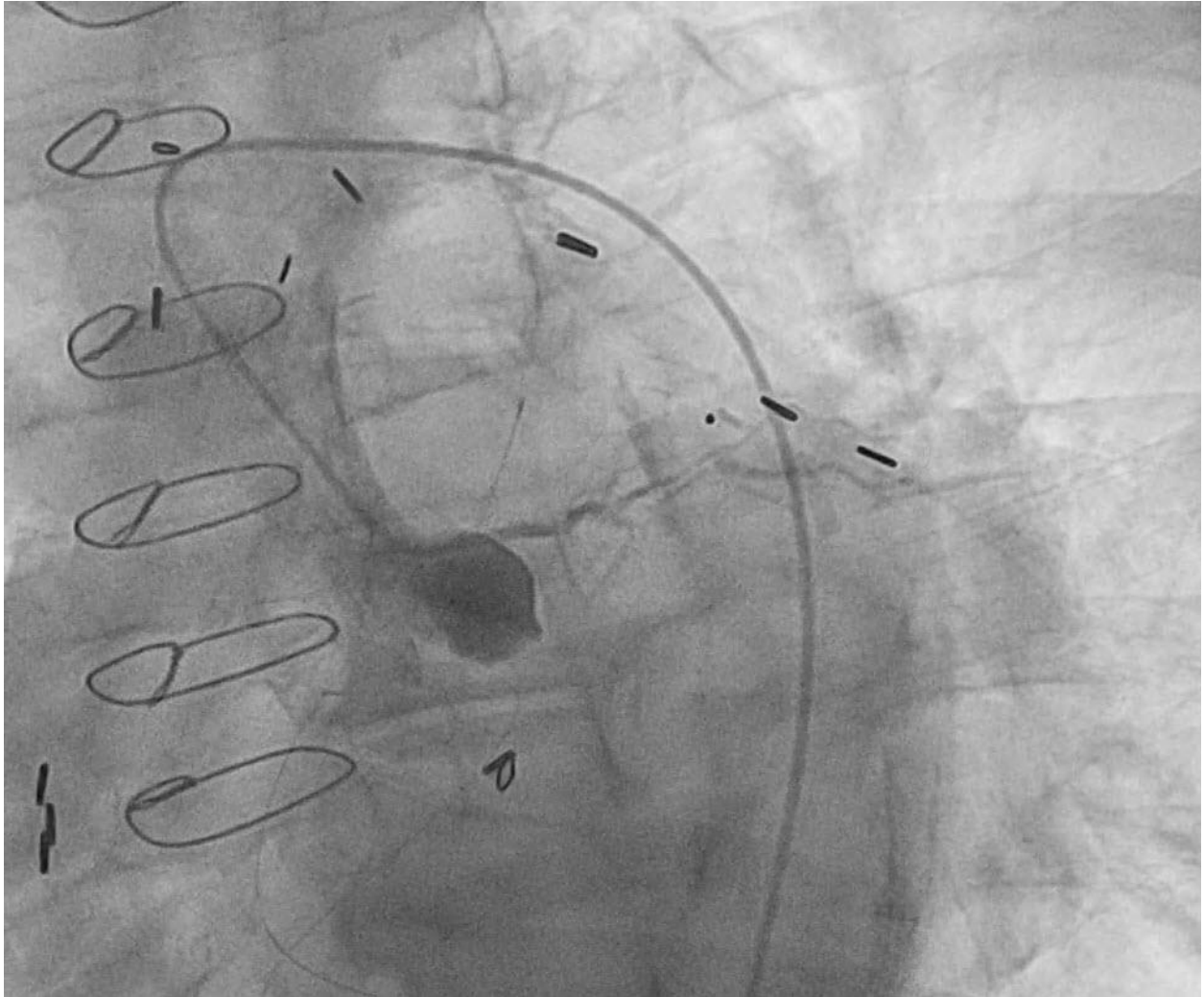
Case 21

Chest CT findings: Chest CT was performed four days before ICA. Patient had CABG. Diffuse heavy calcification of LM and RCA. Chest CT score: 3. Risk Class: E.

ICA findings. CABG. ICA score 4.



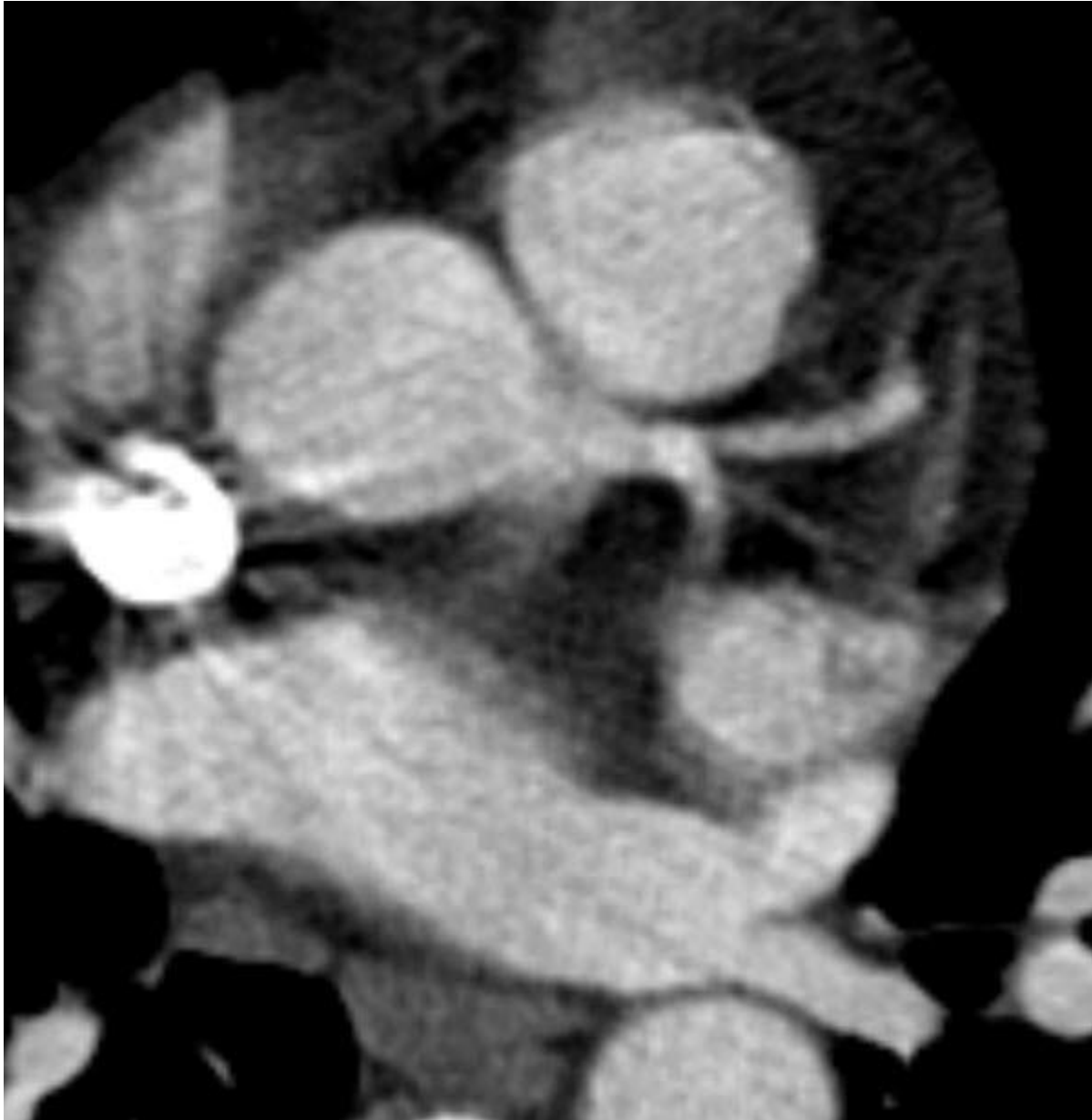


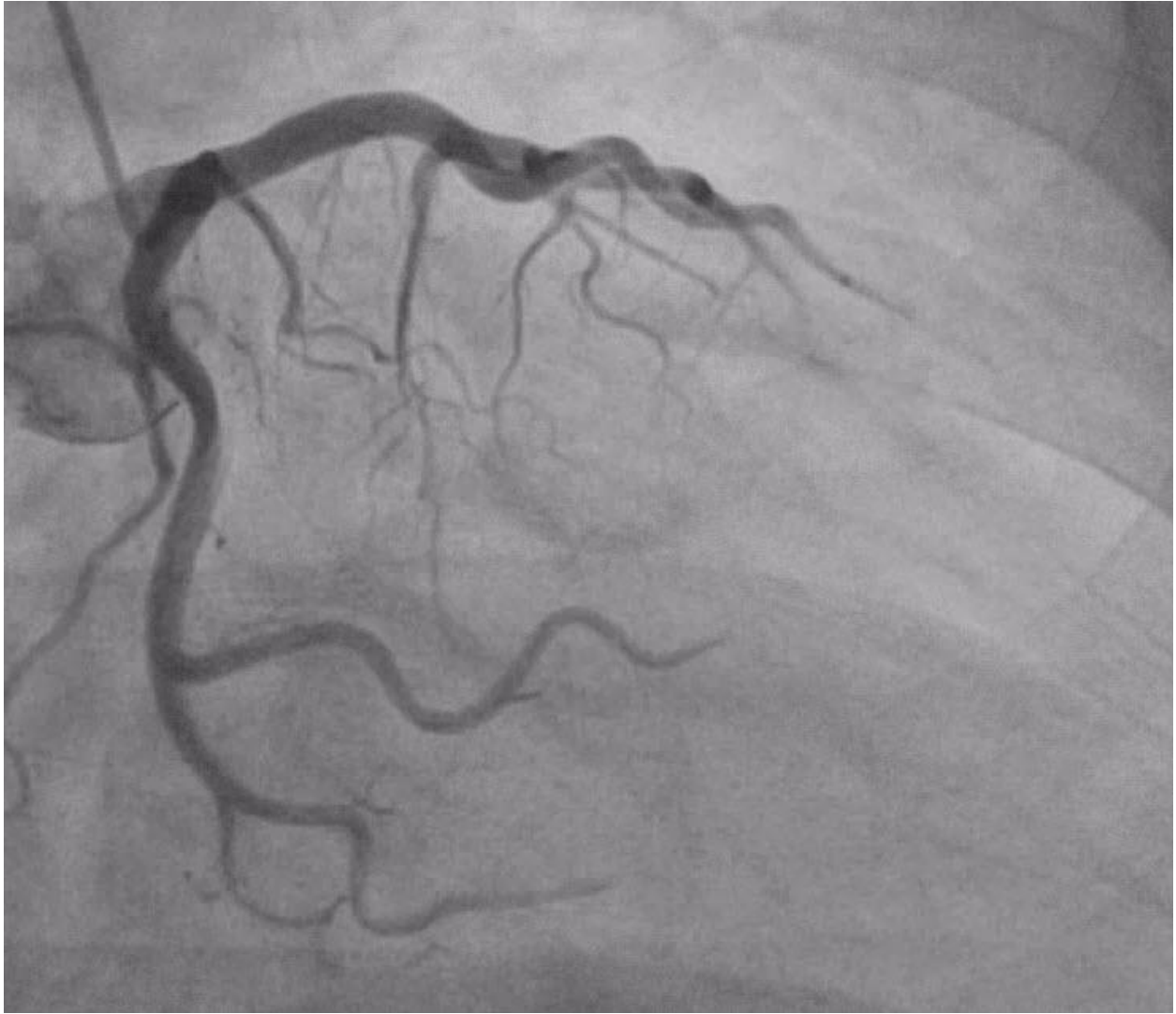
Case 22

Chest CT findings: Chest CT was performed two years before ICA. There is mild disease of proximal LAD. Chest CT score: 1. Risk Class: B.

ICA finding: Normal anatomy. ICA score: 0.

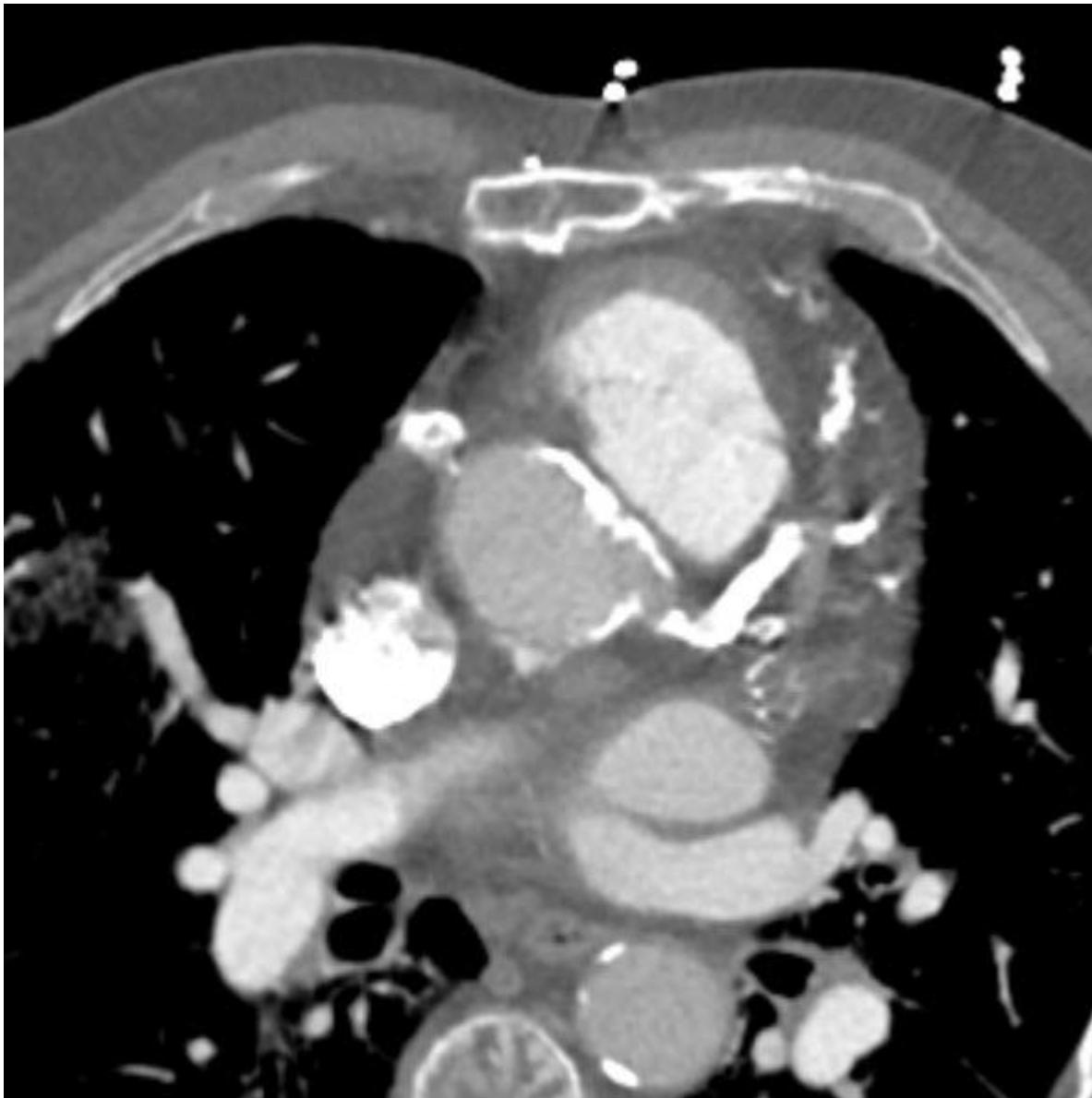


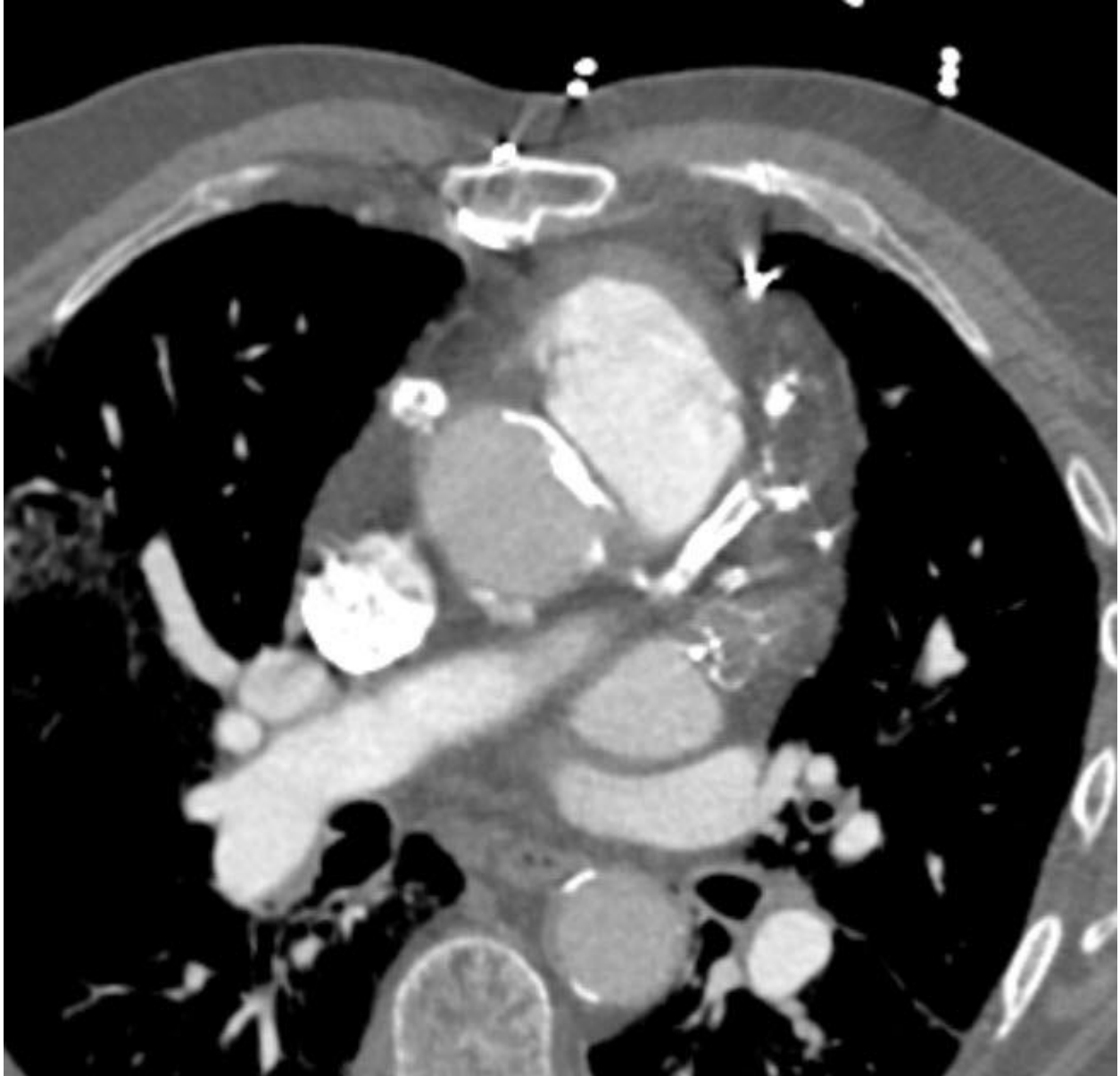

Case 23

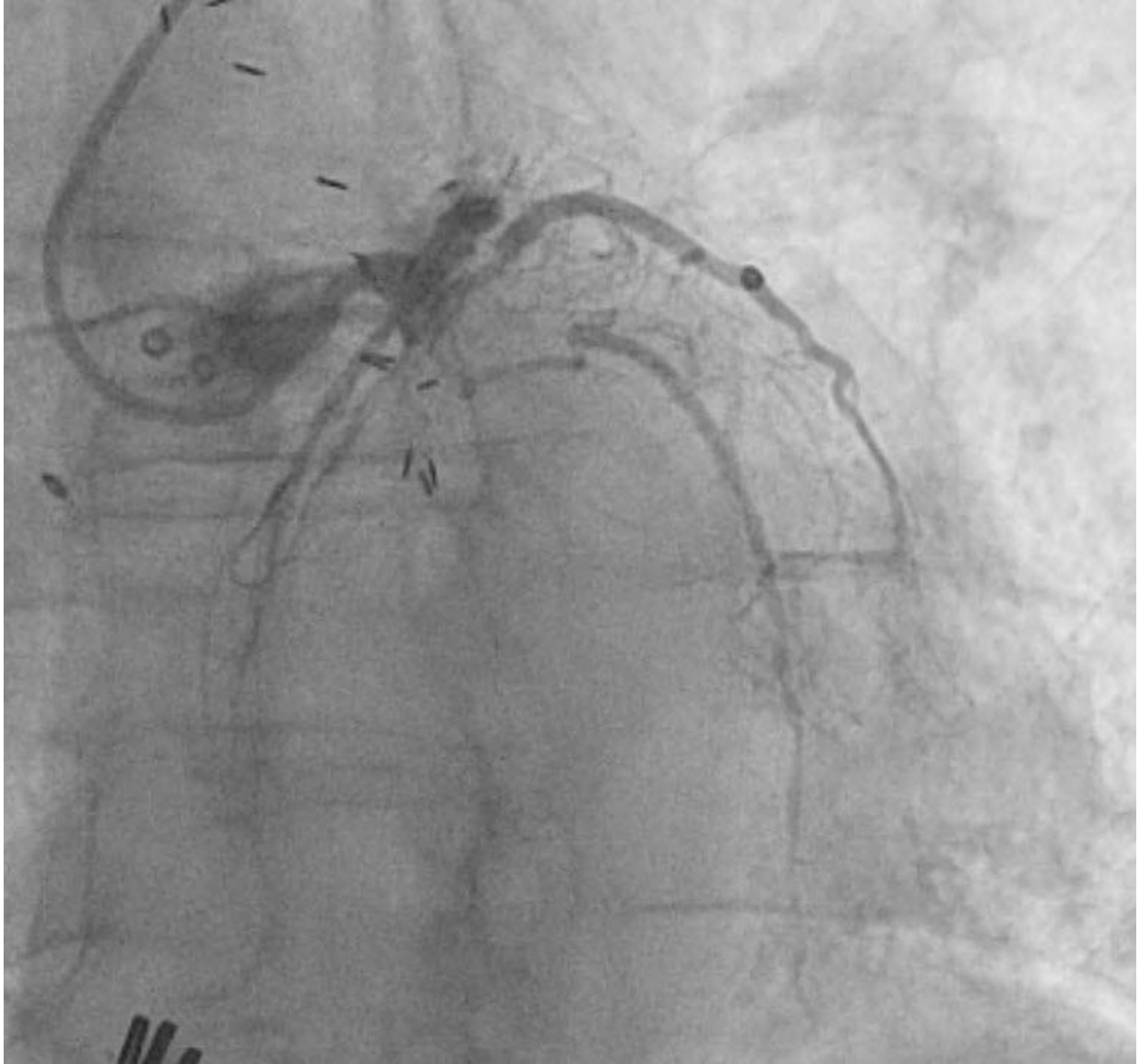Chest CT findings. Chest CT was performed seven days before ICA. Patient had CABG. Obstructive disease in LM and LAD. There is a presence of a Watchman device. Chest CT score 3. Risk Class: E.

ICA findings: Patient had CABG. There is LAD CTO. ICA score: 4.





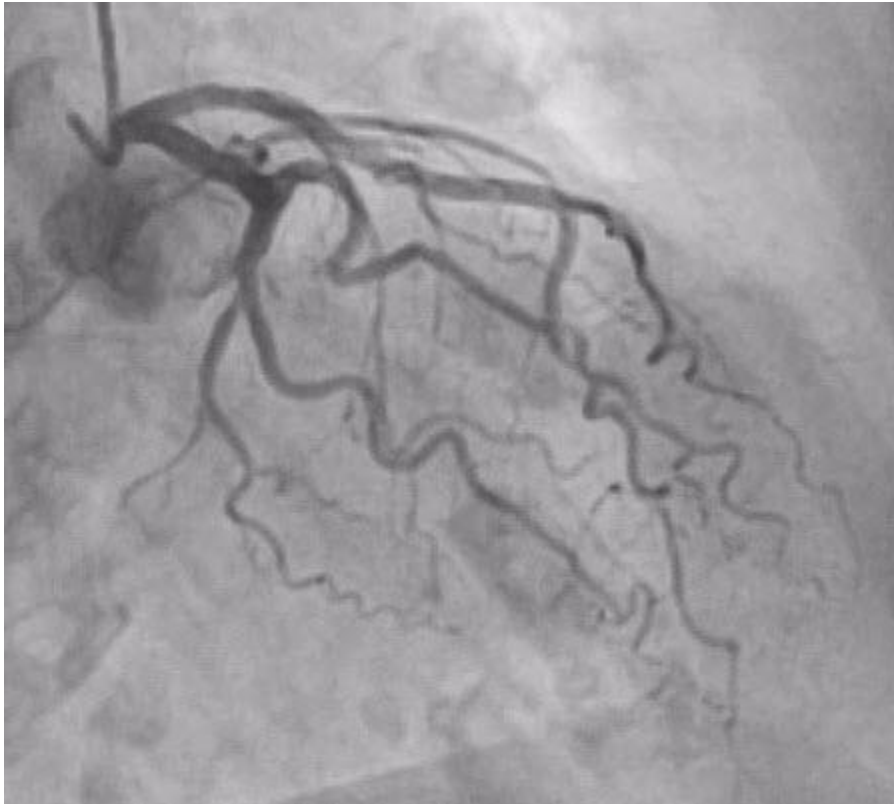


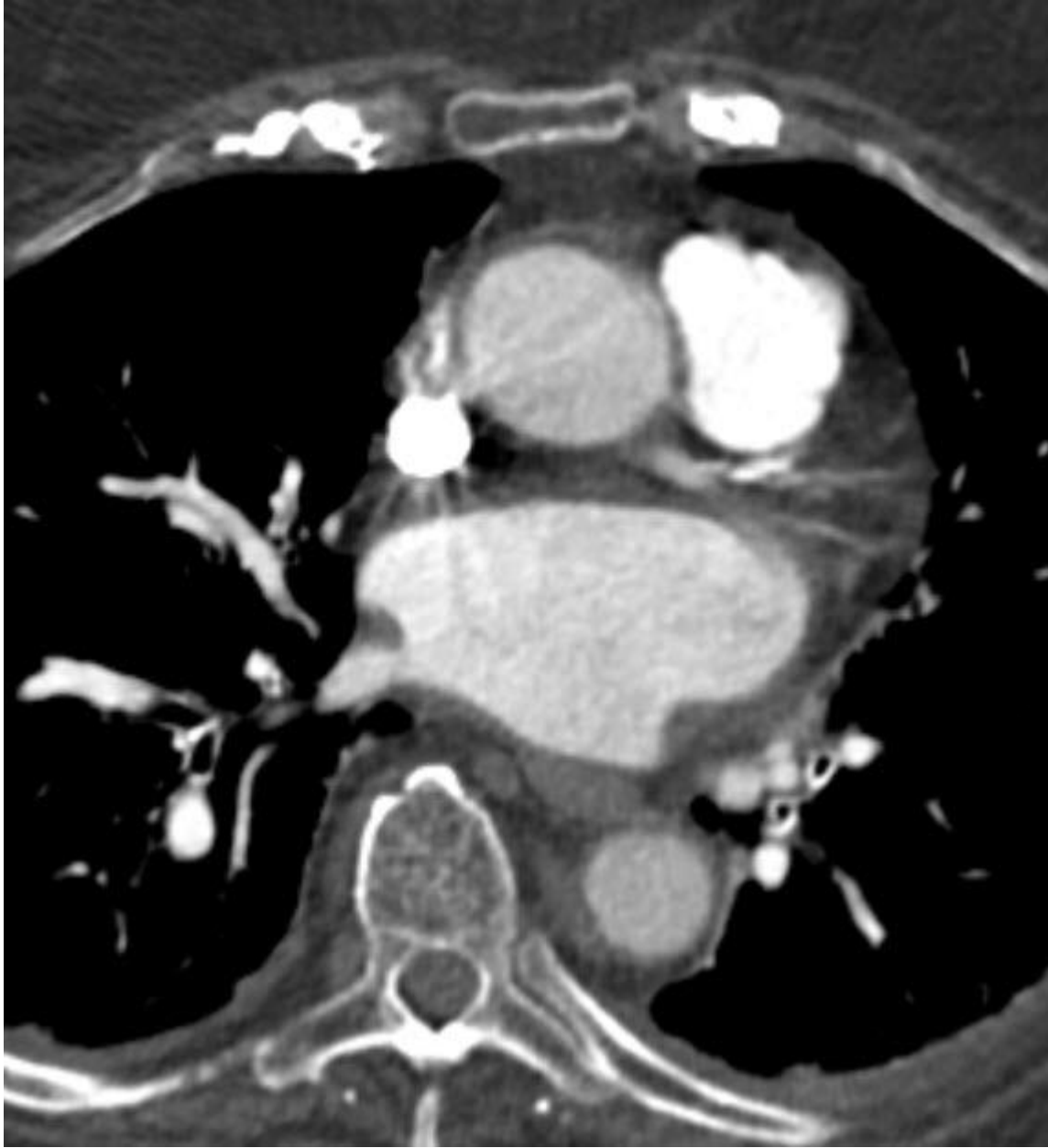
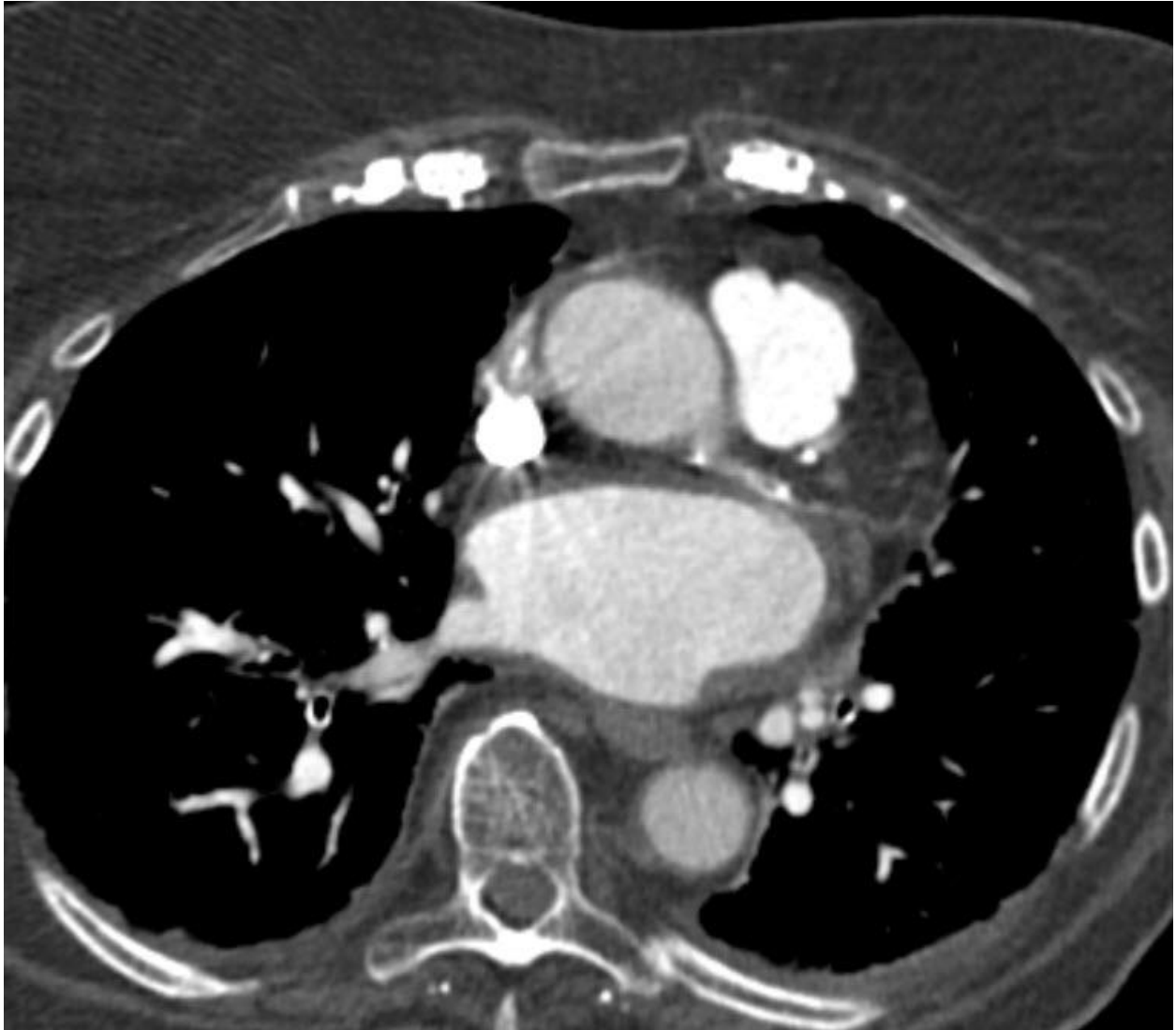
Case 24

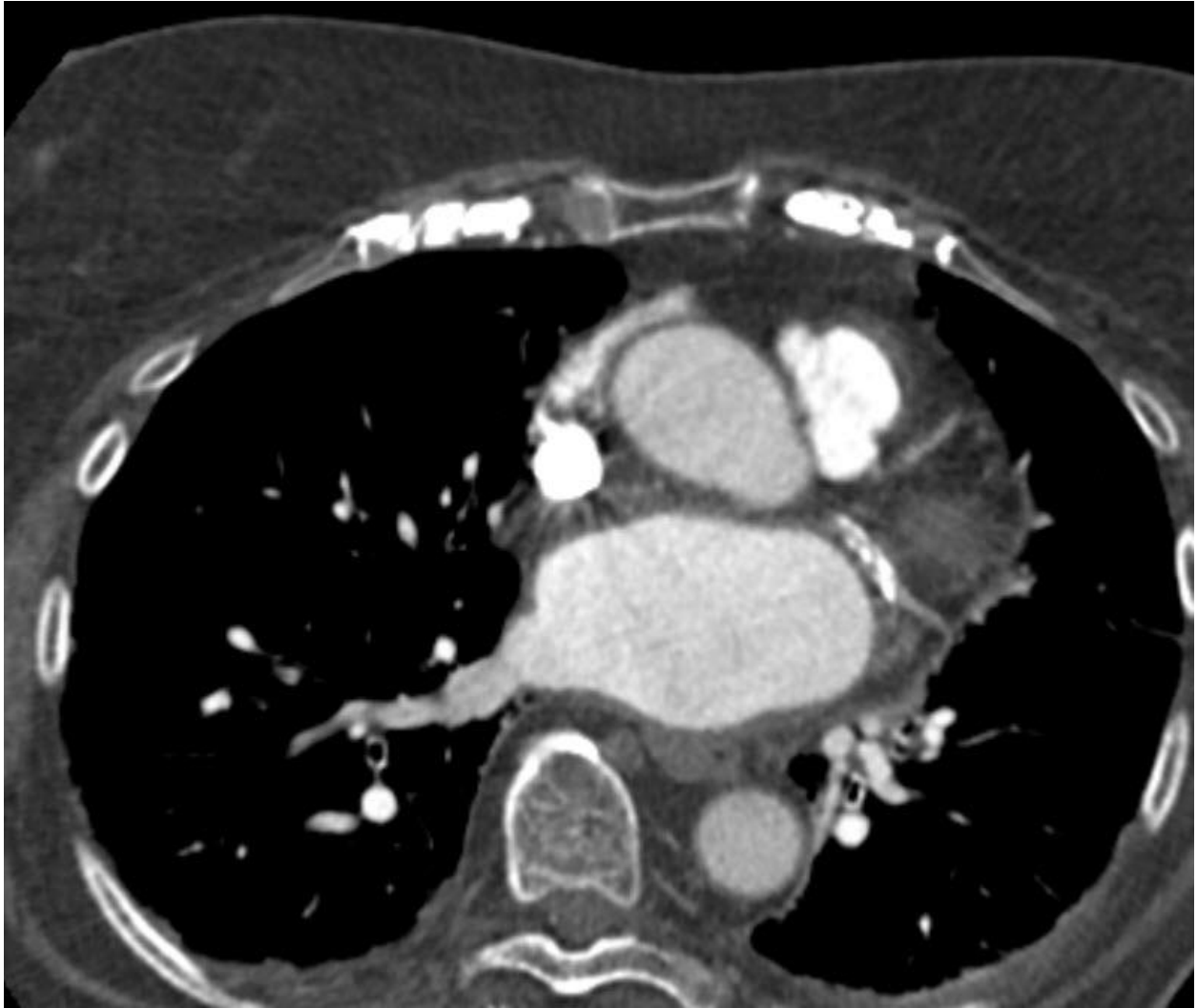ICA findings: ICA performed four years before chest CT. There is mild disease in LAD and LCX. ICA score: 1.

Chest CT findings: There is moderate disease of LAD and LCX. Chest CT score: 2. Risk Class: D.









End of File. Hope you find this information useful to treat your patients.