

EXTRACTION,IMMEDIATE IMPLANT-A CASE REPORT

Nezar Watted¹,KareemTrabih¹,Qawasmeh Nour², Abdulgani Azzaldeen²,Chlorokostas George ³ ,Abu-Hussein Muhamad¹

1.Center for Dentistry research and Aesthetics, Jatt/Israel

2. Faculty of Dentistry,Al-Quds University,Jerusalem,Palestine

3.Private practice,Athens,Greece

ABSTRACT:

Background: This case report describes extraction of a fractured right maxillary lateral incisor tooth, followed by immediate placement of a dental implant in the prepared socket and temporization by a bonded restoration.

Materials and Methods: The tooth was extracted with minimal hard and soft tissue trauma and without flap reflection. The socket was prepared to the required depth and a Biohorizons Implant was inserted. An impression was made 4 months after implant insertion, and a definitive restoration was placed.

Results: The atraumatic operating technique and the immediate insertion of the Implant resulted in the preservation of the hard and soft tissues at the extraction site. The patient exhibited no clinical or radiologic complications through two years of clinical monitoring after loading.

Conclusion: The dental implant and provisional restoration provided the patient with immediate esthetics, function, comfort and most importantly preservation of tissues.

Key words: Implant, Immediate placement, Temporization,crown



INTRODUCTION:

Missing teeth and supporting oral tissues have traditionally been replaced with dentures or bridges permitting restoration of chewing function, speech, and aesthetics ^[1]. Dental implants offer an alternative. These implants are inserted into the jawbones to support a dental prosthesis and are retained because of the intimacy of bone growth on to their surface ^[2]. This direct structural and functional connection between living

bone and implant surface, termed osseointegration, was first described by Branemark 1977 ^[2,3]and has undoubtedly been one of the most significant scientific breakthroughs in dentistry over the past 30 years. Teeth may have been lost through dental disease or trauma or they may be congenitally absent. However in many clinical situations compromised teeth or roots may still be present in the patient's mouth. Traditionally, before placing dental implants, compromised teeth were removed and the extraction

sockets were left to heal for between several months and 1 year. However, the great majority of patients are interested in shortening the treatment time between tooth extraction and implant placement or even better in having the implants inserted during the same session as the teeth are extracted (immediate implants) [4,5]. This would result Interventions for replacing missing teeth: dental implants in fresh extraction sockets. Implant placement in fresh extraction sockets is well documented [5]. Animal and human studies have demonstrated attainment of osseointegration following immediate placement of implant in freshly extracted tooth/teeth at a light microscopic level. In addition, numerous human clinical studies have documented high levels of success of implant placed at the time of tooth extraction and subsequently restored and in function [2,5,6].

CASE DETAIL:

A 53 year old boy reported of root stump in upper right front region and gave history of trauma to maxillary Left Lateral incisor due to accidental fall on floor during Cricket game three years back in which he had fractured crown and patient went for root canal treatment but left it incomplete due to negligence and slowly tooth crown was worn out(Fig.1,2). He was referred to Implantology for needful. Patient's general and medical history was taken and was non significant. Patient was examined clinically and Orthopantomograph was taken. After thorough analysis clinically and radiographically it was evaluated that there is no underlying pathology and tooth root was unrestorable but was surrounded by healthy bone. It was there and then decided to do

extraction and place the implant immediately and so was desired by the patient.(Fig.3)

Tooth root was extracted atraumatically under local anaesthesia after carefully raising the flap The pilot drill (D-2.0 mm) was put to use for creating a osteotomy site of the appropriate depth i.e. 15mm for implant placement (Biohorizon-implant system) . It is indexed with various markings corresponding to the desired implant lengths.

When appropriate depth was reached with the pilot drill, the implant depth probe was used for tactile perception of intact bony plates & or any perforations & the confirmation of desired osteotomy depth. Once desired depth was confirmed, paralleling pins were placed to check the proper alignment of the implant with adjacent teeth & opposing occlusion. After confirmation of depth & angulation, the osteotomy site was prepared by a series of gradually larger drills to the requisite width with a speed of 1400-1600 r.p.m at 1: 16 reduction torque as per manufacturer instructions. The Implant site was generously irrigated with sterile saline to remove any residual bone chips/other residue following preparation. The depth of the osteotomy site was ascertained with Implant depth probe.

The implant was removed from the sterile vial using the insertion tool and delivered directly into the osteotomy site. Contamination by touching the implant with instruments made of a dissimilar metal or by contact with soft tissue, cloth or even surgical gloves may affect the degree of osseointegration. The implant was then pressed into the prepared site with manual pressure aided by the insertion mount & insertion tool attached to the implant head. Following which, the insertion mount was removed and hex driver was placed into the implant internal hex & ratcheted with torque-

controlled implant ratchet. Implant was never forced into the socket with excessive force as this might lead to micro cracks in the surface bone resulting in improper osseointegration(Fig.,4,5). Implant that was placed was checked for stability by applying gentle pressure to determine if it could be depressed or rotated. Also, primary implant stability was assessed with the torque controlled ratchet. The cover screw, provided with the implant package was then placed using the hex-driver using finger pressure (Fig.6,7). At this point, implant was confirmed to be immobile, which re-affirmed primary implant stability.

The flap margins were then repositioned & sutured tension free using 3-0 mersilk in interrupted fashion (Fig.8). A radiograph was taken post operatively to evaluate the implant angulation & position (7).(Fig.9)

The patient was on regular recall and under strict oral hygiene measures.

The patient was recalled after 12 weeks radiograph was taken and prosthetic phase was carried out under the opinion & supervision of a prosthodontist. After soft tissue healing (Fig.10,11),

Impressions were made with the impression post attached to the implant using the closed tray impression technique. Shade selection was also done during this appointment. Casts with impression post-implant analogue complex, abutment, lab drivers and selected shade were sent to laboratory for preparation of cement retained porcelain fused to metal crown. Healing abutment/ gingival former was replaced till the time taken for laboratory manufacture of prosthesis. After approx. 4-7 days, the healing abutments were removed and replaced with final abutment. The PFM crown was checked for its passive fitting to abutment and non-interference with adjacent

teeth. Crown was then cemented with glass ionomer cement (Fig12,13,14). The patient was dispatched with a reminder of oral hygiene instructions & the recall programme.

DISCUSSION:

Many clinical reports and experimental studies in the animal model demonstrated the favorable outcome of dental implants immediately inserted in freshly extraction socket, without the use of any regenerative materials [2,3,5,8,9,10]. Our data show a survival rate of immediately implantation carried out on this patient at one year after immediate implantation and does not differ from the cases in which implant was placed in healed sites. These data agree with those from other authors who evaluated the clinical success rate of immediate implantation without use of any membrane or graft material in both humans and animals [11]. It must be kept in mind that the present study is related to immediate implant not subjected to functional loading and therefore not fully comparable with the results from loaded implants. However, it has been demonstrated that functional loading does not impair, but rather enhances, bone maturation. [5,12]

CONCLUSION:

This case report describes a technique to preserve and augment anterior aesthetics by combining atraumatic teeth extraction, hard and soft tissue augmentation, immediate provsionalization and using the platform switching concept to preserve the buccal plate. The gingival tissue surrounding the implants has remained

stable with no recession one year following final crowns placement.

The implant therapy must fulfill both functional and esthetic requirements to be considered a primary treatment modality. Aiming to reduce the process of alveolar bone resorption and treatment time, the immediate placement of endosseous implants into extraction sockets achieved high success rate of

REFERENCES:

1. Wagenberg BD, Ginsburg TR. Immediate implant placement on removal of the natural tooth: retrospective analysis of 1,081 implants. *Compendium of Continuing EducDent* 2001, 22:399-404
2. Bajali M., Abdulgani Azz., Abu-Hussein M.; EXTRACTION AND IMMEDIATE IMPLANT PLACEMENT, AND PROVISIONALIZATION WITH TWO YEARS FOLLOW-UP: A CASE REPORT, *Int J Dent Health Sci* 2014; 1(2): 229-236
3. Branemark et al. Osseointegrated implants in the treatment of the edentulous jaw. Experience from a 10-year period. Stockholm: Almqvist & Wiksell Int, 1977.
4. Douglass GL, Merin RL. The immediate dental implant. *J California Dent Assoc* 2002,30:362-5
5. Abu-Hussein M., Abdulghani A., Sarafianou A., Kontoes N.; Implants into fresh extraction site: A literature review, case immediate placement report, *Journal of Dental Implants* . 2013 , 3; 2,160-164
6. Gomez-Roman G, Schulte W, d'Hoedt B, Axman-Krcmar D. The Frialit-2 implant system: five-year clinical experience in single-tooth and immediately postextraction applications. *The International Journal of Oral and Maxillofacial Implants* 1997;12(3):299–309.
7. Schwartz-Arad, D, Chaushu G. The ways and wherefore of immediate placement of implants into fresh extraction sites. A literature review. *J of Periodontol* 1997; 68:915-923.
8. Esposito M, GrusovinMG, Worthington H, Coulthard P. Intervention for replacing missing teeth: bone augmentation techniques for dental implant treatment. *Cochrane Database of Systematic Reviews*. 2006; issue 1.
9. Esposito M, Hirsch JM, Lekholm U, Thomsen P. Biological factors contributing to failures of osseointegrated oral implants. (II) Etiopathogenesis. *European Journal of Oral Sciences* 1998;106(3):721-764
10. Schwartz-Arad, D, Chaushu G. Placement of implants into fresh extraction sites: 4-7 years' retrospective evaluation of 95 immediate implants. *J of Periodontol* 1997; 68:1110-1116.
11. Strub JR, Kohal RJ, Klaus G, Ferraresso F. The reimplant system for immediate implant placement. *J Esthet Dent* 1997, 9:187-96
12. Michele Paolantonio, Marco Dolci, Domenico D' Archivio, et al. Immediate implantation into fresh extraction sockets. A controlled clinical trial and histological study in man. *J of Periodontol* 2001; 72:1560-1571.

FIGURES:

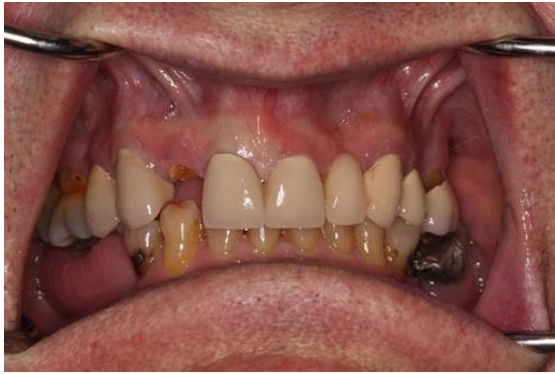

Fig.1. Fractured lateral

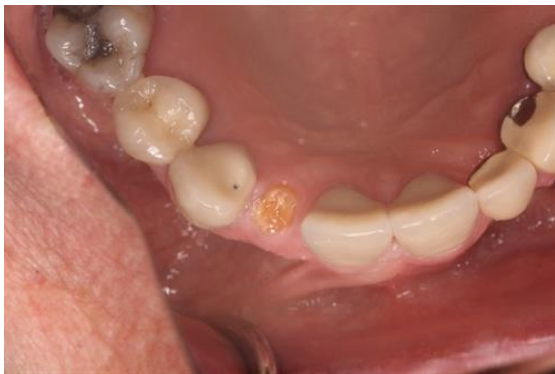

Fig.2: Occlusal view

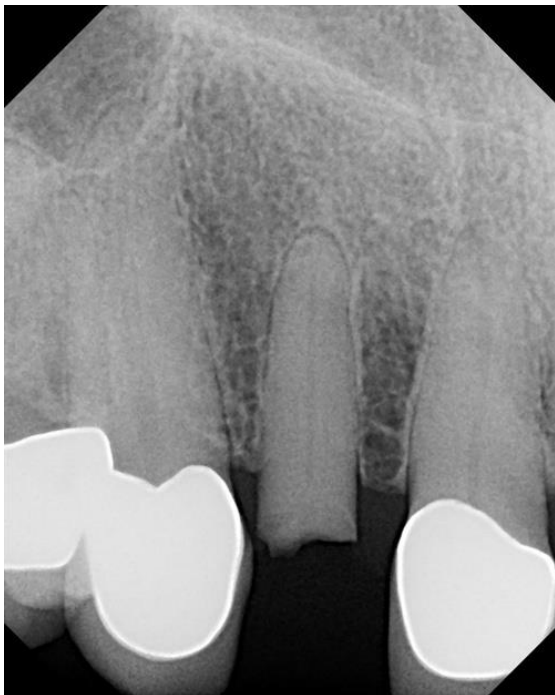

Fig.3: Initial PA

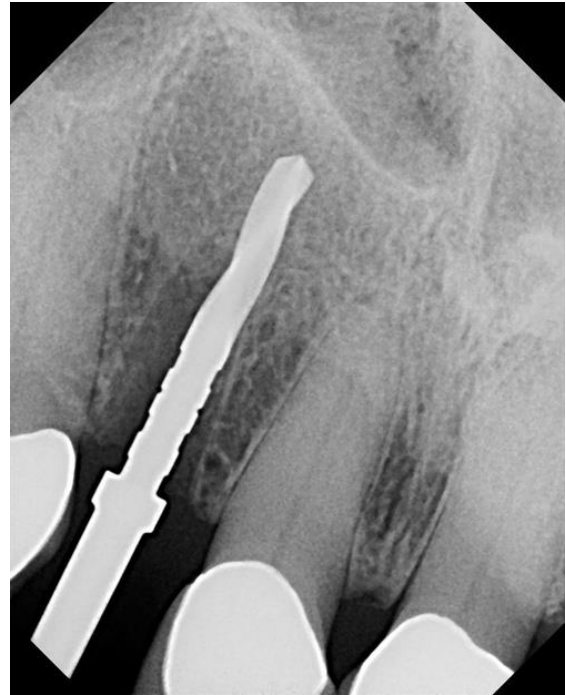

Fig.4:PA post extraction with 15mm 2.0 drill

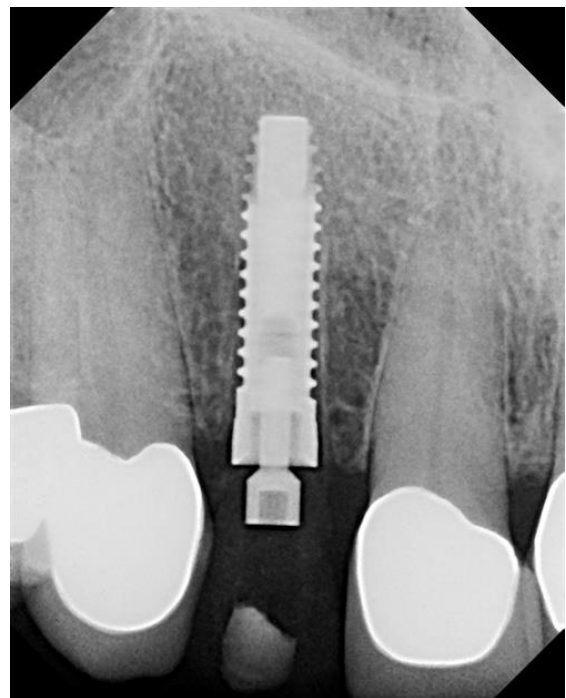


Fig.5:PA of implant with screw retained temporary

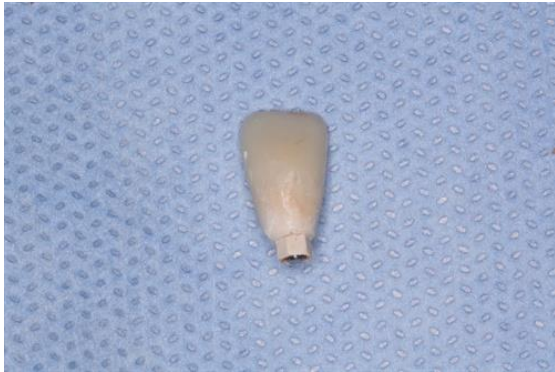

Fig.6: Peek prefab abutment with stock temp crown

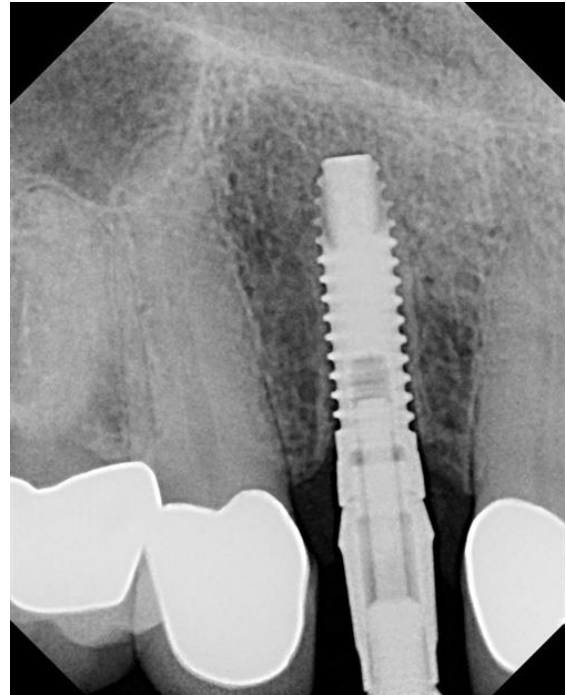


Fig.9: PA to confirm seating

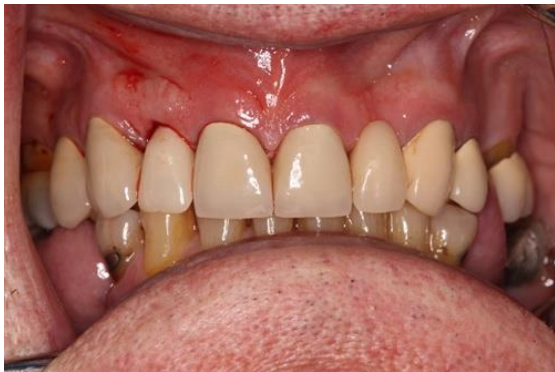

Fig.7:Temp in mouth the day of surgery

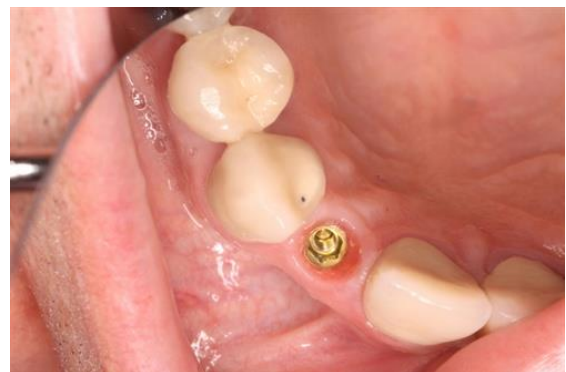

Fig.10: Cement appt, view of tissue

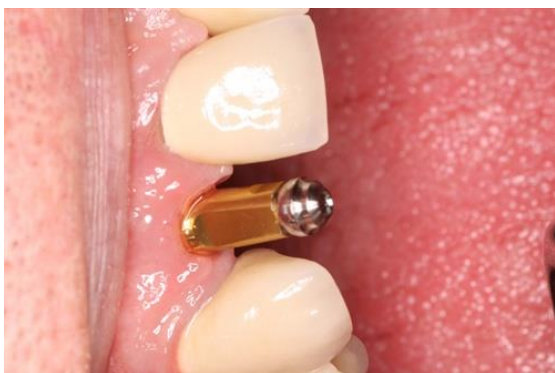

Fig.8: 4 months later impression, stock abutment with ball screw.

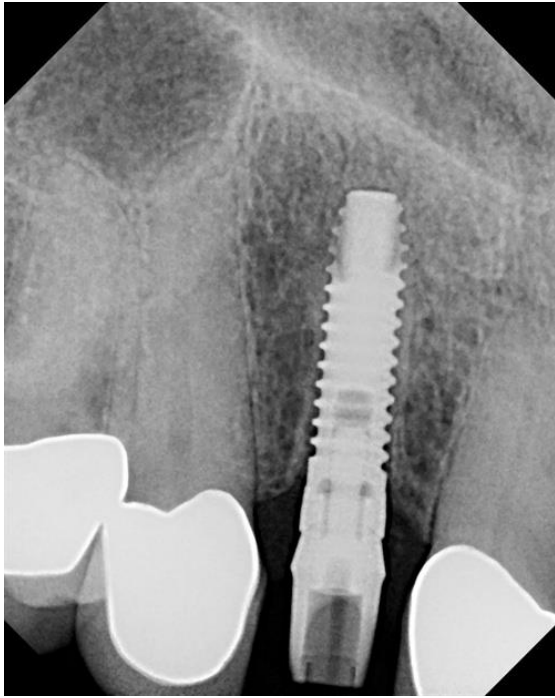


Fig.11: Stock abutment PA to confirm seating

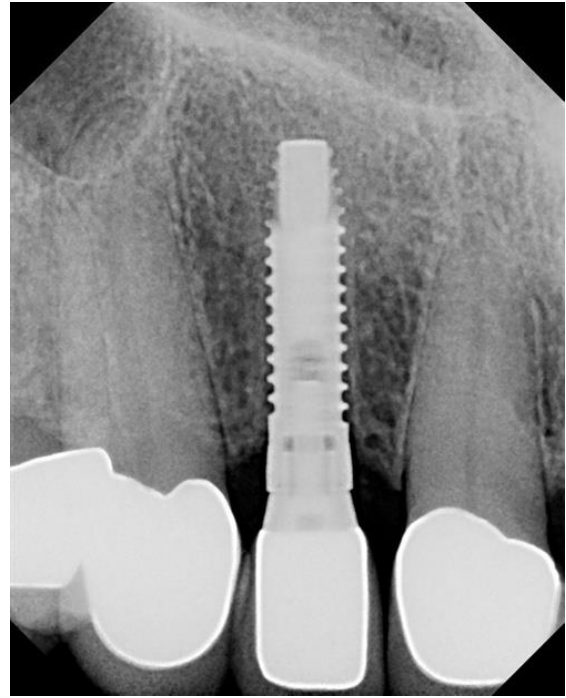


Fig.13: Crown cement PA

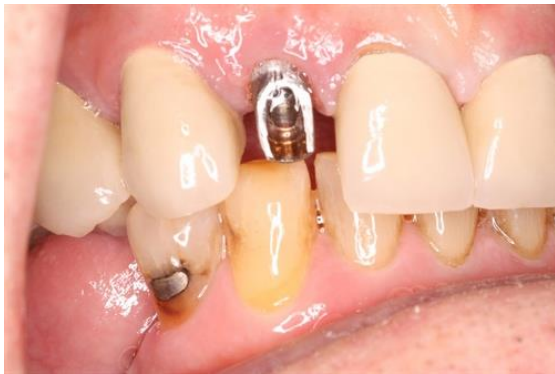

Fig.12: View of prepped stock abutment in mouth

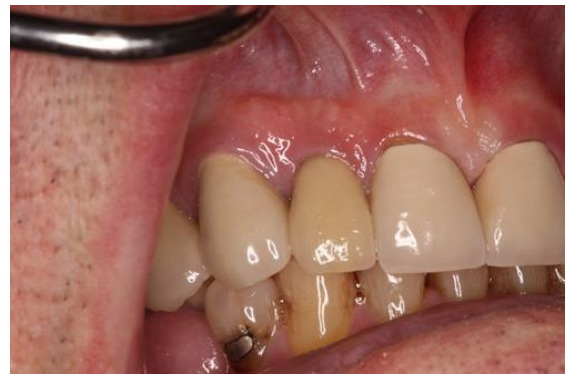

Fig.14: Final crown the day of cementing