

CLINICAL OUTCOMES OF THE MAXILLARY SINUS FLOOR AUGMENTATION USING DIFFERENT AUGMENTATION MATERIALS WITH SIMULTANEOUS IMPLANT PLACEMENT : A SYSTEMATIC REVIEW

Amr Zahran¹, Ahmed Reda², Ahmed mortada³

1. Professor of periodontology and implantology , Cairo university, Egypt

2. Lecturer of periodontology and implantology , Cairo university, Egypt

3. Assistant lecturer of periodontology and implantology , Assiut university, Egypt

ABSTRACT:

Background: To date, there are still no clear cut guidelines for the maxillary sinus floor augmentation technique materials either by autogenous bone or bone substitutes or by platelet rich fibrin or by graftless augmentation with simultaneous implant placement .

Aim: The aim of the present review was to analyze the current literature in order to determine whether there are advantages of using autogenous bone (AB) over bone substitutes (BS) or platelet rich fibrin (PRF) in sinus floor augmentation or by graftless augmentation . The focused question was: is AB superior to BS or platelet rich fibrin (PRF) in sinus floor augmentation or by graftless maxillary sinus floor augmentation in partially dentate or edentulous patients in terms of implant survival, patient morbidity, sinusitis, graft loss, costs, and risk of disease transmission?

Materials and methods: The analysis was limited to titanium implants with modified surfaces placed in sites with 6mm of residual bone height and a lateral wall approach to the sinus. A literature search was performed for human studies focusing on sinus floor augmentation. Results: nine articles were included in the review. The highest level of evidence consisted of prospective cohort studies. A descriptive analysis of the constructed evidence tables indicated that the type of graft did not seem to be associated with the success of the procedure, its complications, or implant survival. Length of healing period, simultaneous implant placement or a staged approach or the height of the residual alveolar crest, sinusitis or graft loss did not modify the lack of effect of graft material on the outcomes. The studies documented that there was donor site morbidity present after the harvest of AB. When iliac crest bone was harvested this sometimes required hospitalization and surgery under general anesthesia. Moreover, bone harvest extended the operating time. The assessment of disease transmission by BS was not a topic of any of the included articles.

Discussion and Conclusion: The retrieved evidence provides a low level of support for selection of AB or a bone substitute or any other types of materials .Clear reasons could not be identified that should prompt the clinician to prefer AB or BS any other types of materials.

Keywords: autogenous bone, bone substitute, complication, implant survival, sinus floor augmentation, platelet rich fibrin, graft less



INTRODUCTION:

Sinus floor augmentation is a technique based on the elevation of the sinus membrane from the floor of the maxillary sinus. Various graft materials have been used to fill the newly formed space. Autogenous bone (AB), allografts, xenografts, alloplastic materials, and mixtures of various materials have been proposed for this purpose (Wheeler 1997). AB is very popular for sinus floor augmentation, because it possesses osteoconductive, osteoinductive, and osteogenic properties (Galindo-Moreno et al. 2008).

Unfortunately, the harvest of AB requires donor site surgery and potentially increases patient morbidity (Nkenke et al. 2004). In this context, it is important to note that maxillary sinus floor augmentation is an elective procedure. In such kind of surgery, it should always be a priority to reduce patient morbidity to a minimum.

It has been clearly stated that donor site morbidity cannot be ignored when AB is used for maxillary sinus floor augmentation (Kunzler et al. 1999; Raghoebar et al. 1999). Harvesting AB from intraoral sites can be associated with a number of problems like devitalization of anterior mandibular teeth by involvement of tooth apices, changes in facial esthetics, possible damage to mental and lower dental nerves, and increased risk of mandibular ramus fracture when intraoral donor sites are chosen (Galindo-Moreno et al. 2007).

Bone harvest from extraoral sites may cause hemorrhage, instability of the sacroiliac joint, hernia through the donor site, a dynamic ileus, or gait disturbances (Kalk et al. 1996). As a consequence, the use of AB for sinus floor augmentation has been questioned (Tadjoedin et al. 2002). Therefore, it was the aim of the present review to determine whether there are advantages in using AB over bone substitutes (BS) or (PRF) or by graftless technique for sinus floor augmentation. The question focused on was: what is the best material used in the lateral approach maxillary sinus floor augmentation with simultaneous implant placement .

MATERIALS AND METHODS

Search strategy

A systematic search strategy was used. In the initial phase of the review, a computerized literature search for human studies was performed (22-8-2015). There was no language restriction. In addition, a hand search was carried out. Moreover, the Cochrane Controlled Trials Register and The Cochrane Health Group Specialized Register were checked for publications on sinus floor augmentation. The full text of reviews was obtained from reviews on sinus floor augmentation published to date of (22-8-2015) Additional publications were identified from the reference lists of the retrieved articles.

Search terms Keywords
were((((((((((platelet rich fibrin implants)
OR platelet rich fibrin sinus) OR platelet
rich fibrin sinus lift)) OR (((((autogenous
bone) OR autogenous bone grafts) OR
autogenous bone graft) OR autogenous
bone grafting) OR autogenous bone graft
dental implants)) OR (((allograft) OR bone
allograft) OR allograft bone)) OR
((((alloplastic) OR alloplastic bone) OR
alloplastic bone graft) OR alloplastic bone
substitutes) OR alloplastic implant)) OR
((graftless) OR graftless sinus))) AND
((((((maxillary sinus augmentation) OR
maxillary sinus elevation) OR maxillary
sinus floor elevation) OR maxillary sinus
lifting)) OR maxillary sinus lift))) AND
((((dental implants) OR implants) OR
implants) OR titanium implants) OR
implants dental))) AND survival of
implants were used.

Inclusion criteria The inclusion criteria for
study selection were:

(i) clinical studies, (ii) lateral window
approach to the sinus, (iii) use of root-form
or cylindrical titanium implants with
modified surfaces, (iv) studies with a
follow-up interval of at least 6 months
after simultaneous implant placement in
the region of the sinus floor
augmentation, (v) average residual height
of pristine bone in the region of sinus floor
augmentation of a maximum of 6mm, (vi)
defined survival or success criteria for the
implants placed in the region of the sinus
floor augmentation, (vii) documentation
of the implant survival rate after a defined
period of time, and (viii) a sample size of
at least 6 patients.

Exclusion criteria Publications dealing with
invitro studies or preclinical (animal)
studies were excluded.

Human studies not meeting all inclusion
criteria were also excluded from the
review: In addition, studies were excluded
if

(i) additional augmentation procedures
were carried out besides sinus floor
augmentation, (ii) survival rates or success
rates could not be distinguished for rough-
and smooth-surfaced implants, (iii) they
reported on the same patient cohort, and
(iv) personal communication was included
in the paper.

Selection of studies Titles derived from
this broad search were independently
screened by the three authors based on
the inclusion criteria. Disagreements were
resolved by discussion. Following this,
abstracts of all titles agreed on by all
authors were obtained and screened for
meeting the inclusion criteria. If no
abstract was available in the database, the
abstract of the printed article was used.
The selected articles were then obtained
in full text. If the title and abstract did not
provide sufficient information regarding
the inclusion criteria, the full report was
obtained as well. Again, disagreements
were resolved by discussion. Finally, the
selection based on inclusion and exclusion
criteria was made for the full-text articles.
For this purpose, Material and Methods
and Results of these studies were
screened. This step was again carried out
independently by the authors.

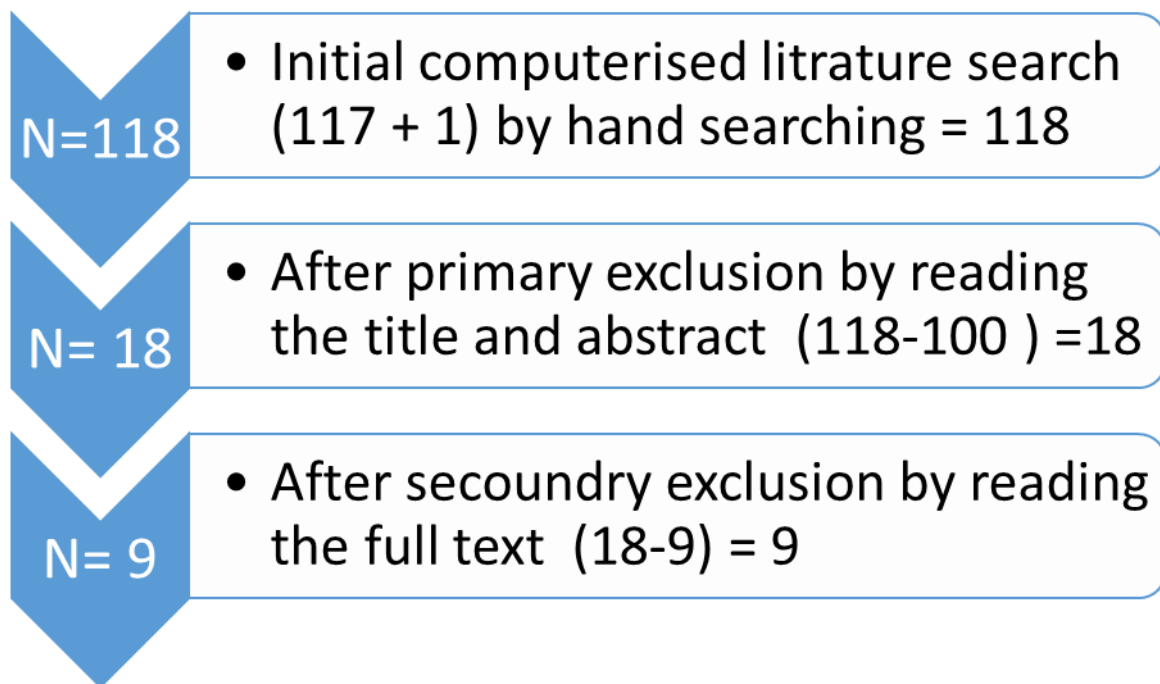
Disagreements were resolved by discussion (Diagram. 1).

Data extraction : Three reviewers independently extracted the data using data extraction tables. Any disagreements were resolved by double-checking the original data and by discussion. From the selected papers, data were extracted on author(s), year of publication, study design, total number of patients, inclusion and exclusion criteria, follow-up period, patients lost to follow-up, healing period, simultaneous implant placement or staged approach, height of residual alveolar crest, sinus mucosa perforation, operating time, sinusitis, graft loss, patient morbidity, disease transmission, and costs. All abbreviations used in the text are given in Table 1.

Table 1 : list of abbreviations :

| | |
|-------|---|
| AB | Autogenous bone |
| BS | Bone substitutes |
| PRF | Platelet Rich Fibrin |
| FDBA | Freezed dried bone allograft |
| DFDBA | Demerelaised freezed dried bone allograft |
| NS | Not specified |
| CJD | Creutzfeldt–Jakob disease |
| vCJD | The new variant CJD |
| BSE | Bovine spongiform encephalopathy |
| VB | Venous blood |
| BMP | Bone morphogenic proteins |

Diagram 1: Flow chart



| | |
|--|---------------|
| Initial computerized search after removal of duplicates | N= 117 |
| Hand searching (one article) | N= 118 |
| After Primary exclusion (-100) | N=18 |
| After secondary exclusion (-9) | N=9 |

RESULTS:

Study characteristics by the electronic literature search, 117 titles were identified and one article was added by hand searching . nine original articles fulfilled the inclusion criteria (Diag. 1). The studies with the highest level of evidence were prospective cohort studies (Table 2). Exclusion of studies The reasons for excluding studies after the full text was obtained were two stages non simultaneous implant placement with sinus floor augmentation (9 articles), case report (one article), technique of sinus floor augmentation not assigned (one article) .(Diag. 1).

List of excluded articles

| Title | Authors | Reasons of exclusion |
|---|-------------------------------------|---|
| Volume changes of autogenous bone after sinus lifting and grafting procedures: A 6-year computerized tomographic follow-up | (Carolina Sbordone etal .2013) | Case report study (one case) |
| RehabilitationoftheEdentulousPosterior Maxilla After Sinus Floor Elevation Using Deproteinized Bovine Bone: A 9-Year Clinical Study | (Rita Oliveira etal .2012) | Two stages implant placement (not simultaneous) |
| Comparative Study of Alveolar Bone Height and Implant Survival Rate Between Autogenous Bone Mixed with Platelet Rich Plasma Versus Venous Blood for Maxillary Sinus Lift Augmentation Procedure | (Namineni Kiran Kumar, etal. 2015) | Two stages implant placement after 4-6 months (not simultaneous) |
| Radiographic comparison of different | Froum SJ, etal 2014) | The technique of sinus floor |

Included studies

Nine articles were selected for inclusion in the review. They are presented in Tables 2–8. Nine studies reported inclusion and exclusion criteria for their patients. Most often, patients with a history of sinusitis, immune system disorders, and uncontrolled systemic diseases were excluded. While most of the studies excluded smokers (Table 3). Patients lost to follow-up were documented (Table 4). The approach to the sinus through the lateral antral wall was either performed by a trap door technique or by the preparation of an access hole by removal of the buccal bone plate (Table 4). In some studies, the approach was not reported in detail. In the included studies, groups with sinus floor augmentation and simultaneous implant placement and groups with a staged approach were excluded. In these studies, the decision on the use of one or the other technique was based on the height of the residual crestal bone beyond the sinus to ensure the implant primary stability .

| | | |
|---|----------------------------------|--|
| concentrations of recombinant human bone morphogenetic protein with allogenic bone compared with the use of 100% mineralized cancellous bone allograft in maxillary sinus grafting. | | augmentation was not assigned (crestal or lateral approach) |
| Maxillary sinus floor elevation surgery with BioOss® mixed with a bone marrow concentrate or autogenous bone: test of principle on implant survival and clinical performance. | Rickert D, etal. 2013 | Staged implant placement after 3-4 months (not simultaneous) |
| Atrophic maxillary floor augmentation by mineralized human bone allograft in sinuses of different size: an histologic and histomorphometric analysis | (Carlo Maria Soardi , etal.2010) | Two stages implant placement after 6-9 months (not simultaneous) |
| Histologic and histomorphometric evaluation of a synthetic bone substitute for maxillary sinus grafting in humans | (Mauro Tosta , etal. 2011) | Two stages implant placement after 9 months (not simultaneous) |

Table 2 . Study design and basic patient data

| The author | Design of study | No. patients | No. Sinuses | Age (years) | Mean of age | Residual bone height |
|-------------------------------|-----------------|--------------|------------------|-------------|-------------|----------------------|
| Kunal Jodia etal.2013 | NS | 12 | 13 | 20-50 | | More than 5mm |
| Naoki Hatano etal.2003 | NS | 191 | | | 55.9(+9.7) | 4-6mm |
| Gavriel Chaushu etal.2009 | NS | 28 | | 24-65 | 54(+9) | 4-5mm |
| Maurizio silvestri etal. 2013 | RCCT | 37 | 42 | 35-68 | | 2-5MM |
| Fabio L. Borges etal. 2011 | RCCT | 17 | 17*2 Split mouth | Ns | 57.9 | More than 3mm |
| Tassos irinakis etal.2011 | Retrospective | 49 | 27 + 22 | Ns | Ns | More than 3mm |
| Wang Peng etal.2013 | NS | 24 | 29 | Ns | Ns | 1.9-6.6 |
| Young-Kyun Kim etal.,2014 | NS | 30 | 25 | Ns | Ns | Less than 5mm |
| Nobutaka Tajima etal.,2013 | Ns | 6 | 9 | 53-82 | 67.8 | 1.9-6mm (4.3+-1)mm |

(Table 5). No differences were detectable for implant survival rates for the different graft materials that were associated by simultaneous implant placement. A wide variety of sources for AB were used. AB from the chin, the mandibular ramus, the calvarium, and the iliac crest was included. Donor site morbidity was specified in the studies (Marchetti et al. 2007). Harvesting of bone from the iliac crest led to donor site morbidity within the first two postoperative weeks (Marchetti et al. 2007). Donor site infections were found

after harvest of mandibular ramus grafts. Hematomas, penetration into the cranial cavity, and minimal patches of alopecia were found after harvest of calvarial bone (Iturriaga & Ruiz 2004). The length of the healing periods did not seem to influence implant survival in dependence of the graft material used. The implant survival rate was not influenced by the use of AB alone or BS or PRF or graftless sinus floor augmentation.

None of the studies examined whether systemic diseases or other risk factors had an influence on implant survival in

dependence of the different graft materials used. The resorption of the graft material over time was documented in some of the studies (Hallman & Nordin 2004; Kim et al. 2009). Graft resorption did not seem to influence implant survival in dependence of the graft material used. None of the studies that used allogenic or xenogenic material was designed to report on the transmission of infectious diseases. Cases of disease transmission were not documented in any of the studies. The aspect of cost was not explicitly treated in any of the studies. However, it was reported that bone harvesting led to an extension of operating time of up to 15min, when intraoral donor sites were chosen (Peleg et al. 2004). Moreover, it was mentioned that surgery was carried out under general anesthesia when iliac crest bone was harvested and that patients were hospitalized up to 5 days after this procedure (Marchetti et al. 2007).

DISCUSSION:

Sinus floor augmentation is one of the most reliable procedures in preprosthetic surgery. A number of systematic reviews and meta- analyses have been performed on this topic (Table 9). These reviews have shown that titanium implants without modified surfaces performed significantly worse than implants with modified surfaces when placed following sinus floor augmentation. Therefore, implants without modified surfaces were excluded from the present review. Based on this major change compared with the previous reviews, the aim to determine whether

there are advantages in using AB compared with BS , PRF and graftless sinus floor augmentation. The question focused on was: is AB superior to BS or PRF or by graftless sinus floor augmentation in partially dentate or edentulous patients in terms of implant survival, patient morbidity, sinusitis, graft loss, costs, and risk of disease transmission? A major concern with the use of AB is donor site morbidity (Nkenke et al. 2001, 2002, 2004).

It seems that donor site morbidity can be a major reason to question the use of AB. On the other hand, allografts and xenografts used as alternatives to autografts have a potential for disease transmission (Cordioli et al. 2001). Infectious particles (prions) cause Creutzfeldt–Jakob disease (CJD) in humans and bovine spongiform encephalopathy (BSE) in cattle. Therefore, the use of xenogenic material for medical products and devices poses the question: to what degree such material can be considered free of prions and what are the risks of transmission of the disease to humans. Cases have been reported of iatrogenic transmission of CJD from humans to humans through the use of human-derived medicinal products (Brown et al. 1992). While the appearance of the new variant CJD (vCJD) appears to be caused through consumption of infectious bovine food, none of the vCJD patients had a history of surgery and the use of xenografts (Will et al. 1996). Allografts also pose the risk of transmission of other infectious diseases, such as acquired immunodeficiency syndrome. However, it

has been stated that adequate material processing including freezing, demineralization, and lyophilization can decrease the risk of infection transmission to minimum (Gomes et al. 2008). It seems that the risk for transmission of these diseases by BS is minimal. Cases have been reported of iatrogenic transmission of CJD from humans to humans through the use of human-derived medicinal products (Brown et al. 1992). While the appearance of the new variant CJD (vCJD) appears to be caused through consumption of infectious bovine food, none of the vCJD patients had a history of surgery and the use of xenografts (Will et al. 1996). Allografts also pose the risk of transmission of other infectious diseases, such as acquired immunodeficiency syndrome. However, it has been stated that adequate material processing including freezing, demineralization, and lyophilization can decrease the risk of infection transmission to minimum (Gomes et al. 2008). It has been stated that perforation of the sinus membrane does not compromise the osseointegration process or the survival of dental implants placed in anaugmented maxillary sinus (Karabuda et al. 2006). A correlation between sinus membrane perforation and extended post-operative sinusitis or implant loss could not be found (Kaptein et al. 1998). The present review reveals that the advent of sinusitis, partial or total graft loss is independent of the graft material. Using AB will not protect patients from developing sinusitis or graft loss. Resorption of graft material and subsequent repneumatization have

been mentioned as reasons to choose non-resorbable or slowly resorbable BS in sinus floor augmentation. However, the data of the present review do not reveal that resorption of the graft material has an influence on implant survival (Hallman & Nordin 2004; Kim et al. 2009). The aspect of resorption does not seem to be of concern that should prompt the clinician to prefer or abandon AB. The height of the residual alveolar ridge was the basis for the decision of a staged approach or implant placement simultaneous with sinus floor augmentation in some studies. As the thresholds for one or the other procedure were chosen arbitrarily and had no scientific basis, the implant survival was comparable for the different graft materials used. The aspects of height of the residual alveolar crest and simultaneous or delayed implant placement did not seem to contribute to the decision of whether AB should be preferred in sinus floor augmentation or not. However, it has to be kept in mind that simultaneous implant placement is less invasive than a staged approach, more cost-effective, and more time efficient (Becktor et al. 2008). However, this is true for every graft material used. The healing periods elapsed after the different sinus floor augmentation procedures were also chosen arbitrarily in the different studies. Longer healing periods did not increase implant survival in a relevant way. Implant survival seemed not to be influenced by the healing periods of the different graft materials. The length of the healing period of the

graft material could not be identified as a reason to prefer AB over BS or PRF or graftles technique. The aspect of costs cannot be ignored in sinus floor augmentation procedures. Harvesting AB increases the operating time (Peleg et al. 2004). Especially, in case of extraoral donor sites, surgery is performed under general anesthesia (Ruiz 2004). In some studies the patients even had to be hospitalized (Marchetti et al. 2007). These different aspects lead to an increase in costs. It has to be assumed that the money spent on increased operating time, general anesthesia, and hospitalization will exceed the expenses for BS by far. Consequently, costs may not be a reason to prefer AB. However, detailed incremental cost-effectiveness analyses are needed to clarify this aspect. From the present review, it is impossible to decide whether general diseases, smoking, or other risk factors have an influence on the implant survival rate depending on the graft material used.

Presently, it is not possible to decide whether the use of cytokines, growth factors, and BMPs will change the characteristics of AB or BS in way that one or the other material should be preferred as far as implant survival is concerned. All in all, the current literature provides only a low level of evidence as far as the decision-making between the use of AB, BS, PRF or without graft is concerned. To date, studies are missing that are dedicated to the clarification of the influence of residual bone height, simultaneous or delayed implant placement, sinusitis, and graft resorption

on implant survival in dependence of the graft material used. The aspects of donor site morbidity, disease transmission, and costs have also not been treated adequately.

Meta analysis by Tong et al. 1998 showed that Implant survival was 90 % for autogenous bone (484 implants in 130 patients followed for 6–60 months), 94 % for the combination of hydroxyapatite (HA) and autogenous bone (363 implants in 104 patients followed for 18 months), 98 % for the combination of demineralized freeze-dried bone (DFDB) and HA (215 implants in 50 patients followed for 7–60 months), and 87 % for HA alone (30 implants in 11 patients followed for 18 months) (Tong et al. 1998). No difference in measure of success such as plaque index, gingival index, pocket depth and implant stability were noted in various studies using different augmentation procedures such as with bovine hydroxyl-apatite mixed with fibrin glue (Hallman M, Nordin T, 2004), anorganic bovine bone (Valentini P, Abensus DJ 2003) and autogenous bone graft (Stricker A, Voss PJ, Gutwald R, Schramm A, Schmelzeisen R., 2003).

The overall height of bone graft decreased during the first 2–3 years after augmentation. Thereafter, only minor changes occurred. However, graft height up to 96 months after augmentation was higher than that observed preoperatively. These findings suggest that implant loading promotes osteogenesis over the long term (Nystrom et al. 1993; Keller et al. 1994). Implant loading may exert a

stabilizing effect on the maintenance of bone graft height, consistent with the findings of Listrom & Symington (1988). The absence of implant loss after about 3 years may be associated with the stability of sinus-graft height.

Good long-term results can be achieved using a 2:1 autogenous bone/xenograft mixture for maxillary sinus floor augmentation with simultaneous placement of implants. Overall, graft height decreased during the first 2–3 years after augmentation, but subsequent changes were minimal. The results suggest that long-term stability of sinus-graft height represents an important factor for implant success. (Naoki et al., 2004)

A block of cancellous freeze-dried allograft may be used as a grafting material for sinus floor augmentations and for the initial stabilization of dental implants when placed during this procedure . Its main advantage is its ability to provide initial stability for the implant and the grafting material, without the need for autogenous bone harvesting, even in the presence of membrane perforation. (Gavriel, 2009) that autogenous bone mixed with platelet rich plasma (PRP) or venous bone (VB) produces similar long term clinical results with autologous bone mixed with VB having slight advantage. Even though there are studies which are providing evidence that the use of autologous PRP does accelerate soft and hard tissue healing in at least limited number of applications further controlled clinical studies with larger sample sizes are

needed to evaluate the influence of different parameters on treatment outcome. In addition, defined clinical protocols in combination with long term clinical documentation are needed to identify the clinical benefits for the use of VB in combination with autogenous bone grafts for maxillary sinus augmentation procedures. (Namineni Kiran , et al. 2015)

Simultaneous sinus membrane elevation and implant placement, with or without bone graft, reach a comparable bone gain and implant survival at 6-month follow-up. The sinuses, in a split-mouth design, were assigned to two groups: a control group consisting of 17 sinuses, which received simultaneous sinus membrane elevation, autogenous bone graft, and implant placement; and a test group consisting of 17 sinuses, which received simultaneous sinus membrane elevation and implant placement without graft material . The results demonstrates a high survival rate for simultaneous implant placement in both groups. The success rate ranged between 96.4% and 100%, similar to previous reports (Borges et al., 2011)

The bone resorption rate after single autogenous bone graft was significantly higher compared to the autogenous bone combined with Bio-Oss. The resorption rate of maxillary sinus bone graft in the one-stage surgery group was significant higher than that in the two-stage surgery group. The resorption rate of maxillary sinus bone graft in the higher residual bone height group (>4 mm) was significant higher than that in the residual bone

height group (<4 mm). There was no significant correlation with the resorption rate of maxillary sinus bone graft among patients' age, implant size, implant placement region, local infection, and surgical complication. During an average monitoring period of 2.7 years, the success rate and survival rate of the implant were 92.2% and 100%, respectively. The results suggest that maxillary sinus floor elevation with autogenous bone graft through the lateral window approach technique is feasible and safe, and that the elevation of maxillary sinus floor is predictable in implant rehabilitation for patients with reduced vertical bone height in the posterior maxillary region. (Wang Peng, et al. 2013)

Bone materials were mixed and used, and they were divided into two groups, containing autogenous bones and without autogenous bones. In the group containing autogenous bones (46 implants), the bone harvested from the maxillary tuberosity or the mandible symphysis was mixed with allogeneic bones such as Regenaform (Exactech, Gainesville, FL, USA) or xenogeneic bones such as Bio-Oss (Geistlich Pharma AG, Wolhusen, Switzerland) and grafted. In the group without autogenous bones (30 implants), allogeneic bones such as Regenaform were mixed with xenogeneic bones such as Bio-Oss and grafted. An evaluation of cases at an average of 47.6 months after maxillary sinus bone graft and implant placement showed that the average resorption volume of maxillary

bone graft materials was 3.15 ± 2.95 mm. Significant differences according to the bone graft procedure or materials were not observed. Complications that occurred during maxillary sinus bone graft such as perforation did not mediate the decisive effects on the resorption of grafted bones or the prognosis. (Young – Kyum kim et al. 2014)

Platelet-rich fibrin is an autologous and inexpensive material, which can be considered as an optimized blood clot. Sinus floor augmentation with simultaneous implant placement using platelet-rich fibrin as the sole filling material is a secure and reliable option that promotes natural bone regeneration. (Tajima 2013).

CONCLUSIONS:

-The available evidence neither supports nor refutes the superiority of AB over other graft materials for sinus augmentation with regard to implant survival but regarding the operative and post operative complications the AB was more than other grafts at the recipient site.

- Good long-term results can be achieved using a 2:1 autogenous bone/xenograft mixture for maxillary sinus floor augmentation with simultaneous placement of implants.

- A block of cancellous freeze-dried allograft may be used as a grafting material for sinus floor augmentations and for the initial stabilization of dental implants when placed during this

procedure. Its main advantage is its ability to provide initial stability for the implant and the grafting material, without the need for autogenous bone harvesting, even in the presence of membrane perforation.

- Sinus floor augmentation with simultaneous implant placement using platelet-rich fibrin as the sole filling material is a secure and reliable option that promotes natural bone regeneration .

- Maxillary sinus floor augmentation using xenografts is predictable technique with good results and minimal postoperative complications .

- Simultaneous sinus membrane elevation and implant placement, with or without bone graft, reach a comparable bone gain and high implant survival rate.

- Implant survival may be confounded by factors other than the graft material used for sinus floor augmentation.

Table 3: Exclusion characters

| The authors | Smokers | Systemic disease | Sinus pathology | Others |
|-------------------------------|---------|------------------|-----------------|-----------------|
| Kunal Jodia etal.2013 | Yes | Yes | Yes | Ns |
| Naoki Hatano etal.2003 | Ns | Yes | Ns | Ns |
| Gavriel Chaushu etal.2009 | Yes | Ns | Ns | No drug history |
| Maurizio silvestri etal. 2013 | Yes | Yes | Yes | Ns |
| Fabio L. Borges etal. 2011 | Yes | Yes | Yes | Ns |
| Tassos irinakis etal.2011 | Yes | Yes | Yes | Ns |
| Wang Peng etal.2013 | Ns | Yes | Yes | Ns |
| Young-Kyun Kim etal.,2014 | Ns | Yes | Ns | Ns |
| Nobutaka Tajima etal.,2013 | Ns | Yes | Yes | Ns |

Table 4: characters of surgical procedures:

| The authors | Simultaneous /Staged implant placement | Antibiotic use | Surgical approach (lateral approach) | Membrane use | Follow up (month) |
|------------------------|--|--|---|---------------------|-------------------|
| Kunal Jodia etal.2013 | Simultaneous | Pre &postoperative 625mg Augmentin (T.I.D) 0.2% Chlorhexidine gluconate mw | Round – elliptical shape using round burr | Resorbable collagen | 6-18-30 |
| Naoki Hatano etal.2003 | Simultaneous | Ns | Modified cauld well lauc | Ns | Ns |
| Gavriel | Simultaneous | Pre | Trapezoid – | Resorbabale | Ns |

| | | | | | |
|-------------------------------|---|---|---|--|-------------------|
| Chaushu etal.2009 | | &postoperative 500mg Amoxicillin (T.I.D) 0.2% Chlorhexidine gluconate mouthwash | oval Kent & block 9mm height ,15mm width by round burr | collagen (orapharma – bionet- biogide) | |
| Maurizio silvestri etal. 2013 | Simultaneous | Pre &postoperative 500mg Amoxicillin (T.I.D) | Boyne & James Round burr or piezo electric | Collagen (eulution Teenoss or biogide) | Ns |
| Fabio L. Borges etal. 2011 | Simultaneous | postoperative 875mg Amoxicillin (T.I.D) 125mg Sulbactam 0.2% Chlorhexidine gluconate mouthwash | Window 15mm *10mm , bone block used new floor of sinus by round burr | Polypropylene | 6 |
| Tassos irinakis etal.2011 | Simultaneous | postoperative 875mg Amoxicillin (T.I.D) 125mg clavulate 0.2% Chlorhexidine gluconate mouthwash | Window by piezo | Collagen 15 *20 mm Neomembrane (test) Newmed or biomend (contro) | 12-24 |
| Wang Peng etal.2013 | 17sinus simultaneous , 47 sinus staged | Yes | Trapdoor , new floor by round burr | Ns | 24-68 |
| Young-Kyun Kim etal.,2014 | Simultaneous | Ns | Window by round burr | collagen | 47.6 (+- 11.2) |
| Nobutaka Tajima etal.,2013 | Simultaneous | Postoperative 250 mg amoxicillin tid | Window by piezo | Ns | 6 |

Table 5 : Healing time

| The authors | Healing |
|---------------------------|---|
| Kunal Jodia etal.2013 | 6 months after extraction , 6 months after implants Follow up 6-18-30 months |
| Naoki Hatano etal.2003 | Ns |
| Gavriel Chaushu etal.2009 | Mean 27 months (11-46 months) |

| | |
|-------------------------------|--|
| Maurizio silvestri etal. 2013 | After 6 months of healing , loading 2 months after uncovering the implants |
| Fabio L. Borges etal. 2011 | 6 months |
| Tassos irinakis etal.2011 | 12 months after functional loading |
| Wang Peng etal.2013 | 2.7 years |
| Young-Kyun Kim etal.,2014 | 3 years |
| Nobutaka Tajima etal.,2013 | 6 months |

Table 6 : Grafting materials, implant type

| The authors | Grafting | Implants |
|-------------------------------|--|---|
| Kunal Jodia etal.2013 | Novabone (bioactive glass putty) | EZ double thread |
| Naoki Hatano etal.2003 | Autogenous + Biooss (2:1) | Nobelbiocare |
| Gavriel Chaushu etal.2009 | FDBA | MSI (35) Bioment(29) Zimmer (8) |
| Maurizio silvestri etal. 2013 | Bovine particulate (control) porcine particulate (test) | SPI Contact , thommen |
| Fabio L. Borges etal. 2011 | Autogenous bone (symphysis/ramus) milled | Conus ,INP, Brazil screw shape |
| Tassos irinakis etal.2011 | Allograft control : particulate (mineross , biohorizon) Test : injectable (Dynablast) | Nobel biocare |
| Wang Peng etal.2013 | Autogenous (ramus – iliac crest) Vrs Composite (autogenous + xenograft Biooss) | Biohorizons external implant RBT |
| Young-Kyun Kim etal.,2014 | Autogenous mixed with allogenic (Regenaform)or xenograft (Biooss) Vrs allogenic or xenograft | 3-i (15) , Biohorizons (5) , Implantium (19) , US2 (7) , SS2 (4) , GS2 (6) ,XIVE (10) , AVANA (6) |
| Nobutaka Tajima etal.,2013 | PRF | Noble biocare |

Table 7 : Complications

| The authors | Sinus perforation | Postoperative sinusitis | Graft loss | Other |
|-------------------------------|--------------------------------------|-------------------------|--|---|
| Kunal Jodia etal.2013 | One patient | Ns | Ns | Ns |
| Naoki Hatano etal.2003 | Ns | Ns | Ns | Ns |
| Gavriel Chaushu etal.2009 | 6 cases (21.4%) | Ns | Ns | Ns |
| Maurizio silvestri etal. 2013 | Ns | Ns | Residual bovine =16, residual porcine =13.5 | Ns |
| Fabio L. Borges etal. 2011 | 1 more than 5mm , 2 more than 2mm | Ns | Ns | 2 fistulas ,suppuration in both groups |
| Tassos irinakis etal.2011 | 2 small (control) | Ns | Ns | Ns |
| Wang Peng etal.2013 | 10 | 5 | Ns | Ns |
| Young-Kyun Kim etal.,2014 | 12 | Ns | Ns | Infection =2 Fail = 4 |
| Nobutaka Tajima etal.,2013 | No | Ns | Ns | Ns |

Table 8 : Results

| The authors | Implant survival rate | Graft height reduction | Bone height |
|-------------------------------|--|---|---|
| Kunal Jodia etal.2013 | 100 % | 0.3mm -0.7mm (18 months) 0.2-0.3mm (30 months) | 0-6 months 4.8 6-18 months -0.5 18-30 months -0.5 0-30 months -3.8 |
| Naoki Hatano etal.2003 | 94.2 % 21 of 216 | Grafted sinus height / original sinus height mean = 2.3+1.5 | |
| Gavriel Chaushu etal.2009 | 94.4 % | Ns | 12.3mm |
| Maurizio silvestri etal. 2013 | 96.3% (3 implants) | Ns | Ns |
| Fabio L. Borges etal. 2011 | 96.4% graftless group 100% autogenous group | Ns | 8.3 +- 2.6 autogenous 7.9 +- 3.6 graftless |
| Tassos irinakis etal.2011 | 100% | Ns | Ns |
| Wang Peng etal.2013 | 100% | 23.1 % autogenous after 6m 18.9% both after 6m | Ns |
| Young-Kyun Kim etal.,2014 | 94.7% | 3.4mm+-2.9 autogenous 2.7mm+-2.8 without | Ns |
| Nobutaka Tajima etal.,2013 | 100% | Ns | Gain 7.5mm |

REFERENCES:

1. Carlo Maria Soardi , Sergio Spinato , Davide Zaffe & Hom-Lay Wang (2010) : Atrophic maxillary floor augmentation by mineralized human bone allograft in sinuses of different size: an histologic and histomorphometric analysis : Clin. Oral Impl. Res. 22, 2011; 560–566
2. Carolina Sbordone & Paolo Toti (2012) :Volume changes of autogenous bone after sinus lifting and grafting procedures: A 6-year computerized tomographic follow-up ; JCMS. 09.007
3. Cordioli, G., Mazzocco, C., Schepers, E., Brugnolo, E. & Majzoub, Z. (2001): Maxillary sinus floor augmentation using bioactive glass granules and autogenous bone with simultaneous implant placement. Clinical and histological findings. Clinical Oral Implants Research 12: 270–278.
4. Fabio L. Borges, Rafael O. Dias, Adriano Piattelli, Tatiana Onuma, Luciana Ap. Gouveia Cardoso, Munir Salomão, Antonio Scarano, Eduardo & Jamil Awad Shibli (2011): Simultaneous Sinus Membrane Elevation and Dental Implant Placement Without Bone Graft: A 6-Month Follow-Up Study ; J Periodontol 2011;82:403-412.

5. Galindo-Moreno, P., Avila, G., Fernandez-Barbero, J.E., Aguilar, M., Sanchez-Fernandez, E., Cuntando, A. & Wang, H.L. (2007) : Evaluation of sinus floor elevation using a composite bone graft mixture. *Clinical Oral Implants Research* 18: 376–382.
6. Galindo-Moreno, P., Avila, G., Fernandez-Barbero, J.E., Mesa, F., O'Valle-Ravassa, F. & Wang, H.L. (2008) Clinical and histologic comparison of two different composite grafts for sinus augmentation: a pilot clinical trial. *Clinical Oral Implants Research* 19: 755–759.
7. Gavriel Chaushu, Ofer Mardinger, Shlomo Calderon, Ofer Moses & Joseph Nissan (2009) : The Use of Cancellous Block Allograft for Sinus Floor Augmentation With Simultaneous Implant Placement in the Posterior Atrophic Maxilla , *J Periodontol* 2009;80:422-428.
8. Gomes, K.U., Carlini, J.L., Biron, C., Rapoport, A. & Dedivitis, R.A. (2008) : Use of allogeneic bone graft in maxillary reconstruction for installation of dental implants. *Journal of Oral and Maxillofacial Surgery* 66: 2335–2338.
9. Hallman, M. & Nordin, T. (2004) Sinus floor augmentation with bovine hydroxyapatite mixed with fibrin glue and later placement of nonsubmerged implants: a retrospective study in 50 patients. *The International Journal of Oral & Maxillofacial Implants* 19: 222–227.
10. Iturriaga, M.T. & Ruiz, C.C. (2004) : Maxillary sinus reconstruction with calvarium bone grafts and endosseous implants. *Journal of Oral and Maxillofacial Surgery* 62: 344–347.
11. Kalk, W.W., Raghoobar, G.M., Jansma, J. & Boering, G. (1996) : Morbidity from iliac crest bone harvesting. *Journal of Oral and Maxillofacial Surgery* 54: 1424–1429; discussion 1430.
12. Kaptein, M.L., de Putter, C., de Lange, G.L. & Blijdorp, P.A. (1998) : Survival of cylindrical implants in composite grafted maxillary sinuses. *Journal of Oral and Maxillofacial Surgery* 56: 1376–1380; discussion 1380–1381.
13. Karabuda, C., Arisan, V. & Hakan, O. (2006) : Effects of sinus membrane perforations on the success of dental implants placed in the augmented sinus. *Journal of Periodontology* 77: 1991–1997.
14. Kumbler, N.R., Will, C., Depprich, R., Betz, T., Reinhart, E., Bill, J.S. & Reuther, J.F. (1999): Comparative studies of sinus floor elevation with autologous or allogeneic bone tissue. *Mund-, Kiefer- und Gesichtschirurgie* 3 (Suppl. 1): S53–S60.
15. Kunal Jodia , Bipin S. Sadhwani , Babu S. Parmar , Sonal Anchlia & Shaili B. Sadhwani (2013): Sinus Elevation with an Alloplastic Material and Simultaneous Implant Placement: A 1-Stage Procedure in Severely Atrophic Maxillae , *J.*

- Maxillofac. Oral Surg. DOI
10.1007/s12663-013-0536-1
16. Listrom, R.D. & Symington, J.M. (1988): Osseointegrated dental implants in conjunction with bone grafts. *International Journal of Oral & Maxillofacial Surgery* 17: 116–118.
 17. Marchetti, C., Pieri, F., Trasarti, S., Corinaldesi, G. & Degidi, M. (2007): Impact of implant surface and grafting protocol on clinical outcomes of endosseous implants. *The International Journal of Oral & Maxillofacial Implants* 22: 399–407.
 18. Maurizio silvestri ,paolo martegna & Mauro teventi (2013): simultaneous sinus augmentation with implant placement : histomorphologic comparison of two different grafting materials . A multicenter double blind prospective randomized controlled clinical trial ; *Int J OralMaxillofac implants* ; 28:543-549
 19. Mauro Tosta , Arthur R. G. Cortes , Luciana Corre , Isabel Tumenas & Eduardo Katchburian(2011) : Histologic and histomorphometric evaluation of a synthetic bone substitute for maxillary sinus grafting in human ; *Clin. Oral Impl. Res.* 00, 2011, 1–5.
 20. Namineni Kiran Kumar , Mahaboob Shaik , Koteswara Rao Nadella & Balakrishna Manohar Chintapalli 2015 ; Comparative Study of Alveolar Bone Height and Implant Survival Rate Between Autogenous Bone Mixed with Platelet Rich Plasma Versus Venous Blood for Maxillary Sinus Lift Augmentation Procedure; *JMaxillofac. Oral Surg.* 14(2):417–422
 21. Naoki Hatano , Yoshinaka Shimizu , Kiyoshi Ooya (2004) : A clinical long-term radiographic evaluation of graft height changes after maxillary sinus floor augmentation with a 2:1 autogenous bone/xenograft mixture and simultaneous placement of dental implants *Clin. Oral Impl. Res.* 15; 339–345
 22. Nkenke, E., Weisbach, V., Winckler, E., Kessler, P., Schultze-Mosgau, S., Wiltfang, J. & Neukam, F.W. (2004) : Morbidity of harvesting of bone grafts from the iliac crest for preprosthetic augmentation procedures: a prospectivestudy. *The International Journal of Oral and Maxillofacial Surgery* 33: 157–163.
 23. Nobutaka Tajima, Seigo Ohba, Takashi Sawase & Izumi Asahina (2013): Evaluation of Sinus Floor Augmentation with Simultaneous Implant Placement Using Platelet-Rich Fibrin as Sole Grafting Material : *Int J Oral Maxillofac IMplants* 2013;28:77–83
 24. Nystrom, E., Kahnberg, K.-E. & Albrektsson, T. (1993) : Treatmentoftheseverely resorbedmaxillae with bone graft and titanium implants: histologic review of autopsy specimens. *International Journal of Oral & Maxillofacial Implants* 8: 167–172.
 25. Peleg, M., Garg, A.K., Misch, C.M. & Mazor, Z. (2004): Maxillary sinus and ridge augmentations using a

- surface-derived autogenous bone graft. *Journal of Oral and Maxillofacial Surgery* 62: 1535–1544.
26. Raghoobar, G.M., Batenburg, R.H., Timmenga, N.M., Vissink, A. & Reintsema, H. (1999): Morbidity and complications of bone grafting of the floor of the maxillary sinus for the placement of endosseous implants. *Mund-, Kiefer- und Gesichtschirurgie* 3 (Suppl. 1): S65–S69.
27. Rickert, Vissink & Meijer (2014) : Maxillary sinus floor elevation surgery with Biooss mixed with a bone marrow concentrate or autogenous bone : test of principle on implant survival & clinical performance ; *Int J Oral Maxillofac surg* :43:243-247.
28. Rita Oliveira Rita Oliveira, , Marc El Hage, Jean-Pierre Carrel, Tommaso Lombardi & Jean-Pierre Bernard, (2012) : Rehabilitation of the Edentulous Posterior Maxilla After Sinus Floor Elevation Using Deproteinized Bovine Bone: A 9-Year Clinical Study ; *Implant Dent* 2012;21:422–42.
29. Stricker A, Voss PJ, Gutwald R, Schramm A, Schmelzeisen R (2003) : Maxillary sinus floor augmentation with autologous bone graft to enable placement of SLA-surfaced implants—preliminary results after 15–40 months. *Clin Oral Implants Res* 14:207–212 .
30. Stuart J. Froum, sang –choon cho , Ismael khouly & Edwin Rosenberg (2014) : Radiographic comparison of different concentrations of recombinant human bone morphogenetic protein with allogenic bone compared with the use of 100% mineralized cancellous bone allograft in maxillary sinus grafting.; *Int J Periodontics Restorative Dent* : 34:611-620.
31. Tadjoeidin, E.S., de Lange, G.L., Lyaruu, D.M., Kuiper, L. & Burger, E.H. (2002) High concentrations of bioactive glass material (biogran) vs. autogenous bone for sinus floor elevation. *Clinical Oral Implants Research* 13: 428–436.
32. Tassos Irinakie (2011) : Efficacy of injectable demineralized bone matrix as graft material during sinus elevation surgery with simultaneous implant placement in the posterior maxilla : clinical evaluation of 49 sinuses
33. Tong DC, Rioux K, Drangsholt M, Beirne OR (1998) : A review of survival rates for implants placed in grafted maxillary sinuses using meta-analysis. *Int J Oral Maxillofac Implants* 13:175–182.
34. Uckan S, Deniz K, Dayangac E, Araz K, Özdemir BH (2010) : Early implant survival in posterior maxilla with or without tricalcium phosphate sinus floor graft. *J Oral Maxillofac Surg* 68:1642–1645.
35. Valentini P, Abensus DJ (2003) : Maxillary sinus grafting with anorganic bovine bone—a clinical report of long term results. *Int J Oral Maxillofac Implants* 18:556–560 .

36. Wang Peng, Il-Kyu Kim, Hyun-Young Cho, Sang-Pill Pae, Bum-Sang Jung, Hyun-Woo Cho & Ji-Hoon Seo 2013; Assessment of the autogenous bone graft for sinus elevation ;J Korean Assoc Oral Maxillofac Surg ;39:274-282
37. Will, R.G., Ironside, J.W., Zeidler, M., Cousens, S.N., Estibeiro, K., Alperovitch, A., Poser, S., Pocchiari, M., Hofman, A. & Smith, P.G. (1996): A new variant of Creutzfeldt–Jakob disease in the UK. Lancet 347: 921–925.
38. Young-Kyun Kim, Su-Gwan Kim, Bum-Su Kim & Kyung-In Jeong (2014) ; Resorption of bone graft after maxillary sinus grafting and simultaneous implant placement ; J Korean Assoc Oral Maxillofac Surg .40:117-122