

Management of Haemorrhagic Stroke with Hyperbaric Oxygen Therapy - A Case Report

I Lim, W K Lim, T T Yeo, Y Y Sitoh, E Low

ABSTRACT

Hyperbaric oxygen therapy (HBOT) has been used in the treatment of cerebral ischaemia with positive effects on tissue oxygenation. We present a case of haemorrhagic stroke treated successfully with HBOT and review the literature on its role in cerebrovascular disease.

Keywords: Hyperbaric oxygen, haemorrhagic stroke

Singapore Med J 2001 Vol 42(5):220.223

INTRODUCTION

Stroke, or "brain attack", is a leading cause of mortality and morbidity in developed populations. The treatment of thrombo-embolic ischaemic stroke has been revolutionised by the use of thrombolytics, but haemorrhagic stroke has no such equivalent and its past management was often gloomy and bereft of any "active" therapy. The primary pathology is that of lack of tissue oxygenation and Illingworth et al in 1961 suggested that HBOT could be beneficial in cerebrovascular disease(1). Its use in the treatment of cerebral ischaemia was first reported by Ingvar and Lassen four years later(2). Of their four patients, three improved and the fourth did show dramatic initial improvement before succumbing to thrombotic lesions in the brainstem.

Since then, more than 1,000 cases have been reported world-wide and since last year, the Naval Medicine and Hyperbaric Centre (NMHC) began treating selected intracerebral haemorrhages with HBOT. We wish to present here a typical case of a patient treated with HBOT.

CASE REPORT

SYL, a 48-year-old Chinese lady with a two year history of hypertension, presented to a local hospital with right-sided weakness associated with giddiness and slurred speech. Initial examination revealed a slight dulling of consciousness (GCS = 10/15: E4, M5, VI) and right-sided hemiparesis (MRC grade 2/5). Tone was increased on the right with upgoing plantar response and there was also an upper motor neuron VII nerve palsy and absent

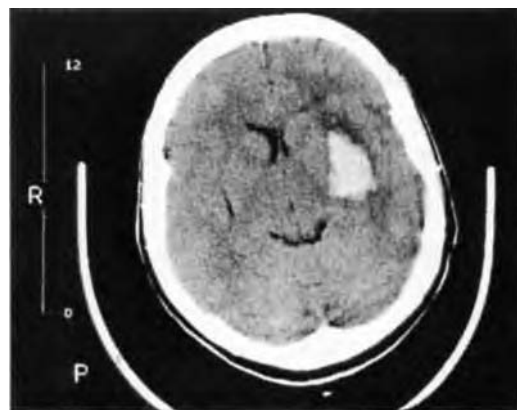


Fig. 1 CT scan on admission shows left putamen haemorrhage.

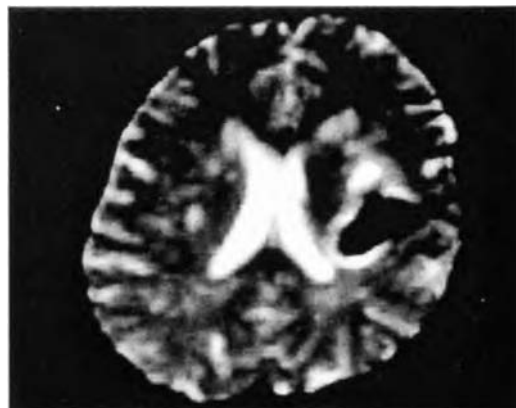


Fig. 2 T2 weighted MRI shows left putamen with mild adjacent oedema and mass effect.

gag reflex. Blood pressure on admission was 196/98 and was stabilised with nifedipine. Emergency CT scan showed a left putaminal haemorrhage (approx. 2 x 3 cm) Fig 1.

As she was haemodynamically stable and the size of the haemorrhage was less than 40 ml, she was selected for non-surgical intervention and referred to NMHC for a trial of HBOT. After assessment to determine her fitness for HBOT, treatment based on the Long Beach table (100% O₂ at a depth of 8 metres for 1 hour and 30 minutes; this table originated from work done at the Long Beach Memorial Medical Centre) was initiated

Nasal Hyperbaric
Centre
Republic of
Singapore Navy
Medical Service
AFPN 6060
Sembawang Camp
36 Admiralty
Road West
Singapore 759960

I Lim,
MBBS (Singapore),
Medical Officer

W K Lim,
MOBS (Singapore),
FRCOphth (UK),
FRCS Ed (00111),
MMcd (Ophth)
(Singapore)
Registrar

E Low, MOBS
(Singapore),
FRCA (UK),
MPH (Harvard)
Consultant

Department of
Neurosurgery
National Neuroscien
Institute

T T Yeo, MBBS,
FRACS
(Neurosurgery)
Consultant

Department of
Neuroradiology

Y V Snob,
MOBS (Singapore),
FRCR (UK), FAMS
Consultant

Correspondence to:
Dr Lim Wee Kiaik
Tel: (65) 750 5678
Fax: (65) 750 5610

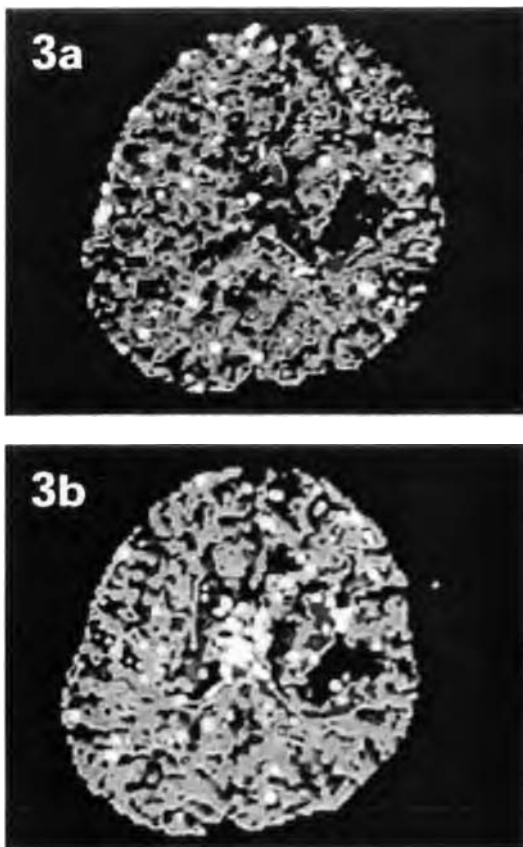


Fig. 3 Perfusion maps of relative regional cerebral blood volume pre (Fig. 3a) and post (Fig. 3b) HBOT shows an increase in rCBV immediately around the hematoma after HBOT. These are the areas colour coded red and white around the hematoma.

intervention has become more acceptable". This is largely due to the generally poor long-term functional outcome regardless of the modality of treatment. Oxygenation is the most critical function of blood flow and in this respect. HBOT has many attractive theoretical benefits. Experimental and clinical data have been encouraging . and with the increasing sophistication of positron emission tomography (PET), single photon emission computed tomography (SPECT) and functional MRI studies including diffusion and perfusion weighted scans, it is probable that the effects of HBOT on cerebral blood flow and metabolism will become better appreciated.

The fMRI techniques have superior spatial and temporal resolution over PET and SPECT: neither do they involve the use of ionising radiation. In perfusion weighted fMRI, dynamic images are obtained during the first-pass effect of an MRI contrast agent through the brain. Brain perfusion maps of relative regional cerebral blood volume (rCBV) and mean transit time (MTT) of contrast are generated. This semi-quantitative technique can potentially document the changes in perfusion with HBOT treatment.

PROPOSED MECHANISMS OF ACTION

HBOT is essentially the supply of oxygen under pressure to ischaemic areas. The hyperoxic state not only improves oxygenation of ischaemic tissues, but also has beneficial effects of cellular metabolism and intra-cranial pressure.

1. Improvement of oxygenation

HBOT increases the amount of oxygen dissolved in plasma and can nourish tissues even in the absence of red blood cells. Even in total vascular obstruction, plasma has been shown to seep through and deliver oxygen". There is also increased extravascular diffusion because of the greater diffusion gradient and the abundance of capillaries in brain tissue. The supply of oxygen is further facilitated by the induced hyperoxic state decreasing blood viscosity and increasing red cell deformability". Though there is vasoconstriction with reduction in blood flow, this is ameliorated by the alignment of red cells in a column instead of moving randomly (Fahraeus Liindqvist effect). Hence the improved rheology tends to counter the effects of vasoconstriction.

2. Reduction of Intra-cranial Pressure

Intracranial pressure (ICP) is a function of blood flow, amount of brain tissue and oedema, and the volume of cerebrospinal fluid (Kelly-Munroe doctrine). HBOT, by inducing vasoconstriction, counters the vasodilatation of capillaries in hypoxic tissue and reduces the

within 24 hours of onset of symptoms. Dynamic contrast enhanced perfusion weighted functional magnetic resonance imaging (fMRI) was obtained immediately before and after the first session of HBOT treatment. Fig. 2 and 3. She underwent a total of nine treatments over eight days with no complications of therapy. By the third treatment, her GCS had improved to 15/15. Motor power improved to 4/5 after the fourth treatment but deteriorated to 3+/5 after the fifth treatment. Treatment continued until power improved to 4/5 and we decided to terminate treatment after nine sessions because of a plateau of improvement. There was marked improvement of the facial nerve palsy and the gag reflex had returned.

Her improvement was sustained at 3- and at 6-months follow-up.

DISCUSSION

Despite decades of intense debate and research, the optimal management of spontaneous intracerebral haemorrhage is still unresolved. The role of surgery is still controversial for supratentorial haematoma, but a more conservative attitude towards operative

extravasation of fluid. Blood flow is reduced but tissue oxygenation is not compromised because of the improved delivery of oxygen. However, this effect is short-lived and Kohshi suggests that reduced ICP is maintained during HBO inhalation by induced hypocapnia(6). With the cessation of a treatment period, normal breathing is resumed and this could account for the initial fluctuation in improvement seen in our patient.

3. Improved metabolic function of cerebral tissue

HBOT has been shown to improve glucose metabolism(7), and hence prevents glycolysis and intracellular lactic acidosis build-up. Mink and Dutka, working on rabbit models, found that HBOT promoted blood-brain barrier integrity after global cerebral ischaemia(8), and Japanese studies have demonstrated the HBOT reduces intracellular potassium ion concentration in red cells(9). The underlying mechanism may relate to restoration of ion pump function in ischaemic cell membranes, and this may prevent the production of potentially damaging vasoactive mediators and facilitate recovery (10).

THEORETICAL NEGATIVE EFFECTS OF HBOT

There is concern that HBOT may worsen re-oxygenation injury by promoting oxygen free radicals and lipid peroxidation. However, Yasu was only able to demonstrate this in normal rat brains, but not in ischaemic rat brains". Furthermore, rabbit studies from Bethesda, USA, showed that while HBOT increased the amount of free radicals, this was not associated with an increase in lipid peroxidation or a reduction in neurophysiologic recovery!

Another criticism of HBOT is that induced vasoconstriction will compromise cerebral blood flow. While HBOT does reduce blood flow, this has not resulted in clinical detriment. It was also not associated with a reduction in evoked potential recovery or cerebral metabolism" on SPECT imaging. Hence, we can postulate that cerebral oxygenation is improved with HBOT despite the reduction in blood flow. Another possibility is the inverse steal phenomenon described by Lassen and Palvogyi(14), in which constriction of vessels in normal brain may increase blood flow in unresponsive areas.

FUTURE DIRECTIONS

HBOT has been described as "a therapy in search of diseases". Though ischaemic cerebral injury is a theoretically attractive disease to treat with HBOT, it is not one of the indications under the Undersea and Hyperbaric Society guidelines (1992) (10). Nonetheless, the growing body of experimental and clinical experience appears to be favourable.

Improvements in functional MRI techniques may obviate the need for large-scale randomised trials (difficult presently because of limited hyperbaric facilities) to demonstrate clinical efficacy as improvement can be documented radiologically and correlated with clinical symptomatology.

More work needs to be done on determining the optimum time of administering treatment though, regarding stroke as a "brain attack" will intuitively suggest that the earlier the treatment, the better the outcome. Animal studies combining HBOT with nicardipine administration showed acceleration of neurologic recovery(17), and combination of HBOT with neuro-protective pharmacological agents and antioxidants is likely to further benefit derived.

CONCLUSION

HBOT may be a useful modality in the treatment of spontaneous intracerebral haemorrhage. Evidence thus far has been encouraging, but this has largely been in the form of limited series and case reports and a randomised controlled trial is required to clarify the issue. More work also needs to be done to determine the optimum timing of treatment and to identify patients who would benefit most from HBOT. The role of combining HBOT with pharmacotherapy e.g. antioxidants, needs to be explored further. It is envisioned that diffusion and perfusion functional MRI may play a pivotal role in both defining the role of HBOT and elucidating its mechanisms of action.

REFERENCES

1. Illingworth CFW, Smith G, Lawson DD, Ledingham I MCA, Sharp GR, Griffith JC. Surgical and physiological observations in an experimental pressure chamber. *Br J Surg* 1961; 49:222-7.
2. Ingvar HD, Lassen NA. Treatment of focal cerebral ischaemia with hyperbaric oxygen. *Acta Neurol Scand* 1965; 41:92-5.
3. Jain KK. Role of Hyperbaric Oxygenation in the Management of Stroke. In: *Textbook of Hyperbaric Medicine* (2nd ed). Jain KK (ed) Hogrefe and Huber Publishers Inc 1996; pp:253-72.
4. Kanno T, Nagata I, Nonomura K, Asai T, Inoue T, Nakagawa T, Mitsuyama F. New approaches in the treatment of hypertensive intracerebral haemorrhage. *Stroke* 1993; 24(12 Suppl):196-100, discussion 1107-8.
5. Mathieu D, Coget J, Vinakeir L, et al. Filtrabilite erythrocytaire et oxygenotherapie hyperbare. *Circulation et metabolisms du Verveau* 1985; 2:27-31.
6. Kohshi K, Yokota A, Konda N, Kinoshita Y, Kajiwara H. Intracranial pressure responses during hyperbaric oxygen therapy. *Neurol Med Chir (Tokyo)* 1991; 31(9):575-81.
7. Contreras FL, Kadckaro M, Eisenberg HM. The effect of hyperbaric oxygen on glucose utilization in a freeze-traumatized rat brain. *J Neurosurg* 1988; 68:137-41.
8. Mink RB, Dutka AI. Hyperbaric oxygen after global cerebral ischaemia in rabbits reduces brain vascular permeability and blood flow. *Stroke* 1995; 26(12):2307-12.
9. Fujita T, Kitani Y. Intracellular electrolytes in erythrocytes during and after shock: relation to impaired consciousness. *J Trauma* 1978; 18:345-54.
10. Ducasse JL, Cathala B. Brain Injuries and HBO. In: *Handbook on Hyperbaric Medicine*. Oriani G, Marroni A, Wattel F (eds). Springer-Verlag Italia Milano 1996; pp:403-8.
11. Yasu T. H202 generation in rat brain in vivo correlates with oxygen pressure. *Masui (english abstract)* 1986; 35:1077-82.

12. Mink RB, Dutka AJ. Hyperbaric oxygen after global cerebral ischaemia in rabbits does not promote lipid peroxidation. *Crit Care Med* 1995; 23(8):1398-404.
13. Neubauer RA, James P. Cerebral oxygenation and the recoverable brain. *Neurol Res* 1998; 20 Suppl 1:S33-6.
14. Lassen NA, Palvogyi R. Cerebral steal during hypercapnia observed by the 133-Xenon technique in man. *Scan J Clin Lab Inves* 1968; Suppl 1:02-1014-3.
15. Gabb G, Robin ED. Hyperbaric oxygen: a therapy in search of diseases. *Chest* 1987; 92:1074-82.
16. *Hyperbaric Oxygen Therapy: a committee report*: Rev ed. Bethesda, Md: Undersea and Hyperbaric Medicine Society 1992.
17. Iwatsuki N, Takahashi M, Ono K, Tajima T. Hyperbaric oxygen combined with nicardipine administration accelerates neurologic recovery after cerebral ischaemia in a canine model. *Crit Care Med* 1994; 22(5):858-63.

19th Malaysia-Singapore Ophthalmic Congress

Organised by: Ophthalmological Society (2000/2001)
Malaysian Medical Association

Date: 15th - 17th June 2001

Venue: Eastern & Oriental Hotel
Penang, Malaysia

Scientific Program:

1. Key note lecture Dr Ang Chong Lye
2. Plenary lectures by invited speakers (Dr Frank Martin, Australia and others)
3. 5^h Keshmahinder Singh Oration (Dr Ronald Yeoh, Singapore)
4. Ocular Surgery News Symposium
5. Paramedic Course
6. Free papers & poster presentations (awards given for the best presentations)
7. Breakfast and 'meet the expert' Symposiums
8. Trade Exhibition
9. Social/ Sport Programs: - Welcome Reception
 - Congress Banquet
 - Tennis Tournament
 - Golf Tournament
 - Telematch

For more information, please contact

Ms S. Muthulechumi
Ophthalmological Society, MMA
4th Floor, MMA House,
124, Jalan Pahang, 53000 Kuala Lumpur
Fax: +603-40418187
Tel: +603-40418972

Email: skonsv@pa.jaring.my