

## 6 Role of Platelet-Rich Plasma in Articular Cartilage Injury and Disease

*Randy Mascarenhas, Bryan M. Saltzman, Lisa A. Fortier, and Brian J. Cole*

### 6.1 Introduction

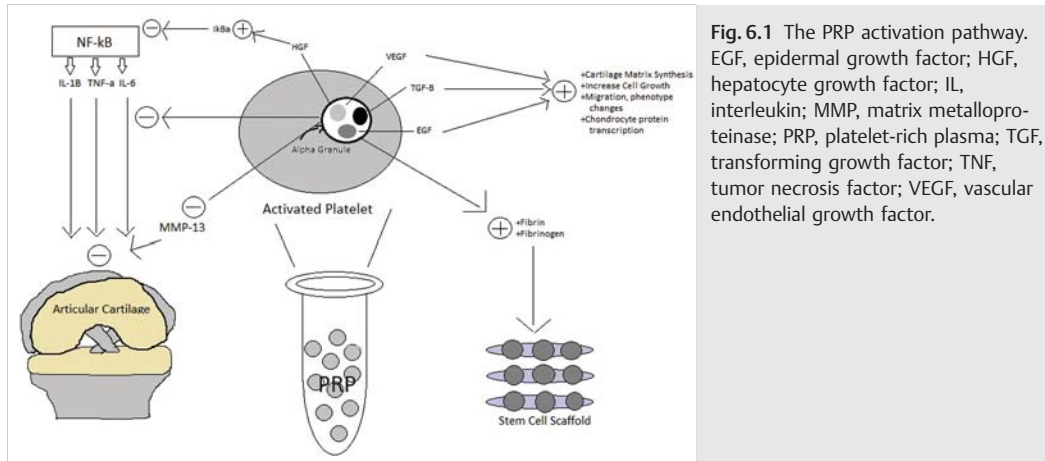
The articular cartilage in the setting of a diseased articular environment has very poor regenerative capacity. Thus, clinical and laboratory research aimed at biological approaches to repair cartilage injury using growth factors provides promise for the treatment of disabling articular cartilage disease. Growth factors are naturally occurring substances—often proteins or steroid hormones—that are capable of stimulating cellular differentiation, growth or proliferation while serving an important role in regulating various cellular processes. Numerous growth factors have quantitative and temporal effects on articular cartilage growth including transforming growth factor- $\beta$ 1 (TGF- $\beta$  1), bone morphogenetic protein-2 and -7, insulin growth factor-1, fibroblast growth factor-2 and -18 (FGF-2, FGF-18), vascular endothelial growth factor (VEGF), epidermal growth factor (EGF), and platelet-derived growth factor (PDGF). Many of these factors are found stored in the  $\alpha$ -granules of platelets, including VEGF, TGF- $\beta$ , EGF, FGF, and PDGF. Independently, these factors serve to promote local angiogenesis, modulate inflammation, inhibit catabolic enzymes and cytokines, recruit local stem cells and fibroblasts to sites of damage or injury, and induce healthy nearby cells to manufacture greater numbers of growth factors.<sup>1</sup> In combination, these proanabolic and anticatabolic effects attempt to return injured or diseased articular cartilage to its preinjury state. Platelet-rich plasma (PRP) is a sample of plasma with a supra-physiological concentration of platelets manufactured to harness and unleash these anabolic effects on injured or diseased cartilage in an effort to augment cartilage regeneration. Platelets and their associated cytokines and growth factors comprise the workhorse of the biological mixture, although the plasma contains valuable biological molecules also involved in injury repair.<sup>2</sup>

### 6.2 Basic Science behind Platelet-Rich Plasma

Osteoarthritis is a chronic degenerative joint disease in which the catabolic activity that becomes favored within chondrocytes leads to eventual

articular cartilage wear.<sup>2</sup> Cartilage has an extremely limited ability for self-repair given its avascularity<sup>3</sup>; thus, the traditional inflammatory repair process does not contribute to the healing response in the setting of cartilage injury as it has no means to travel to the locally affected tissue. The rationale for the use of PRP is that the supraphysiological release of platelet-derived factors at the direct site of cartilage injury or disease can stimulate the natural healing cascade and tissue regeneration.<sup>4</sup> Platelet activation leads to a release of the aforementioned growth factors and hundreds of others from its  $\alpha$ -granules to promote cartilage matrix synthesis, increase cell growth, migration, and phenotype changes, and facilitate protein transcription within chondrocytes.<sup>5,6</sup> The chemoattractants stored in platelets draw proteins, such as fibrinogen and fibrin, the latter of which acts as an initial scaffold for stem cells to migrate and differentiate. Generally, basic science evidence has demonstrated the ability of PRP to increase mesenchymal stem cell and chondrocyte proliferation, deposit type II collagen and proteoglycan.<sup>7,8</sup> This in theory may accelerate the formation of cartilage repair tissue.

The abundance of platelets in PRP increases the concentrations of relevant substances locally leading to a sustained effect on articular cartilage. The transcription of many degradative cytokines including interleukin-1 $\beta$ , tumor necrosis factor- $\alpha$ , and interleukin-6 are under the upstream control of nuclear factor KB (NF-KB), and the  $\alpha$ -granule contents in platelets inhibit this catabolic pathway on the downstream end and prevent the otherwise detrimental effects on articular cartilage changes in the process of osteoarthritis.<sup>9,10,11</sup> Activated PRP increases *in vitro* levels of hepatocyte growth factor, which enhances cellular I $\kappa$ B $\alpha$  expression and subsequently disrupts the NF-KB transactivating activity. It does so via NF-KB-p65 subunit cytosolic retention and nucleocytoplasmic shunting, thus decreasing its downstream proinflammatory effects.<sup>12</sup> PRP additionally has antinociceptive and anti-inflammatory properties, which result from the ability of PRP to decrease synovio-cyte matrix metalloproteinase-13 expression as shown in cartilage explant studies, which would otherwise have a primary role in cartilage matrix degradation while undergoing osteoarthritic



**Fig. 6.1** The PRP activation pathway. EGF, epidermal growth factor; HGF, hepatocyte growth factor; IL, interleukin; MMP, matrix metalloproteinase; PRP, platelet-rich plasma; TGF, transforming growth factor; TNF, tumor necrosis factor; VEGF, vascular endothelial growth factor.

changes. The same research demonstrated significantly increased hyaluronan synthase-2 expression in PRP-treated samples, which is an enzyme known to produce large hyaluronic acid (HA) isoforms and thus contribute to the cartilage construct (► Fig. 6.1).<sup>11</sup> Of final note, PRP decreases the expression of cyclooxygenase-2 and chemokine-receptor CXCR4 target genes which may regulate local inflammation when used in the setting of articular cartilage injury.<sup>12</sup>

### 6.3 Platelet-Rich Plasma in the Treatment of Articular Cartilage Injury

Preclinical animal studies on PRP have appraised its utility in both in vivo and in vitro repair of focal cartilage lesions and osteoarthritis therapy.<sup>5</sup> Many of the early clinical human studies have reported on PRP use in the treatment of osteoarthritis, with specific focus on the ability of PRP to achieve patient-reported improvements in pain and symptoms during the treatment of such articular cartilage pathology (► Table 6.1).

A randomized double-blinded study of 78 total patients by Patel et al<sup>13</sup> demonstrated that PRP injections into the knee of patients with mild or moderate osteoarthritis produced higher Western Ontario and McMaster Universities Arthritis (WOMAC) subjective knee symptom scores when compared with a saline injection control cohort. Filardo et al<sup>14</sup> prospectively evaluated 91 patients who received three PRP injections every 3 weeks for degenerative osteoarthritic knee chondral lesions and reported a median duration of improvement of 9 months. Outcome measures

were still improved from baseline at 2 years but were not maintained at the same level as the 1-year level of improvement, thus leading the authors to question the long-term efficacy of PRP. The research team also determined that superior results were gathered from younger patients and those with less cartilage degradation. Kon et al<sup>15</sup> prospectively followed 100 patients with degenerative chondral lesions and osteoarthritis who received three PRP injections every 3 weeks, and similarly reported superior responses to treatment in younger patients and a decrease in the improvement of outcomes at 1 year following injections when compared with the results at 6 months. Sampson et al<sup>16</sup> prospectively followed 14 patients with knee osteoarthritis treated with three PRP injections at 4-week intervals and reported significant improvements in pain and symptom relief in the majority of patients at 12 months postinjection as per Knee Injury and Osteoarthritis Outcome Score (KOOS) and Brittberg–Peterson visual analog scale (VAS) scores.

Filardo et al<sup>17</sup> compared PRP to HA injections in the treatment of knee chondropathy or osteoarthritis and reported a trend toward favorable outcomes in the PRP group at 1-year follow-up for patients with low-grade articular degeneration, but no superiority to HA injections in middle-aged patients with moderate signs of arthritis. By contrast, significantly better results in WOMAC index and Numeric Rating Scale scores were recorded in patients receiving three PRP injections as compared with HA injections for knee osteoarthritis at 3- and 6-month follow-up, as per the findings of Spaková et al.<sup>18</sup>

Gobbi et al<sup>4</sup> treated 50 patients with knee osteoarthritis using two intra-articular injections of

Table 6.1 Clinical outcome studies of isolated platelet-rich plasma use in cartilage disease

References	Study design	Methods	PRP platelet count	Results	Conclusions
Patel et al <sup>13</sup>	Randomized controlled trial Level of evidence: 1	Group A: 52 OA knees, single PRP injection Group B: 50 OA knees, two PRP injections at 3 wks apart Group C: 46 OA knees, single saline injection (control)	WBC-filtered Leukocyte quality: poor PLT count: 300% of whole blood values	All WOMAC parameters improved significantly in Group A, B within 2-3 wks lasting to 6 mo follow-up but slight worsening at the final week Ahlbäck grade 1 knees better than grade 2 22.2% of Group A with mild complications (nausea, dizziness); 44% of Group B with mild complications	Both groups treated with PRP had significantly superior results compared to control Results declined after 6 mo Single dose as effective as two injections
Filardo et al <sup>14</sup>	Prospective cohort study Level of evidence: 4	90 patients (114 OA knees) All treated with three total intra-articular PRP injections (q3 wks)	PLT count 600% of whole blood values Leukocyte quality: N/S	Outcomes all improved at 24-mo follow-up compared with baseline Outcomes all worsened with respect to 12-mo follow-up Better results for younger patients, lower degrees of cartilage degeneration Median duration clinical improvement: 9 mo	Treatment with PRP injections reduces pain, improves knee function, improves quality of life in short-term Less durable results in the long-term
Kon et al <sup>15</sup>	Prospective cohort study Level of evidence: 4	100 patients (115 OA knees) All treated with three total intra-articular PRP injections (q3 wks)	PLT count 600% of whole blood values Leukocyte quality: N/S	All clinical scores significantly improved from baseline to 6-12 mo follow-up (IKDC, EQVAS) Results declined from 6-to 12-mo follow-up	PRP is safe, reduces pain, and improves knee function and quality of life Superior results in younger patients, lower articular degeneration
Sampson et al <sup>16</sup>	Prospective cohort study Level of evidence: 4	14 patients with knee OA All treated with three total intra-articular PRP injections (~q4 wks)	PLT count not reported Leukocyte quality: rich	No adverse events Significant improvements in outcomes at 1-y follow-up (KOOS, VAS) 62% with favorable outcome at 1-y follow-up	Positive trends for PRP use Good safety profile for PRP use

Table 6.1 continued

References	Study design	Methods	PRP platelet count	Results	Conclusions
Filardoeta <sup>17</sup>	Prospective cohort study, with control group Level of evidence: 2	109 total patients with knee OA 55 treated with HA 54 treated with PRP Treated with a cycle of 3 weekly injections	WBC present Leukocyte quality: rich PLT count 500% of whole blood value	No major complications Higher postinjection pain reaction in PRP > HA Significant improvement in outcomes at 2-, 6-, and 12-mo follow-up No significant difference in scores between HA and PRP groups	PRP injections offer significant clinical improvement up to 1-y follow-up PRP is not better than HA for middle-aged patients with moderate OA More promising results in low-grade degenerative OA
Spakova et al <sup>18</sup>	Prospective cohort study, with control group Level of evidence: 2	120 patients with knee OA (grades 1–3) 60 treated with HA 60 treated with PRP Treated with a cycle of 3 weekly injections	PLT count 450% of whole blood value Leukocyte quality: rich	No severe adverse events Significantly higher WOMAC index and NRS scores in PRP group at 3- and 6-mo follow-up	PRP is safe, effective in the initial stages of knee OA
Gobbi et al <sup>4</sup>	Prospective cohort study Level of evidence: 4	50 patients with knee OA Treated with two injections, 1 mo apart	PLT count 200% of whole blood Leukocyte quality: rich	All patients with significant outcome score (IKDC) at 6- and 12-mo follow-up All patients returned to previous activities No differences in improvements in patients with or without previous cartilage operation	PRP is well-tolerated with encouraging clinical results PRP had efficacy in patients with previous microfracture or cartilage shaving procedures
Hart et al <sup>19</sup>	Randomized, controlled trial Level of evidence: 1	100 patients with knee OA (grade II/III chondromalacia) 50 treated with PRP 50 treated with mesocaine (control) Treated with six injections weekly, then 3 mo break, followed by three injections every 3 mo for maintenance	PLT count 200–250% of whole blood Leukocyte quality: poor	No adverse events Significant improvement in all clinical outcome scores (Lysholm, Tegner, IKDC, Cincinnati) Results improved at 12-mo follow-up MRI evaluation of cartilage showed no significant regeneration	PRP reduced pain significantly, improved quality of life for patients with low amounts of cartilage degeneration

Table 6.1 continued

References	Study design	Methods	PRP platelet count	Results	Conclusions
Jang et al <sup>20</sup>	Prospective cohort study Level of evidence: 4	65 patients with knee OA Treated with a single injection	PLT count not reported Leukocyte quality: N/S	Clinical improvement in mean VAS score at 6-mo follow-up, declined some at 1-y follow-up Significant IKDC outcome score improvement Relapsed pain at mean 8.8 mo follow-up Significant negative correlation between patient age and VAS, IKDC	PRP injection is useful in the treatment of early cartilage degeneration Increasing age, developing degeneration, presence of patellofemoral degeneration all decrease PRP efficacy
Kon et al <sup>21</sup>	Prospective cohort study, with control group Level of evidence: 2	150 patients with knee OA 50 treated with PRP 50 treated with LW HA (control) 50 treated with HW HA (control) All treated with three total intra-articular injections (q2 wks)	PLT count 600% of whole blood Leukocyte quality: N/S	At 2-mo follow-up, PRP and LW HA groups improved more than HW HA At 6-mo follow-up, significantly better results in PRP group PRP and LW HA treatments similar in patients > 50 y old, and in advanced OA PRP > HA in younger patients with early OA, chondral lesions	PRP was superior to control groups in reducing symptoms, pain PRP had better results in more active, young patients with early OA
Riardo et al <sup>22</sup>	Prospective, comparison cohort study Level of evidence: 4	144 patients with knee OA 72 treated with PRGF (single-spinning) 72 treated with PRP (double-spinning) All treated with three total intra-articular injections (q3 wks)	PLT count not reported Leukocyte quality: rich (single-spinning) vs. poor (double-spinning)	Both groups improved significantly in terms of outcome scores over the course of 1-y follow-up Significantly more minor local adverse (swelling, pain) events in PRP group	PRP injections produced more pain or swelling than PRGF Significant clinical improvement, with best results in younger patients with low degree of OA

Abbreviations: HA, hyaluronic acid; HW, high weight; IKDC, International Knee Documentation Committee; LW, low weight; N/S, not specified; OA, osteoarthritis; PRP, platelet-rich plasma; q, every; VAS, visual analog scale; WOMAC, Western Ontario and McMaster Universities Arthritis Index.

autologous PRP and reported significant improvements in all outcome scoring scales at both 6- and 12-month follow-up with 100% return to previous activities. These results were irrespective of whether or not the patients had undergone previous operative intervention for cartilage lesions (cartilage shaving and/or microfracture). Total 50 consecutive patients with grade II or III chondromalacia underwent 1 year of treatment with nine PRP injections by Hart et al,<sup>19</sup> with the results demonstrating significant improvements in all measured outcome scores. Magnetic resonance imaging determined that despite the reduced pain and improved quality of life in these patients, there was no significant cartilage regeneration. Jang et al<sup>20</sup> prospectively evaluated 65 patients suffering from osteoarthritis treated with intra-articular PRP injection; their results showed statistically significant improvements in several outcome scores, but pain relapsed at an average 8.8 months after the procedure. Increased age and the presence of patellofemoral joint degeneration worsened the outcomes with PRP in this study. Similarly, Kon et al<sup>21</sup> reported on 50 patients with degenerative cartilage lesions of the knee and severe osteoarthritis who were treated with three autologous PRP intraarticular injections and found that PRP had longer therapeutic efficacy than HA injections in comparable demographic cohorts. As with many of the aforementioned clinical studies, superior results were reported in younger and more active patients with a lower degree of cartilage degeneration.

The variety of techniques for PRP production has also been compared in patients with degenerative knee cartilage lesions and osteoarthritis. Filardo et al<sup>22</sup> compared 72 patients treated with three injections of PRP prepared with a single-spinning procedure (plasma rich in growth factors [PRGF]) to an equal number of patients treated in similar fashion with PRP prepared with a double-spinning approach. The authors reported statistically significant improvements in subjective knee clinical outcome scores at 2-, 6-, and 12-month follow-up, particularly in younger patients with a lower degree of cartilage degeneration. There were no differences in the comparative analysis of the two groups at these follow-up outcome time points, although a significantly larger number of double-spinning PRP injections produced transient local pain and swelling reactions.

While most clinical studies on PRP have evaluated its use in patients with chronic degenerative cartilage disease, a single case report from Freitag

et al<sup>23</sup> found good efficacy for a course of photoactivated PRP injections in a 38-year-old patient with a traumatic focal chondral lesion of the knee from a basketball injury. Another case reported by Sánchez et al<sup>24</sup> reported accelerated articular cartilage healing and excellent symptomatic improvement in a patient with a nontraumatic knee cartilage avulsion injury treated by arthroscopic reattachment supplemented with PRP injection.

PRP has recently been studied as an augmentation device with various other cartilage procedures for the purpose of osteochondral lesion treatment with early reports of success (► Table 6.2). Guney et al<sup>25</sup> evaluated treatment for osteochondral lesions of the talus by comparing arthroscopic microfracture alone to that augmented with PRP injection on the 1st postoperative day. The latter cohort of patients had significantly superior American Orthopaedic Foot and Ankle Society (AOFAS) scores, Foot and Ankle Ability Measure (FAAM) overall pain domain and 15-minute walking domain subgroup scores, and VAS pain scores in comparison to isolated arthroscopic microfracture. Siclari et al<sup>26</sup> reported significant KOOS improvements in all subcategories after treatment of focal knee chondral defects with a cell-free resorbable polyglycolic acid-hyaluronan implant immersed with autologous PRP after bone marrow stimulation via subchondral drilling. The improvement seen at 1 year postoperatively was still present at 2 years after the surgery, with histological analysis of biopsy tissue showing potential regeneration of hyaline-like cartilage. Recently, the senior author (B.J.C.) published a promising technique using micronized allogeneic articular cartilage combined with PRP as a scaffold and adjunct to traditional microfracture surgery (BioCartilage, Arthrex, Inc., Naples, FL).<sup>27</sup>

### 6.4 Future Roles for Platelet-Rich Plasma in Treating Cartilage Disease

Cartilage damage can take place secondary to both acute and chronic processes. Acute traumatic injury to articular cartilage can create focal chondral loss and potentially lead to a more widespread osteoarticular problem. By contrast, chronic joint stress over a prolonged period of time may lead to eventual widespread inflammatory chondral degradation and osteoarthritis. Most studies evaluating PRP have evaluated its use within the setting of uniform cartilage degeneration as seen

**Table 6.2** Clinical outcome studies of platelet-rich plasma use in combination with articular cartilage surgery for cartilage injury

References	Study design	Methods	PRP platelet count	Results	Conclusions
Guney et al <sup>25</sup>	Case-control study Level of evidence: 2	Group A: 16 OA lesions of talus, arthroscopic microfx alone (control) Group B: 19 OA lesions of the talus, arthroscopic microfx + PRP	PLT mean count 5.4-folds ( $\pm$ 1.2) increase from whole blood Leukocyte quality: N/S	At average 16.2 mo follow-up, combined treatment arthroscopic microfx 4- PRP had significantly better functional score outcomes (AOFAS, FAAM overall pain, FAAM 1 5-min walking domain, VAS pain)	PRP as an adjunct to arthroscopic microfx for treating osteochondral lesions of talus improves medium-term functional score status in patients compared with microfx alone
Siclari et al <sup>26</sup>	Case series Level of evidence: 4	52 patients with focal chondral defects of the knee treated with arthroscopic subchondral drilling 4- PGA-HA implant immersed with autologous PRP	PRP not conditioned, mean concentration $832.1 \times 10^3$ PLT/ $\mu$ L Leukocyte quality: N/S	At 1-, 2-y follow-up, significant improvement in all KOOS subcategories compared with baseline and 3-mo follow-up Maintained KOOS data between 1 and 2y Biopsy histological analysis showed hyaline-like to hyaline cartilage repair tissue rich in chondrocyte morphology cells, type II collagen and PGs	Patients with focal cartilage defects improve clinically with PGA-HA implant 4- PRP after subchondral drilling, and may have greater potential for regeneration of hyaline-like cartilage

Abbreviations: AOFAS, American Orthopaedic Foot and Ankle Society scoring system; FAAM, Foot and Ankle Ability Measure; KOOS, Knee Injury and Osteoarthritis Outcome Score; microfx, microfracture; N/S, not specified; PRP, platelet rich plasma; PLT, platelet; PGA-HA, cell-free resorbable polyglycolic acid-hyaluronan; PGs, proteoglycans; VAS, visual analog scale for pain.

in osteoarthritis. While relatively devoid from the literature in human clinical studies, animal studies have evaluated the proposed effect of PRP on focal osteochondral defects (► Fig. 6.2). Sun et al<sup>3</sup> evaluated the treatment of large osteochondral defects created in the patellofemoral groove of rabbit models with treatment arms consisting of PRP in a polylactic-glycolic acid (PLGA), PLGA alone, or no treatment. The authors reported no significant differences between the PRP and untreated groups in terms of macroscopic examination, microcomputed tomography (larger amount of subchondral bone formation) and histological changes of the newly formed bone and cartilage within the defect after 12 weeks. With the knowledge of the efficacy of PRP in younger cohorts, future clinical evaluations of the use of PRP with younger patients sustaining acute osteochondral defects would be

valuable.<sup>23</sup> Moreover, the utility of PRP in the treatment of cartilage degeneration and injury in joints other than the knee is largely unreported and may become a worthwhile research venue that is pursued.

Aside from cartilage degeneration, the clinical use of PRP has been studied in numerous clinical and preclinical reports to determine value in the following sports medicine pathologies: Achilles tendon rupture, chronic tendinosis, chronic rotator cuff tendinopathy or tearing, muscle injury, and meniscal repair.<sup>28</sup> Sadoghi et al<sup>29</sup> systematically reviewed the use of PRP in the treatment of Achilles tendon ruptures in animal and human studies, and found that analysis of 14 total studies demonstrated significant effects of PRP in the treatment of Achilles tendon ruptures likely secondary to enhanced scar tissue maturation. Krogh et al<sup>30</sup>



**Fig. 6.2** (A) A blood draw is performed on the patient intraoperatively after the induction of anesthesia. (B) The blood is spun down in a centrifuge to separate out the platelet-rich plasma. (C) The platelet-rich plasma is placed at the microfracture site with a fibrin glue sealant.

systematically reviewed and analyzed randomized controlled trials of injection therapies for patients with lateral epicondylitis, and determined that PRP was statistically superior to placebo, although most studies were at risk for bias using the Cochrane risk of bias tool. Carter et al<sup>31</sup> analyzed 24 articles evaluating PRP use in advanced wound therapy and concluded that PRP therapy in cutaneous wounds showed improved partial and complete wound healing compared with wound care alone in a control group. Villela et al<sup>32</sup> reported similar conclusions in the treatment of diabetic ulcers with PRP. These additional uses for PRP continue to be studied with higher levels of evidence, with the hope that more definitive conclusions can be made either in favor of or against routine use in the orthopedics.

While most of the cartilage-related research on the efficacy of PRP has been devoted to its effect on chondrocytes thus far, recent studies have examined the effect of both leukocyte-rich and leukocyte-poor PRP on synoviocytes. More than 80% of normal human synovium is composed of synoviocytes that produce cytokines and matrix metalloproteinases that can mediate cartilage metabolism. While no differences in clinical outcomes have been observed till date between leukocyte-rich and leukocyte-poor derivatives, a recent laboratory study by Braun et al<sup>33</sup> found that leukocyte-rich PRP and red blood cell concentrates both led to significantly greater cell death and proinflammatory mediator production than leukocyte-poor PRP or platelet-poor plasma. These findings led the authors to suggest that clinicians consider using leukocyte-poor, red blood cell-free

formulations of PRP when performing intra-articular procedures. Further research and clinical correlation is required in this area to determine whether clinical consequences may exist secondary to the release of catabolic proteases that may perpetuate inflammation and potentially inhibit tissue healing.

## 6.5 Conclusion

There are numerous basic science and clinical studies demonstrating the positive effects that PRP has on cartilage degeneration or injury, with many of the aforementioned *in vivo* studies exhibiting improvements in both symptoms and joint function. The improvement in symptoms after intra-articular injection of PRP in knee osteoarthritis is short-term, with many studies demonstrating declines in efficacy after 1 year. In addition, both age and degree of cartilage degeneration have an inverse relationship with the effectiveness of PRP. PRP as a treatment option for cartilage damage or injury is attractive given the low rate of adverse events observed in numerous clinical studies, its simplicity of quickly obtaining a sample of autogenous whole blood, and the absent risk of disease transmission. PRP has been used as an adjunct to several cartilage-related procedures including microfracture surgery and graft, scaffold and implant insertion.<sup>7</sup> Ultimately, however, recent systematic reviews on the topic conclude that there is still a paucity of high-quality data providing sufficient evidence to support or disprove the clinical utility of PRP in symptomatic osteoarthritis of the knee.<sup>34</sup> There is even less clinical evidence



supporting its use in other joints or in the treatment of focal osteochondral defects despite the basic science evidence in favor of its use.<sup>35</sup> In addition, not all basic science and clinical studies on PRP have concluded it has positive effects.<sup>7</sup> Further studies— particularly randomized, controlled trials—to evaluate the *in vivo* effects of PRP on human cartilage are imperative to conclusively determine the proper patient population and expected outcomes for the use of PRP in the setting of cartilage damage and injury.

### Practical Clinical Application

In our practice, we routinely utilize platelet-rich plasma (PRP) as an adjunctive therapy when performing microfracture for cartilage defects in the knee especially when combined with micronized allograft articular cartilage (BioCartilage, Arthrex, Inc., Naples, FL). In the clinic setting, we have had good results using PRP injection therapy for patients with knee osteoarthritis who have failed cortisone and/or viscosupplementation (HA) injections. We have recently completed a randomized prospective comparison of HA vs PRP and determined that some will respond to PRP when they have previously failed HA treatment. Recognizing that it is an uncovered benefit by third-party payers, we typically utilize covered treatments as first-line options, however, we are striving to better understand and predict who will be a PRP responder with symptomatic knee OA.

### References

- [1] Fortier LA, Barker JU, Strauss EJ, McCarril TM, Cole BJ. The role of growth factors in cartilage repair. *Clin Orthop Relat Res* 2011; 469(10): 2706–2715
- [2] Zhu Y, Yuan M, Meng HY et al. Basic science and clinical application of platelet-rich plasma for cartilage defects and osteoarthritis: a review. *Osteoarthritis Cartilage* 2013; 21(11): 1627–1637
- [3] Sun Y, Feng Y, Zhang CQ, Chen SB, Cheng XG. The regenerative effect of platelet-rich plasma on healing in large osteochondral defects. *Int Orthop* 2010; 34(4): 589–597(SICOT)
- [4] Gobbi A, Karnatzikos G, Mahajan V, Malchira S. Platelet-rich plasma treatment in symptomatic patients with knee osteoarthritis: preliminary results in a group of active patients. *Sports Health* 2012; 4(2): 162–172
- [5] Fortier LA, Hackett CH, Cole BJ. The effects of platelet-rich plasma on cartilage: basic science and clinical application. *Oper Tech Sports Med* 2011; 19: 154–159
- [6] Weiser L, Bhargava M, Attia E, Torzilli PA. Effect of serum and platelet-derived growth factor on chondrocytes grown in collagen gels. *Tissue Eng* 1999; 5(6): 533–544
- [7] Smyth NA, Murawski CD, Fortier LA, Cole BJ, Kennedy JG. Platelet-rich plasma in the pathologic processes of cartilage: review of basic science evidence. *Arthroscopy* 2013; 29(8): 1399–1409
- [8] Krüger JP, Hondke S, Endres M, Pruss A, Siclari A, Kaps C. Human platelet-rich plasma stimulates migration and chondrogenic differentiation of human subchondral progenitor cells. *J Orthop Res* 2012; 30(6): 845–852
- [9] Abrams GD, Frank RM, Fortier LA, Cole BJ. Platelet-rich plasma for articular cartilage repair. *Sports Med Arthrosc Rev* 2013; 21(4): 213–219
- [10] Hayden MS, Ghosh S. Shared principles in NF-kappaB signaling. *Cell* 2008; 132(3): 344–362
- [11] Sundman EA, Cole BJ, Karas V et al. The anti-inflammatory and matrix restorative mechanisms of platelet-rich plasma in osteoarthritis. *Am J Sports Med* 2014; 42(1): 35–41
- [12] Bendinelli P, Matteucci E, Dogliotti G et al. Molecular basis of anti-inflammatory action of platelet-rich plasma on human chondrocytes: mechanisms of NF-κB inhibition via HGF. *J Cell Physiol* 2010; 225(3): 757–766
- [13] Patel S, Dhillon MS, Aggarwal S, Marwaha N, Jain A. Treatment with platelet-rich plasma is more effective than placebo for knee osteoarthritis: a prospective, double-blind, randomized trial. *Am J Sports Med* 2013; 41(2): 356–364
- [14] Filardo G, Kon E, Buda R et al. Platelet-rich plasma intra-articular knee injections for the treatment of degenerative cartilage lesions and osteoarthritis. *Knee Surg Sports Traumatol Arthrosc* 2011; 19(4): 528–535
- [15] Kon E, Buda R, Filardo G et al. Platelet-rich plasma: intra-articular knee injections produced favorable results on degenerative cartilage lesions. *Knee Surg Sports Traumatol Arthrosc* 2010; 18(4): 472–479
- [16] Sampson S, Reed M, Silvers H, Meng M, Mandelbaum B. Injection of platelet-rich plasma in patients with primary and secondary knee osteoarthritis: a pilot study. *Am J Phys Med Rehabil* 2010; 89(12): 961–969
- [17] Filardo G, Kon E, Di Martino A et al. Platelet-rich plasma vs hyaluronic acid to treat knee degenerative pathology: study design and preliminary results of a randomized controlled trial. *BMC Musculoskelet Disord* 2012; 13: 229–236
- [18] Spaková T, Rosocha J, Lacko M, Harvanová D, Gharaibeh A. Treatment of knee joint osteoarthritis with autologous platelet-rich plasma in comparison with hyaluronic acid. *Am J Phys Med Rehabil* 2012; 91(5): 411–417
- [19] Hart R, Safi A, Komzák M, Jajtner P, Puskeiler M, Hartová P. Platelet-rich plasma in patients with tibiofemoral cartilage degeneration. *Arch Orthop Trauma Surg* 2013; 133(9): 1295–1301
- [20] Jang SJ, Kim JD, Cha SS. Platelet-rich plasma (PRP) injections as an effective treatment for early osteoarthritis. *Eur J Orthop Surg Traumatol* 2013; 23(5): 573–580
- [21] Kon E, Mandelbaum B, Buda R et al. Platelet-rich plasma intra-articular injection versus hyaluronic acid viscosupplementation as treatments for cartilage pathology: from early degeneration to osteoarthritis. *Arthroscopy* 2011; 27(11): 1490–1501
- [22] Filardo G, Kon E, Pereira Ruiz MT et al. Platelet-rich plasma intra-articular injections for cartilage degeneration and osteoarthritis: single- versus double-spinning approach. *Knee Surg Sports Traumatol Arthrosc* 2012; 20(10): 2082–2091
- [23] Freitag J, Barnard A, Rotstein A. Photoactivated platelet-rich plasma therapy for a traumatic knee chondral lesion. *BMJ Case Rep* 2012; 2012: pii: bcr2012006858
- [24] Sánchez M, Azofra J, Anitua E et al. Plasma rich in growth factors to treat an articular cartilage avulsion: a case report. *Med Sci Sports Exerc* 2003; 35(10): 1648–1652

- [25] Guney A, Akar M, Karaman I, Oner M, Guney B. Clinical outcomes of platelet rich plasma (PRP) as an adjunct to microfracture surgery in osteochondral lesions of the talus. *Knee Surg Sports Traumatol Arthrosc* 2013
- [26] Siclari A, Mascaro G, Gentili C, Kaps C, Cancedda R, Boux E. Cartilage repair in the knee with subchondral drilling augmented with a platelet-rich plasma-immersed polymer-based implant. *Knee Surg Sports Traumatol Arthrosc* 2014; 22(6): 1225–1234
- [27] Abrams GD, Mall NA, Fortier LA, Roller BL, Cole BJ. BioCartilage: background and operative technique. *Oper Tech Sports Med* 2013; 21: 116–124
- [28] Lopez-Vidriero E, Goulding KA, Simon DA, Sanchez M, Johnson DH. The use of platelet-rich plasma in arthroscopy and sports medicine: optimizing the healing environment. *Arthroscopy* 2010; 26(2): 269–278
- [29] Sadoghi P, Rosso C, Valderrabano V, Leithner A, Vavken P. The role of platelets in the treatment of Achilles tendon injuries. *J Orthop Res* 2013; 31(1): 111–118
- [30] Krogh TP, Bartels EM, Ellingsen T et al. Comparative effectiveness of injection therapies in lateral epicondylitis: a systematic review and network meta-analysis of randomized controlled trials. *Am J Sports Med* 2013; 41(6): 1435–1446
- [31] Carter MJ, Fyelling CP, Parnell LK. Use of platelet rich plasma gel on wound healing: a systematic review and meta-analysis. *Eplasty* 2011; 11: e38
- [32] Villela DL, Santos VL. Evidence on the use of platelet-rich plasma for diabetic ulcer: a systematic review. *Growth Factors* 2010; 28(2): 111–116
- [33] Braun HJ, Kim HJ, Chu CR, Drago J. The effect of platelet-rich plasma formulations and blood products on human synoviocytes: implications for intra-articular injury and therapy. *Am J Sports Med* 2014; 42(5): 1204–1210
- [34] Dold AP, Zywiell MG, Taylor DW, Dwyer T, Theodoropoulos J. Platelet-rich plasma in the management of articular cartilage pathology: a systematic review. *Clin J Sport Med* 2014; 24(1): 31–43
- [35] Filardo G, Kon E, Roffi A, Di Matteo B, Merli ML, Marcacci M. Platelet-rich plasma: why intra-articular? A systematic review of preclinical studies and clinical evidence on PRP for joint degeneration. *Knee Surg Sports Traumatol Arthrosc* 2013;•••: 10.1007/s00167-013-2743-1