Review Article

International Journal of Dental and Health Sciences
Volume 01,Issue 04

PROSTHETIC REHABILITATION OF MAXILLARY DEFECTS: A REVIEW

Sanjeeva Rao Olepu[1], Mithilesh Kumar[2],Ramu Rajesh Babu[3],Tanvi Kalra[4]
1,2,3,4.Post Graduate,Department of Prosthodontics & Implantology,D.J College of Dental Sciences & Research,Modinagar-201204 (UP)

ABSTRACT:

The maxillofacial region is of crucial importance during one's all interpersonal relationships and relates to some of our deepest needs. A high value is placed upon personal attractiveness in most societies and it is also one of the primary modes of self-expression. In the wide variety of maxillary deformities resulting from congenital malformation, trauma, or excision of malignant tissue, restoration of function and of facial form is achieved by replacement of missing soft tissue, sectioning and repositioning misplaced bone, bone grafting of osseous defects and normal contour. In many cases, it is challenging to reconstruct maxillary defects and satisfactory aesthetic outcomes can be difficult to achieve. Maxillary defects can be treated by surgical reconstruction or prosthetic rehabilitation. Prosthetic intervention should occur at the time of surgical resection and will be necessary for the reminder of patient's life and the primary surgical enhancements that can improve prosthesis outcome and patient acceptance, the time sequence and phases of prosthetic procedures, prosthetic techniques and materials and troubleshooting patient's functional complaints.

Key words: Maxillary defects, prosthetic rehabilitation, surgical reconstruction, aesthetics.

INTRODUCTION:

Maxillary defects can be treated by surgical reconstruction or prosthetic rehabilitation. Surgical reconstruction is particularly difficult from a technical perspective and this approach has a high risk of complications and seldom leads to patient satisfaction. And this approach may not possible when recurrence of malignancy is suspected, when fragments of facial bones are displaced in fracture.[1] There are also cases in which plastic surgery is not feasible in cases of advanced age of patient, very large deformity, poor blood supply on post radiated tissues, and poor health.[2] In severe compound comminuted fractures of the mandible or maxilla with loss of tissue such are seen in gunshot wounds or other sever maxillofacial injuries, the provision of surgical prosthesis is an essential part of treatment. The prosthesis serves not only to maintain the anatomic position of the remaining fragments, but also as a framework over which the soft tissues are sutured. [3] And there are many deformities with defects of the bony framework of the face in which a prosthetic appliance is needed, either in the form of a denture, or to restore contour. [4]

*Corresponding Author Address: Dr. Sanjeeva Rao Olepu,Dept. of Prosthodontics & Implantology,D.J College of Dental Sciences & Research,Modinagar-201204 (UP) E-mail: sanjeevaolepu@yahoo.co.in

CLASSIFICATION OF ACQUIRED MAXILLARY DEFECTS PROPOSED BY ARAMANY: FIGURE [1]

Class i - The resection in this group is performed along the midline of the maxilla; the teeth are maintained on one side of the arch. This is the most frequent maxillary defect, and most patients fall into this category. [5]

Class ii- The defect in this group is unilateral, retaining the anterior teeth on the contra lateral side.

Class iii - The palatal defect occurs in the central portion of the hard palate and may involve part of the soft palate. The surgery does not involve the remaining teeth.

Class iv- The defect crosses the midline and involves both sides of the maxillae. There are few teeth remaining which lie in a straight line.

Class v- The surgical defect in this situation is bilateral and lies posterior to the remaining abutment teeth.

Class vi- It is rare to have an acquired maxillary defect anterior to the remaining abutment teeth. This occurs mostly in trauma or in congenital defects rather than as a planned surgical intervention. [5]

MANAGEMENT OF MAXILLECTOMY PATIENT:

Preoperative considerations:

The prosthodontist is concerned with four objectives, according to Desjardins [1977]:

- Psychological support of the patient,
- Pre-operative dental management,
- Preoperative impressions,
- Suggestions for the surgeon.[6]

Obturator design for partially edentulous patients: According to ARAMANY- Basic principles of obturator design for partially edentulous patients are as follows:

Class i design: In classical maxillectomy resection, the dentition and the alveolar bone are removed along the midline. Preservation of the alveolar bone adjacent to teeth abutting the defect has been recommended by Desjardins. [11] The design can be either linear or tripodal. Two or three anterior teeth are splinted whenever possible, and support is derived from the central incisor and the most posterior abutment tooth. If the dental arch is curved, the principle of effective indirect retention is utilized by the location of a rest on the canine, or on the distal surface of the first premolar in a tripodal design. Direct retention is obtained either from the labial surface of the anterior teeth with a gate design or an I bar on the central incisor. Posterior retention is placed on the buccal surface of the molars, and bracing is located palatally. If the anterior teeth are not included in the design, a linear design is recommended. Unilateral design requires bilateral retention and stabilization on the same abutment teeth. A diagonally opposed retention and stabilization system can be utilized. Support is located

in a linear fashion, and retention is located on the buccal surfaces of the premolars and the palatal surfaces of the molars. Stabilizing components are placed on the palatal surfaces of the premolars and buccal surfaces of the molars. [7] FIGURE [2]

Class ii design: The premaxilla on the defect side is maintained. A tripodal design is recommended. Primary support is placed on the tooth nearest the defect as well as the most posterior molar on the opposite side. An indirect retainer is positioned as perpendicular to the fulcrum line as possible. Guiding planes are located proximally on the distal surface of the anterior tooth and the distal surface of the molar. Retention on all abutment teeth is located on the buccal surfaces, and stabilizing components are placed on the palatal surfaces. [7] FIGURE [3]

Class iii design: The design is based on quadrilateral configurations. Support is widely distributed on both premolars and molars. Retention is derived from the buccal surfaces and stabilization from the palatal surfaces. FIGURE [4]

Class iv design: The defect includes the premaxilla on the nonsurgerized side. The design is linear. Support is located on the centre of all remaining teeth. Retention is located mesially on the premolars and palatally on the molars. Stabilizing components are palatal on the premolars and buccal on the molars. [7] FIGURE [5]

Class v design: Splinting of at least two terminal abutment teeth on each side is suggested. I-bar clasps are placed bilaterally on the buccal surface of the most distal teeth, and stabilization and support are located on the palatal surfaces. This is basically a tripodal configuration. Gate prosthesis is a viable alternative for this patients.[7] FIGURE [6]

Class vi design: Anterior palatal defects, the least frequently occurring class, are caused by trauma more often than by surgery. In such defects, two anterior teeth are splinted bilaterally and connected by a transverse splint bar. A clip attachment may be used without an elaborate partial framework. If the defect is large, or the remaining teeth are in less than optimal condition, a quadrilateral configuration design is followed. [7] FIGURE [7]

Surgical obturator design: The surgical obturator is normally fabricated from polymethylmethacrylate resin of either the heat or auto polymerizing type. It is most commonly fabricated in clear resin to facilitate visualization of the underlying tissues at the time of placement and during the initial healing period.

The need to retain the surgical obturator in place for an extended period of time without removal makes maximum retention a necessity. Wire clasps will usually not provide adequate retention for the surgical obturator and may, at times, actually make it more difficult to place. [8] Similarly, the addition of teeth to the surgical obturator is both unnecessary and contraindicated. The surgical obturator will be replaced very soon after it is placed, usually in about a week's time,

and the presence of teeth on the obturator may complicate its placement, particularly if the obturator does not seat completely with the surgical packing in place and the occlusion on the teeth of the obturator is unacceptably heavy. The surgical obturator may be fabricated with holes placed in the periphery to permit suturing to the borders of the defect, for circumzygomatic wiring, or for interdental wiring or suturing. The prosthodontist must design the obturator for use regardless of the final line of resection. There are two basic approaches that can be taken when designing a surgical obturator for the dentate patient. One can fabricate the obturator according to the most conservative line of resection, which will still allow the obturator to be used for larger resections with the understanding that surgical dressing may be needed to fill the space between the obturator and the final line of resection. This method allows the surgeon to utilize the obturator regardless of the size of the defect and does not require the surgeon (or the prosthodontist) to perform intraoperative adjustments to the obturator.

The other option is to design and fabricate the surgical obturator for the most extreme surgical resection; thereby making it fit best in the worst case situation. With this approach the surgeon must be willing and able to modify the obturator to accommodate teeth that are not resected but have been removed from the cast during obturator fabrication. Another option with this type of design is to have the prosthodontist available at the time of surgery to perform the modifications. [9]

Surgical obturator fabrication and use: The teeth in the area of resection are removed and the surrounding alveolar process in the planned defect area is reduced approximately 2 mm.

This additional reduction is important to allow adequate space for the surgical obturator introrally without coming into premature occlusal contact with the opposing dentition during function. Only the alveolar process is reduced to ensure a lack of occlusal interference. Substantial interdental and soft tissue undercuts are blocked out and the cast is duplicated. The surgical obturator is then waxed and processed on the duplicate cast. Another option is to fabricate the surgical obturator directly on the cast with auto polymerizing resin. FIGURE [8]

Two thicknesses of base plate wax are adapted to the duplicate cast as outlined and serve as the pattern for the surgical obturator. For the dentate patient, the wax up should contact all remaining teeth up to their height of contour but without approaching the area of occlusal contact. Having the cast articulated with the mandibular cast is beneficial for die wax up. The wax is carried to the height of contour of the teeth to ensure that there is an adequate thickness of resin to support interdental wiring if it is to be used. If clasps are added, it is important to place them in areas that will not interfere with seating of the obturator during surgery nor interfere with the occlusion of the opposing teeth. Following processing and

retrieval, the obturator is adjusted to ensure ease of seating on the original cast and trouble-free placement at the time of surgery. The completed surgical obturator is sterilized and inserted following resection and placement of the surgical dressing. The surgical obturator and dressing will be removed approximately 1 week postoperatively. [9]

Postsurgical obturator fabrication and use: The postsurgical obturator prosthesis is customarily fabricated of resin with wire retentive clasps in strategic locations. If adequate retentive undercuts are not present on the abutment teeth, they may be created by modification of tooth structure or added with composite resin. Substantial retentive undercuts and multiple clasps may be required to retain the postsurgical obturator with wire clasps, depending upon the location and size of the surgical defect and the position and number of abutment teeth available. [12] The resin base portion of the obturator prosthesis should contact the axial surfaces of all remaining teeth whenever possible. While maximal tooth contact makes the prosthesis more difficult to adapt to the teeth initially, it provides maximum stability and has the greatest potential for distributing the forces generated by the obturator to the greatest number of teeth and the broadest area of residual palate possible.[10] FIGURE [9]

At the time, the surgical obturator and packing are removed from the defect, the post surgical obturator should be available to place immediately when the postsurgical obturator has been fabricated on a preoperative cast with arbitrarily drawn and carved extensions in the defect area, and it is assumed that extensive immediate modification of the obturator will be necessary to make it functional. Modification of the obturator in the area of the defect is critical to its function as well as to the comfort of the patient.

Stabilizing the obturator during the relining procedure is an open-mouth procedure because adaptation of the defect walls to the obturator when the teeth are together cannot be obtained. A technique that has proven useful in such situations for patients with remaining mandibular teeth opposing the defect area is to provide a single posterior occlusal stop on the oral surface of the obturator .With this occlusal stop, the obturator can be inserted and the patient instructed to occlude the teeth to seat the obturator completely during impression or reline procedures. In this way the obturator can be maintained at its original level. It also provides support for the obturator to resist downward rotation during function, thereby reducing the retentive load on the maxillary abutment teeth. The risk of this technique is that downward pressure on the obturator caused by tissue shrinkage in the defect may lead to premature occlusion. Careful evaluation of the soft tissue contact within the defect with pressure-indicating paste or resilient material on a regular basis is necessary during the healing period to avoid this problem.

Oral surface of the obturator prior to placement: Unlike conventional dentures, the obturator is usually worn during sleeping hours and should only be removed for brief periods while cleaning the defect and the prosthesis. Extended periods without the obturator may result in difficulty reinserting the prosthesis. Constant wearing of the obturator necessitates the application of proper hygiene to both the prosthesis and the defect. During the postsurgical or interim healing period, when it is likely that tissue-conditioning and/or soft reline material is present on the bulb of the obturator, the patient should be instructed to avoid effervescent types of denture cleansers as they will tend to cause blistering of the lining material.

Regular recall visits of approximately 1 week initially and then 2 weeks and eventually a month apart are appropriate to monitor the progress of healing within the defect and to modify the obturator prosthesis to reflect healing changes. [9]

Definitive obturator mouth preparation: In the later stages, attention should be given to preparing the mouth for fabrication of the definitive obturator prosthesis. Teeth that were provisionalized should be definitively restored. Treatment of teeth on which endodontic therapy had been initiated should be completed. Definitive periodontal therapy may also take place during the late interim period. Every effort should be made to maintain the remaining maxillary teeth and to restore them to an optimum state of health in preparation for definitive obturator fabrication. Determination of which teeth will be used as the primary abutment teeth is made taking into account the location of the teeth relative to the surgical defect and also the position of the teeth in die remaining arch, their coronal integrity, and their periodontal support. Strategic teeth that are determined to be in less than ideal condition may be strengthened by splinting them to adjacent teeth. [9]

Definitive obturator fabrication: When the design of the removable partial denture framework portion of the obturator prosthesis has been determined and the appropriate mouth preparation performed, the final impression for the nondefect portion of the prosthesis should proceed. The impression should be extended into the surgical defect sufficiently to allow the laboratory technician to extend the retentive meshwork portion of the casting into the region of the defect without interference from remaining anatomic structures. The nondefect portion of the obturator prosthesis, including restoration of abutment teeth, fabrication of the cast framework, and placement of any attachments to be used, should be completed before the impression of the defect area is undertaken. [13] It is important to finalize the adaptation and position of the retaining and supporting portion of the prosthesis (the cast framework) prior to extending into the surgical defect to create die obturator portion. Die cast framework is tried in the mouth to verify complete seating and sufficient frictional

fit to resist downward rotational dislodgment. FIGURE [10].When the framework has been adjusted to satisfy these prerequisites, autopolymerizmg acrylic resin is added to the retentive meshwork to serve as an impression tray for the obturator portion extending into the surgical defect. A wax occlusion rim may also be added to assist in evaluating facial support, tooth position, and occlusal registration. FIGURE [11]

One of the most difficult aspects of generating the defect portion of obturator prosthesis is to maintain the framework or nondefect portion in its original position relative to the residual palate and abutment teeth. The incremental addition of impression or reline material to the detect portion may frequently and unavoidably cause incomplete seating or rotation of the nondefect portion of the prosthesis away from its original position.

Further additions only increase the lack of complete seating of the framework. One technique that will counter this tendency for inferior displacement of die prosthesis is to add an occlusal stop to the occlusion rim prior to the impression/extension of the surgical defect.

The impression of the surgical defect is carried out with the materials of choice until complete obturation is attained. While satisfactory obturation of the defect is evaluated by speech production and absence of nasal leakage during swallowing, it is also important to ensure that the framework remains in its original relationship to the abutment teeth.

When satisfactory obturation has been attained, the impression is removed and the original master cast is altered. If the obturator prosthesis is processed on the original cast without functional generation of the defect area, it can be performed as a reline/addition procedure as part of the delivery process. FIGURE [12]

Obturators for large detects should routinely be made hollow to reduce the weight. Numerous techniques have been described for the fabrication of hollow obturator bulbs and most have their merits. As a general principle, the shape and position of the defect may be the best determinant of whether the obturator is hollowed and sealed from the oral surface or from the superior surface.[15] FIGURE [13]

Delivery and post insertion follow-up: The delivery appointment for definitive obturator prosthesis is generally a relatively brief session. Post insertion instructions should include recommendations for the frequency of removal and cleaning of the prosthesis and defect. Prior experience with the interim prosthesis will usually suggest how much difficulty the patient will experience with accumulation of secretions on the surface of the obturator as well as the need for oral hygiene counselling to maximize the ongoing health and stability of the abutment teeth. It should be assumed that the patient will wear the obturator 24 hours a day, and for that reason hygiene procedures must be re-emphasized at every visit to avoid complications of

dental disease. The patient should be seen approximately 24 hours following placement to assess the function of the obturator and to examine the defect area for early signs of irritation. Additional follow-up visits should be scheduled depending upon the findings at 24 hours, and adjustments should continue until it is determined that optimal adaptation of the obturator has been attained. Patient complaints of leakage from the nose or changes in speech clarity will usually signal that the tissues contacting the obturator have undergone further change and readaptation is indicated. [14]

CONCLUSION:

Patients with intraoral defects will seek treatment to address the loss of comfort, function, or natural appearance. The science and art employed in the profession of dentistry can play an important role in the fabrication of prosthesis. Prosthodontic rehabilitation of any maxillofacial defect is a skilled, lengthy and involved process. However, if attention is paid to the proper sequencing and details of treatment, it can be one of the satisfying procedures in all the branches of prosthodontics.Over the years there has been lot of advancement and development occurring in the field of maxillofacial prosthetics. It may be technique of impression making, the material used for fabrication of prosthesis, recent trends for impression 3-D imaging which captures a digital image of defect and these are also helpful in making prosthesis, thus to rehabilitate patient to as nearly as possible to normal human being.

REFERENCES:

1. Genden EM, Okay D, Marita TS et al. comparison of functional and quality of life outcomes in patients with and without palatomaxillary reconstruction. Arch Otolaryngol Head Neck Surg 2003; 129: 775-80.
2. Chang TL, Garrett N, Roumanas E, Beumer J. treatment satisfaction with facial prostheses. J Prosthet Dent 2005; 94 (3):275-80.
3. Koyama S, Sasaki S, Inai T, Watanabe. Effects of defect configuration, size, and remaining teeth on masticatory function in post maxillectomy patients. Journal of oral rehabilitation 2005; 32: 635-641.
4. Converse JM. Maxillofacial deformities and maxillofacial prosthetics. J Prosthet Dent 1963; 13 (3):571-82.
5. Mohamed A. Aramany. Basic principles of obturator design for partially edentulous patients. Part I: Classification J Prosthet Dent 2001; 86 (6): 559-561.
6. Desjardins R. early rehabilitative management of the maxillectomy patient J Prosthet Dent 1977; 38:311.
7. Mohamed A. Aramany. Basic principles of obturator design for partially edentulous patients. Part II: Design principles. J Prosthet Dent 2001; 86 (6): 562-568.
8. Raja HZ, Saleem MN. Gaining Retention, Support and Stability of a Maxillary Obturator. Journal of the College of the

Physicians and Surgeons Pakistan. 2011; 21(5): 311-14.

9. Jacob RF. Clinical management of the dentulous maxillectomy patient. IN: Taylor TD (2000). Clinical maxillofacial prosthetics. Chicago: Quintessence, 2000:103-120.

10. Bailey LW, Edwards D. psychological considerations in maxillofacial prosthetics. J Prosthet Dent 1975; 34 (5):533-8.

11. Desjardins R. obturator prosthesis design for acquired maxillary defects J Prosthet Dent 1978; 39:424. Brown k. peripheral considerations in improving obturator retention J Prosthet Dent 1968; 20:176.

12. Brudwik J. Advanced removable partial dentures. Chicago Quintessence 1999:71.

13. Gregory R. Parr and L. Kirk Gardner. The evolution of the obturator framework design. J Prosthet Dent 2003; 89 (6): 608-10.

14. Converse JM. Maxillofacial deformities and maxillofacial prosthetics. J Prosthet Dent 1963; 13 (3):571-82.

15. Ronald P. Desjardins, Early rehabilitative management of the maxillectomy patient. Contemp Clin Dent 2013; 4: 492-97.

FIGURES:

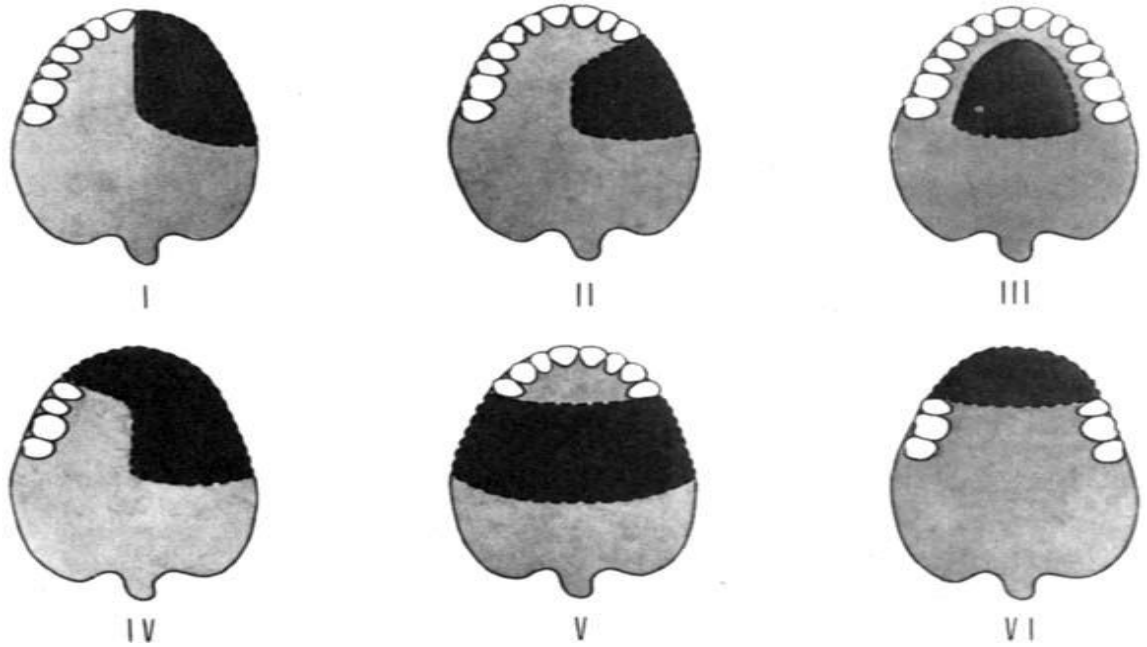

FIGURE: 1

Classification of acquired maxillary defects proposed by aramany

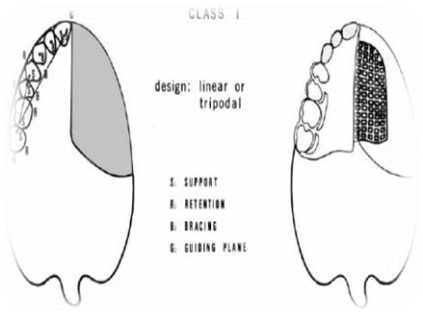

FIGURE: 2

Obturator design for partially edentulous patients: according to aramany- class 1 design

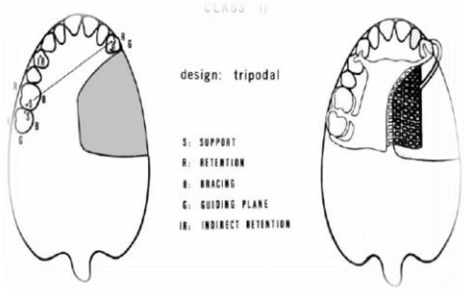

FIGURE: 3

Class 2 design

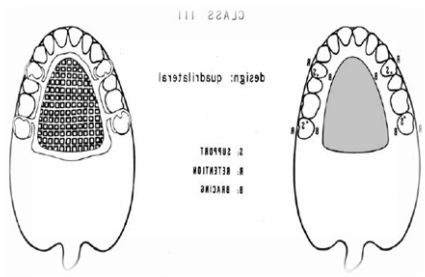

FIGURE: 4

Class 3 design

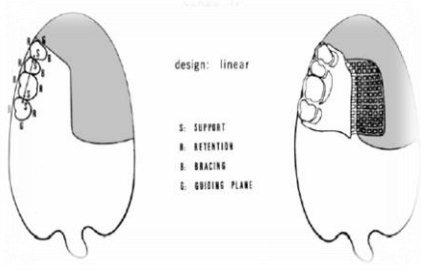

FIGURE: 5

Class 4 design

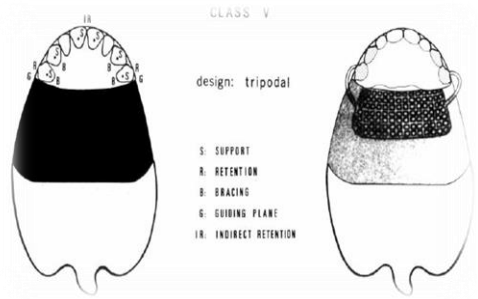

FIGURE: 6

Class 5 design

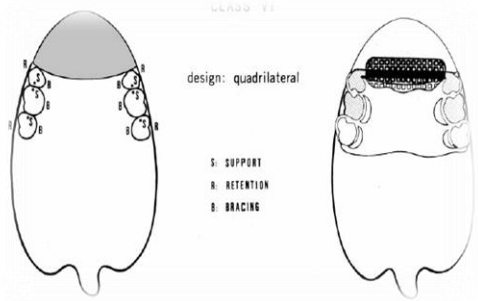

FIGURE: 7

Class 6 design

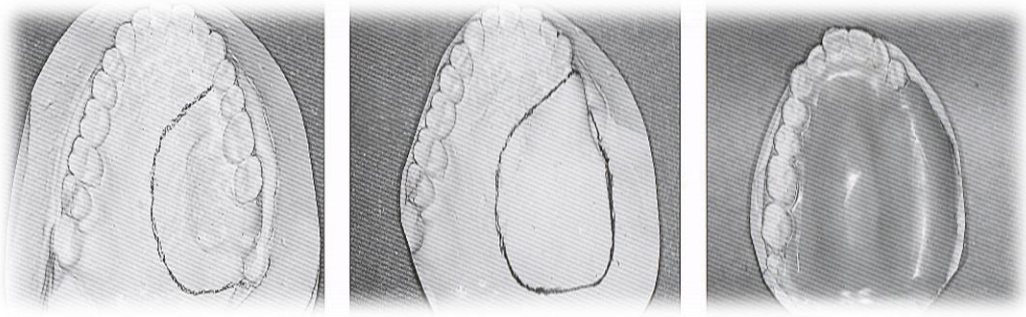

FIGURE: 8

Surgical Obturator

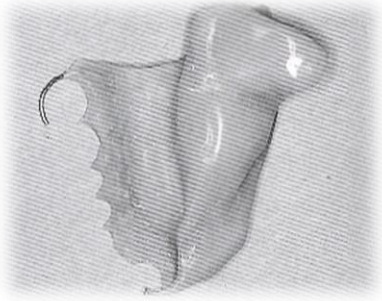

FIGURE: 9

Post Surgical Obturator

FIGURE: 10

Autopolymerizing acrylic resin tray has been added to the framework

FIGURE: 11	FIGURE: 12
A wax occlusal rim has also been added to the try prior to making the defect impression	An occlusal stop was added to the wax occlusion rim of the tray/record base to assist in mainta ining the framework in its original position .During the impression procedure

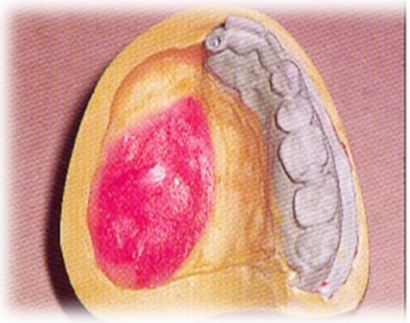

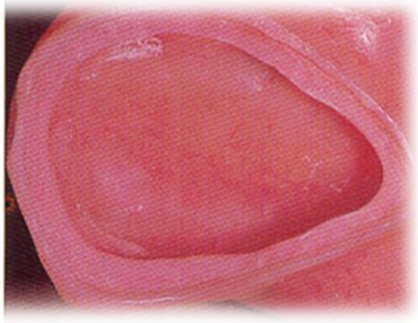

FIGURE: 13

The superior surface of the obturator is prepared for the addition of a lid which may be made by adapting a sheet of wax directly to the finish line seen on the obturator, after which it is carefully removed and processed in resin.