

FUNCTION AFTER BILATERAL TOTAL HIP ARTHROPLASTY

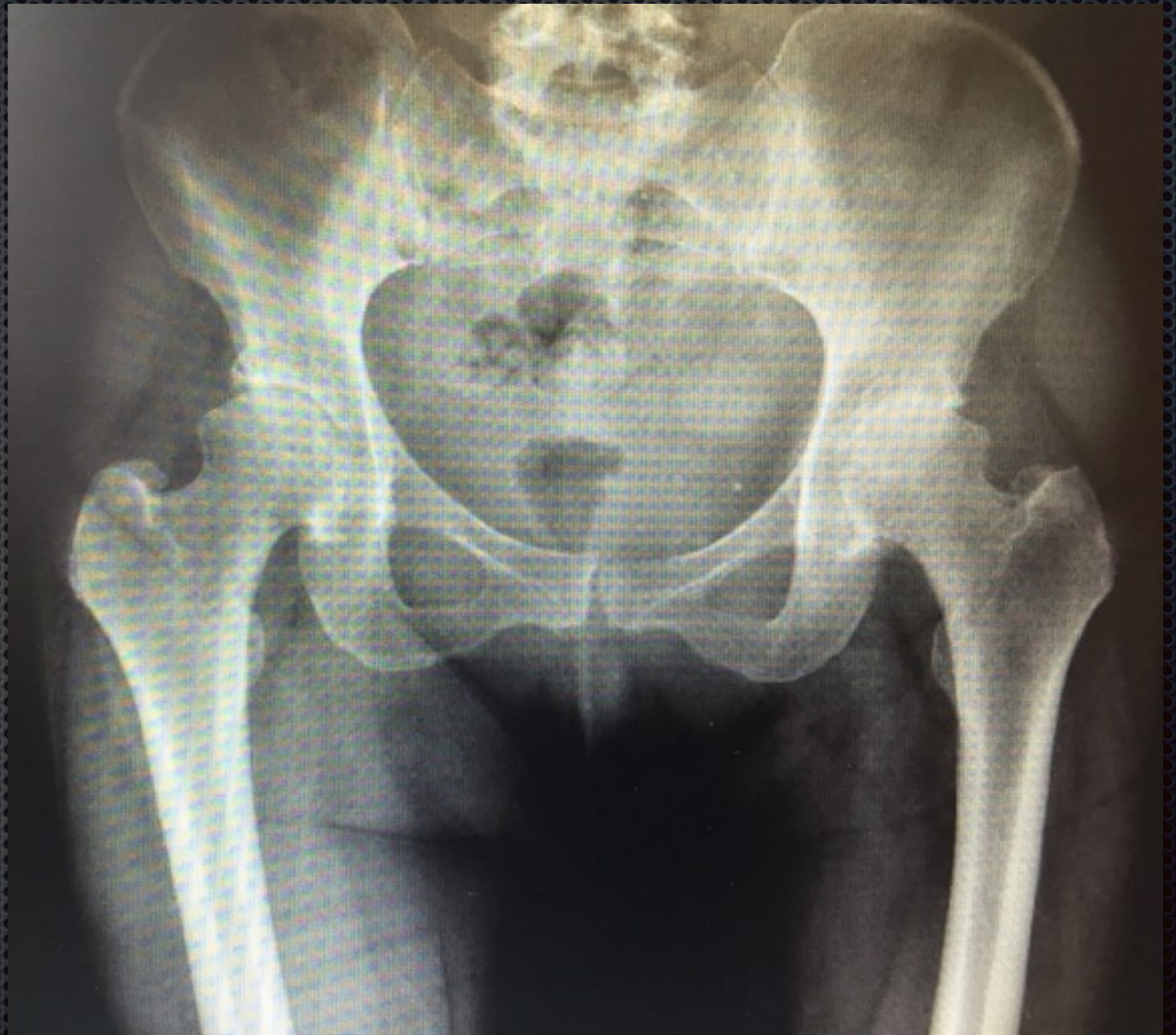
CASE STUDY

- Active lady, 74yrs of age
- severe bilateral hip arthritis
- has Staged THR surgery

Preoperative Xrays

SYMPTOMS

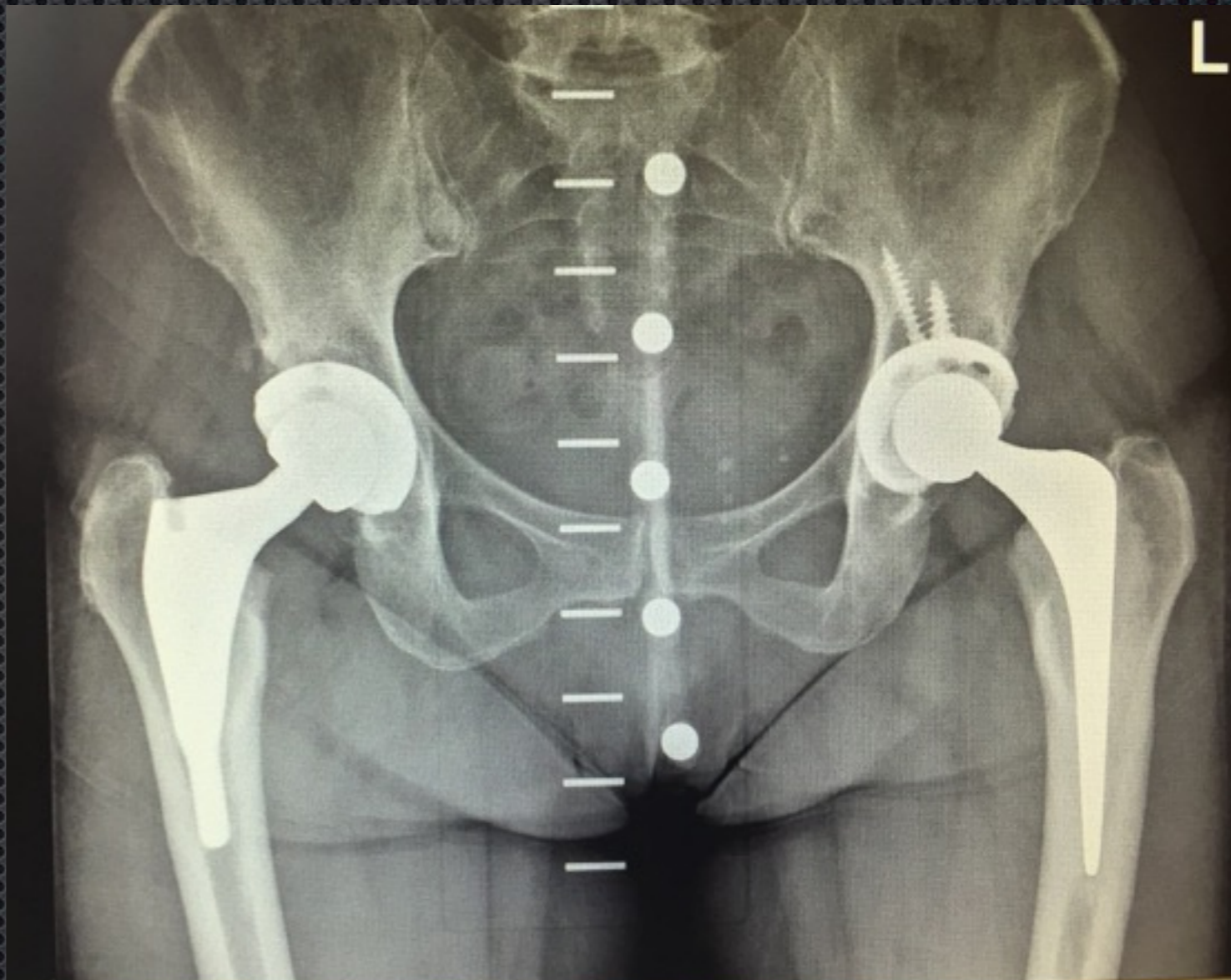
- PAIN
- LIMP
- DECREASED ACTIVITY



Postoperative Xrays

Left Hip done -6 yrs ago

Right done 1 year ago



Functional Outcome

