

---

## **KEEPING THE BETTER HALF: A CASE OF HEMISECTION WITH SOCKET PRESERVATION**

Shruta Narayanan<sup>1</sup>, Mala Dixit Baburaj<sup>2</sup>

1. MDS, Department of Periodontics, Nair Hospital Dental College.

2. Head of Department, Department of Periodontics, Nair Hospital Dental College.

---

### **ABSTRACT:**

Hemisection (removal of one root) involves removing significantly compromised root structure and the associated coronal structure through deliberate excision. Hemisection of a multirooted tooth may be a suitable treatment option when the destruction is restricted to one root and the other root is healthy.

Hemisection is a conservative approach. The goal is to retain as much of the original tooth structure as possible and preserves tooth structure and alveolar bone.

This case report describes a procedure of hemisection of a mandibular molar with the extraction of distal half of the tooth. This has been followed by socket preservation of the distal socket using an allograft (Demineralised Freeze Dried Bone Allograft-DFDBA). The tooth has been restored with a fixed prosthesis.

The present case was followed up for a period of 1 year. Satisfactory preservation of ridge height was observed.

An interdisciplinary approach was required with endodontic, surgical and prosthetic procedures. Long term success is achievable with thorough diagnosis and treatment planning.

**Keywords:** DFDBA, Socket Preservation, Resection, Hemisection



### **INTRODUCTION**

Maintenance of a functional dentition is of high importance to the patient. Various treatment modalities are available that combine multiple branches of dentistry like restorative dentistry, endodontics and periodontics in order to retain the teeth.

Loss of a posterior tooth leads to several sequelae, such as drifting of teeth, supra eruption of opposing tooth, loss of supporting bone and compromised mastication. The clinician should follow the principle of salvaging that which is present.

Tooth resection aims at preserving as much healthy tooth structure as possible rather than sacrificing the whole tooth.<sup>[1]</sup> Hemisection denotes removal or separation of root with its accompanying crown portion of mandibular molars.<sup>[2]</sup>

Compiled results of several studies have shown that the average failure rate of hemisected tooth supported prosthesis is close to 13.1% which is comparable to the failure rate of implants. According to Buhler et al, hemisection should be considered an option prior to molar extraction, as this procedure can ensure cost savings with good long-term success.<sup>[3]</sup>

The indications of hemisection are as follows:

Periodontal Indications:

- Severe vertical bone loss involving only one root of multi-rooted teeth.
- Through and through furcation destruction.
- Unfavourable proximity of roots of adjacent teeth, preventing adequate hygiene maintenance in proximal areas.
- Severe root exposure due to dehiscence.

Endodontic and Restorative Indications:

- Prosthetic failure of abutments within a splint
- Endodontic failure:
- Vertical fracture of one root
- Severe destructive process

Contraindications:

- Presence of a strong abutment tooth adjacent to the proposed hemisection, which could act as an abutment to a prosthesis.
- The remaining root may be inoperable for the necessary root canal treatment.
- Fusion or proximity of the roots which may prevent their separation.

Appropriate endodontic therapy must be performed before these tooth modifications to avoid intrapulpal dystrophic calcification and postoperative tooth sensitivity. The furcation region is carefully smoothed, to allow proper

cleansing and thus to prevent accumulation of plaque

Following hemisection, socket preservation procedure helps in retaining the available bone and soft tissue for better function and aesthetics. [4]

## CASE DETAIL

A 44 year old female patient reported to the Out Patient Department of Nair Hospital Dental College with the chief complaint of pain in the lower right posterior tooth region since the past two months. On examination, the right mandibular first and second molar i.e. 46 and 47 were found to be carious and there was food lodgment between the two teeth.

Examination and Investigation:

The baseline probing pocket depth in 46 was 5mm. (Fig.1)

An Introral Periapical Radiograph of the same region showed bone loss extending beyond middle half of the root in 46 and 47. The distal root of 46 showed radiolucency in the root and coronal portion suggestive of extensive root caries. There was also mesial and distal radiolucencies in the coronal portion of the 47, involving pulp.(Fig.2)

The inter radicular bone in 46 did not seem affected and mesial root showed no abnormality. Hence the decision to retain the mesial root was made and a hemisection was planned to remove distal half of the 46, following root canal therapy in the same tooth.

#### Phase I therapy:

The oral prophylaxis was performed for the patient and she was kept under recall. The patient first underwent root canal therapy in 46 and 47. (Fig.3)

#### Phase II therapy:

The hemisection procedure was then carried out. 2 % Chlorhexidine was used as a pre procedural mouth wash. A full thickness mucoperiosteal flap was reflected. The area was thoroughly debrided to remove all the granulation tissue. (Fig.4) The tooth was split in half, through the furcation with an air rotor. (Fig. 5,6) The distal half of the tooth was extracted using an elevator and forceps. (Fig. 7)

The socket was irrigated and any residual debris cleared. An allograft – Demineralised Freeze Dried Bone Allograft of particle size 500-1040 µm obtained from Tata Memorial tissue bank, was packed into the socket (Fig. 8), to preserve ridge height. The mucoperiosteal flaps were then approximated and sutured to obtain primary closure over the grafted site. (Fig. 9) The occlusal table was reduced to minimise forces on the mesial half of 46. The surgical site was covered with periodontal dressing –Coe-Pack. ( Fig. 10) The patient was prescribed medication, Doxycycline 200mg stat followed by 100 mg twice daily for 3 days and an analgesic, Ibuprofen, thrice daily for 3 days. Suture removal was done 1 week later. Four weeks following surgery, complete healing was observed at surgical site (Fig.11). Intra Oral Periapical

radiograph showed good bone height in the region where the graft was placed.(Fig. 12)

#### Phase III Therapy

A porcelain fused to metal, fixed partial denture was planned and the 46 and 47 were used as abutments as a premolar and molar respectively, with a premolar pontic in between to replace the missing distal half of the tooth. ( Fig. 13a, 13b, Fig. 14)

### DISCUSSION

In the present case, satisfactory healing was noted 4 weeks after surgery. A ridge lap design was used for the pontic. The case was followed up for a period of 1 year. There was no mobility noted in the mesial root of 46 and the patient was able to maintain good oral hygiene.

Hemisection of teeth helps preserve the healthy tooth structure and avoids the complications following extraction of tooth, such as extrusion of opposing tooth and ridge resorption.

Carnevale , in his study on long term effects of root resective therapy, concluded that hemisection can be considered an effective measure to resolve periodontal problems of furcation defects.<sup>[5]</sup>

Resected molars used as intermediate abutments of a fixed bridge, had a higher survival rate, according to Shin-Young Park .The occlusal loads on the intermediate abutment are smaller than on terminal abutments and single abutments.<sup>[6]</sup>

Socket preservation with bone graft, post hemisection, aids in preserving volume and contour of the remaining bone to permit subsequent implant placement or prosthetic restoration with a more stable support and aesthetic emergence profile. Studies have shown that DFDBA has osteoinductive property (thus, act as a scaffold). A good amount of bone fill was noted . Thus it can be concluded that the socket preservation helped to maintain the remaining alveolar bone height and prevented further bone resorption.<sup>[7-8]</sup>

## CONCLUSION

Hemisection is a procedure which may be considered as an alternative to extraction and implants. Preservation of the remaining natural root allows for physiologic tooth mobility, which acts as a more suitable abutment for fixed partial dentures than an osseointegrated counterpart.

It must always be considered as an option before extraction. Socket preservation aids in preservation of the ridge height and volume.

## REFERENCES

1. Basaraba N. Root Amputation and tooth hemisection. *Dent Clin of N Amer* 1969;13 : 121
2. Weine FS. *Endodontic Therapy*, 5th Edition.
3. Bühler H. Survival rates of hemisected teeth: an attempt to compare them with survival rates of alloplastic implants. *Int J Periodontics Restorative Dent* 14: 536-543.
4. Rapoport RH, Deep P. Traumatic hemisection and restoration of a maxillary first premolar: a case report. *Gen Dent* 2003; 51(4):340–2.
5. Darby I, Chen S, De poi R. Ridge preservation: What is it and when should it be considered. *Aust Den J* 2008;53:11-21
6. Carnevale G, Pontoricco R, Di febo G. Long term effect of root resective therapy in furcation involved molars.-A 10 year longitudinal study *J Clin. Periodontol* 1998; 25: 209-14.
7. Shin-Young Park, Seung-Yun Shin, SeungMin Yang, Seung-Beom Kye. Factors Influencing the Outcome of Root-Resection Therapy in Molars: A 10-Year Retrospective Study. *J Periodontol* 2009; 80(1):32-40.
8. Kost WJ, Stakiw JE (1991) Root amputation and hemisection. *J Can Dent Assoc* 57: 42-45.

**FIGURES:**

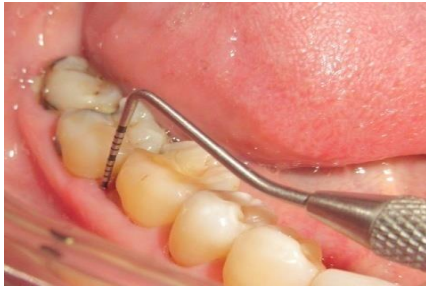

Figure.1: Carious 46, 47 with probing depth of 5mm

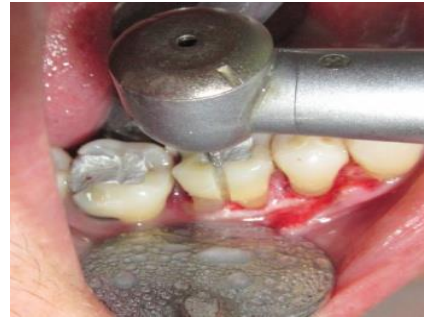

Figure.5: Sectioning of 46 with air rotor

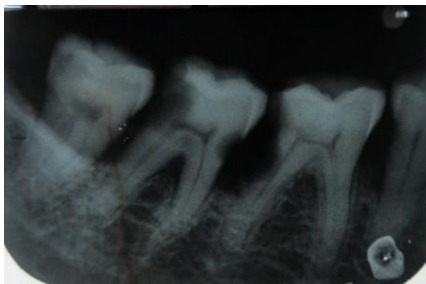

Figure.2: IOPA showing caries in distal root of 46 and coronal 47. Horizontal bone loss present in 46, 47.

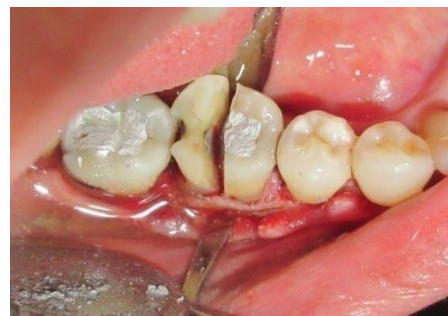

Figure.6: Sectioning of 46 completed

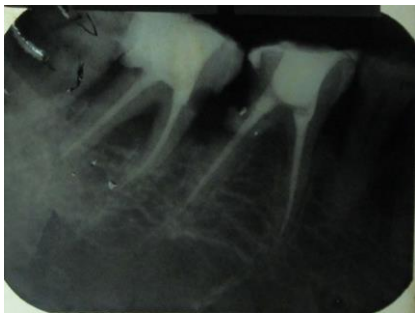

Figure.3: Post RCT IOPA of 46, 47.

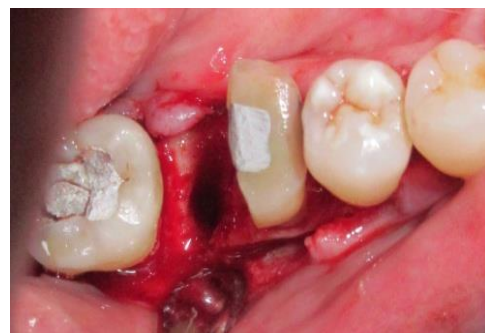

Figure.7: Removal of distal half of tooth

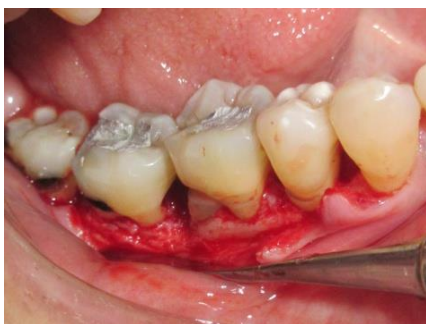

Figure.4: Open flap debridement from 44-48

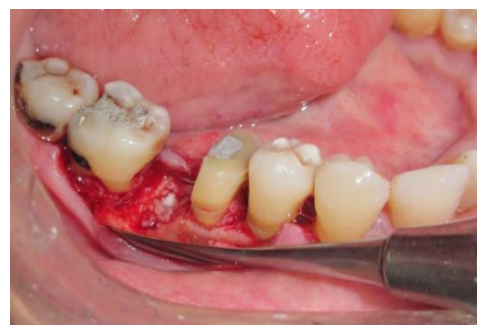

Figure.8: DFDBA graft placed in the socket

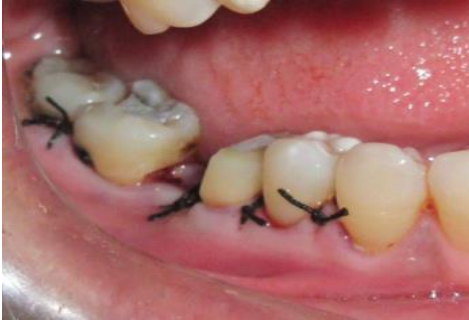

Figure.9: Sutures placed

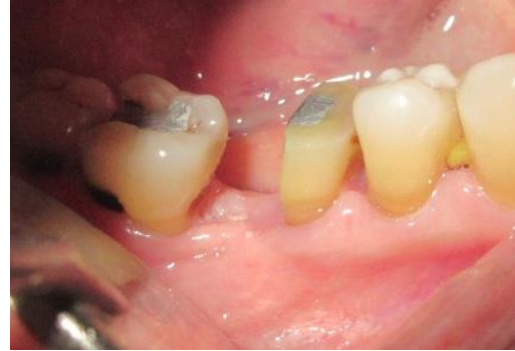

Figure.11: 1 month follow up

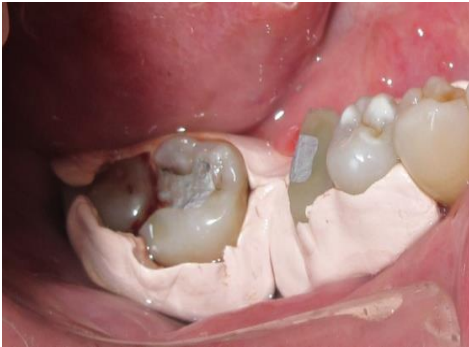

Figure.10: Periodontal pack

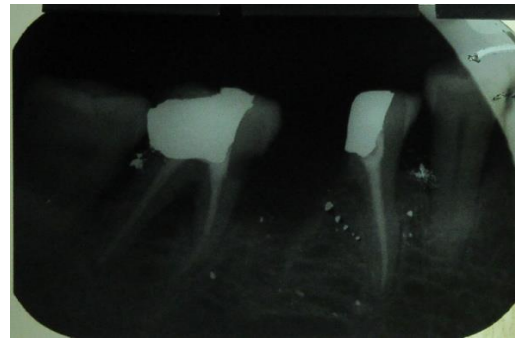


Figure. 12: Fixed prosthesis in 46,47. IOPA 1 month after surgery

Figure. 13 (a),(b)

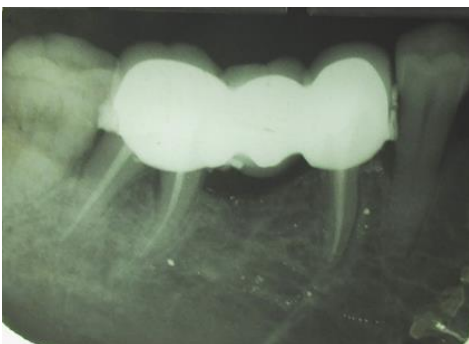
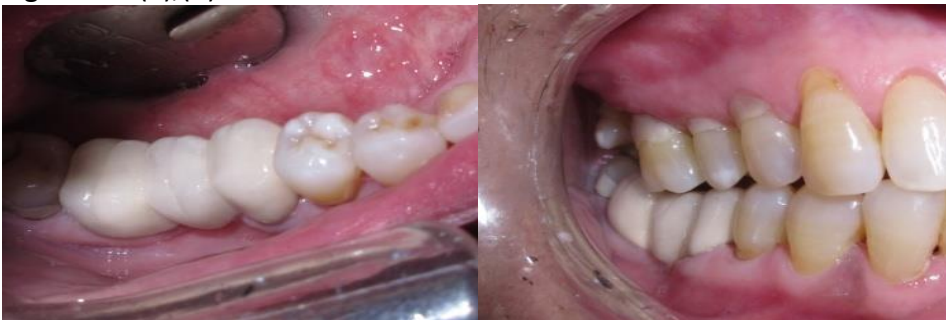
Figure.14:IOPA of Fixed prosthesis in 46,47