

RECONSTRUCTION OF INTERDENTAL PAPILLA IN MAXILLARY ANTERIOR REGION: A CASE SERIES

Bipina P¹, Nagarathna D.V², Manjushree Kadam²

1. Post Graduate Student, Department of Periodontics, A.J Institute of Dental Sciences, Mangalore

2. Professor, Department of Periodontics, A. J Institute of Dental Sciences, Mangalore, India.

ABSTRACT:

An attractive pleasing smile can be achieved with proper positioning of the teeth, gingiva, interdental soft tissue and hard tissue. Several reasons contribute to the loss of gingival and interdental soft tissue. This may result in long clinical crown and black triangle. Most common cause in adult patient is dental plaque. Several surgical and non surgical techniques has been proposed to treat such deformities. The surgical technique is used to re contour, preserve and re construct the soft tissues.

Four patients who had class I or class II type of interdental papilla loss according to Nordland and Tarnow classification were treated. Scaling and root planing was done for all the patients and standard brushing technique was advised (roll on technique) to maintain oral hygiene. The patients were treated for interdental papilla reconstruction with a partial thickness flap. Post-operative evaluation was done after a week in a month interval for three months. The interdental papillary reconstruction was fairly successful.

Key words: Inter dental papilla loss, black triangle, papilla reconstruction.



INTRODUCTION:

Smile plays an important role in improving esthetics and radiates health and self-confidence. An attractive pleasing smile can be achieved with proper positioning of the teeth, gingiva, interdental soft tissue and hard tissue. [1] The interdental papilla is the gingival area that occupies the space between two adjacent teeth. It not only acts as a biologic barrier protecting the underlying

periodontal structures, but also plays a critical role in aesthetics. [2] The shape of interdental papilla is determined by the contact relationships between the teeth, width of tooth surface and the course of CEJ. [3] Several reasons contribute to the loss of gingival and interdental soft tissue. This may result in long clinical crown and black triangle. Most common cause in adult patient is dental plaque.[4] The absence of interdental papilla as a result

*Corresponding Author Address: Dr Bipina P, Department of Periodontics, A.J Institute of Dental Sciences, Mangalore, India. Email: drbipina@gmail.com

of the periodontal disease development leads to aesthetic, phonetic and food impaction problems.^[5] Papillary regeneration aims to fill the black spaces that occur in interproximal surfaces. The absence or loss of interdental papillae can be due to several reasons like plaque associated lesions, traumatic oral hygiene procedures, abnormal tooth shape, improper contours of the restorations, spacing between teeth, loss of teeth.^[3]

Several classifications have been proposed to assess the presence or absence of interdental papilla. Nordland and Tarnow^[3] proposed a classification using three reference point - contact point, facial apical extent of CEJ and interproximal CEJ (Figure1). They classified it into four categories:

Normal: Interdental papilla fills embrasure space to the apical extent of the interdental contact point/area.

Class I: The tip of interdental papilla lies between the interdental contact point and the most coronal extent of CEJ.

Class II: The tip of the interdental papilla lies at/or the apical to the interproximal CEJ but coronal to the apical extent of the facial CEJ.

Class III: The tip of the interdental papilla lies at level with or apical to the facial CEJ.

The aim of this study was to reconstruct the lost or blunted interdental papillae with gingival tissue for esthetic purpose and for maintaining oral health.

CASE SERIES:

The present study was undertaken at department of periodontology and implantology at A.J Institute of Dental Sciences, Mangalore. Four patients reported to the department were treated. They had class I or class II type of interdental papilla loss in maxillary anterior region according to Nordland and Tarnow classification.

CASE REPORT:

Case 1: A 22 year old female patient with complain of black space in upper front teeth was reported. Detailed case history and clinical examination was done in first visit. There was no relevant medical history. On clinical examination class I type of interdental papilla loss was seen between 11 and 21(Figure2). Scaling and root planing was done and standard brushing technique was advised to maintain oral hygiene. Interdental papilla reconstruction was done with a partial thickness flap during the second visit.

Procedure: Complete extra oral and intraoral mouth disinfection was carried out with 2% betadine. Local infiltration anesthesia was administered. Incision was given in a particular manner so as to raise a partial thickness flap from the attached gingiva apical to the open embrasure using two vertical and one horizontal incision(Figure3). Flap was then slid down to completely obliterate the open embrasure(Figure5). Periodontal dressing was applied to the labial aspect of the surgical site(Figure6). Antibiotics and analgesics were administered. The

dressing was removed after one week. Post-operative evaluation was done after one week, (Figure7) one month and three months (Figure8). The interdental papilla reconstruction was fairly successful.

Case 2: A 24 year old male patient reported to department for routine dental checkup. On clinical examination class II type of interdental papilla loss was seen between 21 and 22(Figure 9). There was no relevant medical history. The same procedure was followed and post-operative evaluation was done after one week, one month and three months (Figure10,11). Results were satisfactory.

Case 3: A 23 year old female patient with class I interdental papilla loss between 11 and 21(Figure 12-14) was treated in the above given manner and the papilla reconstruction was successful.

Case 4: A 28 year old female patient with class II interdental papilla loss between 11 and 12 (Figure 15) was treated. Spacing was present between the teeth which may be the cause of interdental papilla loss. Results after three months (Figure 16,17) showed that papilla reconstruction was fairly successful.

DISCUSSION:

The presence of interdental papilla is extremely important in the esthetics. Several reasons contribute to the loss of interdental soft tissue. This may result in black triangle. Several surgical and non-surgical techniques has been proposed to treat such deformities. Non-surgical techniques include correction of traumatic oral hygiene procedure,

restorative/prosthetic restorations, orthodontic approach, and repeated curettage of the papilla. The surgical technique is used to re contour, preserve and re construct the soft tissues. Surgical approaches included three treatment modalities, papilla re-contouring, papilla preservation and papilla reconstruction. [2]

Use of free soft tissue grafts for papillary augmentation was first proposed by Han and Takie in 1996. They described a semi lunar incision with coronal displacement of gingivopapillary unit and placement of sub gingival connective tissue graft. [6]

Azzi et al presented three case reports with a surgical technique that elevated the papilla from its base while leaving it attached to the palatal flap. All these techniques required a second surgical site to obtain the connective tissue graft to obliterate the open embrasure space. [7,8]

Beagle [9] presented a technique to reconstruct interdental papilla using the principles of Abram's roll technique and Evian papilla preservation technique. But this technique has certain disadvantages. There is a risk of damage to the incisive nerves and vessels and incorporation of fat in the undersurface of flap thereby, preventing its vascularization. Obtaining a uniform thickness of flap from the palate and retention of periodontal dressing is difficult.

Sawai and kohad [1] aimed to reconstruct the lost or blunted interdental papillae with gingival tissue for esthetic purpose. A total of 39 open embrasures were surgically closed using this technique. A

partial thickness flap from the attached gingiva was raised apical to the open embrasure using two vertical and one horizontal incision. The flap was then folded upon itself to completely obliterate the open embrasure. The free end of the flap was sutured with the adjacent gingiva. The surgical technique for reconstruction of interdental papilla was fairly successful.

In the present case series four patients were treated for closure of unaesthetic open gingival embrasure and their results were evaluated after a week in a month interval for three months. All these patients had either class I or class II type of interdental papilla loss. Scaling and root planning was done for all the patients and standard brushing technique was advised to maintain oral hygiene. Patients were

REFERENCES:

1. Madhuri Lokhande Sawai, R. M. Kohad. An evaluation of a periodontal plastic surgical procedure for the reconstruction of interdental papillae in maxillary anterior region: A clinical study. Journal of Indian Society of Periodontology - Oct-Dec 2012 Vol 16, Issue 4
2. Damodhar Deepalakshmi et al. Surgical reconstruction of lost interdental papilla. Quintessenz journals perio 2007; 4 (3): 229-234
3. Vijendra P. Singh et al Black triangle dilemma and its management in esthetic dentistry. Dent Res J. 2013 May-Jun; 10(3): 296–301.
4. Priyanaka Jaiswal et al. Surgical reconstruction of interdental papilla using subepithelial connective tissue graft with a coronally advanced flap : A clinical evaluation of five cases .The journal of contemporary dental practice dec 2010 vol 11, no 6
5. surgically treated with partial thickness flap which was slid down to close the open gingival embrasure. Interdental papilla re construction was fairly successful in treated cases.

Advantages of the procedure are it is a simple procedure, secondary surgical site is not required, color matching, better aesthetics.

CONCLUSION:

The surgical technique evaluated for reconstruction of interdental papilla was fairly successful in the treated cases. Post-operative time interval was short, only three months. Further follow up is required for the predictability of the surgical procedure.

5. Jaína Dias de Oliveira et al. Papillary regeneration: anatomical aspects and treatment approaches. RSBO. 2012 Oct-Dec;9(4):448-56
6. Han TJ, Takie HH. Progress in gingival papilla reconstruction. Periodontol 2000 1996;11:65-8.
7. Nelson Carranza et al. Reconstruction of interdental papilla with underlying sub epithelial connective tissue graft : Technical consideration and case report. The international journal of periodontics and restorative dentistry 2011; 31(5) 45-50
8. Azzi R, Ettenne D, Carranza F. Surgical reconstruction of the interdental papilla. Int J Periodontics Restorative Dent 1998;18:467-73
9. Beagle JR. Surgical reconstruction of interdental papilla - Case report. Int J Periodontics Restorative Dent 1992;12:145-51.

FIGURES:

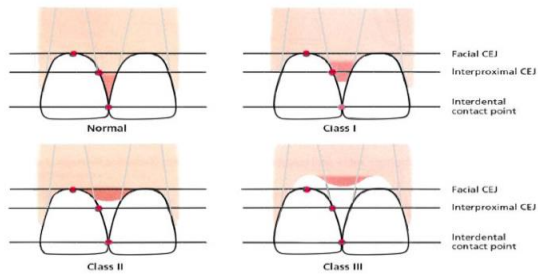


Figure 1- Norland and Tarnow

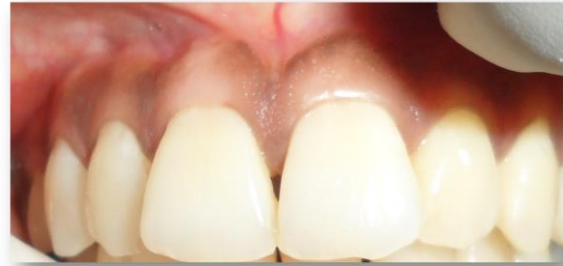

Figure 2 – pre operative class I interdental papilla loss between 11 and 21

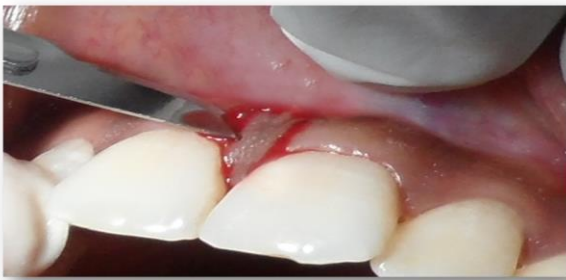

Figure 3- incision

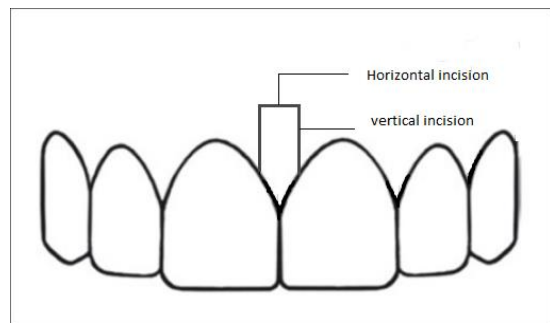


Figure 4- diagrammatic representation of procedure

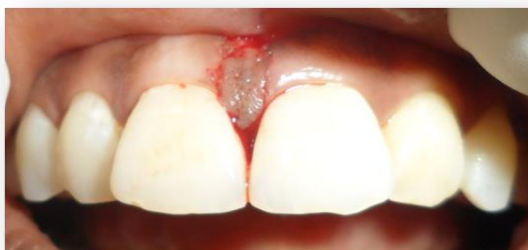

Figure 5- flap slid down to obliterate the open embrasure

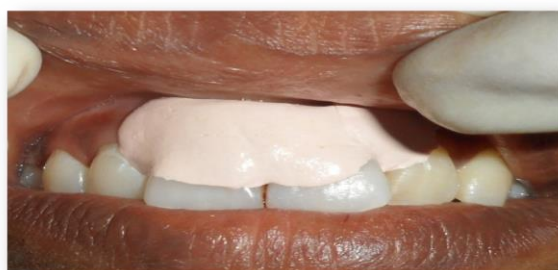

Figure 6- periodontal dressing placed

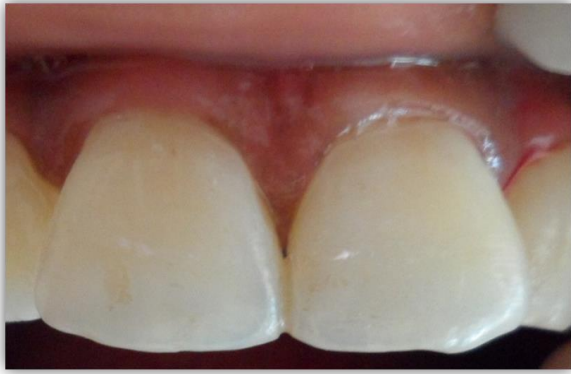

Figure 7- one week post operative

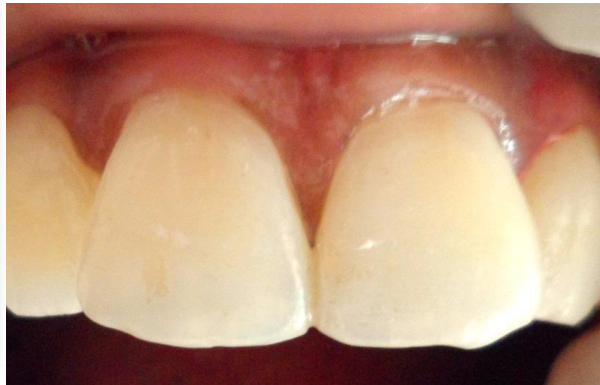

Figure 8- three months post-operative

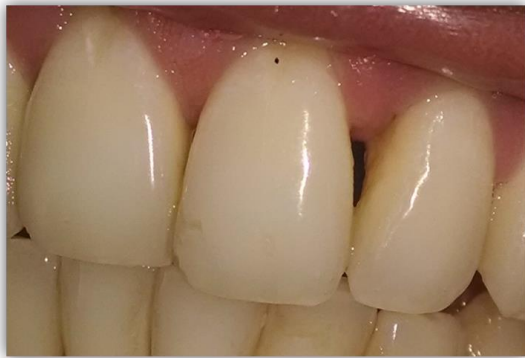

Figure 9 – class II interdental papilla loss between 21 and 22

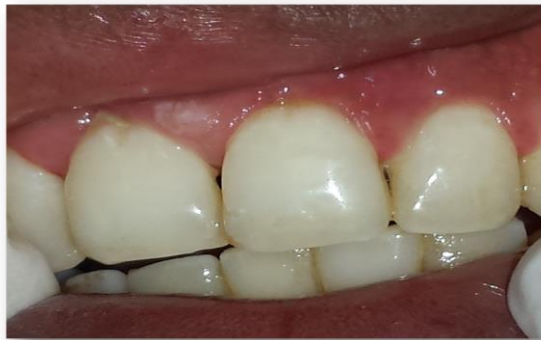

Figure 10- one week post operative

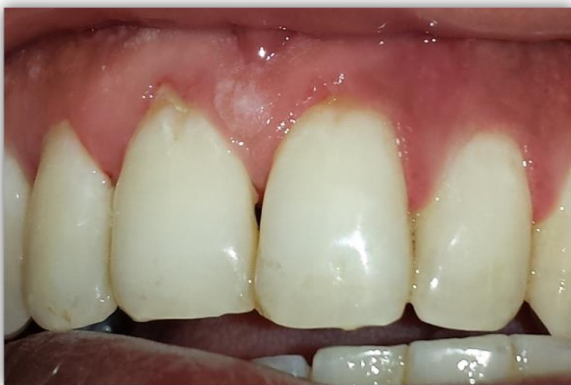

Figure 11 – three months post operative

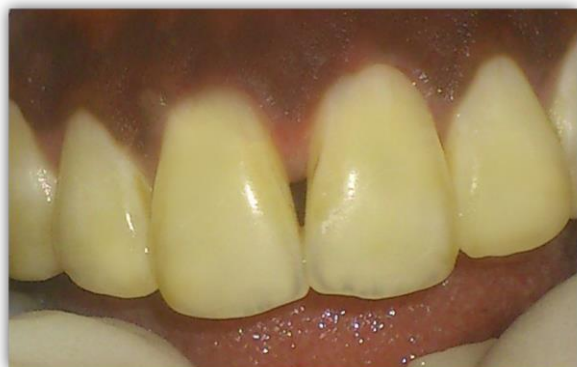

Figure 12- class I interdental papilla loss between 11 and 21

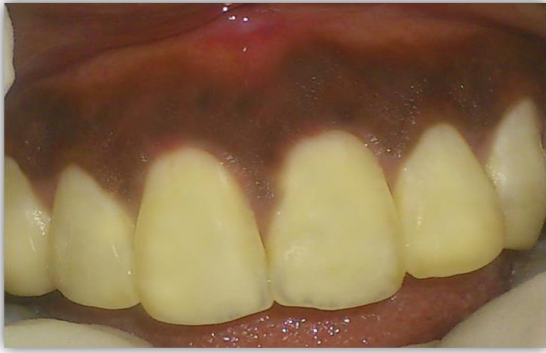

Figure 13 - one week post operative

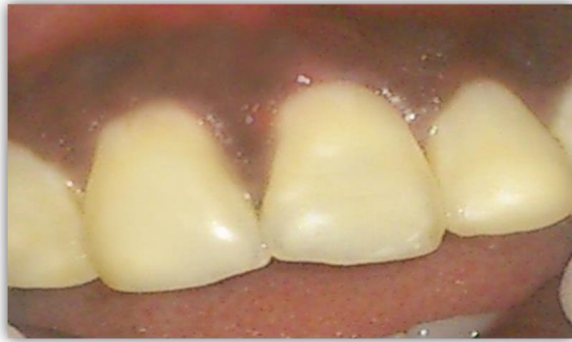

Figure 14- three months post operative

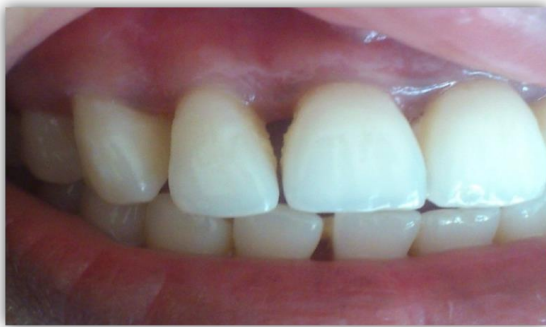

Figure 15- class II interdental papilla loss between 11 and 12

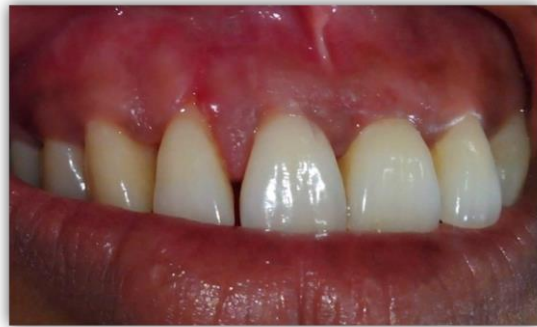

Figure 16- one week post-operative

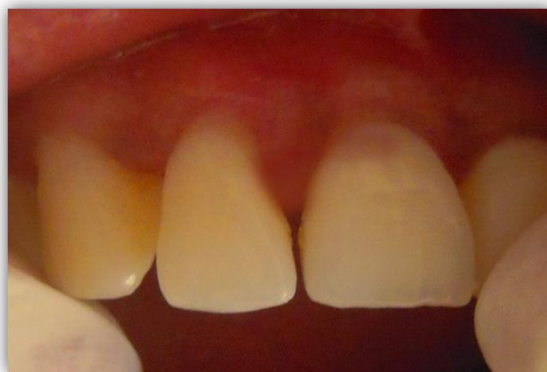

Figure 17- three months post operative