

## MAXILLARY SULCUS EXTENSION TECHNIQUE: A CASE REPORT

Natarajan C<sup>1</sup>

1.M.D.S (Maxillofacial & Oral Surgery), Assistant Professor, Department of Maxillofacial & Oral Surgery, Government Dental College & Hospital, Mumbai.

### ABSTRACT:

Pre-prosthetic surgery is considered as one of the most unheeded parts of oral surgery, in spite of being required more often than not. It is concerned with the surgical modifications of tooth supporting and surrounding structures to enable a better dental prosthesis fabrication. Accurate diagnosis of the problem is of utmost importance in devising and executing a treatment plan. Though various sulculoplasty techniques are available in the literature, in this case report a modified sulculoplasty technique for a shallow maxillary sulcus has been discussed. Six month post-operative results are highly satisfactory.

**Key words:** Flabby Ridge, Pre-prosthetic Surgery, Sulculoplasty.



### INTRODUCTION

Sulculoplasty is a technique wherein the existing basal bone is uncovered surgically by repositioning the overlying mucosa and muscle attachments to a superior position in maxilla. Osseointegrated implants in prosthodontia have decreased the need for major ridge improving surgeries but certain clinical conditions in maxilla warrant surgical intervention.<sup>[1]</sup>

### CASE DETAIL

A 63year old male patient with completely edentulous upper and lower arch was referred by his prosthodontist in view of shallow sulcus and flabby ridge in anterior maxilla. Patient was already a denture wearer for the past two years. Patient had poor stability of dentures and required a new set of dentures. Patient's hard and soft tissues were assessed through clinical examination and radiographs. Intra oral

examination showed pink moist mucosa without ulceration with redundant hyperplastic alveolus in the upper anterior region from canine to canine. Patient's past medical history was unremarkable and after basic blood investigations, he was planned for a modified Cooley's technique of sulculoplasty under regional anaesthesia. Bilateral infra orbital nerve blocks and a naso-palatine nerve block was administered with 2% lignocaine with 1:80000 adrenaline. Anterior maxillary sulcus was infiltrated with normal saline for obtaining easy plane of dissection. A crestal incision was made from right canine region (13) and extended over the crest and around the flabby tissue labially and palatally till the opposite side canine region 23 (figure 1). Vertical releasing incisions were placed at both the ends. The flabby soft tissue over the alveolar crest was excised (Figure 2,3). A supra-

\*Corresponding Author Address: Dr Natarajan C.Email: natarajan.balaji.c@gmail.com

periosteal flap was raised labially, all the muscle attachments were detached and pushed superiorly. The flap was dissected approximately 7mm and the free margin of the flap was sutured to the periosteum (Figure 4). The raw area over the alveolar crest was covered with coe pack and was left to heal by secondary intention. No surgical splints were used. Sutures were removed after ten days and sufficient sulcus extension was achieved. No significant complications were seen intra operatively and post operatively. Postoperatively patient was prescribed analgesics and antibiotics for 1 week. Patient was then followed up at regular intervals of 1 week, 1 month, 4 month and 6 month. Postoperative healing was uneventful with satisfactory surgical and prosthetic outcomes (Figure 5, 6).

## DISCUSSION

Following loss of teeth, bone resorption is inevitable and progressive with a specific pattern for maxilla and mandible. In maxilla resorption occurs labially and buccally with inward and upward resorbing maxilla.<sup>[2, 3]</sup> This results in loss of sulcular depth and apparent changes in level of muscle attachment inferiorly towards the alveolar crest. These consequences of bone resorption affect the future denture stability.

With advances in prosthodontic rehabilitation techniques, sulculoplasty procedures are not routinely done nowadays. Sulculoplasty is broadly classified into three basic types.

Type 1: Mucosal advancement without secondary epithelialisation;

Type 2: Mucosal advancement with secondary epithelialisation;

Type 3: Sulculoplasty with grafting.

A successful sulculoplasty requires no scar formation at the fornix of the sulcus, minimal or no connective tissue between the epithelium and the periosteum on the osseous side of the sulcus and no tension on the soft tissue side of the sulcus.

Kazanjian in 1935 first described a technique to deepen the mandibular labial sulcus.<sup>[4]</sup> Though various surgical procedures are described in the literature, the basic difference in all these procedures lies in three areas.

Area 1:

Location of the incision, whether crestal or vestibular incision is made.

Area 2:

Exposure of bone, whether supra-periosteal or sub-periosteal dissection is made.

Area 3:

Grafting.

Following table provides a comprehensive view of various most common sulculoplasty techniques.

Proposed by	Area	Incision	Dissection	Advantages/Disadvantages
Kazanjian <sup>4</sup> (1935)	For Mandibular Labial Vestibule.	Over the Lip	Supraperiosteal	Labial surface of the sulcus healed by secondary intention resulting in the loss of sulcular depth.
Goodwin <sup>2</sup> (1947)	For Mandibular Labial Vestibule.	Over the Lip	Subperiosteal	Similar to Kazanjian technique.
Cooley <sup>2</sup> (1952)	For both Maxilla and Mandibular vestibule	Over the crest	Supraperiosteal and Subperiosteal	Crest heals with secondary epithelialisation, nerve repositioning possible.
Clark <sup>5</sup> (1953)	For Mandibular Labial Vestibule.	Over the crest	Supraperiosteal	Decreased scar contracture.
Edlan <sup>6</sup> Lip Switch Technique. (1963)	For Mandibular Labial Vestibule.	Over the Lip	Supraperiosteal	The labial side raw surface is covered with the periosteal layer thereby reducing the scar contracture.
Obwegeser <sup>7</sup> Secondary Epithelialisation (1967)	For Maxillary Labial Vestibule.	Mucogingival Junction	Supraperiosteal	Requires pre formed denture with shorter flange.
Tortorelli <sup>2</sup> (Modified obwegeser) (1968)	For Mandibular vestibule	Mucogingival Junction	Supraperiosteal, but at the base of the newly formed sulcus the periosteum is incised and the bone is exposed.	Requires pre formed denture with shorter flange.

Table 1 : Most common Sulculoplasty Techniques

Apart from these most common procedures there are many modifications that are less commonly followed in practice.<sup>[8, 9, 10, 11]</sup>

Excision of tissue in a patient with maxillary alveolar atrophy will result in obliteration of any alveolar support and loss of vestibular depth. Patients with anterior maxillary atrophy can be broadly classified into 3 types<sup>[12]</sup> and the surgical plan is altered accordingly,

Type: 1 when sufficient sulcular depth is present – simple excision of the hypertrophic tissue.

Type: 2 when decreased sulcular depth is present with sufficient basal bone – excision of hypertrophic tissue with sulculoplasty.

Type: 3 when decreased sulcular depth is present with insufficient basal bone – ridge augmentation with bone grafts and then secondary sulculoplasty.

Cooley in 1952, described a technique of sulculoplasty, wherein **incision was made on the palatal side** of the maxillary alveolar crest and a supra-periosteal dissection was carried out till the crest and then continued as **sub-periosteal dissection till the desired sulcus depth**. Then drills are made on the alveolar ridge and the free flap margin on the labial side is sutured through the drill hole to the palatal mucosa. The new sulcus was supported with rubber catheter and percutaneous sutures.

In our case the patient had reduced vestibular depth with sufficient basal bone, so excision of the flabby tissue with sulcus extension was planned. Patient was taken under regional anaesthesia and modified Cooleys technique was used.

Modification 1 - Since the flabby tissues were to be removed an **elliptical incision was made** around the flabby tissues and was **extended over the crest on either side till the canine region** (Figure 1).

Modification 2 - A **supra-periosteal dissection was carried out till the desired sulcular depth** and the free flap margin was sutured to the periosteum of the labial bone as high as possible, which is little bit lower than the sulcular depth dissected but since the muscle attachments are released the mucosa above the suture adapts to the newly formed sulcus.

The alveolar crest is allowed to heal by secondary intention. The advantage of this procedure is that it is done as a day care procedure, under regional

anaesthesia. There is no need for drilling through the maxilla for securing the flap and per alveolar wiring for splinting.

## CONCLUSION

This modified sulculoplasty procedure can be used to concurrently remove the flabby tissues and to increase the sulcular depth in anterior maxilla. The procedure can be carried out as a day care procedure under regional anaesthesia with minimal complications and faster recovery, but careful attention must be paid in case selection. Patients with insufficient basal bone will require an augmentation bone grafting. Six months postoperative results are extremely encouraging.

## REFERENCES

1. Hillerup S. Preprosthetic surgery in the elderly. *Journal of prosthetic dent* 1994 nov72(5):551-8.
2. StarshakTJ Preprosthetic oral and maxillofacial surgery, 2nd ed. CVMosby Co, St. Louis, 1980.
3. Atwood, D. A.: Reduction of residual ridges: A major oral disease entity. *J. Prosthet. Dent.* 1971; 26: 266-279.
4. Kazanjian VH. Surgery as an aid to more efficient service with prosthetic dentures. *J Am Dent Assoc.* 1935;22:566–572.
5. Clark HB, Jr: Deepening of labial sulcus by mucosal flap advancement: Report of a case. *J Oral Surg* 11:165, 1953
6. Edlan A and Mejchar B: Plastic surgery of the vestibulum in periodontal therapy, *Int Dent J* 13: 593-596, 1963.
7. Macintosh, R. B., and Obwegeser, H. L.: Preprosthetic Surgery: A Scheme for Its Effective Employment, *J. Oral Surg.* 25: 397, 1967.
8. Obwegeser H. Surgical preparation of the maxilla for prosthesis. *J Oral SurgAnesthHosp Dent Serv.* 1964;22:127–134.
9. George A. Wessberg, Stephen A. Schendel And Bruce N. Epker: Modified maxillary submucosal vestibuloplasty. *Int. J. Oral Surg.* 1980: 9: 74-78
10. ALLAN C. MOON, DDS: Transpositional Flap Vestibuloplasty of the Maxilla. *J Oral MaxillofacSurg* 41:272-273. 1993.

11. P. Egyedi: Deepening of the buccal sulcus by vestibuloplasty with secondary epithelialization. Revised technique. *Australian Dental Journal*, vol 13 no 6, December, 1968.
12. Richard B. Liposky, Maxillary osteotomy and vestibuloplasty for the

correction of maxillary anterior atrophy: Preliminary report. *OOO* Volume 48, Number 2, August, 1979.

ACKNOWLEDGMENT: The author is indebted to Dr. Mayuri Sanap for her line drawings.

**FIGURES:**

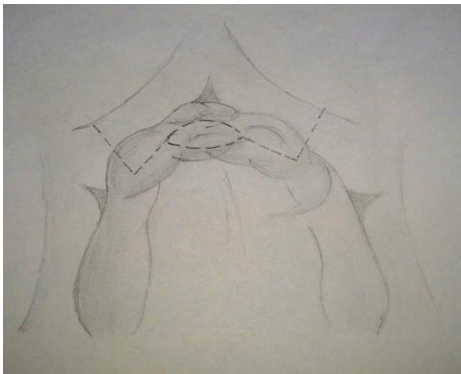

Figure 1: Incision Outline

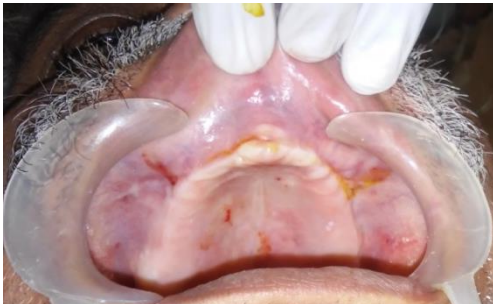

Figure 2: Pre Op Vestibular Depth

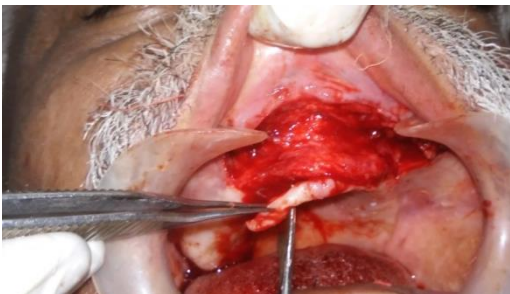


Figure 3: Excision of Flabby Tissue and Sulcular Extension

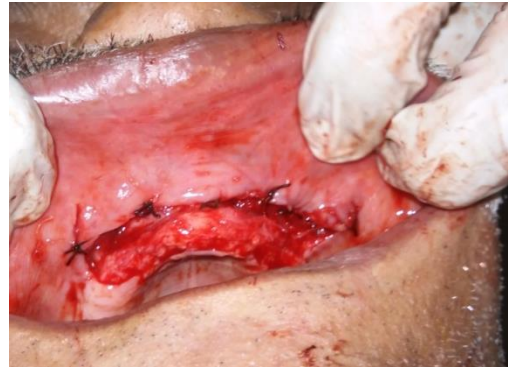

Figure 4: Immediate Post Op

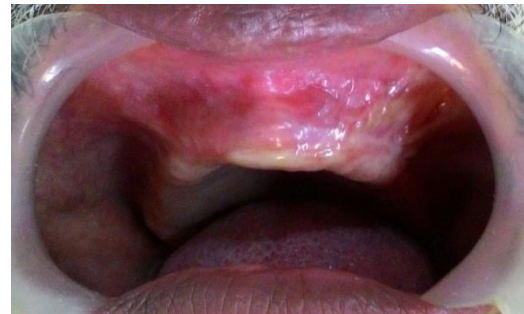

Figure 5: 1 Month Post Op

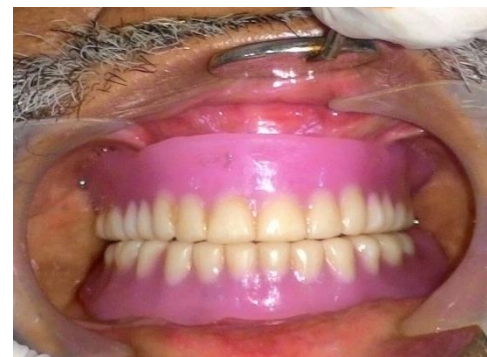

Figure 6: After Prosthetic Rehabilitation