

# Complex Regional Pain Syndrome and Lyme Borreliosis: Two Different Diseases?

B. Šibanc, G. Lešničar

## Abstract

Complex regional pain syndrome (CRPS) is a frequent complication appearing as pain of unexplained pathogenesis. Its association with Lyme borreliosis (LB) is fairly rare. In the presented clinical case, clinical features as well as the findings of radiological, radionuclide, neurophysiological and serological investigations pointed to an association between the two conditions. The patient fulfilled the criteria for both diagnoses, i.e. CRPS and LB. The subsequent antibiotic therapy resulted in a complete remission of both clinical entities.

Infection 2002; 30: 396–399  
DOI 10.1007/s15010-002-2006-4

## Introduction

Lyme borreliosis (LB) is a zoonosis transmitted to man by ticks. It can affect several organ systems. LB is caused by *Borrelia burgdorferi*. The course of the disease is variable and patients rarely present with all the associated symptoms. Complex regional pain syndrome (CRPS) is a frequent complication where persistent pain of either known or unknown etiology tends to increase rather than subside and is accompanied with the signs of inflammation and local vegetative dystonia.

The diagnosis of LB is based on epidemiological data, clinical features and microbiological findings. Some believe that the diagnosis of LB is often precipitated [1]. However, the associations of patients with LB call attention to rare manifestations of LB which often pass unrecognized and point out the need for treatment [2].

Generally, the typical forms of LB do not pose particular diagnostic problems. However, *B. burgdorferi* can also infect organs and tissues in which it is detected and isolated less frequently. The clinical features have not been fully explained yet and new clinical peculiarities of this disease are still being discovered.

This report presents a rare manifestation of *B. burgdorferi* infection in a patient who presented with CRPS of the left lower limb. There are three similar cases reported in the literature, which point out the possibility of such a compli-

cation, however, the results of antibiotic therapy differed [3–5]. The borreliosis-associated etiology of CRPS in our patient was confirmed by the positive history of untreated erythema migrans (EM), oligoarthritis, positive serological tests for *B. burgdorferi* with seroconversion, detection of the *B. burgdorferi* genome in urine by PCR as well as by the response to antibiotic therapy.

## Case Report

In autumn 1997, a 46-year-old patient presented with increasing pain in his left foot, which soon also became swollen. The skin of the distal part of the left shank and the upper part of the foot were slightly erythematous, glossy and dry. Edema of the left shank and leg occurred and in the following weeks the pain intensified to the point that the patient's left leg became dysfunctional. Even the slightest contact with the skin of the affected area caused the patient unbearable pain. The patient denied having suffered any former injury to his leg. Otherwise, he did not have fever and vital signs were within normal limits.

X-ray and CT scan of the left foot showed a patchy osteoporosis. Using <sup>99m</sup>Tc-methylenediphosphonate (DPD), a target static scintiscan of foot bones showed evidence of a large uptake of radionuclide-labeled medium in the region of the left foot, while the rest of the skeleton was without evidence of disease. There were signs of hyperemia seen on a dynamic bone scintiscan of the affected area. A scintiscan of both feet using labeled granulocytes also imaged a large uptake of labeled leukocytes in the area of the left foot which included the bone and partly the soft tissue (Figure 1a).

Thus, all the criteria for the diagnosis of CRPS of unknown etiology were fulfilled. Eight-month symptomatic treatment with analgesia, psychotherapy for reestablishment of psychic balance, anti-pain electrostimulation, magnetotherapy, laser therapy, desensitization with manual massage, kryotherapy, calcitonin, limb elevation and active physical exercises proved unsuccessful.

Later on the patient remembered having had a tick on the upper side of his left foot in spring 1997. One week after the tick bite he developed a 5 cm large circular erythema (EM) in the affected

---

**B. Šibanc** (corresponding author), **G. Lešničar**

Dept. of Infectious Diseases and Febrile Conditions, General Hospital Celje, Oblakova 5, SI-3000 Celje, Slovenia; Phone: (+386/4) 1672110, Fax: -4233752, e-mail: branko.sibanc@guest.arnes.si

Received: January 10, 2000 • Revision accepted: August 8, 2002

site, which vanished spontaneously within the following 2 weeks. Not having had any other complaints, he did not consult a doctor and forgot about the tick bite. In March 1998 he was referred to an infectologist owing to suspected LB.

In the course of directed anamnesis the patient further mentioned having pains in the muscles and that his left knee had become swollen and very painful 1 month ago; the swelling subdued spontaneously within the following 2 weeks. He also claimed being constantly tired and depressed as well as having spells of dizziness and headache.

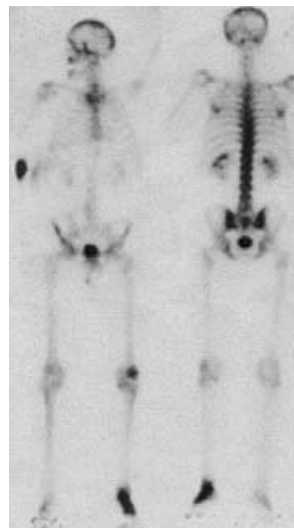
On examination the patient presented with thickened upper part of his left foot which was diffusely painful to palpation. His left ankle was slightly swollen, while the skin of the distal part of the shank and foot was shiny, smooth and slightly pale but also partly livid.

The circumference of the left shank was 2.5 cm smaller than that of the right one. Crude muscular power of left foot flexors and extensors was considerably diminished. The patellar and Achilles myotactic reflexes were symmetrical. Sympathetic skin response (SSR) of the right foot was within the limits of normal amplitudes and latencies, whereas in the left foot SSR could not be evoked with either mechanical or electric stimulation (Figure 2a). The SSR result was consistent with a damage of the sudomotor reflex arch.

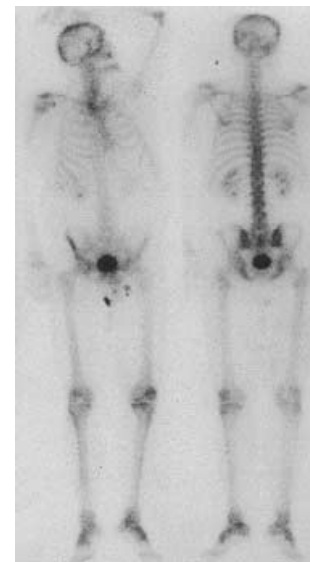
The findings of serological tests for *B. burgdorferi* are presented in table 1. Rheumatoid factor (RF) was positive. The results of extended hematological and biochemical investigations were within normal limits. Serological tests for venereal disease, *Treponema pallidum* hemagglutination test and Epstein-Barr virus were negative.

In April 1998 the patient was admitted to the Department of Infectious Diseases and Febrile Conditions, General Hospital Celje, Slovenia, and had lumbar puncture performed. The findings of CSF examination were normal with negative results for *B. burgdorferi* IgG antibody by IFT, *B. burgdorferi* antibody index (Dako Diagnostics Ltd, Mississauga, Ontario, Canada) and *B. burgdorferi* culture. At the patient's request, skin and bone biopsies were not performed. The results of bone densitometry of the left heel showed a 35% reduction in the bone mass.

The patient received a 4-week treatment with ceftriaxone and he was able to stand on his foot without support 2 weeks after commencing therapy. By the end of treatment period he could walk independently, the skin of the affected foot had resumed its normal appearance and myalgia had vanished completely; the patient was no longer depressed and his headaches did not recur. According to subjective evaluation, the pain was reduced by 75% and therefore the treatment was continued with doxycycline for a further 3 weeks.



**Figure 1a.** Large uptake of labeled leukocytes in the area of the left foot which included the bone and partly the soft tissue.



**Figure 1b.** Scintiscan with labeled granulocytes was within normal limits 6 months after antimicrobial treatment.

On a follow-up examination in June 1998 the patient mentioned having slight pain in the left foot on walking; the difference in the circumference of both shanks had decreased to 1.5 cm. As he complained of the recurrence of depression and myalgia after the cessation of antibiotic therapy, he was prescribed depo-penicillin which he was receiving for 3 months at regular intervals.

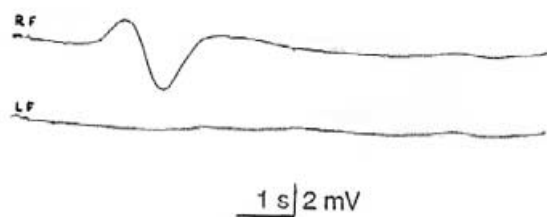
In October 1998 bone densitometry and scintiscan of the feet were repeated. The dynamic scintiscan with DPD showed even blood supply in both feet, while the static scintiscan evidenced a slight difference in the uptake of radionuclide, which was 70% less than on the first measurement. Scintiscan with labeled granulocytes was within normal limits (Figure 1b). Bone densitometry showed only a slight deviation from normal values. While SSR of the left foot could now be evoked, the latency and amplitude of SSR were still below average. Serological tests for *B. burgdorferi* using three methods (ELISA, IFT, Western blot) showed disappearance of IgM, while the IgG titer increased (Table 1).

In December 1998 the patient was without clinical evidence of disease. An X-ray of the left foot imaged signs of remineralization, while the patchy osteoporosis had disappeared. SSR of the feet was symmetrical, the amplitudes and latencies being within normal limits (Figure 2b).

The course of the disease is still being followed up. It has been more than 1 year since the patient resumed his job and has been free of any psychical complaints and arthritic pain. The left shank is still 1 cm thinner than the right (healthy) one, the force of the flexors and extensors of the feet is adequate and symmetrical. The skin is adequately supplied with blood and warm, perspiration is symmetrical and sufficient. *B. burgdorferi*-specific IgM is negative, while the *B. burgdorferi*-specific IgG titer is decreasing (Table 1). RF has become negative.

**Table 1**  
**Results of serological and PCR tests for *B. burgdorferi* before and after antimicrobial treatment.**

	Before treatment February 1998	After treatment October 1998	May 2000
ELISA	IgM positive IgG positive	IgM negative IgG positive	IgM negative IgG positive
IFT	IgM 1:256 IgG 1:256	IgM negative IgG 1:512	IgM negative IgG 1:128
Western blot	IgM positive IgG positive	IgM negative IgG positive	IgM negative IgG positive
PCR	(urine) positive	(urine) negative	Not performed

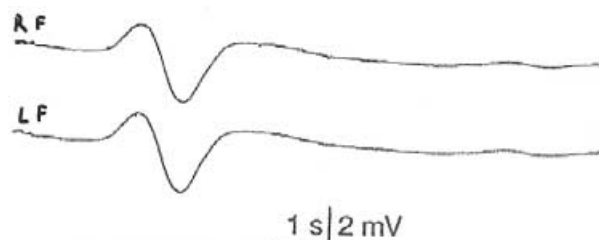


**Figure 2a.** Before antimicrobial treatment the sympathetic skin response of left foot (LF) could not be evoked, while sympathetic skin response (SSR) of right foot (RF) was normal in amplitude and latency.

### Discussion

CRPS is a relatively frequent and unexplained pain syndrome, which is described under several different names in the literature: Sudeck dystrophy, reflex dystrophy, algodystrophy, causalgia, painful osteoporosis and the shoulder-hand syndrome. [6]. CRPS is characterized by considerable pain (allodynia, hyperalgesia), edema, trophic changes of the skin and muscles and sudomotor disorders. The diagnosis of CRPS is based on the above-mentioned clinical signs; it is confirmed by radiological evidence of the patchy osteoporosis, diphosphonate uptake and the absence of sympathetic skin response. Our patient met all the criteria for CRPS diagnosis. Although *B. burgdorferi* could not be isolated in this case, there were enough causative factors identified during the clinical course that were consistent with *B. burgdorferi* infection. The clinical picture developed a few months after a tick bite, and moreover, it occurred at the very site where the tick had attached itself to the skin and where a characteristic EM subsequently developed which was not treated and disappeared spontaneously within the following 2 weeks. It could be presumed that the bacterium invaded the organism locally – in the subcutis and/or bone, where it caused a chronic infection associated with the described clinical symptoms. At that, the patient's immune response was adequate since the presence of IgM and IgG *B. burgdorferi* antibodies could be detected in the initial stage of the disease. A prolonged antibiotic therapy resulted in a clinical remission, disappearance of IgM and reduction in IgG titer. It is also conceivable that we were dealing with two distinct diseases, months apart. Cellulitis and osteomyelitis were practically excluded with long persistence of disease and absence of fever, leukocytosis or elevated erythrocyte sedimentation rate.

It should be mentioned that we were the first to prove a damage of sudomotor fibers in a patient with CRPS using the neurophysiological method of SSR detection. SSR represents a momentary alteration in the electric potential of the skin of the palms and soles. It occurs as a result of the changed electric responsiveness of the skin caused by the sympathetic activity of the autonomous nervous system. Thus, it actually reflects the function of non-myelinated nervous fibers which control the function of sweat glands. SSR



**Figure 2b.** Six months after antimicrobial treatment the SSR of the left foot (LF) could be evoked and is symmetrical with right one (RF).

is a phenomenon that can be repeated and is present in all healthy persons. When SSR cannot be evoked, this should always be regarded as a sign of some pathological condition [7].

In our patient the use of SSR helped us to prove the sudomotor nervous tissue damage. In the most developed stage of the disease, SSR in the affected limb could not be evoked. Following antibiotic therapy, a retarded and decreased SSR reaction was noted, which was restored completely during the remission phase (Figures 2a and 2b).

There are theories that CRPS is attributable to the release of pain (triggering) substances and an excessive inflammatory response. In our patient the latter seems quite likely. The presented case points out the close relation between CRPS and a borreliosis. *Bruckbauer et al.* [5] described the case of a 72-year-old patient with generalized borreliosis, who developed EM and radiculitis. After an antibiotic treatment the symptoms subdued, however, 1 month later the patient presented with a clinical picture of CRPS which failed to respond to antibiotic therapy. Therefore, the author suspected that the occurrence of CRPS was due to autoimmune mechanisms rather than due to the local infection with a spirochete [5].

In contrast to *Bruckbauer et al.* [5], we believe that the persistent local presence of the bacteria in the tissue is the most likely cause of the mentioned condition. Our theory is supported by the success of antibiotic therapy and the remission achieved. The prior conservative treatment that preceded the antibiotic therapy proved completely ineffective. Nevertheless, *B. burgdorferi* was successfully isolated from the cartilage and bone in Lyme arthritis already in 1986 [8].

Among the possible mechanisms of CRPS occurrence, the so-called post-arthritis syndrome should also be considered. Thus, in our case this factor could not be definitely excluded since in the course of the disease the patient developed a mild synovitis of the ankle and knee joints. Nevertheless, we believe that this cannot be regarded as the main (causative) factor as the most prominent pathological changes evidenced by the imaging methods used were found outside the joint and not within the synovial membrane.

Reports on CRPS as a complication of Lyme borreliosis are rare. Neumann et al. [4] reported four patients, three of whom had a cutaneous form of borreliosis. All four patients also had positive serological tests for *B. burgdorferi* and responded to antibiotic therapy. Kohler and Thoden [3] described three patients with CRPS, which developed in association with neuroborreliosis. All the cases were seropositive. The response of the disease to antibiotic treatment differed [3].

In our patient the disease was obviously associated with a primary *B. burgdorferi* infection and EM occurrence, followed 3 months later by CRPS with simultaneous evidence of the characteristic serological dynamics of *B. burgdorferi* and a clear clinical and laboratory remission of the disease after antibiotic therapy. In addition, the course of the disease was documented by radiological, nuclear medical and neurophysiological findings.

Although the presented clinical picture is very rare, the medical profession should be aware of it. LB is actually a multifaceted disease, and some of its manifestations have not been recognized yet. Despite the frequent abuse of diagnosis, it should be taken into account that LB may sometimes cause rare conditions that are curable. Generally, CRPS is a chronic disease with poor treatment results. On the other hand, the disease that occurs in association with LB can be managed by antibiotic therapy.

## References

1. Svenungsson B, Lindh G: Lyme borreliosis - an overdiagnosed disease? *Infection* 1997; 25: 140–142.
2. Lang D, Lant DV, Territo J: Coping with Lyme disease: a practical guide to dealing with diagnosis and treatment. Henry Holt, New York 1997: pp 1–272.
3. Kohler J, Thoden U: Schmerzsyndrome bei Zeckenübertragenen Borrelieninfektionen des Nervensystems. *Der Schmerz* 1987; 1: 107–113.
4. Neumann RA, Aberer E, Stanek G: Evidence for spirochetal origin of Sudeck's atrophy (algodystrophy, reflex sympathetic dystrophy). *Arch Orthop Trauma Surg* 1989; 108: 314–316.
5. Bruckbauer HR, Preac Mursic V, Herzer P, Hofmann H: Sudeck's atrophy in Lyme borreliosis. *Infection* 1997; 25: 372–376.
6. Höfferle Felc A: Morbus Sudeck ali kompleksni regionalni bolečinski sindrom. *Med Razgl* 2000; 39: 71–78.
7. Šibanc B: Elektrofiziološke značilnosti simpatičnega kožnega odziva pri zdravih ljudeh. *Zdrav Vestn* 1992; 62: 555–559.
8. Jacobs JC, Stevens M, Duray PH: Lyme disease simulating septic arthritis. *JAMA* 1986; 256: 1138–1139.