ANATOMY OF THE HAND

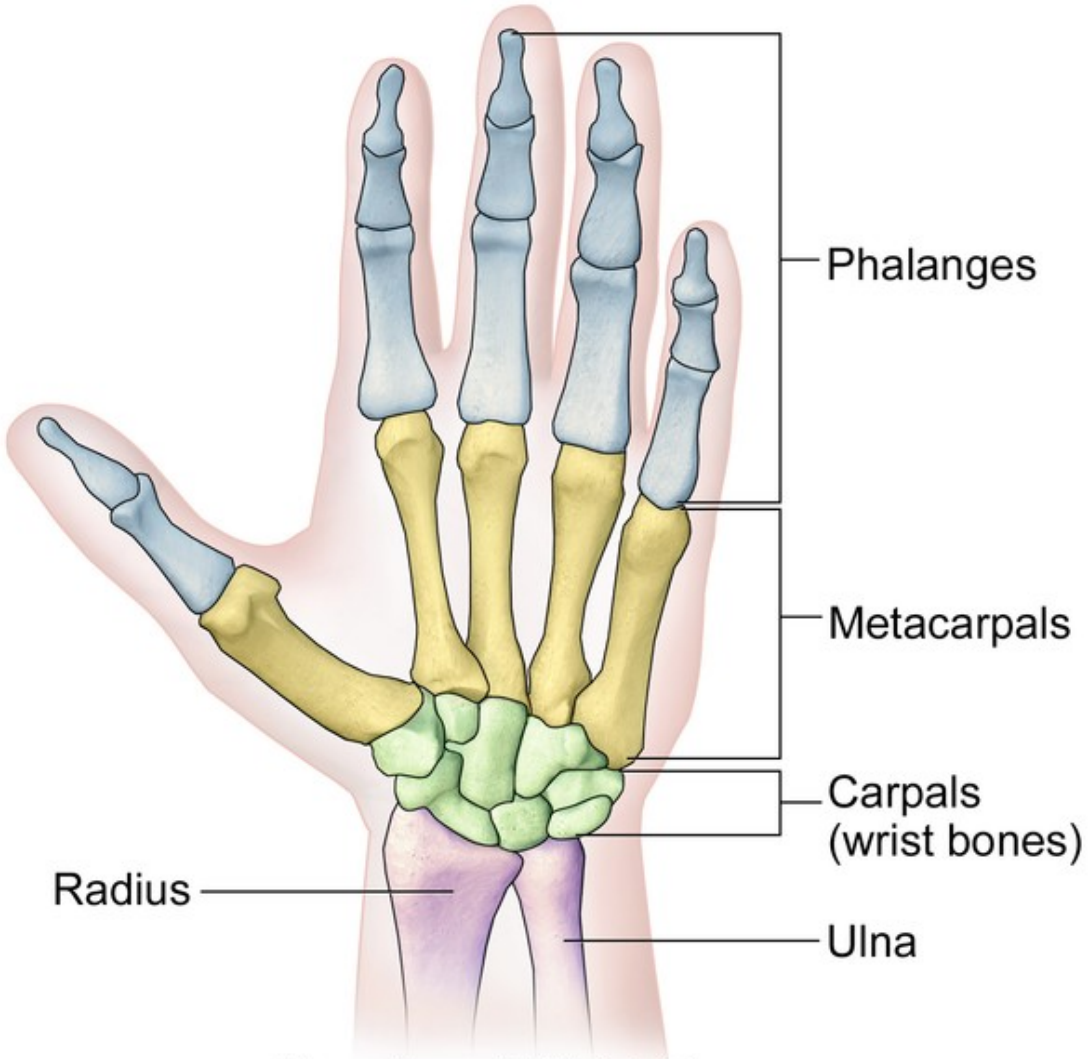
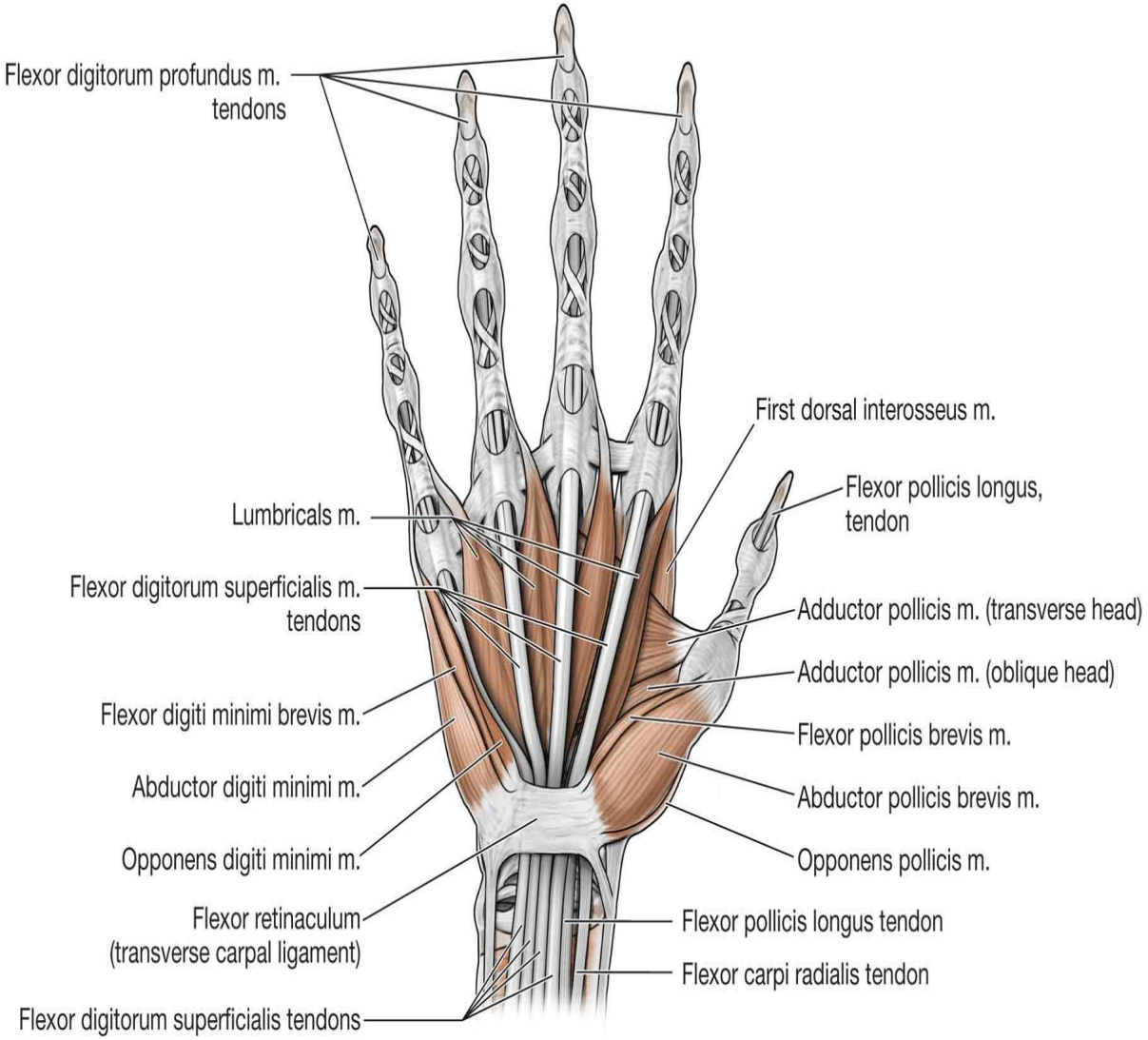
Hand and Wrist Bones