

COMPLEX ANTERIOR ASTHETIC REHABILITATION- AN INTERDISCIPLINARY APPROACH

Prajakta Khadse¹, Mrunal B. Doiphode², Abhay Kamra³, Kishor M. Mahale⁴, Babita Yeshwante⁵, Nazish Baig⁶

1.P.G. Student, Dept. of Conservative Dentistry and Endodontics, CSMSS Dental College & Hospital, Kanchanwadi, Aurangabad

2.P.G. student, Dept. of Prosthodontics, CSMSS Dental College & Hospital, Kanchanwadi, Aurangabad.

3.Professor & Head of Department, Dept. of Conservative Dentistry and Endodontics, CSMSS Dental College & Hospital, Kanchanwadi, Aurangabad.

4.Professor & Head of Department, Dept. of Prosthodontics, Govt. Dental College & Hospital, Mumbai.

5.Professor & Head of Department, , Dept. of Prosthodontics, CSMSS Dental College & Hospital, Kanchanwadi, Aurangabad.

6.Professor, , Dept. of Prosthodontics, CSMSS Dental College & Hospital, Kanchanwadi, Aurangabad.

ABSTRACT:

Complete rehabilitation of smile of a patient with multiple esthetic challenges involves a multidisciplinary approach and presents a considerable clinical challenge. The interactions between new restorative materials and techniques allow the reproduction of dental structures, restoring form and function in such a way that restorative procedures become imperceptible. The completion of root development and closure of the apex occurs up to 3 years after the eruption of the tooth. Traumatic dental injuries during this period result in endodontic complications. Unfavorable relationships between the residual edentulous ridge, pontic, and gingival papilla may compromise the definitive result of a restoration. Different procedures have been described and developed to improve the relationship between esthetics and functionally acceptable fixed partial dentures. A modified design for ovate pontics is proposed to achieve the esthetic, functional, and hygienic requirements for fixed partial dentures. The purpose of this case is to report successful apexification of non-vital central incisor with open apex using calcium hydroxide and biodentine, followed by an effective and easy technique of tissue sculpturing and long term provisionalization for fabricating modified ovate pontics, for the purpose of achieving optimal esthetics.

Key words: Biodentine, Traumatic dental injuries, Apexification, Modified ovate pontic, anterior pontic, aesthetics, ovate pontic, tissue sculpturing

INTRODUCTION:

Complex treatment needs can necessitate oral rehabilitation of patients. Often these patients will require a multi-disciplinary approach to correct problems. To return the patient to optimal function, regain

normal form and address possible concerns such as esthetics, an integrated approach that involves various disciplines needs to be taken.

The biggest endodontic challenge while treating teeth with associated open apices

is obtaining an apical seal. The main objective of treatment for these teeth is apexification. Apexification is defined as “a method to induce a calcified barrier in a root with an open apex or the continued apical development of an incomplete root in teeth with necrotic pulp.”

Calcium hydroxide has been the first choice of material for apexification,^[1] with repeated changes over the course of 5 to 20 months to induce the formation of a calcific barrier.^[2] The unpredictable and often lengthy course of this treatment modality presents challenges, including the vulnerability of the temporary coronal restoration to reinfection.^[3] moreover, the treatment requires a high level of patient compliance. For these reasons, one visit apexification has been suggested.^[4]

In recent times, synthetic apical barriers have popularized as alternatives to the traditional calcium hydroxide apexification method.^[5] Mineral trioxide aggregate (MTA) has successfully evolved as a material of choice for this procedure. MTA creates an apical plug at the root end and helps to prevent the extrusion of the obturating materials.^[6] A novel material biodentine was announced in September of 2010 and made available in January of 2011. Biodentine is similar to MTA in basic composition and can serve as its substitute.^[7]

The extraction of a tooth in the anterior region often involves simultaneous local alveolar ridge deficiencies. In the past, primarily prosthodontic methods were used to compensate for these defects. With advances in periodontology, a

number of techniques have been developed to preserve the alveolar ridge and surgically rebuild defective sites. Today, these techniques are also used in crown-and bridge prosthetics for ridge preservation before or directly after extraction, as well as for buccal crown-lengthening procedures and ridge augmentation procedures, leading to an increased frequency of satisfying ridge contours.^[8]

The ovate pontic was first described by **Dewey and Zugsmith** in 1933, and this design was intended to form a concave soft tissue outline in the site of the alveolar ridge mucosa and allows for an excellent esthetic outcome.^[9] But ovate pontic requires adequate faciolingual thickness to create an emergence profile. At times surgical augmentation of the ridge is also required.

To overcome the problems encountered with the ovate pontic, a modified ovate pontic was introduced by **Liu** in 2003. The modification of the ovate pontic involves moving the height of contour at the tissue surface from the center of the base to a more labial position. The modified ovate pontic does not require as much faciolingual thickness to create an emergence profile. It is much easier to clean compared with the ovate pontic owing to the less convex design. Its major advantage over the ovate type is that often there is little or no need for surgical augmentation of the ridge. The height of contour at the tissue surface of the pontic is 1 to 1.5 mm apical and palatal to the labial gingival margin. Dental floss can be

used to push the labial gingival margin away and cleanse the tissue surface without any difficulty, in contrast with other pontic types. The labial gingival margin rebounds after the dental floss is removed. Due to the specific design of this pontic, the illusions of a free gingival margin and papilla are created, and dark interproximal spaces, also known as "black triangles," are minimized. However, the modified ovate pontic may leave a shadow in the apical area of the tooth-gingival margin if Class I or Class II ridge defects and a high smile line are present.^[10] Hence, the modified ovate pontic offers outstanding results with regards to esthetics, function, and phonetics, and also, risk of food impaction is minimal. (Figure 1)

It appears that the presence of adjacent teeth and the size of gingival embrasure formed by the teeth is responsible for the presence and height of the papilla; a deeper sulcus and overall increased height of tissue above bone will exist on the interproximal (5mm) as compared to facial aspect (3mm). After extraction of a tooth, a confined embrasure no longer remains, and the interdental papilla receded to the same 3mm level above bone as exists facially, and gingival scallop flattens, which results in compromised gingival esthetics. (Figure 2) ^[11] One solution to this is to fabricate a long term provisional restoration with the same embrasure volume as existed prior to extraction, with the application of controlled pressure in an apical direction, and the papilla and surrounding gingival

tissues will be subsequently permitted to reform.

Several authors demonstrated that soft tissue under pontics is associated with clinical signs and symptoms of inflammation such as edema, swelling, and histological changes. Contrary to these findings, *Silness et al* and *Tolboe et al* reported that clinically healthy conditions can be established at pontic sites if appropriate plaque control is performed.^[12] *Jaques et al* reported that a well-controlled hyperpressure applied with a convex and highly polished pontic, associated with rigid plaque control, resulted in only a thinning of the epithelium and shortening of rete pegs, without inflammation.^[13]

The article highlights an interdisciplinary approach (Endodontic – Prosthodontic) for a successful rehabilitation of smile of a patient with an esthetic challenge. In this case, we report successful apexification of non-vital central incisor with open apex using calcium hydroxide and biodentine, followed by an effective and easy technique of tissue sculpturing and long term provisionalization for fabricating modified ovate pontics.

CASE DETAIL:

A 49-year-old male patient was reported to the Department of Conservative Dentistry and Endodontics with the chief complaint mobile and discolored upper front teeth with H/O trauma 10 years back. (Figure 3) The tooth in question did not respond to both electric and heat pulp tests. The pre-operative radiograph

revealed a large blunderbuss canal for upper central incisors. (Figure 4) Clinical examination revealed with deep cervical abrasion with discoloured left maxillary central incisor and grade III mobility with right maxillary central incisor and discoloured right maxillary lateral incisor. (Figure 3) Due to the poor prognosis and diminished bone support with respect to right maxillary central incisor, extraction of the tooth was advised. Apexification with biodentine was planned for the other maxillary central incisor and conventional endodontic therapy for the lateral incisor.

Labial abrasion was sealed with light cure composite restoration and standardized access cavities were prepared and working length was determined. Biomechanical preparation was carried out using 80-size k-file in circumferential manner. Root canal was disinfected using 1% NaOCl and normal saline. Calcium hydroxide was placed as an intracanal medicament and patient was recalled after a week.

At 1-week recall, canal was irrigated using 1% NaOCl and normal saline. The canals were dried using paper points and biodentine was mixed according to manufacturer's protocol and it was placed with a plugger until a thickness of 5 mm. A sterile cotton pellet was placed in the canal and the cavity was sealed using MD-Temp for 30 min and the root canal was obturated with thermoplasticized gutta percha technique. Conventional root canal cleaning and shaping was done for the lateral incisor and canal was obturated with lateral condensation

technique. (Figure 5) The access cavity was then sealed with the composite restoration and the patient was referred to Department of Prosthodontics for full coverage restoration.

When the patient reported to the Department of Prosthodontics, the chief complaint was that of discolored upper front teeth and a missing tooth. Clinical examination revealed a missing right central incisor with adjacent discolored teeth with composite restorations. The adjacent discolored teeth were non tender to percussion and non mobile. The surrounding gingiva was firm and healthy. The oral hygiene of the patient was good. (Figure 6)

The treatment plan was to fabricate a conventional porcelain-fused-to-metal fixed partial denture using a modified ovate pontic.

Scaling and root planing were done before starting the prosthodontic procedure and a diagnostic impression of the abutments upper and lower arches were made. A wax diagnostic mock up was made on this diagnostic cast using tooth- colored wax. A putty impression (Speedex C-Silicone Impression Material Coltène/Whaledent) of this diagnostic mock up was obtained.

Tooth preparation was done on both the abutments adjacent to the tooth to be extracted. After following all aseptic protocol and administering local anaesthesia by local infiltration with 2% lidocaine containing 1:80,000 epinephrine (Lignox 2% Adr, Indoco. Remedies, Goa, India). Gingivoplasty was also performed

at the same time with a foot ball shaped diamond according to the procedure as described by *Liu*.^[10] A 30° to 45° gingivoplasty was made in the labial edentulous area and extended apically and palatally 1 to 1.5 mm from labial gingival margin. The lingual edentulous area was prepared to create a shallow concavity.(Figure 7)

An irreversible hydrocolloid (Tropicalgin; Zhermack, Badia Polesine, Italy) impression was made of the upper arch, and the impression was poured in die stone (Ultrarock, Kalabhai Karson Pvt. Ltd., Mumbai, India)

With the help of an acrylic resin trimming bur the pontic site was minimally prepared so that the final emergence was in harmony with the emergence profile of the natural adjacent teeth. The stone preparations and ovate pontic site was coated with separating media. Autopolymerising provisional crown material (DPI™ Self – Cure. Tooth Molding Powder, Dental Products of India) was mixed and poured it in the putty impression of the diagnostic mock-up obtained before. Orient it on the stone cast, and tie the cast and impression with rubber bands. The provisional restoration was trimmed, finished and polished. To achieve the objective of optimal soft-tissue levels, the gingival and subgingival forms of the provisional restoration were subtly contoured. The provisional restoration was seated to observe the adaptation of the surrounding gingiva. The necessary additions or subtractions were performed on the provisional

restorations. Thin diamond disks were used to delineate proximal contact areas to create the perception of separate teeth. This contouring process was continued until the soft-tissue profile of the available gingival tissue was optimized. The provisional restoration was adjusted for correct contour, emergence profile and occlusion, and final finishing and polishing was done. At this stage, the surface of the provisionals was not kept too convex, as the gingival tissues had not undergone epithelization yet. (Figure 8A)

The provisional restoration was cemented with a non-eugenol temporary cements cement (TempLute, PrimeDent). Care was taken to ensure that dental floss could pass between the pontic and the abuting tissue. The patient was given oral hygiene instructions, and the use of mouthwash and dental floss was prescribed. (Figure 9)

The patient was kept on a regular follow up at 15 days, 30 days, 45 days and 60 days after soft tissue contouring. (Figure 10 A, B, C & D) The pressure points were relieved at each appointment and the pontic site was checked for proper healing and healthy attached gingiva. At every 15 days interval, 1-mm increment of tooth-colored acrylic was added to the tissue surface of the ovate pontic, trimmed, finished and polished to a convex surface. (Figure 8B) The convex design of the pontic was intended to form a concave soft tissue outline in the site of the alveolar ridge. After the modifications, the provisional restoration was reseated. Some blanching of the gingiva occurred,

which is acceptable and expected upon initial seating of the provisional prosthesis. This procedure was repeated every 15 days. Over a period of 2 months, the provisional restoration was observed and further modified to fine-tune the contours.

At 60 days after soft tissue contouring, the vertical shaping of the pseudopapillae had been successfully completed, with a distally displaced apex and papilla formation. (Figure 10D) At this stage, it was decided to finalize the restoration. Gingival retraction cord (SURE-Cord Knitted Retraction Cord #000, Sure Endo products, South Korea) was placed in the sulcus, and final tooth preparations and finishing was performed on tooth 12 and 21. (Figure 11) Because of the chances of tissue rebound, final impression was made immediately after the removal of the provisional restoration with vinyl polysiloxane impression material (Affinis; Coltène/Whaledent, Inc, Cuyahoga Falls, Ohio)

Once the soft tissue reached full maturity and the dentist and patient were satisfied with the aesthetic results, the approved provisional restoration provided an invaluable script for the laboratory technician to follow. The laboratory was provided with a cast of the provisional restoration.

The trial of the metal framework was done (Figure 12), followed by shade selection, followed by bisque trial and required modifications, and finally the porcelain-fused-to-metal bridge was cemented using Glass Ionomer Type I

luting cement (GC Gold Label Luting and Lining Cement, GC Corp., Tokyo, Japan). The ovate pontic atraumatically seated in its sulcus already established by the provisional restoration. (Figure 14 and 15) At the time of bisque trial of the restoration, care was taken that the tissue surface of ovate pontic final prosthesis was convex, smooth, polished and highly glazed. (Figure 13)

DISCUSSION:

The artificial apical barrier technique is a contemporary approach for managing open apices cases. This technique uses a barrier material that is placed at the apex facilitating obturation by confining it within the canal.

Recently introduced biodentine is similar to MTA in its basic composition with the addition of setting accelerators which is calcium chloride not only results in fast setting but also improves the handling properties and strength. Calcium silicate cements have setting times in the range of several hours. Decreasing the setting time was achieved by a combination of different effects. First particle size greatly influences the setting time, since the higher the specific surface, the shorter the setting. Also, adding calcium chloride to the liquid component accelerates the system. Finally, the decrease of the liquid content in the system decreases the setting time to harden within 9-12 min. Biodentine is superior to MTA like its consistency is better suited to the clinical use, ensures a better handling and safety, does not require a two-step obturation

and as the setting is faster, there is a lower risk of bacterial contamination.^[7]

Apart from functional and hygienic requirements, the pontics of fixed partial dentures in anterior segment have to satisfy aesthetic function also. Earlier, the ridge lap pontic was used in the aesthetic zone, but due to its concave inferior surface oral hygiene was difficult to accomplish. For maintenance of good oral hygiene sanitary pontic and the modified ridge lap pontic were developed but they did not satisfy the aesthetic requirements. Later on, the ovate pontic was developed which had good emergence profile as compared to all previously discussed pontics. Its convex design was intended to fabricate a concave soft tissue outline in the edentulous ridge mucosa.^[8] Here a modified ovate pontic was prepared which had the height of the contour to a more labial position as compared to an ovate pontic for which the height of the contour was at the centre of the edentulous ridge labiolingually.

This article describes a technique for preparation of the edentulous site of an anterior tooth such that it provided a good emergence profile. An acrylic resin provisional fixed partial denture with modified ovate pontic design was used for this purpose. The technique was beneficial to the patient because esthetics was re-established during the period of temporization comfort, phonetics and aesthetics were verified. Sufficient time for tissue healing was provided.

The modified ovate pontic was an improvement over the conventional ovate pontic as it had better cleansing ability and less soft tissue-contact and black triangles were eliminated. It does not require as much faciolingual thickness to create an emergence profile as ovate pontic, and requires little or no surgical augmentation of the ridge.^[10] The drawback of this mode of treatment is that more conservative treatment options like implant, fibre reinforced composites or Maryland bridges could be followed. The period of temporization was also prolonged.

CONCLUSION:

The necessity for an interdisciplinary approach to treatments of routine dental problems has been recognized for a long time. Restoring a missing, diseased or discoloured tooth in the anterior quadrant is a major esthetic challenge. In the present case, a P.G. student in Endodontics, and a P.G. student in Prosthodontics participated in the dental management of a patient with a mobile and discolored incisors with H/O trauma 10 years back. It is clear that without such cooperative action the prognosis would not have been good. In this case report the pontic design which has been chosen was a modification over the conventional ovate pontic. Because of its functional and aesthetic advantages, this pontic design can be effectively used to achieve excellent aesthetics.

REFERENCES:

1. Rafter M. Apexification: A review. *Dental Traumatology* 2005;21:1-8.
2. Sheehy EC, Roberts GJ. Use of calcium hydroxide for apical barrier formation and healing in nonvital immature permanent teeth: A review. *British Dental Journal* 1997;183:241-46.
3. Magura ME, Kafrawy AH, Brown CE Jr, Newton C. Human saliva coronal microleakage in obturated root canals: An in vitro study. *Journal of Endodontics* 1993;25:197-205.
4. Morse DR, O'Larnic J, Yesilsoy C. Apexification: Review of the literature. *Quintessence International* 1990;21:589-98.
5. Holden DT, Schwartz SA, Kirkpatrick TC, Schindler WG. Clinical outcomes of artificial root-end barriers with mineral trioxide aggregate in teeth with immature apices. *J Endod* 2008;34:812-7.
6. Giuliani V, Baccetti T, Pace R, Pagavino G. The use of MTA in teeth with necrotic pulps and open apices. *Dent Traumatol* 2002;18:217-21.
7. Pawar AM, Kokate SR, Shah RA. Management of a large periapical lesion using Biodentine TM as retrograde restoration with eighteen months evident follow up. *J Conserv Dent* 2013;16:573-5.
8. Edelhoff D, Spiekermann H, Yildirim M (2002) A review of esthetic pontic design options. *Quintessence Int* 33(10):736–746
9. Dylina TJ (1999) Contour determination for ovate pontics. *J Prosthet Dent* 82(2):136–142.
10. Chiun-lin steven liu. Use of a Modified Ovate Pontic in Areas of Ridge Defects: A Report of Two Cases. *J Esthet Restor Dent* 16:273-283, 2004
11. Spear FM. Maintenance of the interdental papilla following anterior tooth removal. *Pract Periodont Aesthet Dent* 1999; 11(1): 21-28
12. Kim TH, Domenico Cascione D., and Knezevic A. Simulated tissue using a unique pontic design: A clinical report. *J Prosthet Dent* 2009;102:205-210
13. Jacques LB, Coelho AB, Hollweg H, Conti PC (1999) Tissue sculpturing: an alternative method for improving esthetics of anterior fixed prosthodontics. *J Prosthet Dent* 81(5):630–633

FIGURES:

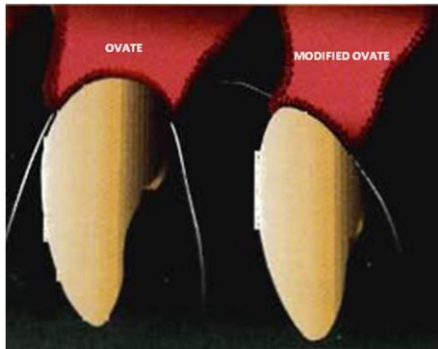


Figure 1. Ovate pontic versus Modified ovate pontic.

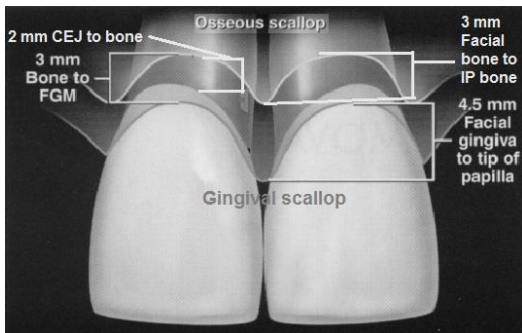


Figure 2. The osseous scallop mimics the CEJs of the natural dentition, which is about 3 mm from the height of the facial to the interproximal of the bone. The gingival scallop, on the other hand, averages about 3 mm from the bone on the facial aspect. Since the tip of the interproximal papilla averages 4.5mm above the bone, the total gingival scallop is 4.5mm from facial to interproximal.

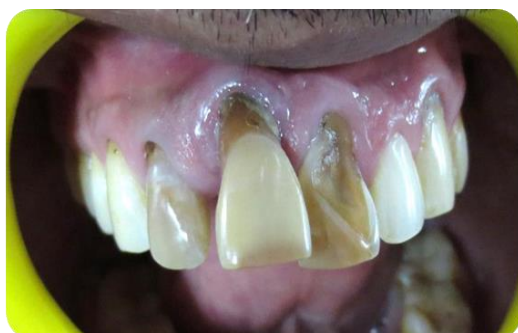

Figure 3. Initial preoperative photograph

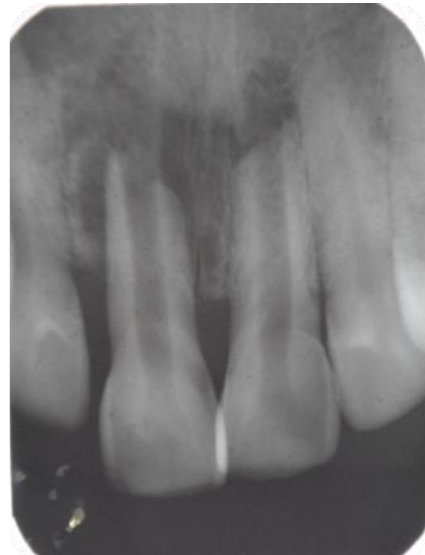

Figure 4. Preoperative IOPA radiograph

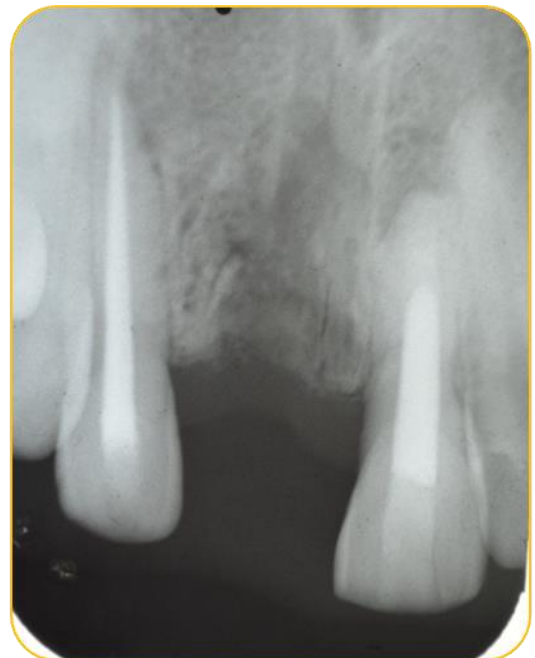

Figure 5. Post-operative IOPA radiograph, with 4mm Biodentine apical plug and root canal obturated with thermoplasticized gutta percha in the central incisor and conventional root canal treatment completed in lateral incisor.

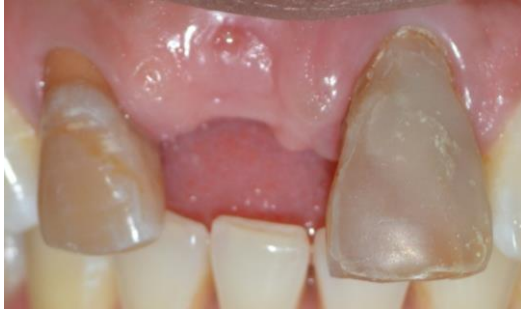

Figure 6. Post-endodontic therapy clinical presentation

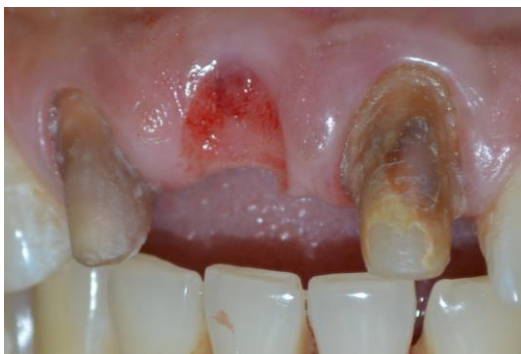

Figure 7. Tooth preparation and Gingivoplasty.

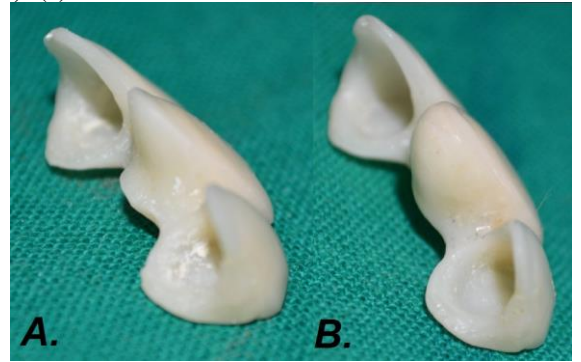


Figure 8. Lateral view of pontic of provisionals. A. Concave aspect of lingual surface prevents proper hygiene. B. 1mm increment added on tissue surface, and repolished to give a cleansable.

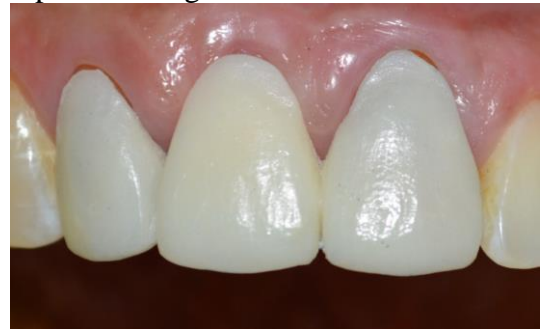

Figure 9. Provisionals in place; luted with a eugenol free temporary cement

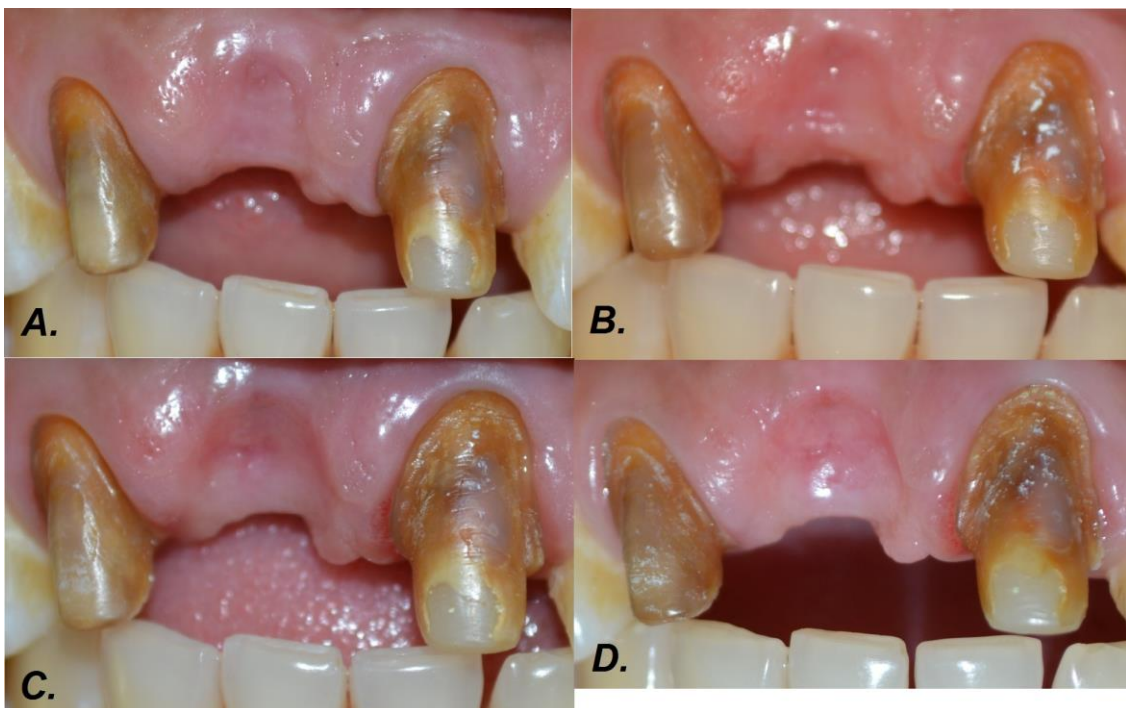

Figure 10. Healing of the modified ovate pontic site 15 days (A), 30 days (B), 45 days (C), and 60 days (D) after soft tissue contouring, i.e. of controlled pressure applied by long term provisional restoration. At 60 days, the vertical shaping of the pseudopapillae has been successfully completed.

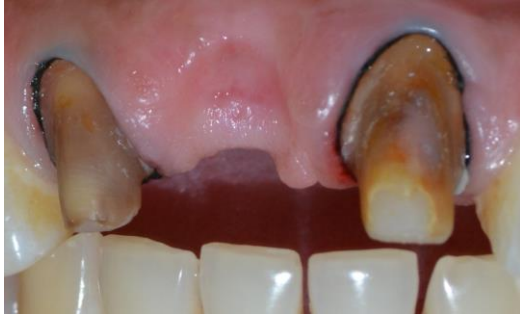

Figure 11. Modification of tooth preparation and gingival retraction.

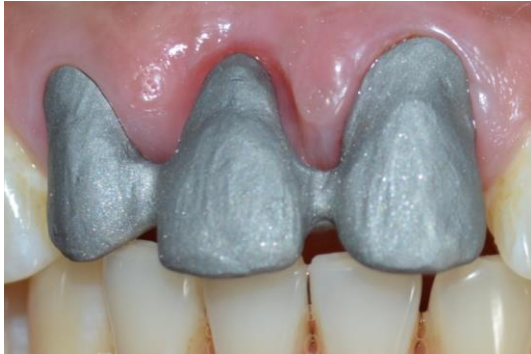

Figure 12. Trial of metal framework

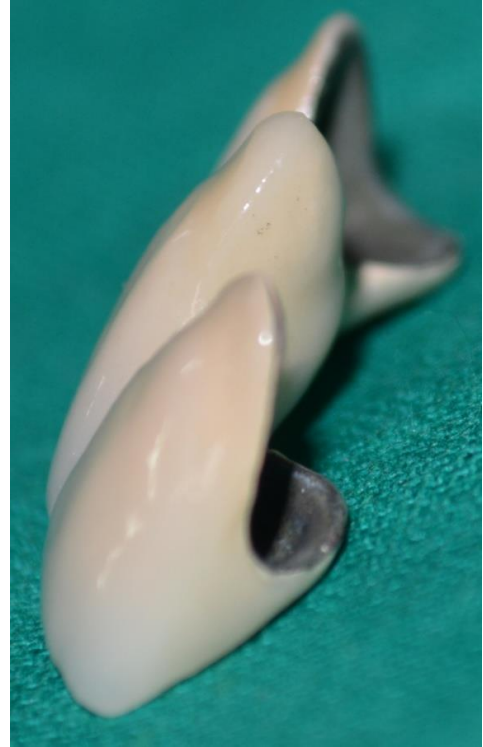
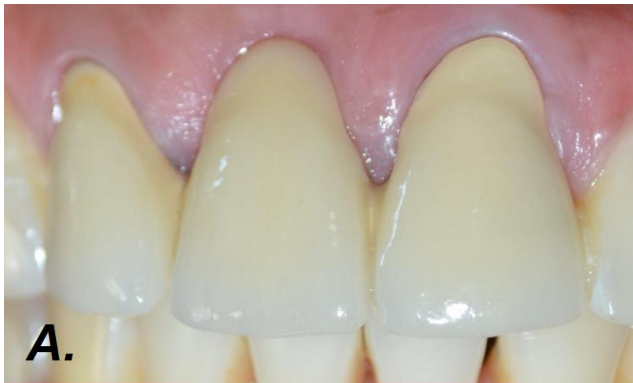
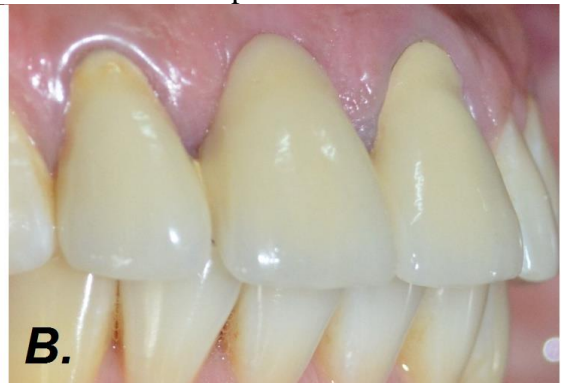Figure 13. Tissue surface of final prosthesis showing the smooth and polished convex surface of the modified ovate pontic



A.



B.

Figure 14. Final prosthesis intraorally, on the day of seating. The modified ovate pontic appears to emerge from the gingiva like a natural tooth A. Front view B. Lateral view (right)

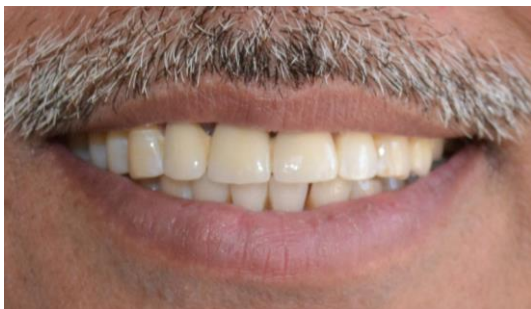

Figure 15. Final prosthesis intraorally.