

PennHIP Report

Referring Veterinarian: Dr Jessica Kirkpatrick	Clinic Name: Cottonwood Veterinary Hospital MT
Email: cvhbozeman@gmail.com	Clinic Address: 450 N. Cottonwood Rd. Bozeman, MT 59718
	Phone: (406) 582-0555
	Fax: (406) 582-4496

Patient Information

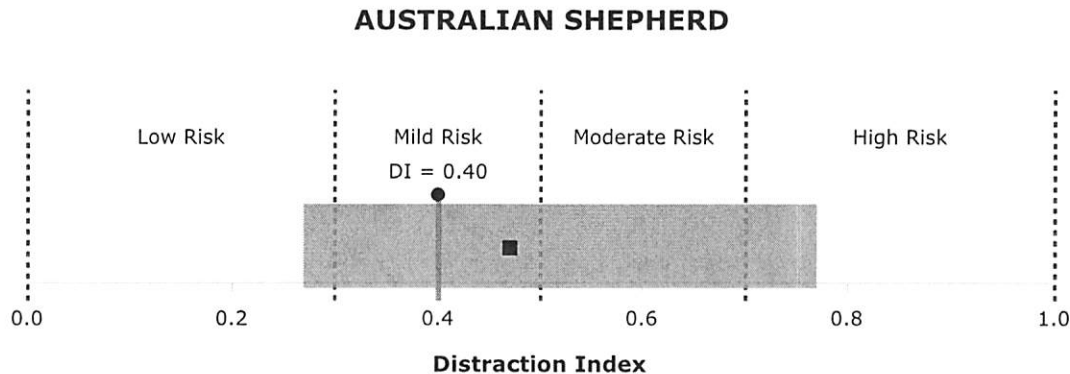
Client: COOKE, KELLY	Tattoo Num:
Patient Name: SAGE	Patient ID: 16849
Reg. Name: TURNIN' THE HERD SHADOWS SWAY	Registration Num: DN51213904
PennHIP Num: 121321	Microchip Num:
Species: Canine	Breed: AUSTRALIAN SHEPHERD
Date of Birth: 24 Sep 2017	Age: 11 months
Sex: Female	Weight: 41.5 lbs/18.8 kgs
Date of Study: 21 Aug 2018	Date Submitted: 21 Aug 2018
Date of Report: 24 Aug 2018	

Findings

Distraction Index (DI): Right DI = 0.40, Left DI = 0.37.
 Osteoarthritis (OA): No radiographic evidence of OA for either hip.
 Cavitation/Other Findings: No cavitation present.

Interpretation

Distraction Index (DI): The laxity ranking is based on the hip with the greater laxity (larger DI). In this case the DI used is 0.40.
 OA Risk Category: The DI is between 0.31 and 0.49. This patient is at mild risk for hip OA.
 Distraction Index Chart:



BREED STATISTICS: This interpretation is based on a cross-section of 1329 canine patients of the AUSTRALIAN SHEPHERD breed in the AIS PennHIP database. The gray strip represents the central 90% range of DIs (0.27 - 0.77) for the breed. The breed average DI is 0.47 (solid square). The patient DI is the solid circle (0.40).

SUMMARY: The degree of laxity (DI = 0.40) falls within the central 90% range of DIs for the breed. This amount of hip laxity places the hip at a mild risk to develop hip OA. No radiographic evidence of OA for either hip.