

# Implementation on Recognize Obstructive Sleep Apnea by using Region Growing Segmentation during Sleep

Pratima Gosavi<sup>1</sup>, Asst.Prof, Kawale Jayashri N<sup>2</sup>, Venkat Ghodke<sup>3</sup>

<sup>1,3</sup>Department of E & TC, G.S. Moze College of Engineering, Balwadi, Pune

<sup>2</sup>Department of E & TC, AISSMS IOIT, Pune

**Abstract-** Obstructive sleep apnea is a typical issue that influences a person's breathing during sleep. There are two types of sleep apnea, but most popular type is obstructive sleep apnea. This type of apnea happens when our throat muscles discontinuously unwind and block our airway during sleep. Obstructive sleep apnea (OSA) is progressively being perceived as an important medical problem in the last a few decades. Obstructive sleep apnea (OSA) disorder in kids is a typical issue and may affect as many as 2% of kids and 4-5% of adults. This paper demonstrates the survey of upper airway during sleep.

**Technical Keyword-** Obstructive sleep apnea (OSA), biomedical image processing, image segmentation, magnetic resonance imaging, medical diagnostic imaging, 3D region growing method.

## I. INTRODUCTION

Obstructive rest apnea (OSA) is the most well-known type of sleep apnea and is characterized by repetitive episodes of airflow cessation during sleep as a result of the collapse of the pharyngeal airway. The predominance of OSA disorder has been evaluated at 2% of the general populace of children (2), 13–66% of obese children (3), and 4–9% of adults. Airway collapse during sleep is caused by a combination of anatomical and functional factors. Anatomical variables incorporate inalienably limited upper airway resulting from 1) enlarged adenoids or tonsils, 2) a large soft palate, and 3) a large tongue. Useful components incorporated decrease in the activation of pharyngeal dilator muscles with sleep onset. Obesity contributes to a narrow airway and airway collapsibility (4), and the prevalence of obesity is on the rise. Despite breathing efforts, airway obstruction results in no gas exchange leading to oxygen desaturation and frequent arousals during sleep [2]. This paper uses modified region growing segmentation where the administrator chooses a region of interest that includes the pharyngeal airway, places two seeds in the patent airway, and chooses an edge for the main edge. Area developing division can correctly break down the cause and level of upper aviation route narrowing in patients with OSA.

## II. MOTIVATION

Obstructive sleep apnea (OSA) disorder is a typical breathing issue in which the airflow pauses during sleep because of physical collapse of pharyngeal airway. It influences roughly 4–9% of grown-ups and 2% of youngsters in the United States; specifically, OSA has been accounted for in 13–66% of hefty kids. OSA is connected to diminished efficiency, mishaps, and expanded danger of cardiovascular sickness. It is broadly perceived that deciding the exact area of obstruction sites may benefit treatment planning and patient outcome. Obstructive sleep apnea (OSA) is caused by a blockage of the airway, usually when the soft tissue in the rear of the throat collapses and closes during sleep. The disruption of the ability to breathe typically because of this blockage is called an apnea. The body is in a casual position when a sleep and sleep apnea is caused when the muscles in the back of the throat relax. These muscles bolster the delicate sense of taste, uvula, and side dividers of the throat, tonsils, and the tongue. When these muscles are relaxed, the airway narrows or closes when breathing in and obstructs smooth breathing, which in turn lowers the level of oxygen in blood. This disturbs rest and the individual awakens. Dangers of this ailment when an individual is:-

- Related to someone who has sleep apnea
- Over the age of 65
- A smoker
- Overweight

Sign and symptoms of sleep apnea:-

- Dry mouth or sore throat at wake ups
- Not able to concentrate
- Morning headaches
- Irritations and depressions
- Loss of memory

## III. LITERATURE SURVEY

C. W. Wang et al. [1] "Evaluation and Comparison of Anatomical Landmark Detection Methods for Cephalometric X-Ray Images: A Grand Challenge," Investigation of two-dimensional (2D) X-ray images of the craniofacial area, i.e. cephalograms, is the backbone of modern orthodontics, orthognathic treatment and maxillofacial surgery. Checking of anatomical milestones in cephalometric investigation is important as it gives the translation of patients' hard structures and gives the entire picture for specialists in orthographic surgery (OGS). Cephalometric examination is a basic clinical and inquires about device in orthodontics for the orthodontic examination and treatment arranging. This paper introduces the assessment of the strategies submitted to the Automatic Cephalometric X-Ray Landmark Recognition Challenge, held at the IEEE International Symposium on Biomedical Imaging 2014 with an on-site competition. This paper introduces a representative selection of current strategies which were submitted to the Automatic Cephalometric X-Ray Landmark Detection Challenge held at ISBI 2014. The 300 cephalometric X-ray images with resolution 1935 by 2400 pixels were given by the Tri-Service General Hospital in Taipei, Taiwan.

Y.-C. Kim et al. [2] "Real-time 3D magnetic resonance imaging of the pharyngeal airway in sleep apnea," the purpose of this paper is to explore the possibility of real-time 3D magnetic resonance imaging (MRI) with simultaneous recording of physiological signals for identifying sites of airway obstruction during natural sleep in pediatric patients with sleep-disordered breathing. Tests were performed utilizing a three-dimensional Fourier transformation (3DFT) gradient echo sequence with prospective under sampling based on golden-angle radial spokes, and L1-norm regularized iterative self-consistent parallel imaging (L1-SPIRiT) reconstruction. This strategy was shown in three healthy adult volunteers and five pediatric patients with sleep-disordered breathing. Outer airway occlusion was utilized to initiate incomplete fall of the upper airway on inspiration and test the effectiveness of the proposed imaging technique. Apneic events were recognized utilizing data accessible from synchronized recording of mask pressure and respiratory effort. The result of this paper is that the Real-time 3D MRI of the pharyngeal airway with synchronized recording of physiological signals is possible and may give profitable data about the destinations and nature of airway narrowing/collapse during natural sleep.

M. E. Wagshul et al. [3] "Novel retrospective, respiratory gating method enables 3D, high resolution, dynamic imaging of the upper airway during tidal breathing.," the purpose of this paper is A retrospective, respiratory-gated system for measuring dynamic changes in the upper airway over the

respiratory cycle was produced, with a definitive objective of building anatomically and practically exact upper airway models in obstructive sleep apnea patients. Three-dimensional cine, retrospective respiratory gated, gradient echo imaging was performed in six young people being assessed for polycystic ovary disorder, a confusion with a high obstructive sleep apnea prevalence. A novel retrospective gating scheme, synchronized to flow from a nasal cannula, limited image acquisition to predefined physiological ranges. Images were evaluated with respect to contrast, airway signal leakage, and demonstration of dynamic airway area changes. The result of this is the Retrospective, respiratory gated imaging of the upper airway has been illustrated, using a gating algorithm to guarantee obtaining over determined scopes of respiratory rate and tidal volume.

Z. Raeesy et al. [4] "Automatic Segmentation of Vocal Tract Mr Images," Magnetic resonance imaging (MRI) is generally connected as a safe what's more, dependable strategy in concentrate the hidden systems of human speech production. Automatic segmentation of vocal tract shape in MRI is a challenging task because of the dynamic way of articulation, the fluctuation in the shape presented by various sounds or distinctive speakers' articulatory arrangements, and the availability of vocal tract airway to other channels of air such as the nasal tract. Another approach for the automatic segmentation of the vocal tract shape in dynamic MR images is proposed. A technique of automatic landmark tagging by recursive boundary subdivision (RBS) is connected to acquire the relating sets of landmarks on the vocal tract contours. The oriented active shape model (OASM) strategy is received to perceive what's more, depict the shape of the vocal tract in standardised MR images. The outcomes are exhibited and assessed both subjectively what's more, quantitatively. We exhibit this is a promising methodology for automatic segmentation of large databases of vocal tract images for the purposes of speech production studies.

T. D. Bradley et al. [5] "Obstructive sleep apnoea and its cardiovascular consequences" Obstructive rest apnoea (OSA) is described by repetitive interruption of ventilation during sleep due to collapse of the pharyngeal airway. The inspiratory airflow can be either decreased or totally absent, and an apnoea that lasts 10 sec or longer, associated with continuous ventilatory exertion, characterizes a patient with OSA. Obstructive sleep apnoea (OSA) is a type of sleep disordered breathing with a high prevalence rate and is regularly underdiagnosed. OSA is related with hypertension, coronary artery disease, stroke, peripheral vascular disease, heart failure, and arrhythmias. The nearness of OSA might be a strong predictor of fatal cardiovascular events in patients with cardiovascular disease (CVD). Increased sympathetic drive, activation of metabolic and inflammatory markers, and

impaired vascular function are some of the proposed systems that could clarify the relationship amongst OSA and cardiovascular diseases. Understanding these mechanisms is important for identifying treatment procedures. The presence of OSA should be considered in clinical practice, particularly in patients with CVD. Randomized intercession studies are expected to build up whether early identification and treatment of OSA patients reduces cardiovascular morbidity.

S.L.Verhulst et al. [6] "Sleep-disordered breathing in overweight and obese children and adolescents: prevalence, characteristics and the role of fat distribution" the aim of this paper is to decide the prevalence of sleep-disordered breathing (SDB) in a clinical sample of overweight and obese youngsters and youths, and to look at the commitment of fat conveyance. Obese children and adolescents are at risk of sleepdisorderedbreathing (SDB). A few reviews, utilizing polysomnography, have reported the commonness of obstructive rest apnoea (OSA) in this gathering, extending from 13% to 66%. SDB is exceptionally regular in this clinical example of overweight kids. OSA is not related with abdominal obesity. Actually, more elevated amounts of stomach heftiness and fat mass are related with focal rest apnoea.

R. Arens et al. [7] "Changes in upper airway size during tidal breathing in children with obstructive sleep apnea syndrome." Different procedures have been utilized as a part of late years to identify dynamic changes in the upperairway including the following: fluoroscopy, cine computed tomography, and fast magnetic resonance imaging (MRI). Obstructive rest apnea disorder (OSAS) in children is a typical disorder and may affect as many as 2% of Every now and again, OSAS is related with adenoid as well as tonsillar hypertrophy. This review describes changes in upper airway area and shape during tidal breathing in mildly sedated children with OSAS. We found that the upper airway in these children is fundamentally smaller contrasted and control subjects, especially during inspiration, whereas dilatation occurs during expiration. We noted essentially more change in airway size, with narrowing during motivation that was more prominent in higher or pharyngeal levels.

RaananArens et al. [8] "Upper Airway Size Analysis by Magnetic Resonance Imaging of Children with Obstructive Sleep Apnea Syndrome" detailed analysis of the upper airway has not been performed in kids with obstructive sleep apnea. Utilized magnetic resonance imaging and automatic segmentation to delineate the upper airway in 20 children with obstructive sleep apnea and in 20 control subjects. Utilized MRI to analyse the size of the upper airway in children with OSAS. The outcomes propose that the upper aviation route in kids with OSAS is significantly smaller with respect to airway

volume, mean airway cross-sectional area, and minimal cross-sectional area compared with matched control subjects. This paper likewise noticed that the upper aviation route in kids with OSAS is confined along the underlying 60–70% of its length and most influenced in locales where adenoid and tonsils cover.

#### IV. PROPOSED SYSTEM

The current gold standard for diagnosing OSA is overnight polysomnography (PSG). PSG involves monitoring and continuously recording several physiological signals that reflect sleep and breathing, for roughly 7–8 h. The single most important output of overnight PSG is the apnea hypopnea index (AHI) the average number of complete or partial obstructive events that occur per hour during sleep. PSG also helps to elucidate the impact of these events on sleep pattern and gas exchange. An overnight PSG requires interpretation by a skilled sleep specialist for visual scoring; in contrast, computer scoring has not been proven accurate. Objective monitoring is required because patient history and physical findings suggestive of OSA are not considered sufficiently sensitive or specific to make a diagnosis. Often, uncomplicated cases of OSA in children can be diagnosed and treated with removal of the tonsils and adenoids or by the provision of positive airway pressure therapy. While PSG provides a detailed physiologic diagnosis, no information regarding the site, or sites, of obstruction can be inferred from the recording. This is especially important for complicated cases of OSA, including obesity and craniofacial abnormalities. In these cases, surgical intervention directed at relieving sites of obstruction may be needed.

#### Block Diagram Description

Figure 1 shows the block diagram of proposed system. This description of each block is describe in below,

**Frame:** First take a frame from video. A reference frame is selected to be the first frame with a visibly patent airway in each dataset.

**Pre-processing:** Pre-processing is the technique of enhancing data images prior to computational processing.

**Enhancement:** The aim of image enhancement is to improve the interpretability or perception of information in images for human viewers, or to provide 'better' input for other automated image processing techniques.

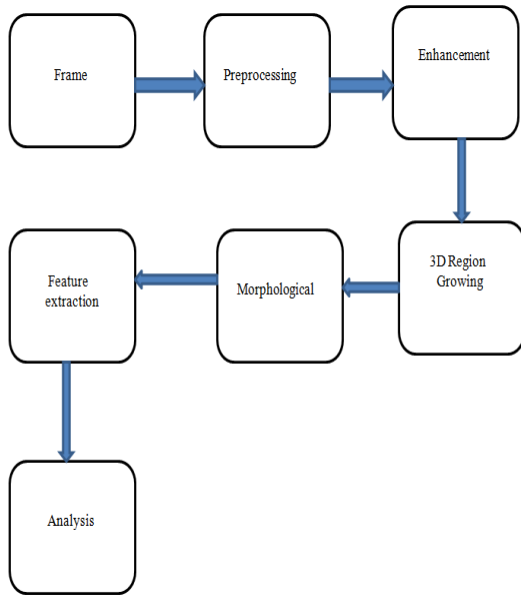


Fig.1: Proposed System

**3-D region growing:** 3D region growing method is an image segmentation method. The main goal of image segmentation is to partition an image into regions. Region based segmentation is a technique for determining the region directly. The first frame is segmented using multisided 3-D region growing. The main idea of region growing is to start with a single picture element and gradually grow a region (segment) by including all neighboring picture elements that are deemed similar enough to the starting element. There are many variations of region growing, but the basic steps that are common to all region growing methods are as follows. First, one or more seeds need to be placed in the image that is to be segmented (at least one seed for each segment). The purpose of these seeds is to serve as starting points for the segmentation process. These seeds can be placed manually by the user, or automatically by an algorithm. Automatic seed placement is usually preferred, but automatic placement is not always reliable (or even possible). Each seed is made from one or a small number of connected pixels. Once the seeds are placed, the growing process can begin. To grow each seed into a region, the region growing process starts by examining each of the pixels or voxels that constitute the neighbors of a given seed, to determine whether these neighbors should be added to the region.

**Flow chart:-**

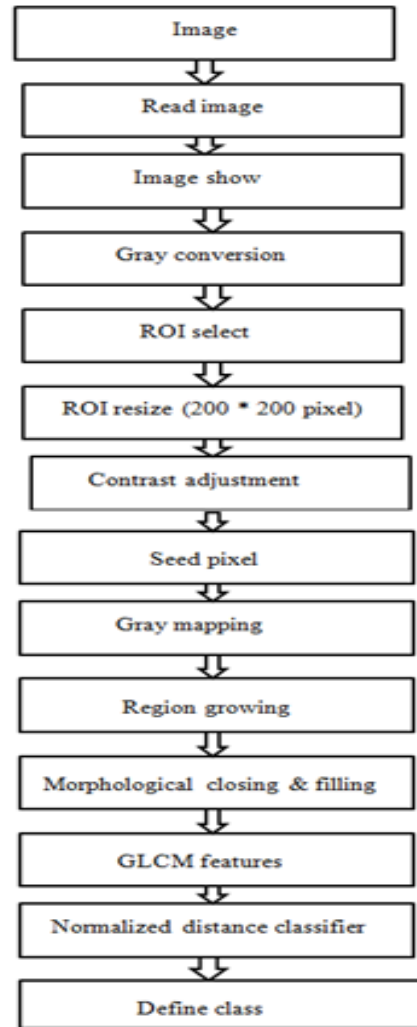


Fig.2: Flow Chart

**V. RESULT ANALYSIS**

Demonstrate the three different outputs from three different images. Fig. 3 shows the normal condition of patient. Fig. 4 and 5 shows the abnormal medium and high condition of patient. Before these condition we completed different levels such as read image, image is converted into gray image, select region of interest, different feature extractions, and finally to classify image into three conditions like normal, abnormal-medium and abnormal high. The extracted features are show in the table no. I.

	Normal	Abnormal
Normal	19	1
Abnormal	0	10

### Confusion matrix

The figure 3 shows the confusion matrix of result and to calculate the accuracy, sensitivity and specificity are as below,

Where, Total image = 100, Train image = 70, Test image = 30, Positive (P) = 20, Negative (N) = 10

Formula of accuracy is given below, to calculate the accuracy of result.

$$\text{Accuracy} = \frac{T_p + T_n}{p + n} = \frac{19 + 10}{20 + 10} * 100 = 96.6\%$$

The sensitivity or true positive rate (TPR) is as follows,

$$\text{Sensitivity (TPR)} = \frac{T_p}{p} = \frac{19}{20} * 100 = 95\%$$

The specificity or true negative rate (TNR) is as follows,

$$\text{Specificity (TNR)} = \frac{T_n}{n} = \frac{10}{10} * 100 = 100\%$$

Where,  $T_p$  is true positive and  $T_n$  is true negative.

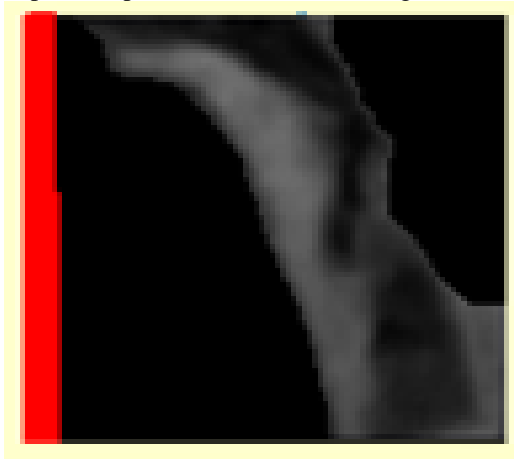


Fig.3: Normal




Fig.4: Abnormal medium

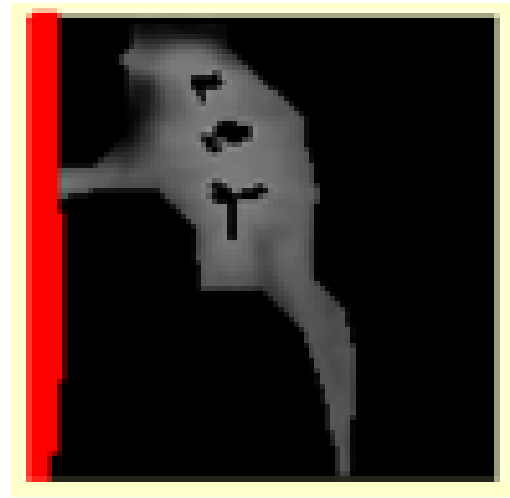


Fig.5: Abnormal high

**Table I: comparison of three different inputs and extract feature**

Feature extracted	Normal	Abnormal medium	Abnormal high
SUM	790256	409085	746345
MEAN	2.5e-0.5	2.5e-0.5	2.5e-0.5
VAR	1.52298e-09	4.87114e-09	2.5785e-09
CONTR	1878.79	1638.23	1187.54
DISSM	36.4424	36.099	28.5622
ENRG	8.59176e-05	0.000219841	0.000128137
ENTRP	9.4632	8.44419	8.99447
HOMOINT	0.0609548	0.0532428	0.0787587
MAXPRB	0.000145522	0.000278671	0.000166143
MAJAX	275.284	236.457	188.849
MINAX	83.651	43.695	85.4008

## VI. CONCLUSION

A region growing segmentation technique for identification and investigation of obstructive rest apnea (OSA). We extricate different components features such as SUM, VAR, MINAX, ENRG, ENTRP, MAXPRB, MEAN, CONTR, DISSM, and HOMOINT. We assessed our model on three different conditions such as normal, abnormal-medium and abnormal-high. Result demonstrates the identified sleep apnea is present or not in persons with different features.

## VII. REFERENCES

- [1]. C. W. Wang et al., "Evaluation and Comparison of Anatomical Landmark Detection Methods for Cephalometric X-Ray Images: A Grand Challenge," IEEE Trans. Med. Imaging, pp. 1–1, 2015.
- [2]. Y.-C. Kim et al., "Real-time 3D magnetic resonance imaging of the pharyngeal airway in sleep apnea.," Magn.Reson. Med., vol. 71, no. 4, pp. 1501–10, Apr. 2014.
- [3]. M. E. Wagshul et al., "Novel retrospective, respiratorygatingmethod enables 3D, high resolution, dynamic

- imaging of the upper airway during tidal breathing,” *Magn. Reson. Med.*, vol. 70, no. 6, pp. 1580–90, Dec. 2013.
- [4]. Z. Raeesy, S. Rueda, J. K. Udupa, and J. Coleman, “Automatic Segmentation of Vocal Tract Mr Images,” pp. 1316–1319, 2013.
- [5]. T. D. Bradley and J. S. Floras, “Obstructive sleep apnoea and its cardiovascular consequences.” *Lancet*, vol. 373, no. 9657, pp. 82–93, Jan. 2009.
- [6]. S.L.Verhulst et al., “Sleep-disordered breathing in overweight and obese children and adolescents: prevalence, characteristics and the role of fat distribution.” *Arch. Dis. Child.*, vol. 92, no. 3, pp. 205–8, Mar. 2007.
- [7]. R. Arens et al., “Changes in upper airway size during tidal breathing in children with obstructive sleep apnea syndrome.” *Am. J. Respir. Crit. Care Med.*, vol. 171, no. 11, pp. 1298–304, Jun. 2005.
- [8]. R. Arens et al., “Upper airway size analysis by magnetic resonance imaging of children with obstructive sleep apnea syndrome.” *Am. J. Respir. Crit. Care Med.*, vol. 167, no. 1, pp. 65–70, Jan. 2003.