

Greater Manchester Local Dental Network

Saving Smiles

Improving outcomes
following dental trauma



SavingSmiles

Improving outcomes
following dental trauma



Contents

04	Introduction to the toolkit from the GM Trauma Network
06	History & examination
10	Maxillo-facial considerations
12	Classification of dento-alveolar injuries
16	The paediatric patient
18	Splinting
20	The AVULSED Tooth
22	The BROKEN Tooth
23	Managing injuries with delayed presentation
24	Follow up
26	Long term consequences
28	Armamentarium
29	When to refer
30	Non-accidental injury
31	What should I do if I suspect dental neglect or abuse?
34	www.dentaltrauma.co.uk
35	Additional reference material
36	Dental trauma history sheet
38	Avulsion pathways
39	Fractures and displacement pathway
40	Fractures and displacements in the primary dentition
41	Acknowledgements



Introduction to the Toolkit from the GM Trauma Network

The Greater Manchester Local Dental Network (GM LDN) has established a 'Trauma Network' sub-group. The Trauma Network was established to support a safer, faster, better first response to dental trauma and follow up care across GM. The group includes members representing general dental practitioners, commissioners, specialists in restorative and paediatric dentistry, and dental public health.

The group has produced this Toolkit to support dentists in managing dental trauma and improving outcomes for patients. At the end of the Toolkit are three quick reference flow charts, to guide first line decision making in situations where time is of the essence. The main text provides more detail to act as a reference guide.

Rationale

Using published estimates¹, we can expect every dental practice in GM to see around one case of child dental trauma per year. Because of this relatively infrequent occurrence, managing dental trauma can sometimes feel quite daunting. In a survey of 354 primary care dentists across GM, 44% reported they did not feel confident in managing dental trauma due to a lack of experience and relatively infrequent occurrence. A similar survey of 30 maxillo-facial consultants and trainees showed that although confidence in managing dental trauma was higher, 46% did not correctly plan the management of an avulsed adult tooth and 80% felt that the most appropriate place for the management of dental trauma was primary care.

The evidence shows that the key to achieving the best outcomes for patients is rapid access to the most appropriate treatment as soon as possible after the injury. This is why it is so crucial to get the first aid, primary care response right. Correct diagnosis and follow-up may avoid the loss of a tooth, which in children would have significant emotional and financial impact over a life time.

¹ Lam, R. (2016). Epidemiology and outcomes of traumatic dental injuries: A review of the literature. Australian Dental Journal, 61, 4–20. <http://doi.org/10.1111/adj.12395>



Ambition for Greater Manchester

The GM Trauma Network wish to work with our colleagues to ensure that:

- All clinicians in GM have the confidence and knowledge to provide a timely and effective first line response to dental trauma.
- All clinicians are aware of the need for close monitoring of patients following trauma, and when to refer.
- All settings have the equipment described within the 'armamentarium' section of this booklet to support optimal treatment.

To support GM practitioners in achieving this ambition, we will be working with Health Education England to provide training days and CPD workshops. We would also like to encourage all practitioners to use the excellent 'Dental Trauma Guide' website for more detailed, comprehensive guidance on the diagnosis and management of dental trauma.

Membership to the Dental Trauma Guide costs 25 USD/year but there are plenty of free resources on the internet to support practitioners most notably the charity Dental Trauma UK.

Key Trauma Facts

- The incidence of dental trauma is estimated at between 1% and 3% of the population/year.
- Around 20-30% of the population are living with a dentition that may have suffered trauma.
- High risk groups can be broadly split into ages 2-4, 10-12 and adolescents onwards.
- In the age group 2-4 years it is associated with the developmental transition from crawling to walking: as one may expect this presents a high risk of trips and falls.
- From ages 10-12 the risk largely comes from sports injuries and accidents.
- From adolescence through to early adulthood the risk largely comes in the form of alcohol related injury and road traffic accidents. These latter injuries usually occur at weekends when access to care may be restricted.
- Trauma is more common in males than females.
- The upper central incisors are the most commonly affected teeth followed by lower centrals then upper lateral incisors.
- Over 90% of such trauma is dento-alveolar alone but nearly a third will have a soft tissue component.
- Jaw fractures are comparatively rare, only present in around 6% of cases.

Most people will have had such minimal trauma that no further treatment is required but for others the consequences could be more severe. Simple cases may include uncomplicated fractures of dentine and enamel. In more severe case this could mean discolouration of teeth, loss of vitality, resorption or loss of the tooth. Timely and appropriate management is critical if such negative outcomes are to be minimised.



History and examination

History

A confused or disorientated patient could be suggestive of systemic problems, drugs, alcohol or underlying head injury. The safest option is such circumstances would be an acute referral to hospital care. If the patient has capacity, try to determine:

Where did the injury occur? In addition the location may, on occasion, indicate the possibility of contamination of the tooth and inform the decision to seek tetanus prophylaxis.

How did the injury occur? This may lead to identification of the impact zones i.e. a chin injury is often combined with crown or crown-root fractures in premolar and molar regions and blunt impact trauma may result in tooth displacement. Sharp or blunt trauma and the velocity all add information on what the likely injury may be.

When did the injury occur? In relation to a tooth avulsion injury the length of time and the extra-oral storage condition becomes very important when planning immediate care and assessing the risk of future complications.

Are there signs of brain injury? Loss of consciousness, amnesia, nausea and vomiting are all signs of brain damage and require medical attention. If there is a positive history of brain injury, refer to the local Accident and Emergency Department. If the patient attends alone it may be prudent to arrange a taxi and arrange a chaperone at this point.

If teeth are broken or avulsed can all missing pieces be accounted for? This is essential as not only can avulsed teeth be re-implanted but fractured portions can be reattached. Further more one must be vigilant to fragments being embedded in soft tissues and if fragments are unaccounted for this indicates the need for soft tissue radiographs.

Is there disruption of the occlusion? Does the patient's bite feel right? If not this should alert the clinician to the possibility of a displacement injury or fracture. This will be confirmed during the examination.



Medical history: This should be rapid but thorough. There are very few medical or systemic factors that may affect acute trauma management in primary care. Questions should include the following factors that may contribute to underlying signs and symptoms:

1. Bleeding disorders or anticoagulant therapy (for increased risk of bruising), haematoma and intracranial bleed.
2. Tetanus status.

Even patients with very complex medical histories should be offered standard acute trauma care including reimplantation as the challenges presented with prosthetic rehabilitation may be more complex than the risks posed by immediate first line treatment.

Social History

Smoking

Smokers should be counselled that continued smoking may have an impact upon healing times.

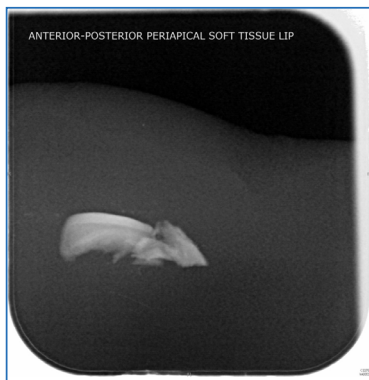
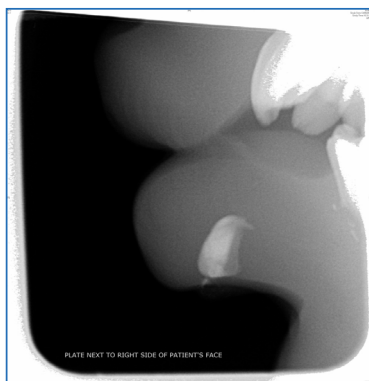
Alcohol

An alcohol history may sign post the clinician to causation (did the injury occur whilst under the influence of alcohol? It may also signpost the clinician to offer advice about reducing alcohol consumption and/or referral to their GP for support.

Occupation/hobbies: If the patient has a high risk of future trauma through occupation and/or pass times they must be counselled on the importance of modifying behaviour until healing has occurred: Implant based reconstructions should not be considered in patients continuing to play contact sports.

Saving Smiles

Improving outcomes
following dental trauma



Extensive, deep or complex soft tissue injury with a high risk of scarring. Referral should be made if it is not possible to decontaminate wounds.

Examination

Clean the patient and administer local anaesthetic.

Soft tissue Examination

Assess all lacerations. If there are significant extra-oral lacerations that require suturing with risk of scarring at a later date: clean the wound and refer to local acute facility for treatment with Max-Facs/Plastics.

Is there any disturbance in the bite?

This may indicate a luxation injury with displacement, an alveolar or jaw fracture or a fracture of the condylar region. Limited or deviation on opening may be consistent with condylar head fracture. Significant disturbances of occlusion or step deformities in the occlusal plane may be suggestive of mandibular fracture or dento-alveolar fracture. If suspected refer to Maxillofacial Services.

Sensibility testing?

Such tests can give false positives and negatives immediately after trauma and can be very painful for the patient who is already distressed. When patients present with multiple or severe injury this can be saved for review stages of treatment.

Radiographs:

Periapical radiography with paralleling holders should be taken at baseline. If alveolar fracture or root fracture is suspected a second view is sensible. If available an occlusal film is best as this shows any fractures in different plane. Key features to assess on radiographs include:

- Apical development
- Fracture lines of the root
- Fracture lines of the alveolus
- PDL alterations

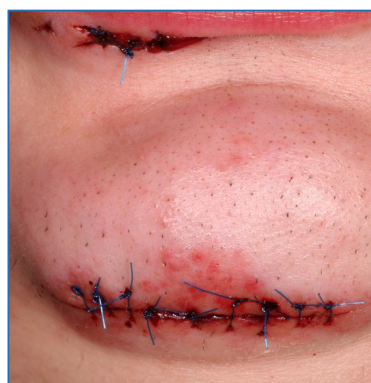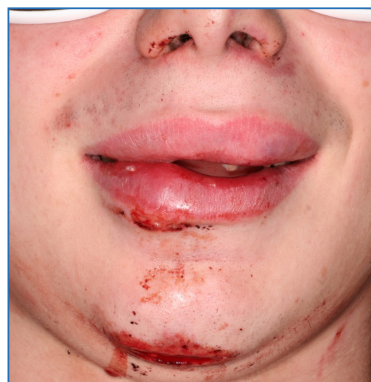Missing teeth/fragments:

Are all fragments accounted for? If not take a radiograph of the lip. Place the film in the labial sulcus and reduce the exposure time to 1/5 of that for an anterior exposure. If fragments cannot be accounted for consideration should be given to referral to emergency department for a chest radiograph.

Photographic Examination:

Offers an exact documentation of the extent of injury and can be used later in treatment planning, legal claims or clinical research. Note that patient consent is required.

Soft tissue injuries



Extensive, deep or complex soft tissue injury with a high risk of scarring. Referral should be made if it is not possible to decontaminate wounds.

These can present in a variety of forms from lacerations that may be closed and heal by primary intention to crush, contusion and abrasion injuries.

The correct management of such injuries can have a significant impact on healing and future cosmetics. If a patient presents in primary care with such injuries it can be hard to know what to do. Following administration of LA wounds should be gently cleaned with gauze and sterile water. If there is no positive history of allergy chlorhexidine or iodoform may be used but attention must be paid to any possible allergic response. Contaminants should be removed if possible. If wounds are very deep, "through and through", heavily contaminated, in close proximity to vital structures such as the parotid, facial nerve or salivary ducts or you feel there may be a high risk of poor outcomes if plastics or max-facs are not involved, refer to the local A&E department.

Suture size	4-0, 5-0 or 6-0 with reverse cutting needle.
Suture material	Non braided, monofilament non resorbing such as nylon or polypropylene are preferred to facilitate healing but if follow-up may not be possible or likely a resorbing suture such as Vicryl is also good.
Suture technique	There are many techniques described but simple interrupted allow accurate wound approximation and spread the tension whilst minimising tissue inflammation.
	Pass the needle and suture into the dermis.
	The ambition should be to slightly evert the wound margins for optimal healing.
	For deeper wounds placing a subdermal suture with a resorbable material can be used to approximate the edges and reduce tension on the finer sutures. This suture will be buried and left to resorb.
Suture removal	Removed in 5-7 days.

Maxillo-facial Considerations

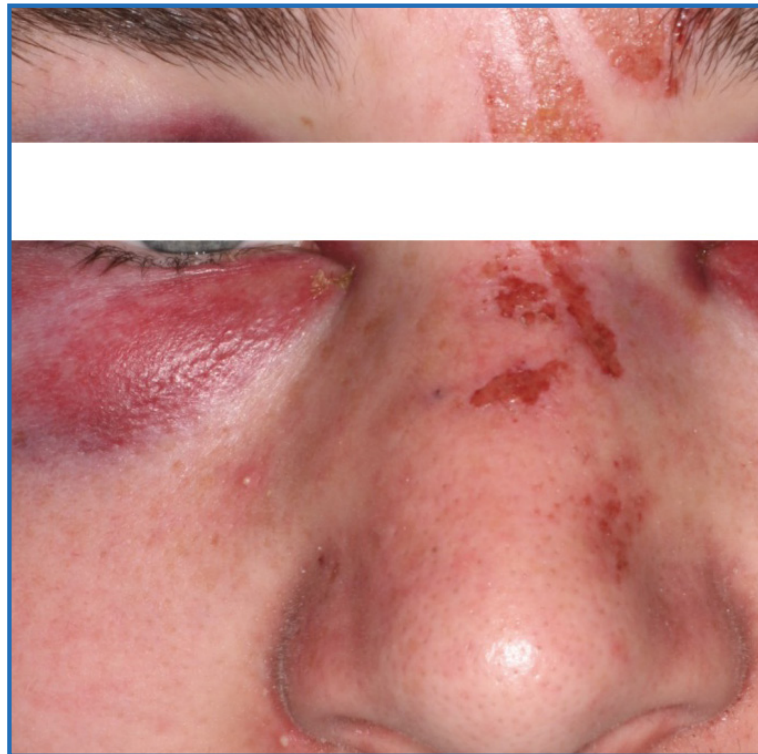Sign posts to refer to the local maxillo-facial department include:

Maxillofacial injuries:

- **Swelling and haematomas** will occur directly over fractures extraorally. A subconjunctival haemorrhage can indicate a fractured zygoma. Intraorally lingual haematomas or bruising of the palatal are good indicators of fractures.
- **Bony steps and/or facial asymmetry** such as flattening of the zygoma or deviation of the nose / nasal septum are common indicators of fractures. Where swelling is present these can be difficult to palpate and can be uncomfortable for the patient
- **Infra orbital, mental or lingual numbness** may indicate fracture.
- **Unilateral epistaxis** when the nose has not been directly traumatised can indicate a zygomatic fracture as blood drains from the sinus.
- **Altered occlusion** suggests a displaced fracture, more commonly seen in the mandible. Many patients will complain of not being able to bite normally.
- **Limitation in opening** often results from condylar fractures or zygomatic arch fractures.
- **Ocular signs** such as displacement of the eye and double vision can indicate an orbital fracture and need referral. Where pain, proptosis and loss of vision are present this can indicate a retrobulbar haemorrhage and URGENT REFERRAL is required. In Children, bradycardia/fainting on looking up can indicate a white-eye blow out and again needs URGENT REFERRAL, other obvious signs of trauma may be absent (advise against looking up).
- **Abnormal mobility** of a block of teeth, suggests a dento-alveolar fracture. Alternatively, the whole maxilla/midface can be mobile to varying degrees in a Le Fort fracture.
- **Post auricular bleeding;** bruising behind the ears (battle sign) or **CSF leak;** clear fluid leaking from the nose may indicate a base of skull fracture. Likewise, extensive periorbital swelling (panda eyes) can indicate a base of skull fracture.
- **Deep, extensive or complex lacerations** – these require thorough decontamination and can be challenging to suture. Where there is potential for vital structures to be involved (e.g facial nerve, supraorbital artery, parotid duct, etc.) referral is required.
- Be aware of the **injury pattern that does not correlate with the mechanism** given in the history, particularly in vulnerable patients and **non-accidental dental injuries**.

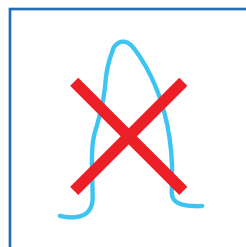
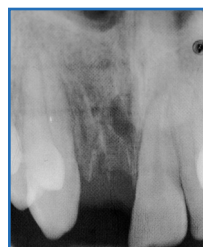Non-maxillofacial injuries:

- A painful neck / Altered sensation in upper limbs could all be a marker of an underlying cervical spine injury.
- Loss of consciousness / confusion / amnesia / drowsiness / nausea & vomiting / neurological changes (dizziness etc.) are all potential indicators of underlying brain injury and need a medical assessment.



Suborbital bruising in this case suggested zygomatic fracture. This was confirmed following a CT scan.

Classification of dento-alveolar injuries

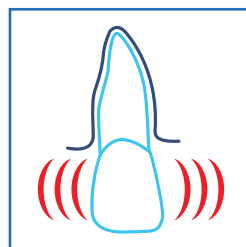
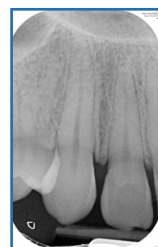


Avulsion

- The tooth is completely displaced out of its socket.
- Clinically the socket is found empty or filled with a coagulum (blood clot).

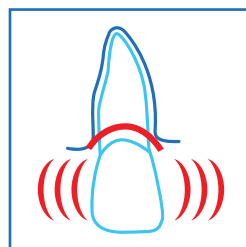
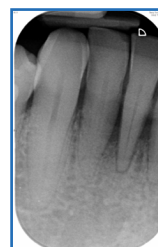
Avulsion (open apex)

- The tooth is completely displaced out of its socket.
- Clinically the socket is found empty or filled with a coagulum.
- The apical foramen of the tooth is > 1mm in diameter.



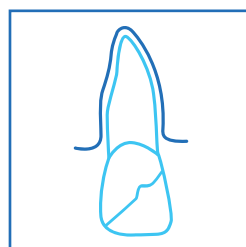
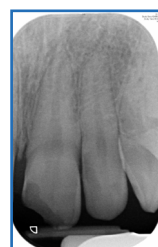Concussion

- An injury to the tooth-supporting structures without increased mobility or displacement of the tooth, but with pain to percussion.



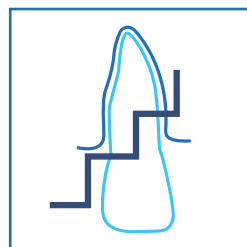
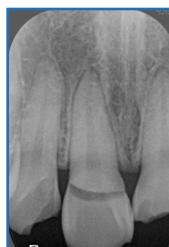
Subluxation

- An injury to the tooth supporting structures resulting in increased mobility, but without displacement of the tooth.
- Bleeding from the gingival sulcus confirms the diagnosis.



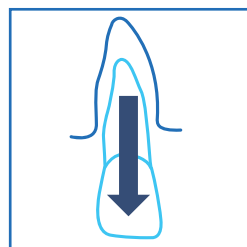
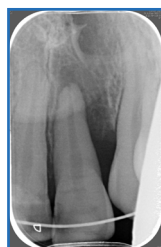Enamel Dentine Fracture

- A fracture confined to enamel and dentine with loss of tooth structure, but not involving the pulp



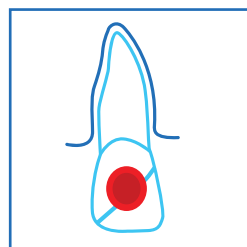
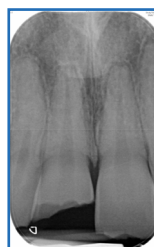
Enamel dentine fracture including the root

- A fracture involving enamel, dentine and cementum with loss of tooth structure.
- May or may not include the pulp.
- If this include the pulp the diagnosis should include the prefix "complex".



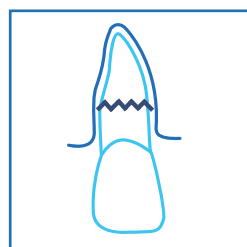
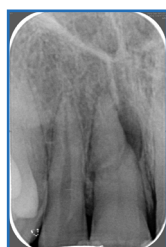Extrusion

- Partial displacement of the tooth out of its socket.
- An injury to the tooth characterized by partial or total separation of the periodontal ligament resulting in loosening and displacement of the tooth.
- The alveolar socket bone is intact in an extrusion injury as opposed to a lateral luxation injury.
- In addition to axial displacement, the tooth will usually have an element of protrusion or retrusion.
- In severe extrusion injuries the retrusion/protrusion element can be very pronounced. In some cases it can be more pronounced than the extrusive element.



Complex enamel dentine fracture

- A fracture involving enamel and dentine with loss of tooth structure and exposure of the pulp.

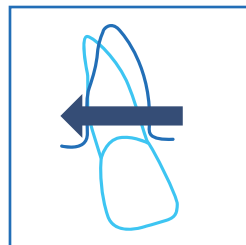
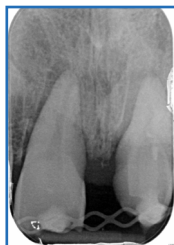

Root fracture

- A fracture confined to the root of the tooth involving cementum, dentine, and the pulp.
- Root fractures can be further classified by whether the coronal fragment is displaced.
- Further information should include the location of the fracture as cervical, mid or apical third.

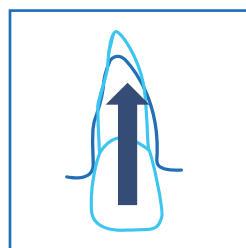
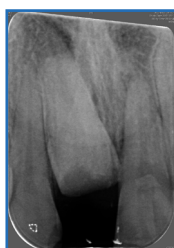Saving Smiles

Improving outcomes
following dental trauma



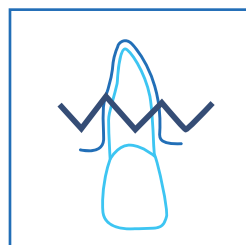
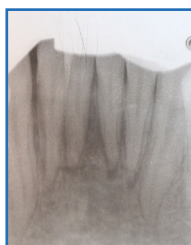Lateral luxation

- Displacement of the tooth other than axially.
- Displacement is accompanied by comminution or fracture of either the labial or the palatal/lingual alveolar bone.
- Characterized by partial or total separation of the periodontal ligament.
- If both sides of the alveolar socket have been fractured, the injury should be classified as an alveolar fracture (alveolar fractures rarely affect only a single tooth).
- In most cases of lateral luxation the apex of the tooth has been forced into the bone by the displacement, and the tooth is frequently non-mobile.
- These can be tricky to reposition. Digital pressure should be applied in the buccal sulcus to the root apex and directed coronally before manipulating the tooth back into the socket.



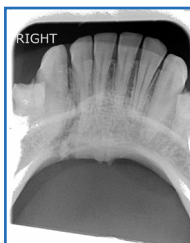
Intrusion

- Displacement of the tooth into the alveolar bone.
- This injury is accompanied by comminution or fracture of the alveolar socket.
- Repositioning can be more challenging in severe injuries as the crown may not be accessible to locate or grasp. Forceps are invariably required.
- Immature teeth intruded less than 7mm should be allowed to spontaneously erupt.
- Adult teeth intruded less than 3mm should be allowed to spontaneously erupt.



Alveolar fracture

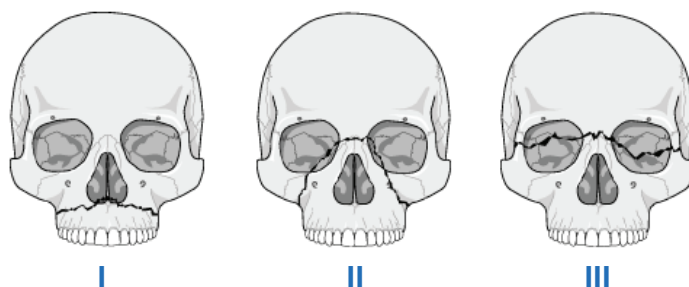
- A fracture of the alveolar process; may or may not involve the alveolar socket.
- Teeth associated with alveolar fractures are characterized by mobility of the alveolar process; several teeth typically will move as a unit when mobility is checked.
- Occlusal interference is often present.



Jaw Fracture

- A fracture involving the base of the mandible or maxilla and often the alveolar process (jaw fracture).
- The fracture may or may not involve the alveolar socket.
- If suspected refer to maxfac urgently.

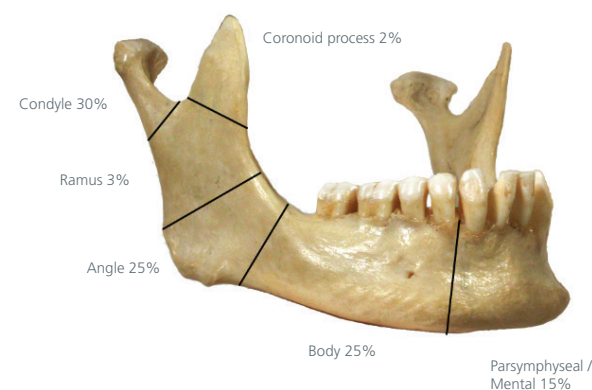
Maxilla LeFort Fractures



Maxillary Fracture Warning Signs!

Asymmetry, double vision, circum-orbital swelling and bleeding, conjunctival bleeding, nasal bleeding, numbness, sunken eye, discontinuity defects, mobile maxilla

Mandibular Fractures (Frequency by location)

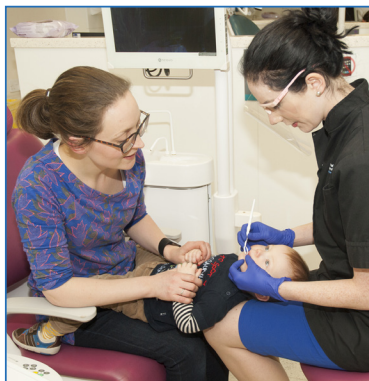

Mandibular Fracture Warning Signs!

Swelling, haematoma, discontinuity defects, altered occlusion/ step deformities, numbness, limitation of opening or deviation of movement

Following diagnosis visit the dental trauma guide for precise information upon management:

www.dentaltraumaguide.org



Lap-to-lap examination.

The Paediatric Patient

Who can consent for the paediatric patient?

In an emergency situation, treatment should be undertaken in the best interest of the child.

- All mothers have automatic parental responsibility
- A father has parental responsibility if his name is on the birth certificate and the child was born after 01/12/2003 regardless of whether or not he is married to the mother
- A father also has parental responsibility if he was married to the mother at the time of conception, birth or sometime after. This is not lost if the parents subsequently divorce.
- If parents were never married but the father has a parental responsibility agreement with the mother, which is registered with the High Court or a parental responsibility order from court.
- If parental responsibility cannot be ascertained or the patient presents with friend or other member of the family one should act in their best interests and begin treatment to avoid unnecessary delays.

How do I examine a child?

Young children are best examined in a lap-to-lap position with the parent. This involves the patient sitting on the parent's lap, facing the parent, with their legs around the parent's waist. The dentist sits knee to knee with the parent and the patient is laid back with their head on the dentist's lap. This allows the patient to maintain eye contact with the parent and for the parent to stabilise the patient's hands if necessary.

A toothbrush will be more familiar to a child patient than a dental mirror and may persuade them to open and allow an examination. The toothbrush can then be used as a mouth prop on one side while the opposite side is examined. Disposable plastic mirrors may prevent the patient further damaging their teeth should they bite down onto it.

Finger props such as the Bedi™ prop are useful aids to allow examination. These are disposable props, which provide a comfortable bite block for the patient. They can be utilised by the operator with one hand, or employed by a dental assistant, leaving the dentist with two hands free to examine the patient.



How do I give local analgesia to a child?

There are no techniques of local analgesia administration that are unique to children; however, modifications to standard techniques may be required. Always place topical analgesia such as benzocaine anaesthetic gel.

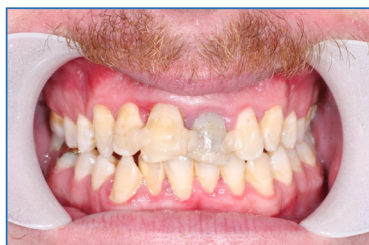- Lay the patient with upper body 30 degrees to the vertical and remain sitting for local analgesia delivery. This appears less threatening for the patient.
- Avoid direct palatal injections in children. Indirect palatal analgesia involves approaching the palatal mucosa through the previously anaesthetised interdental papilla mesially and distally.

How do I behaviour manage the paediatric patient?

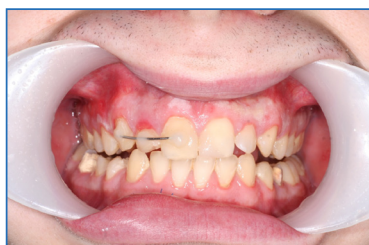This is the means by which the dental team effectively perform dental treatment for the paediatric patient.

Positive behaviour and reduced anxiety is promoted by:

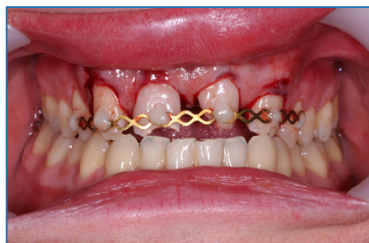- Greeting the child by name
- Clear instructions – i.e. “sit on the dental chair”
- Give illusion of choice – i.e. “which side of the dental chair would you like to get up on?”
- Ignore bad behaviour, reward good i.e. “I like how big you’re opening”
- Verbal praise is the strongest reinforcer of behaviour but other reinforcers such as stickers may be used
- Tell-show-do
- Modelling – using an older sibling to demonstrate the required behaviour



Composite splint: liable to fracture, prevents good plaque control and hard to remove.



Wire and composite splint: Fast, cheap and perfectly adequate.



Titanium trauma splint: Easiest to use and great handling but £££.

Splinting

Splinting immobilizes the tooth in the correct position, reducing the risk of further trauma and allowing healing. Different injuries require varying splinting times. Ideally, the splinting time should be as short as possible and the splint should allow physiological mobility to reduce the risk of ankylosis. The splint should extend to one tooth either side of the traumatised tooth/teeth. The splint should always be placed labially if possible.

When is splinting advised?

Splinting is advised for the following injuries in the permanent dentition:

1. Subluxation – not usually necessary but may be used for patient comfort
2. Extrusive luxation
3. Lateral luxation
4. Intrusive luxation
5. Avulsion
6. Root fracture (only if displaced)
7. Alveolar fracture

In the primary dentition, splinting is only ever indicated in cases of alveolar fracture. Frequently, due to patient age, this procedure is carried out under general anaesthetic.

How long will still be mobile following splint removal)

- Subluxation – 2 weeks
- Extrusive luxation – 2 weeks
- Lateral luxation – 4 weeks
- Intruded teeth that have been surgically repositioned – 4 weeks
- Avulsed teeth with a chance of cemental/periodontal ligament healing – 2 weeks (explain to patient that tooth will still be mobile on splint removal)
- Avulsed teeth likely to heal by ankylosis – 2-4 weeks. A longer duration of splinting may be undertaken if necessary, as this will have no effect on periodontal healing.
- Root fractured teeth (displaced) – apical and mid third – 4 weeks
- Root fractured teeth (displaced) – coronal third – 4 months
- Alveolar fracture – 4 weeks
- Root fractured teeth (displaced) - coronal third - 4months or indefinitely if residual mobility is uncomfortable.

What is the Titanium Trauma Splint (TTS)?

The TTS is a titanium splint, 0.2 mm thick that can be easily adapted to the contour of the dental arch using finger pressure alone. Its rhomboid mesh makes it flexible in all dimensions, allowing physiological mobility and it can be cut to the desired length. The rhomboid openings facilitate fixation as the size of the openings define a small bonding area. It can be fixed using a small amount of flowable composite and easily removed by grinding the composite to the level of the TTS and “peeling” the splint from the teeth. However, the TTS is more expensive than wire/composite or orthodontic bracket/wire splints.

- Administer local analgesia to buccal and palatal/lingual tissues of displaced/avulsed tooth and any lacerated intraoral tissues.
 - Suture any lip or gingival lacerations prior to commencing.
 - Reposition the displaced/avulsed tooth.
 - Splints should be flexible – acid etch/composite and flexible wire, orthodontic brackets and wire (as long as the wire is passive) or a TTS splint. Splints composed of composite alone are not appropriate due to rigidity and patient difficulty cleaning the interproximal areas.
 - Wash and dry the teeth you plan to splint (the injured tooth and one tooth either side).
 - Good lighting and a clean, dry field are essential. Place a rubber dam if possible.
 - Shape your choice of splint so that it sits passively over the labial or buccal surface of the clinical crowns.
-
1. Measure and cut the wire or TTS to extend to one healthy tooth either side of the traumatised tooth/teeth
 2. Spot etch the enamel on the labial surface of the centre of the clinical crown of the teeth using 30-40% phosphoric acid
 3. Wash and dry the teeth again with pressurized air
 4. Spot bond the teeth and light cure
 5. Apply a small amount of flowable or hybrid composite to each uninjured tooth, position the splint and light cure
 6. Apply a small amount of flowable or hybrid composite to the displaced/avulsed tooth, reposition it into the splint and light cure
 7. Apply another small amount of the chosen composite and light cure each tooth

After the prescribed splinting time has elapsed, splint removal should be done carefully with composite removal burs in a slow hand piece.

The AVULSED Tooth

What advice do I give over the phone when a tooth has been avulsed?

It is advisable to have in-practice training on correct telephone advice for callers ringing to report a traumatic dental injury.

- Make sure the tooth is a permanent tooth (do not replant primary teeth)
- Keep the patient calm
- Pick up the tooth by the crown (the shiny part) and avoid touching the root
- If the tooth is dirty, wash it under cold running tap water (10s max)
- Reposition tooth – hold tooth by the crown and push it gently back into the socket until it is level with the other teeth
- Encourage patient to bite on a handkerchief to keep tooth in position
- If replantation is not possible or the caller is unsure whether the tooth is a primary or secondary tooth, place the tooth in milk and bring it with the patient to the dental clinic immediately

Any type of milk may be used. If milk is not available the tooth may be stored in the buccal sulcus though care must be taken to avoid in-gestion and the tooth transferred to milk ASAP.

When should I not replant a tooth?

In most cases, replantation of an avulsed tooth is the best treatment. However, there are some cases where replantation is not appropriate:

- When tooth is a primary tooth
- When other injuries are severe and warrant preferential emergency medical treatment such as a head/eye/limb injury
- When medical history indicates that replantation would put the patient at risk i.e. a patient undergoing chemotherapy or with a cardiac defect (in this case risks/benefits of replantation will need to be carefully discussed with the patient/carer and medical team – for children immediate referral to a specialist in Paediatric Dentistry is indicated)
- When the tooth is extensively periodontally involved
- When tooth is extensively carious and unrestorable

How do I replant an avulsed tooth?

- Administer local analgesia to both buccal and palatal/lingual tissues
- Replantation without local analgesia is possible when there is minimal disruption to the socket – this will also allow quicker replantation
- Gently irrigate the socket with a syringe filled with saline to remove the clot
- Pick the tooth up by the crown
- Do not scrub or scrape the surface
- If contaminated, wash the tooth in saline and if necessary, dab with gauze soaked in saline to remove debris
- If the tooth will not replant fully – stop. Alveolar bone fragments can prevent replantation. Withdraw the tooth and place back in saline/ milk. Use a blunt instrument (such as a flat plastic) in the socket to reposition bony fragments and once again attempt replantation
- A check radiograph should be taken to ensure the root is placed correctly in the socket
- Check the occlusion



Do I need to prescribe antibiotics?

Yes! Prescribe the following antibiotics:

- If under the age of 12 prescribe amoxicillin or penicillin V 250mg, 4x/day for 7 days (28)
- If over the age of 12 prescribe Doxycycline 100mg twice/day for 7 days

A tetanus booster may be required if contamination of the tooth has occurred – if in doubt refer to a medical practitioner within 48 hours

What type of splint should I use?

Splint to one uninjured tooth either side using a physiological splint for 2 weeks days. Acid etch wire and composite splint or titanium trauma splint are recommended.

What advice should I give the patient?

- Soft diet
- Excellent oral hygiene
- Rinse with chlorhexidine mouthwash (unless allergic to chlorhexidine then use hot salty mouthwashes instead)
- Appropriate analgesia

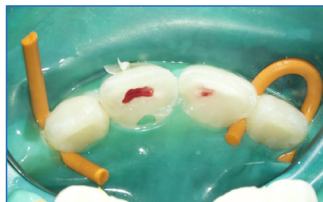Should I extirpate?

Mature teeth:

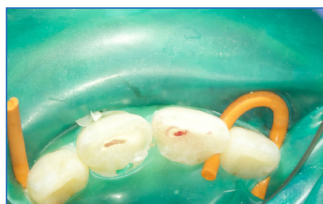- Extirpate, clean and shape prior to splint removal at 2 weeks, dress with calcium hydroxide and obturate within 1 month

Immature teeth:

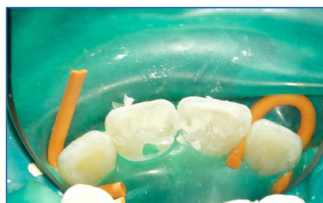Do not extirpate but monitor closely as revascularisation possible. If pulpal regeneration fails (signs of sinus, pain or periapical inflammation) extirpate and dress with non-setting calcium hydroxide. Refer if not confident managing open apices.



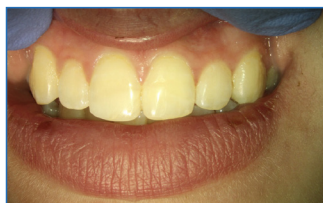Complex fracture of UL1 and UR1:
apply rubber dam



Coronal 2mm of pulp removed
and haemostasis of pulp "stump"



Biodentine placed over pulp.



Coronal fragments reattached.

The BROKEN Tooth

Treatment aims are to rebuild teeth, protect the pulp and, when necessary actively treat ex-posed pulps. Rebuilding teeth is of huge importance in the psychological well-being of patients. Long term prognosis and/or restorability can be discussed at follow-up.

Enamel dentine fracture without pulpal exposure: If the fragments are available these may be etched, bonded and reattached with resin composite, if not direct composite restorations should be used to restore form and aesthetics. Indirect pulp capping may offer little to the biological health of the tooth and minimises the surface area of tooth available for bonding which may increase the risk of failure.

Enamel dentine fracture with pulpal exposure: Exposed pulps may maintain vitality if treated correctly even if exposed for as long as 3 weeks or more. All attempts should be made to preserve vitality if the history does not suggest irreversible pulpal disease is present. Small exposures may be managed with direct pulp capping with Ca(OH)₂ but consideration should be given to partial pulpotomy especially if the exposure has been present for many days.

Cvek Partial pulpotomy technique

- Isolate with rubber dam
- Remove coronal 2mm of pulp with high speed handpiece
- Assess pulp "stump" for haemostasis. If no haemostasis, remove more tissue, rinse, dry, reassess.
- Gently flood cavity with NaOCl to decontaminate

NB: Do not use either white or grey MTA as these can significantly discolour the crown.

- Place setting Ca(OH)₂ or Biodentine over pulp to fill the cavity. (Note: Biodentine may take > 12mins to set.)
- Restore with composite and/or tooth fragments

Crown root fractures: The fractured portion often remains attached to the PDL. The fragment should be removed with tweezers and the remaining tooth assessed for restorability. Fractures not involving the pulp may often be repaired directly though gingival bleeding may prevent the use of resin based materials.

Those involving the pulp may be managed as above with partial pulpotomy but invariably require full extirpation. Subgingival margins may be left subgingival or exposed with gingivectomy or crown lengthening at a later date if the tooth is restorable.

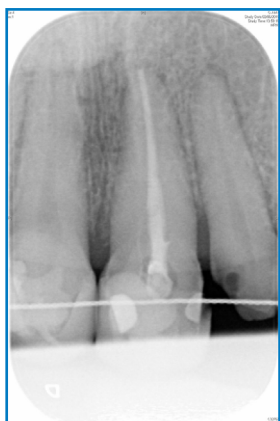
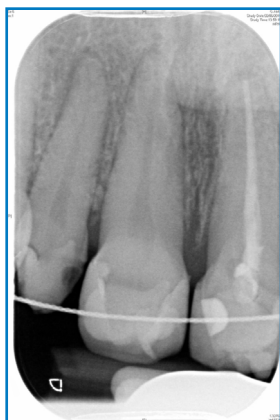Root fractures: The assumption should be that the pulp may remain healthy across the fracture. If displaced, the coronal fragment should be gently manipulated into position and splinted (4 weeks for apical 2/3, 4 months for coronal 1/3). True healing is unlikely. If the coronal fragment remains mobile after splint is removed consider long term splinting with Twistflex orthodontic wire similar to fixed ortho retention. If vitality is lost RCT should be performed only up to the fracture line. This will usually be confirmed with the apex locator giving a zero reading.

Managing injuries with delayed presentation

Many patients may present after seemingly significant delays since the original injury. This does not mean first line care cannot be provided:

- **Acute presentation:** within 1-2 hours
- **Sub acute presentation:** <24 hours post injury
- **Delayed presentation:** >24 hours post injury

INJURY TYPE	PROGNOSIS/NOTES
Enamel dentine fracture without pulpal exposure	May be managed successfully at delayed presentation without long term complications
Subluxation/Concussion	Invariably no treatment is provided for these cases other than OHI, analgesia and reassurance. A delay in access in care is not of significance.
Enamel dentine fracture with pulpal exposure	Partial pulpotomy can be performed in up to 3 weeks without sig. complication. Remove pulp tissue until there is a fresh wound and bleeding can be controlled. If pulpotomy approaches the CEJ consider full extirpation.
Crown Root Fracture	Partial pulpotomy can be performed up to 3 weeks after the injury without significant complications. Prognosis may be more intimately related to the restorability of the tooth and invariably these injuries require extraction or endo and post crown.
Root Fracture	May be repositioned up to 4 weeks later.
Avulsion	Time critical: if sub acute or delayed presentation you may consider reimplantation but the patient must be consented to very poor outcomes. This would be viewed as a short term treatment plan to support patient well being.
Lateral Luxation	Acute management optimal as often very painful/uncomfortable but considered repositioning if injury presents up to 4 weeks later.
Extrusion	Acute management optimal as often very painful/uncomfortable but considered repositioning if injury presents up to 4 weeks later.
Rapid Orthodontic Extrusion	Treatment depends upon extent of intrusion and patient preference: surgical repositioning in acute/sub-acute presentations and rapid ortho in delayed cases.



The lateral incisors show signs of apical pathology despite normal responses to sensibility testing. In the weeks following injury this should be regarded as transient apical breakdown and not periapical periodontitis.

Follow-up

General principles:

- Soft food for one week.
- Maintain optimal oral hygiene: brushing 2x/day and interdental cleaning.
- Chlorhexidine mouth washes may help reduce plaque accumulation but should be regarded as an adjunct, not alternative, to manual cleaning.
- Antibiotics: should only be considered in cases of avulsion.
- Avoid participation in contact sports
- Following splint removal it is normal for there to be residual mobility, reassure the patient and reaffirm the advice given above

Clinical follow-up:

REMEMBER THE GOAL OF TREATMENT STRATEGY SHOULD BE TO MAINTAIN THE VITALITY OF THE PULP. There should be clear evidence of pulpal necrosis before the decision is made to begin endodontic therapy. Transient apical breakdown can result in distinct radiographic changes that give the appearance of periapical osteitis despite normal sensibility test results. If suspected it is sensible to continue to monitor the tooth and defer endodontic therapy until the tooth becomes symptomatic.

A review appointment should include assessment of vitality, appearance and radiographic review. It is recommended that Endofrost is used for sensibility testing as this is much colder than ethyl chloride (-50°C).

Radiographic follow up for fracture injuries:

The Dental Trauma Guide offers injury-specific follow-up times.

See page 25 for a summary of follow-up times.

Endodontic therapy:

Initiated for all avulsion and intrusion injuries of teeth with closed apices within 7-10 days. The ambition should be full cleaning and shaping in this visit to ensure all necrotic tissue is removed and penetration of irrigants is maximised though this may not always be possible. Place an interappointment dressing of Ca(OH) for 2-4 weeks. Some proprietary brands are sold with disposable flexible "Navi-tips" to allow the clinician to inject the medicament to the desired length. This is effective and arguably safer than using lentulo-spiral spinners to place medications which may separate. The tips used for flowable composite can be friction fitted onto calcium hydroxide syringes to achieve a similar outcome! Complete obturation once the splint has been removed.

For all other injuries: only undertake endodontic treatment if there are 2 signs of loss of vitality from clinical and radiographic examination.

1. Tenderness to percussion
2. Radiographic evidence of periapical pathology
3. Non response to Endofrost sensibility testing on sequential review appointments.

Follow up times

INJURY	FOLLOW UP RADIOGRAPHS, PHOTOS AND SENSIBILITY TESTING
Concussion	1 month, 2 months, 1 year.
Subluxation	(2weeks for splint removal if placed) 1 month, 2 months, 6 months, 1 year
Infraction	No follow up required
Non complex crown fracture	2 months, 1 year
Complex crown fracture	2 months, 1 year
Crown/root fractures if tooth saved	2 months, 1 year
Root fracture	1 month (splint removal for apical 2/3 fractures), 2 months, 4 months, 6 months, 1 year, 5 years
Dento-alveolar fracture	4 weeks (splint removal), 2 months, 4 months, 6 months, 1 year, 5 years
Intrusion	2 weeks, 4 weeks (splint removal), 2 months, 4 months, 6 months, 1 year, 5 years
Extrusion	2 weeks (splint removal), 4 weeks, 2 months, 4 months, 6 months, 1 year, 5 years
Avulsion	2 weeks (splint removal), 4 weeks, 2 months, 6 months, 1 year and yearly
Lateral luxation	2 weeks, 4 weeks (splint removal), 2 months, 6 months, 1 year, yearly

Long term consequences

The Dental Trauma Guide can be used to estimate the likelihood of tooth loss, loss of vitality and risk of root resorption. Simply add the details of the injury to the trauma pathfinder and the programme will give an estimate of the risk of complications. It's important to be aware these risks may be calculated from a small cohort of patients and may not be entirely accurate but this does help communicate with the patient the importance of long term follow-up.

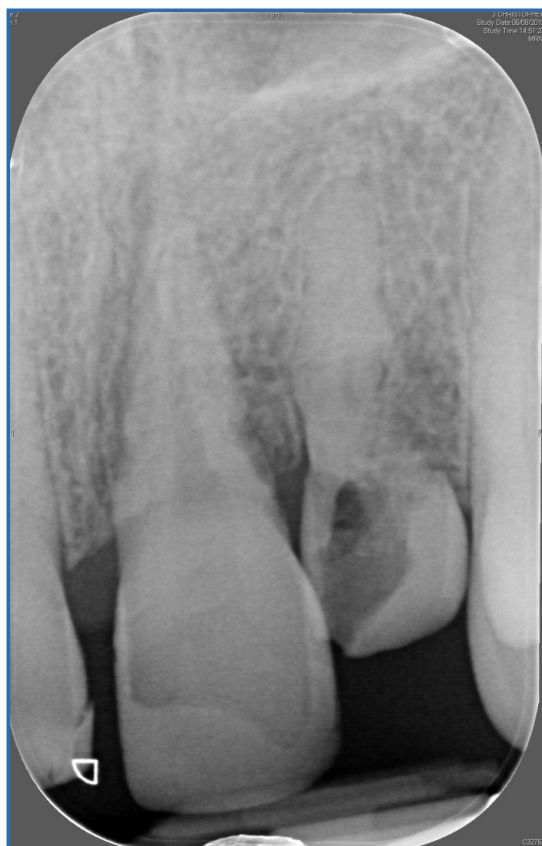Adverse effects on unerupted permanent teeth following trauma to the primary dentition

Whether the crown or the root is affected relates to the successor's stage of development, and the type and severity of injury but below 2 years of age the developing tooth germ is particularly sensitive to damage. Parents should be reassured that the likelihood of damage to the successor is minimal but often very little can be done other than watch and wait.

Alterations to eruption patterns of the permanent successor: Anticipate the possibility of both delayed or premature eruption of the successor.

Enamel discolouration / hypoplasia: A common occurrence that may vary from a mild white / brown spot to a large pitted hypoplastic defect. Likely if trauma occurs before the ages of 2-3 years. Treatment may involve a combination of bleaching, microabrasion or direct composite restorations.

Dilaceration (crown or root): Coronal dilaceration is likely if trauma occurs around 2 years of age and root dilacerations are more likely if trauma occurs between 2 and 5 years. Initial management of dilacerated crowns would be focussed upon minimally invasive whitening and resin based-approaches. Dilacerated roots may result in failure to erupt and these often have a guarded prognosis.



The UL1 has signs of external inflammatory resorption; the root surface is ragged with saucer shaped radiolucencies. The UL2 has signs of replacement resorption; the dist-cervical portion of the root has been remodelled with bone.

Adverse effects on permanent teeth following trauma

Pulpal Canal Obliteration (PCO): Hard tissue healing can result in partial or complete pulp canal obliteration. These teeth usually remain vital. Unless signs of non-vitality are noted these teeth can be monitored. The excess tertiary dentine often produces a yellow colour to these teeth and cause cosmetic concern. First line intervention should focus upon vital tooth bleaching.

Discolouration: Following trauma blood products can be released coronally into the dentine tubules leading to discolouration of the tooth. This is frequently associated with a loss of vitality although, infrequently, may be transient in the early stages of healing. Bleaching is the initial treatment option in persistent cases.

Pulpal necrosis: This is most likely in cases of avulsion or severe intrusion/extrusion, but is influenced by the maturity of the apex and open apices are more likely to remain vital. In teeth with immature apices a lack of continued root development is indicative of loss of vitality. In the initial healing period, two signs of non-vitality are required because of the high risks of false negatives from sensibility testing in traumatised teeth.

Root resorption: Trauma tends to result in either external inflammatory or external replacement resorption (ankylosis). Inflammatory resorption is driven by pulpal necrosis and RCT should be initiated. Replacement resorption follows when the root surface is so badly damaged that it becomes re-modelled during skeletal turnover. It is irreversible but can occur at differing rates and frequently depends on the age of the patient and growth development. In the growing patient, the tooth may become infra-occluded. If this occurs it should be decoronated and a prosthesis provided. This will prevent problems with alveolar development.

Though root resorption can present challenges to endodontics and sometimes need specialist level care, if suspected first stage root canal treatment (full shaping) and dressing with calcium should still be undertaken in primary care as delays in treatment can be catastrophic.

Tooth Loss & Space loss: Teeth having lost considerable amounts of tooth structure or vitality may not survive in the long term and the patient needs to be aware of this prospect. If a tooth is lost following trauma, then space can be lost rapidly; particularly in young patients. Provision of a space maintainer or immediate partial denture is crucial to prevent loss of space for futures prostheses or centreline discrepancies.

Armamentarium

The following is a list of materials that should be available if practitioners are to manage dental trauma optimally.

- Saline/ Sterile water/Chlorhexidine 0.02 %
- Dry air (3 in 1, clean and empty 10ml syringe)
- Sodium hypochlorite and calcium hydroxide paste (e.g. Hypocal)
- Tricalcium silicate material (e.g. MTA or Biodentine)
- Acid Etch, bond and composite and light curing unit OR Self cure composite
- Steel archwire (0.7mm) or Titanium Trauma Spint, wire cutters and wire bending plier
- Extraction forceps
- 3-0 or 4-0 Vicryl Rapide (or other resorbable suture) suture
- Non braided monofilament nylon or polypropylene such as Prolene

Clinical camera (for more information www.thedigitaldentist.co.uk)

For hospital based dentists and core trainees access to the right equipment at the right time can be difficult but should not be! When starting posts locate your trauma kit and ensure it is fully stocked. It is your responsibility to ensure you can deal with trauma appropriately. If your department is not prepared for trauma use the trust incident reporting system to raise your concerns and take control

Go to this useful article on the MaxFacs Toolbox for what you will need:

www.dental-update.co.uk/issuesSingleIssueArticle.asp?aKey=1290.

When to refer

Urgent referrals:

It is essential to attempt management of all injuries immediately. Delays in treatment can result in catastrophic outcomes for patients. As such it is expected that all practitioners should be competent in the diagnosis and management of traumatic injuries.

Nonetheless there are certain injuries that may be more challenging to manage, most notably:

- **Dento-alveolar fractures**
- **Intrusive injuries**

Both of these can require significant repositioning and referral may be advisable. For all other injuries the GDP should attempt repositioning and/or reconstruction.

Following splinting two key questions should be asked:

- **Is the tooth in the right place?**
- **Is the tooth the right shape?**

If these cannot be achieved consider referral for a second opinion. Other important factors to determine acute referral include:

- **Suspected head injury: A&E**
- **Extra-oral soft tissue lacerations/damage with risk of scarring: PLASTICS / MAXFACS**
- **Complexity of diagnosis; If there is doubt about the correct diagnosis/diagnoses:**
 - **Out of hours: local urgent care provider**
 - **In hours Manchester Dental Hospital 0161 393 7730**

Delayed referrals:

- If there is any doubt about the length of time since the trauma and thus what the most appropriate treatment option may be contact Manchester Dental Hospital on 0161 393 7730.
- Adult restorative referrals will be accepted for consultation and treatment planning for: loss of vitality and pulp canal obliteration, evidence of root resorption, assessments of restorability/management of root and crown-root fractures and loss of teeth.

Missing teeth:

Trauma will be prioritised along with our cancer, cleft and hypodontia patients. Under current arrangements with NHS England implant funding is only supported if more than one tooth is lost. If a single tooth is lost a case may be made in exceptional circumstances when a space cannot be restored by conventional means. This could be when there are multiple diastemata, preventing fixed bridge work, or when adjacent teeth are compromised and would not make for suitable abutments. Though we cannot guarantee funding we will always accept referrals for second opinions and treatment planning. **WE ARE HERE TO HELP!**

Non-accidental injury

The General Dental Council states that all members of the dental team have an ethical obligation to take appropriate action if concerned about the possible abuse of a child and to ensure that children are not at risk from members of our own profession by following safe staff recruitment policies.

The CQC states GDPs should have at least level 2 safeguarding and this should be renewed every 3 years.

Assessing a child with an injury with possible signs of abuse or neglect starts with a thorough history focussing upon:

- Details from the child and carer of the mechanism of injury
- Previous history of injuries that may be unexplained
- Social history – particularly in relation to unrelated adults living at home with the patient
- Full examination including dental, oral or facial injuries including site and extent
- The general appearance of the child, their state of hygiene, whether they appear to be growing well or failing to thrive
- Their demeanour with parents – are they interacting well or do they have a “frozen stare” where they take in everything going on but in a wary, fearful way.

What features would be of concern?

- A direct allegation (disclosure) may be made by the child/parent/another person
- Delayed presentation of injury (may be suggestive of neglect)
- Discrepancy between history and clinical findings
- Developmentally inappropriate findings i.e. history of fall in child not yet mobile
- Previous concerns about the child or siblings
- Concerns about the general or mental health of the parent (alcohol, substance misuse)

What should I do if I suspect dental neglect or abuse of children or adults?

Doing nothing is not an option

If neglect is suspected it is best practice to inform the parents/guardians that you are concerned and will be making contact with social services. If appropriate reinforce that this may not necessarily be because their parenting is poor but because you feel they may be in need of some support. If abuse is suspected you have no obligation to inform the parents/guardians but it may be sensible to do so. If you feel the child/adults immediate health is in jeopardy call the police on 999. For all other inquiries follow the pathways identified by your local safeguarding agency below.

Bolton

www.bolton.gov.uk/website/pages/Safeguardingandprotecting.aspx

Bury

www.buryccg.nhs.uk/your-local-nhs/Our-plans/Safeguarding.aspx

Heywood Middleton and Rochdale

www.hmr.nhs.uk/index.php/services/safeguarding

Manchester (Citywide)

www.manchestersafeguardingboards.co.uk

Salford

www.salfordccg.nhs.uk/about-safeguarding

Stockport

www.stockport.nhs.uk/serviceview/28/safeguarding

Oldham

www.oldham.gov.uk/info/200801/report_a_concern_or_abuse

Trafford

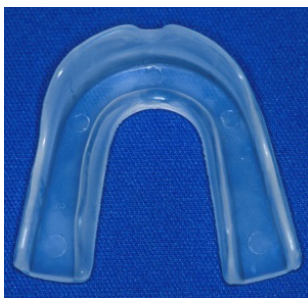www.traffordccg.nhs.uk/safeguarding/

Tameside

www.tamesideandglossopccg.org/your-health/safeguarding

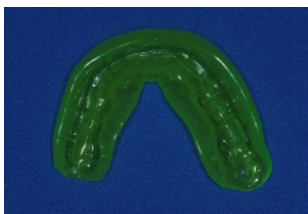Wigan

www.wiganboroughccg.nhs.uk/here-to-help/safeguarding



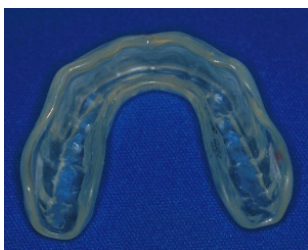Type 1: Bite to hold.

Not recommended.



Type 2: Boil and bite.

Not recommended unless undergoing ortho Tx



Type 3: Custom fabricated.

Prevention of Trauma

There are two groups of higher risk individuals who may be more susceptible to dental trauma. These should be identified and attempts made to reduce their risk with the construction of mouth guards.

- Patients partaking in contact sports: principally these are sports which involve physical contact between players including boxing, rugby, hockey and mixed martial arts but mouth guards should also be considered for any sort of activity which risks injury to the teeth such as lacrosse and horse riding etc. There are many sports organisation across the UK which have a "No guard No play" policy ensuring the safety of their members.
- Patients with increased overjets: It is essential these patients are identified and early referral for orthodontic assessment made. An overjet greater than 6mm gives an IOTN Dental Health Component (DHC) score of 4, and an overjet greater than 9mm gives a DHC score of 5, meaning that the patient is eligible for NHS orthodontic treatment under current contracting arrangements. To correct what is often an underlying skeletal base discrepancy interceptive orthodontics with functional appliances should be considered and thus referral prepuberty (10-11 for girls and 11-12 for boys) is important. Additional protection should be provided until this can be corrected; (up to 50% of patients with an overjet > 9mm will suffer some type of trauma).

Mouth guards:

A custom fitted mouth guard is a safe, cost effective way in the short and long term to protect the teeth and its supporting structures from trauma. As dental professionals there is a duty of care upon us to encourage our patients to wear them and promote their use to the public.

- Stock (Type 1) These are inexpensive and be purchased over the counter from sport shops or high street pharmacies. They come as a rigid plastic in various stock sizes and are held in place by the wearer constantly biting into the plastic for retention and are otherwise loose. They may interfere with speaking and have been known to risk the airway. Cases reports suggest these may only off minimal protection against trauma.
- Boil and Bite (Type 2) These are also available on the high street. They consist of a thermoplastic material that is heated in warm water and moulded to the person's mouth at home. Due to their low temperature of formation the retention and thickness in the mouth continues to decrease making it a poor type of mouth guard and reduces its overall protection. Some professionals feel that type 1 and type 2 mouth guards should be banned from use in sports.
- Custom made (Type 3) This is the gold standard of mouth guards. Laboratory tests have also shown these to be far superior to other forms of mouth guards in preventing dento-alveolar trauma. In addition, the mouthguard will create space between the condylar head and the glenoid fossa which may minimise condylar head concussion or even fracture. They are constructed from layers of thermoplastic ethylene vinyl acetate (EVA) which is vacuum formed over study models and extended distal to the first molars. Up to 5mm of multiple layers should be prescribed in the anterior segment to increase protection.
- Bi-maxillary mouth guards: These can provide improved protection as they cover both arches with the mandible opened at a predetermined level. They provide extra protection from frontal and lateral impact to the mandible and reduce forces on temporomandibular joint. They are however expensive and difficult to construct plus they may cause a sensation of dry mouth and difficulty in speaking.



Mouth guards and the orthodontic patient:

During orthodontic treatment the consequences of trauma may be multiplied with teeth that have greater mobility and arch wires and brackets presenting greater risk to soft tissue trauma. Custom mouth guards cannot be made as there is an inherent requirement to allow orthodontic tooth movement. For these patients a pragmatic decision must be made simple Type 1 mouth guards are the most appropriate by offering some protection without compromising the orthodontic treatment. www.shockdoctor.co.uk and search braces mouth guard.

Additional information:

Several studies have recommended that patients involved in sports should have their mouth guards changed after a period of time generally one-two years depending on their use. Children however should have theirs changed annually due to changes in growth of the jaws and teeth and parents should be informed of this prior to any fabrication of a mouthguard.

In the UK the NHS does not cover the fee for mouth guards for any patients so this is provided on a private fee basis. This does create more of a barrier for patients to invest in such an important aid for prevention of trauma and its sequelae.

The dentist should use appointments with patients to question whether they are involved in any type of sports and explain the benefits of wearing such as an appliance with aid of pictures and the damaging effects of what trauma can do to the teeth and mouth if a mouthguard is not worn. All discussion should be noted for medico-legal reasons.

www.dentaltrauma.co.uk

For further information readers are directed to the charity dental trauma UK.
There is information for both public and professions including:

1. Downloadable POSTERS on the management of dental trauma with the “Pick it, lick it, stick it” campaign.
2. Extensive information about the use of mouth guards to prevent injuries including details on the differing options including boil and bite, non-mouldable and custom fit mouth guards.
3. Self help videos for patients on the acute management of dental trauma.

For the dental team membership to the charity offers:

1. Discount rates for the annual conference.
2. Free CPD including recordings of all the lectures from previous conferences.
3. How-to videos on splinting and management of avulsed and laterally luxated teeth.
4. Patient information leaflets for the practice.
5. Discussion forums and access to specialist advice and support.



Additional reference material

Epidemiology:

Andreasen J. Etiology and pathogenesis of traumatic dental injuries: A clinical study of 1,298 cases. Scand J Dent Res. 1970; 78: 329-42

Bastone E, Freer T, McNamara J. Epidemiology of Dental Trauma: A review of the literature, Australian Dent J 2000;45(1):2-9

Glendor UL. Aetiology and risk factors related to traumatic dental injuries—a review of the literature. Dental Traumatol. 2009;25(1):19-31.

Perez R, et al. Dental Trauma in Children; a survey. Dent Traumatol 2001;7:212-213

Diagnosis and Record Keeping:

Andreasen FM, Kahler B. Diagnosis of acute dental trauma: the importance of standardized documentation: a review. Dent Traumatol. 2015;31(5):340-9.

Management:

www.dentaltraumaguide.org

Andersson L, et al. International Association of Dental Traumatology guidelines for the management of traumatic dental injuries: 2. Avulsion of permanent teeth. Dent Traumatol 2012;28:88-96

Cvek M. A clinical report on partial pulpotomy and capping with calcium hydroxide in permanent incisors with complicated crown fracture. J Endod. 1978;4(8):232-7.

Day P.F. Gregg T.A. Treatment of avulsed permanent teeth in children. British Society of Paediatric Dentistry available at: http://bspd.co.uk/Portals/0/Public/Files/Guidelines/avulsion_guidelines_v7_final_.pdf

Jeeruphan T, et al. Mahidol study 1: comparison of radiographic and survival outcomes of immature teeth treated with either regenerative endodontic or apexification methods: a retrospective study. J Endod. 2012; 38(10):1330-6.

McCabe PS, Dummer PM. Pulp canal obliteration: an endodontic diagnosis and treatment challenge. Int Endod J. 2012; 45(2):177-97.

Mente J, et al. Treatment outcome of mineral trioxide aggregate in open apex teeth. J Endod 2013;39(1):20-6.

Mohammadi Z. Strategies to manage permanent non vital teeth with open apices: a clinical update. Int Dent J. 2011;61(1):25-30.

Simon S, Smith AJ. Regenerative endodontics. Brit Dent J. 2014;216(6):E13.

Torabinejad M, Chivian N. Clinical applications of mineral trioxide aggregate. J Endod. 1999;25(3):197-205.

Yassen GH, Platt JA. The effect of nonsetting calcium hydroxide on root fracture and mechanical properties of radicular dentine: a systematic review. Int Endod J 2013;46(2):112-8.

Splinting:

www.dentaltraumaguide.org

von Arx T, Filippi A, Buser D. Splinting of traumatised teeth with a new device: TTS (Titanium Trauma Splint) Dent Traumatol 2001;17:180-184

Protection of vulnerable children and adults:

Adult safe guarding e-learning (free sign up required)

available at: <https://www.scie.org.uk/assets/elearning/adult-safeguarding/web/#/index>

Child protection and the dental team website available at: <https://www.bda.org/childprotection>

Every child matters available at: <https://www.education.gov.uk/consultations/downloadableDocs/EveryChildMatters.pdf>

Harris J.C., Balmer R.C., and Sidebotham P.D. British Society of Paediatric Dentistry: a policy document on dental neglect in children. Int J Paediatr Dent 2009.

Working together to safeguard children. A guide to inter-agency working to safe guard and promote the welfare of children March 2015 available at: https://www.gov.uk/government/uploads/system/uploads/attachment_data/file/419595/Working_Together_to_Safeguard_Children.pdf

Outcomes & Long term Consequences:

Andreasen FM, Kahler B. Pulpal response after acute dental injury in the permanent dentition: clinical implications—a review. J endod. 2015;41(3):299-308.

Andreasen JO, et al. Effect of treatment delay upon pulp and periodontal healing of traumatic dental injuries—a review article. Dent Traumatol. 2002;18(3):116-28.

Darcey J, Qualtrough A. Resorption: part 1. Pathology, classification and aetiology. Br Dent J. 2013; 214(9):4 39-51.

Darcey J, Qualtrough A. Resorption: part 2. Diagnosis and management. Br Dent J. 2013; 214(10): 493-509.

Diab M, ElBadrawy HE. Intrusion injuries of primary incisors. Part III: Effects on the permanent successors. Quintessence International. 2000; 31(6):377-84

Dental Trauma History Sheet

Complaint

History of presenting complaint

Time of accident

History of trauma

Loss of consciousness Y/N

☐

Headache Y/N

☐

Vomiting Y/N

☐

Tetanus Status

Previous Trauma

Attendance at A&E Y/N

☐

Where

Emergency Treatment Y/N

What

Relevant Medical History

Past Dental History

Dental examination:

Displacement injuries?

Fractures?

Radiographs?

Report

Diagnosis/diagnoses

Treatment Undertaken

Extra Oral Examination

TMJ

Facial Asymmetry

Lymph Nodes

Lips

Lacerations

Contusions

Swellings

Bony Displacements

Intra Oral Examination

Soft Tissues

Throat

Tongue

Floor of Mouth

Mucosa

Gingivae

Follow up date:



Review Appointments

Date:

Saving Smiles
Improving Dental Trauma

Presenting complaints/problems since last visit;

2 weeks ☐

1 month ☐

3 months ☐

6 months ☐

9 months ☐

12 months ☐

Other (please state)

Presenting complaints/problems since last visit;

MAXILLA

TTP Y/N													
Colour Change Y/N													
Mobility O-III													
Sensibility +/-													
	6	5	4	3	2	1	1	2	3	4	5	6	
Sensibility +/-													
Mobility O-III													
Colour Change Y/N													
TTP Y/N													

Radiographs taken?

Radiographic report

Splint removal required?

Treatment undertaken

Follow up date:

Saving Smiles Avulsion Pathway (Page 20)

Telephone Triage?

- Only reimplant adult teeth
- Pick up by the crown
- Rinse under tap (10 seconds)
- Gently reposition tooth
- Apply pressure and attend GDP
- If not possible to reimplant place in milk and attend GDP

Key History (page 6)

How, when, where, what?
Inconsistency in account and nature of injury: Suspect NAI?
Refer to local safeguarding unit

Refer to A&E (page 10)

If history of loss of consciousness, nausea, vomiting, amnesia, extra-oral lacerations with risk of scarring (5)

Post Op Instructions

Soft diet for 2 weeks, avoid contact sports, brush teeth as normal +/- 0.2% CHX mouth wash (17)

Antibiotics Regimen

<12 years pen V tabs 250mg QDS 28
> 12 years Doxycycline caps 100 mg BD 14

Tooth already reimplanted?

Confirm correct position clinically and radiographically and splint as below

DO NOT REIMPLANT IF

1. Primary tooth
2. Extensively periodontally involved or surrounding dentition mutilated

Avulsed permanent tooth (open or closed)

EO time < 60mins

> 60 mins

If available bathe in 2% sodium fluoride for 20 minutes

LA, Irrigate and examine socket for alveolar fracture and reimplant

Check radiograph, occlusion and aesthetics

Splint 2 weeks (page 18)

Splint 4 weeks (page 18)

Open apex: avoid endo unless clinical and radiographic loss of vitality @ review. Extirpate if EO time > 60mins. If loss of vitality in child patient, open, dress with Ca(OH)₂ & refer to local paediatric department
Closed apex: Begin RCT within 7-10 days (full clean and shape and Ca(OH)₂ dressing) & obturate in 4 weeks.

Tooth not reimplantable or lost:

> 1 tooth lost? Refer to DH for implant planning & funding application
Single teeth are not currently funded for implants.

Follow-up radiographs + clinic exam @ (page 24)

1 Month

2 Months

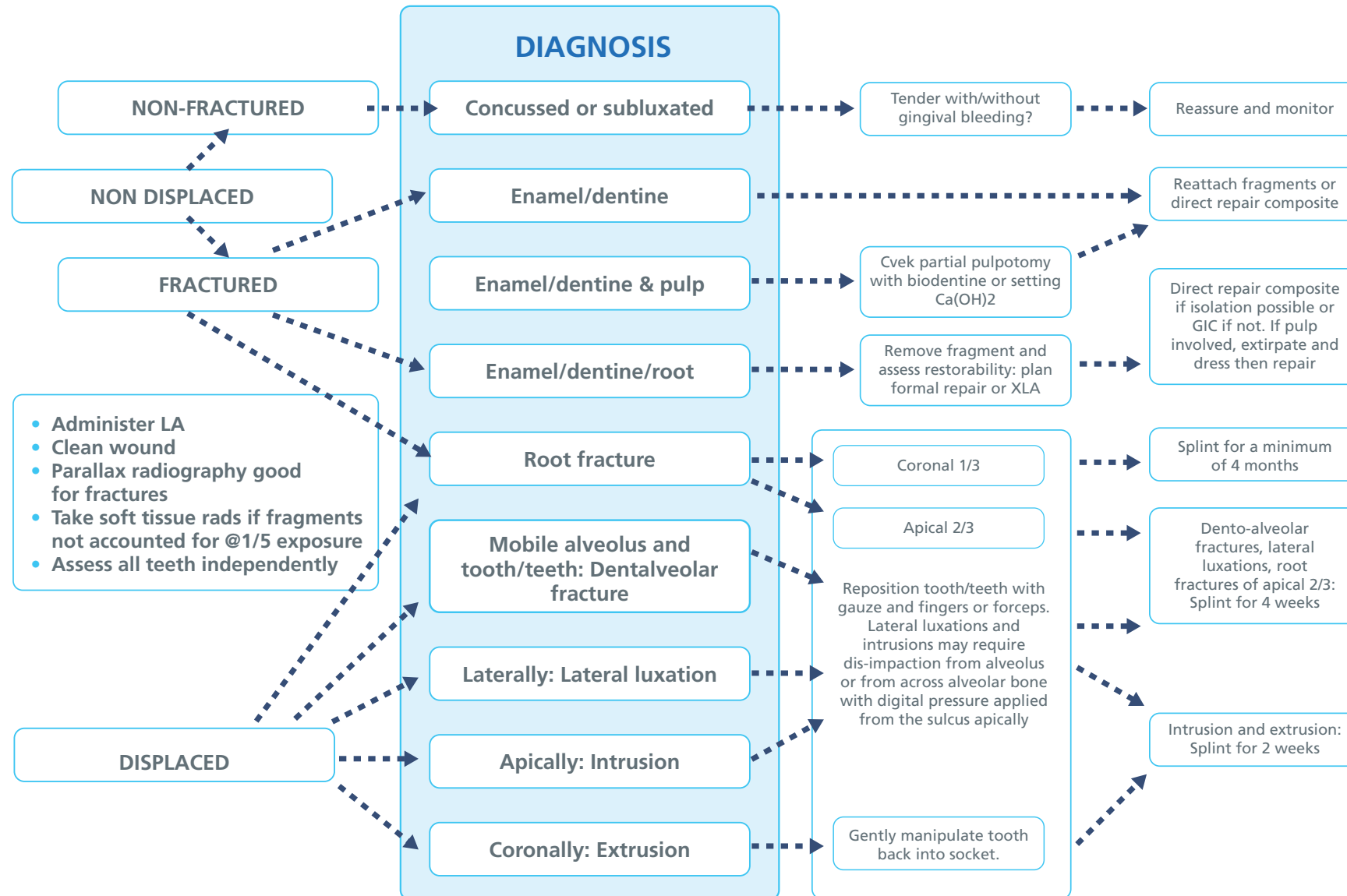
6 Months

1 year & yearly

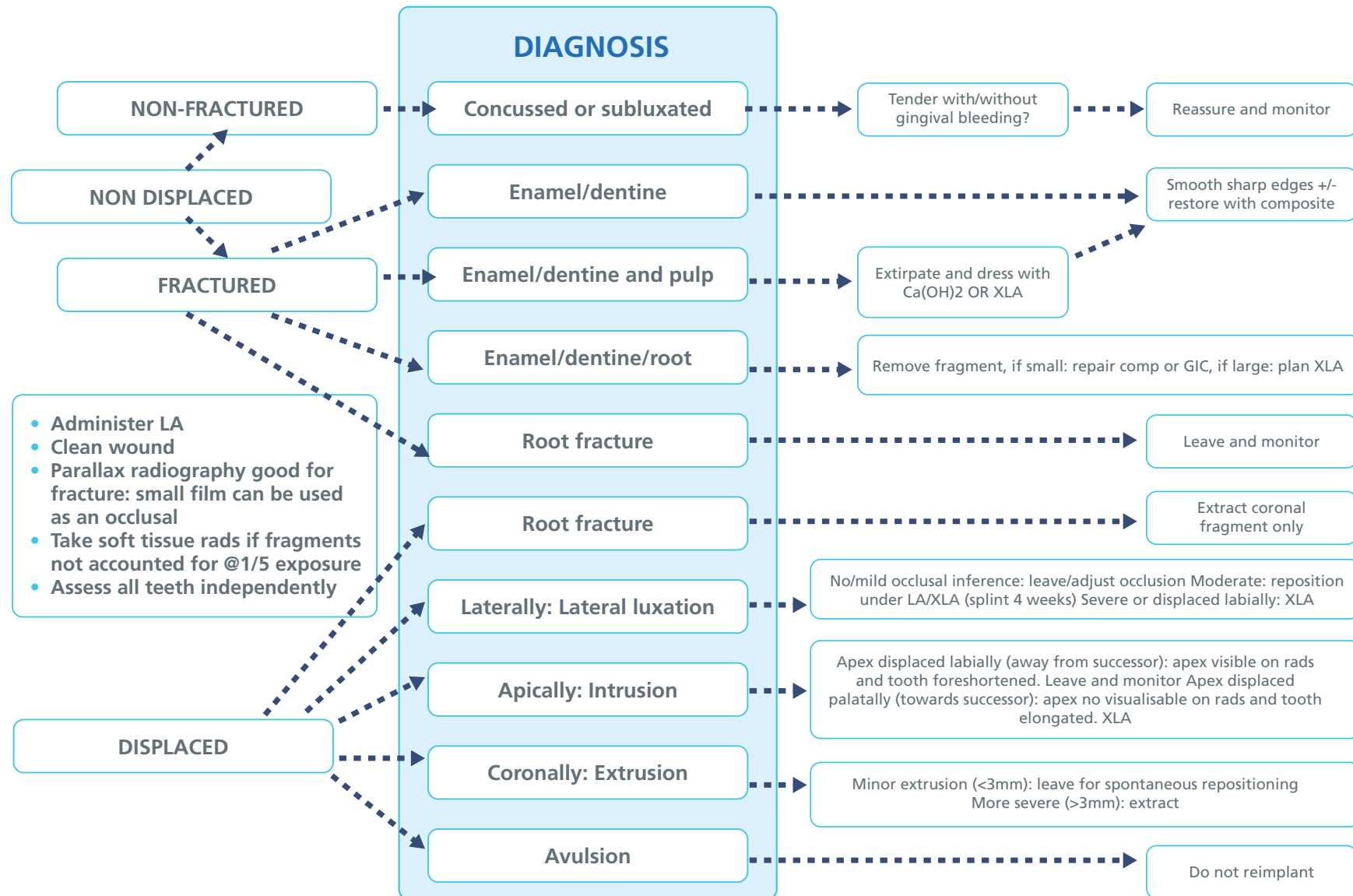
Assess for: Discolouration, loss of vitality (open apex), root resorption? (page 26)

Refer for complex endo: pulp canal obliteration, root resorption, open apices and/or behavioural factors

Saving Smiles: Fractures and Displacements (page 22)



Saving Smiles: Fractures and Displacements in the primary dentition



Acknowledgements

Editor

James Darcey, Chair of the GM Dental Trauma Network and Consultant in Restorative Dentistry, Manchester Dental Hospital

Contributing authors

Siobhan Barry, Consultant in Paediatric Dentistry

Imran Asghar, General Dental Practitioner

Stuart Clarke, Consultant in Oral and Maxillofacial Surgery

Deborah Moore, Specialty Registrar in Dental Public Health

Pippa Cullingham, Specialist in Oral Surgery

Peter Clarke, Specialty Registrar in Restorative Dentistry

GM Local Dental Network (LDN)

Trauma Network Members

Anthony Doggett, Deborah Moore, Elaine Hawthorn, Martin Ashley, Alison Qualtrough, David Read, Don McGrath, Gill Davies, Hilary Whitehead, Ian Sproat, Kirsten Sedgwick, Matt Tushingham, Phil Dawson, Peter Doorey, Susan Ellis, Brian Rosenberg, Lindsey Bowes, Colette Bridgman & Adrian Moss

With comments and contributions gratefully received from

(external advisors who have given a specific piece of advice or input but who may not have attended meetings)

Yvonne Daley

Supported by

Greater Manchester Health and Social Care Partnership

Public Health England North West Centre

Health Education North West

GM Local Dental Network and Dental Advisory Group



Saving Smiles

Improving outcomes
following dental trauma

Greater Manchester Local Dental Network

Saving Smiles
Improving outcomes
following dental trauma



First Edition | Spring 2017