

## ROLE OF MRI IN THE DIAGNOSIS OF TRAUMATIC INJURIES OF MENISCI AND CRUCIATE LIGAMENTS IN KNEE COMPARED WITH ARTHROSCOPY

Hiba Samaan Madani<sup>1</sup>, Faisal Nasser<sup>2</sup>, Safwan Yousif<sup>3</sup>

1. Resident, Department of Radiology, Tishreen University, Faculty of Medicine, Lattakia, Syria.

2. Professor, Department of Radiology, Tishreen University, Faculty of Medicine, Lattakia, Syria.

3. Associated Professor, Department of Orthopedic surgery, Tishreen University, Faculty of Medicine, Lattakia, Syria.

### ABSTRACT:

**Aim:** To study the role of MRI in the diagnosis of injuries of menisci and cruciate ligaments in knee, compared with arthroscopy. And to assess sensitivity, specificity, positive predictive value (PPV), Negative predictive value (NPV) and accuracy of MRI.

**Material and Methods:** This was a cross-sectional analytic study, performed at Tishreen University Hospital in Lattakia, Syria during 14 months. The study included 51 knees (33 males and 18 females), who were clinically suspected of tears of menisci or cruciate ligaments. A MRI scan, arthroscopy and the statistical study was performed, as arthroscopy was considered as the gold standard.

**Results:** The sensitivity, specificity, accuracy, PPV and NPV for medial meniscus were 86.21%, 2.73%, 80.39%, 80.63%, 80%. And for lateral meniscus were 83.33%, 97.78%, 96.08%, 83.33%, 97.78%. For anterior cruciate ligament were 100%, 80.63%, 88.24%, 76.92%, 100%. And in posterior cruciate ligament they were all 100%.

**Conclusion:** MRI is a non-invasive diagnostic tool with high sensitivity, specificity, accuracy, PPV and NPV. So its role has increased in diagnosing of tears of menisci and cruciate ligaments in the knee, resulting in decreased in the diagnostic use of arthroscopy.

**Keywords:** knee MRI, arthroscopy, menisci injuries, cruciate ligaments injuries.



### INTRODUCTION:

The knee joint is an important joint in the body due to its role in the stability and movement, and it is more likely to be injured than the rest joints of the body, because it handles big forces during the motor activity.

Recently, there has been progress in imaging techniques and imaging in the detection of knee injuries. However, arthroscopy is still the gold standard because it can provide a direct view of the joint and its structure.<sup>[1]</sup>

One of the new imaging methods that can detect soft tissue injuries is magnetic resonance imaging (MRI). There is an increased use in the diagnosis of knee injuries before the laparoscopy and surgery.<sup>[2]</sup>

Where MRI is a non-invasive, radiation-free method with a better ability to evaluate soft tissue. Arthroscopy has a diagnostic accuracy ranging from 64 to 94%, but is a surgical procedure which is invasive and is associated with complications.<sup>[3]</sup>

Sports injuries are the leading cause with an incidence of meniscal damage in approximately 9/1000 men and 4.2 / 1000 women.<sup>[4]</sup>

Traumatic fissures, which occur in a healthy meniscus and in young people, are the most common lesions 68 to 75% , which can be distinguished from microtraumatic fissures in a degenerative meniscus, which is constantly increasing in incidence in “mature” older sportsmen and women.<sup>[5,6]</sup>

Anterior cruciate ligaments tears are common sport injuries. The mid-substance of the anterior cruciate ligament is injured more frequently than the distal or proximal portions.<sup>[7]</sup>

Posterior cruciate ligament tears are uncommon. Nearly every 50 ACL tears versus one PCL tear.<sup>[8]</sup> Partial intra-substance ruptures of the PCL are more common than complete tears and avulsion.<sup>[7]</sup>

The aim of this study was to determine the role of MRI in the diagnosis of injuries of menisci and cruciate ligaments in knee, as a non-invasive and less expensive method compared with arthroscopy. And to assess sensitivity, specificity, positive predictive value (PPV), Negative predictive value (NPV) and accuracy of MRI.

## **MATERIALS AND METHODS:**

### **Study population:**

This was a cross-sectional analytic study performed at Tishreen University Hospital in Lattakia, Syria. This institutional study was approved by ethics review committee of Scientific Research Council of our institute, the decision number of the approval is (ID: 1337). It was performed during 14 months from June 2017 to August 2018 . The study included 50 patients (51 knees), divided to 33 males and 18 females, who were clinically suspected of tears of menisci or cruciate ligaments in the knee. For example pain, crackle, locking, , instability , swollen. And informed consent has been obtained from patients who participated in this clinical study.

### **X-ray:**

A plain x-ray has performed to the patient's knee, in order to detect bony injuries.

### **MRI technique:**

MRI was performed using (Siemens, 1.5 Tesla) and multiple slices were obtained with small field of view = 16 cm , the Matrix is standard of 256× 256 , the thickness of 4 mm, the inter slice gap of 1 mm. The sequences that were obtained are: Proton density, PD fat sat, T1- and T2-weighted images in sagittal plane, STIR sequence in the coronal plane, and T2-weighted images in axial plane.

In menisci, any signal within the meniscus was considered abnormal. And this is a grading scale for meniscal signal: Grade 1, rounded or amorphous signal that does

not disrupt an articular surface. Grade 2, linear signal that does not disrupt an articular surface. Grade 3, rounded or linear signal that disrupts an articular surface. Grades 1 and 2 are intra-substance degeneration and should not be reported as tears, and grade 3 is a meniscal tear.<sup>[9]</sup> (Fig. 1 and 2)

For anterior cruciate ligament, the MRI appearance of an ACL tear varies according to the extent and chronicity of the injury. Complete tears appear as discontinuity of the fibers, increased signal and/or laxity (Fig. 3). Partial tears of the ACL are recognized on MRI by altered signal and/or laxity in the presence of continuity of some fibers.<sup>[7]</sup> (Fig. 4) Acute tear appears as a fairly diffuse mass of reactive edema and hemorrhage.<sup>[8]</sup> In the chronic tear, the distal end is no longer vascularized, the edema disappears gradually.<sup>[10]</sup> (Fig. 5). The residual ligament fibers atrophy and the ACL remains retracted. Typically, a discontinuous ACL is seen which is variable in thickness without edema.<sup>[11,12]</sup> The presence and angular orientation of a residual scar produces an irregular thickening appearance of ACL giving it a falsely normal appearance.<sup>[12]</sup>

And for posterior cruciate ligament, the complete tear results in an abnormal hyper intensity of T2-weighted images combined with a discontinuous appearance of the fibers [13,14] (Fig. 6). Partial intra-substance tears exhibit thickening and altered signal on MRI while usually maintaining the appearance

of a continuous structure.<sup>[7]</sup> The normal PCL is 6 mm or less in diameter as measured on sagittal images. When torn, it is almost always thicker than 7 mm (Fig. 7).<sup>[9]</sup>

#### ***Arthroscopy technique:***

Arthroscopies were performed using STORZ, Germany device, via two inferior parapatellar portals under general anesthesia.

Then a comparison between the MRI results and the arthroscopy results was performed. Arthroscopic findings were considered as the gold standard.

#### ***The statistical analysis:***

It was performed in two phases: Description Statistical , and Inferential Statistical using IBM SPSS statistics. sensitivity, Specificity, positive and negative predictive value and accuracy of MRI were done, as arthroscopy was considered as the gold standard.

2010, Microsoft Corp, Washington) and imported to Statistical Package for Social Sciences (SPSS for Windows, version 16.0, SPSS Inc., Chicago, IL, USA) for analysis. Descriptive statistics including proportions, means and standard deviations were estimated. Chi-square test and Independent sample t test with significance level kept at  $P < 0.05$  was performed to compare the proportions and means respectively. Pearson correlations between Quality of life score and sub domains in children with and without TDI were done.

## RESULTS:

The study included 51 patients aged between 20-40 years with an average age of  $32.7 \pm 6.6$  years. The patients were divided into 33 males (64.70%) and 18 females (35,30%), Sex Ratio (M: F) = 1.8: 1 . The study showed injuries of 29 right knee (56.86%), and 22 left knee (28.4%).

There were 25 injuries of menisci (49%), 3 injuries of cruciate ligaments (6%), and 23 injuries of menisci and cruciate ligaments together (45%).

There were 48 injuries of menisci divided into 33 injuries of medial menisci (68.75%), 5 injuries of lateral menisci (10.4%), and 10 injuries of medial and lateral menisci together (20.8%). The most injuries were in the posterior horn of the medial menisci (30 injuries) (62.5%).

There were 26 injuries of cruciate ligaments divided into 24 of the anterior cruciate ligament (92.3%) , and 2 injuries of the anterior and posterior cruciate ligaments (7.7%), and no injury of the posterior ligament was reported.

For the anterior cruciate ligament, 15 injuries of partial tear were recorded (57.7%) and 9 injuries of complete tear (34.6%). And for the posterior cruciate ligament, two injuries of partial tear (7.7%) were recorded, and no complete tear was recorded.

The sensitivity , specificity , accuracy , PPV and NPV are explained in this schedule: (table 1)

## DISCUSSION:

The study showed that males injury was more common than females injury by 65%. And the right knee injury was more common than the left knee injury (57%). Menisci injury is more common than cruciate ligaments injury (49%), and isolated cruciate ligaments injury is as little as 6%, as it is more common with menisci injury.

For the injury of menisci, the majority of cases of medial meniscus 69%. The incidence of lateral meniscus was less than 10%, and the incidence was more common with the medial meniscus. In menisci injuries, the posterior horn of the medial meniscus is the most common injury at 63%. The anterior horn has not recorded any isolated injury.

For cruciate ligaments injury, the majority of injuries were in the anterior cruciate ligament by 93%. The posterior cruciate ligament injury was rare (only 2 cases) and was associated with anterior cruciate ligament injury, with no isolated injury to the posterior cruciate ligament. The partial tear of the anterior cruciate ligament was more common than complete tear and was 58%, and the same was for the posterior cruciate ligament.

Seven false positive cases and 5 false negative cases were recorded in the

menisci tears, which can be explained by that in some cases it was difficult to determine whether the high signal reached the articular surface or did not reach.

In contrast, 6 false positive cases were recorded and no false negative cases was recorded in the cruciate ligaments tears, which was often in the partial tears of the anterior cruciate ligament.

The sensitivity of MRI in medial meniscus injuries was 86.21%, specificity 72.73%, accuracy 80.39%, PPV 80.63%, and NPV 80%. These results are similar to those of a British study performed in 2008 (Vassilios S Nikolaou, et al.)<sup>[15]</sup> where sensitivity were 83%, specificity 69%, accuracy 81%, PPV 83%, and NPV 69%.

For lateral meniscus, sensitivity was 83.33%, specificity was 97.78%, accuracy was 96.08%, PPV was 83.33%, NPV was 97.78%. These results are similar to the results of a Pakistani study performed in 2008 (Khanda, G. et al.)<sup>[16]</sup> where the sensitivity was 87.5%, the specificity 88.23%, the accuracy 88%, the PPV 77% and the NPV 93%.

The anterior cruciate ligament has 100% sensitivity, 80.63% specificity, 88.24% accuracy, PPV 76.92%, and NPV 100%. These results are similar to the results of an Indian study in 2018 (Pawan Shaw, et al.)<sup>[17]</sup>. Sensitivity was 100%, specificity 66.67%, accuracy 95.52%, PPV 95.08% and NPV 100%.

For the posterior cruciate ligament all values were 100%. These results are the same of the results of a German study performed in 2018 (Johannes Walter Schnaiter, et al.)<sup>[18]</sup> where all values were 100%.

This study has limitations. It has a small population. It is possible that many of these lesions may have been missed due to the small size. Additionally, arthroscopy was not available in some cases, so we had to exclude them from the study.

## CONCLUSION:

Our study showed high values for the sensitivity, specificity and accuracy of MRI in the diagnosis of menisci and cruciate ligaments tears, which should lead to decrease the diagnostic use of arthroscopy. Since the false negative of MRI is low, so it can prevent unnecessary surgical arthroscopy in the case of normal MRI of the knee. However, MRI is less sensitive in the partial tear of the anterior cruciate ligament.

Following the appropriate protocol in MRI has a big role in the correct diagnosis:

- T1 is important in the anatomical structures.
- T2 is more sensitive to the diagnosis of ligament and menisci tears.
- T1 and PD are important to detect tears of menisci.
- menisci examination is easier in fat sat in T1 or in PD, we followed PDFS

- in our study and it showed better detection tears.
- STIR is important in detecting associated bone injuries.

## REFERENCES:

1. Karim Z, et al. Validation and reproducibility of ultrasonography in the detection of synovitis in the knee: A comparison with arthroscopy and clinical examination. *Arthritis Rheum.* 2004; 50:387–94.
2. Rastegar S, et al. Where does magnetic resonance imaging stand in the diagnosis of knee injuries?. *J Res Med Sci.* 2016 Jul 29;21:52.
3. Remer EM, et al. Anterior cruciate ligament injury: MR imaging diagnosis and patterns of injury. *Radiographics.* 1992; 12(5):901–11.
4. Hede A, et al. Epidemiology of meniscal lesions in the knee, 1215 open operations in Copenhagen 1982–84. *Acta Orthop Scand* 1990; 61:435–7.
5. De Smet AA, et al. MR diagnosis of posterior root tears of the lateral meniscus using arthroscopy as the reference standard. *AJR Am J Roentgenol* 2009; 192:480–6.
6. Drapé JL, et al. Les limites de l’RM dans la pathologie méniscale. In: *Le genou traumatique et dégénératif.* GETROA OPUS XXIV. Montpellier: Sauramps Medical. 1997; p.379–409.
7. Andreas Adam, et al. Grainger & Allison's Diagnostic Radiology, 6th Edition. Volume 1. 2015; 1079-1084.
8. John R. Haaga, et al. CT and MRI of the whole body. Volume Two, Fourth Edition. 2003; 1869-1908.
9. William E. Brant, et al. Fundamentals of diagnostic radiology, Fourth edition. 2012; 1098-1108.
10. Costa-Paz M, et al. Magnetic resonance imaging follow-up study of bone bruises associated with anterior cruciate ligament ruptures. *Arthroscopy* 2001; 17:445-9.
11. Smith DK, et al. MR imaging of the cruciate ligament: frequency of discordant findings on sagittal oblique images and correlation with arthroscopic findings. *AJR Am J Roentgenol* 1996; 166:411–3.
12. Vahey TN, et al. Acute and chronic tears of the anterior cruciate ligament: differential features at MR imaging. *Radiology* 1999; 181:251–3.
13. Sonin AH, et al. MR imaging of the posterior cruciate ligament: normal, abnormal, and associated injury patterns. *Radio graphics* 1995; 15:551–61.
14. Sonin AH, et al. Posterior cruciate ligament injury: MR imaging diagnosis and patterns of injury. *Radiology* 1994; 190:455–8.
15. Vassilios S Nikolaou, et al. MRI efficacy in diagnosing internal lesions of the knee: a retrospective analysis. *J Trauma Manag Outcomes.* 2008; 2: 4.
16. Khanda GE, et al. Assessment of menisci and ligamentous injuries of the knee on magnetic resonance imaging: correlation with arthroscopy. *J Pak Med Assoc.* 2008; 58:537-40.
17. Pawan Shaw, et al. Categorization of discrepancies in findings of menisci and cruciate ligament between arthroscopy and MRI. *IJOS* 2018; 4:930-934.
18. Johannes Walter Schnaiter, et al. Diagnostic Accuracy of an MRI Protocol of the Knee Accelerated Through Parallel Imaging in Correlation to Arthroscopy. *Fortschr Röntgenstr* 2018; 190:265–272.

**TABLES:**

Table 1: The sensitivity , specificity ,accuracy , PPV and NPV of MRI compared with arthroscopy.

injury	MRI results	Arthroscopy results		Sensitivity %	Specificity %	Accuracy %	PPV %	NPV %
		Positive	Negative					
MM	Positive	25	6	86.21	72.73	80.39	80.63	80
	Negative	4	16					
LM	Positive	5	1	83.33	97.78	96.08	83.33	97.78
	Negative	1	44					
ACL	Positive	20	6	100	80.63	88.24	76.92	100
	Negative	0	25					
PCL	Positive	2	0	100	100	100	100	100
	Negative	0	49					

MM: medial meniscus, LM: lateral meniscus, ACL: anterior cruciate ligament, PCL: posterior cruciate ligament, PPV: , positive predictive value , NPV: , negative predictive value.

**FIGURES:**

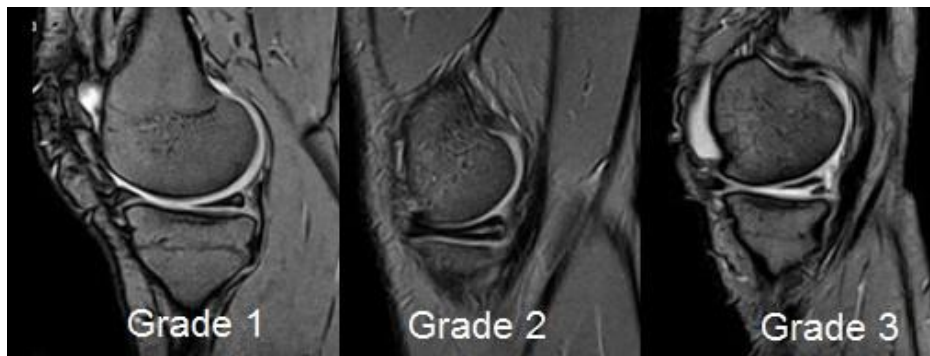


Figure 1: Sagittal MRI image shows grade1, 2 and 3 of the high signal in the posterior horn of the medial meniscus.

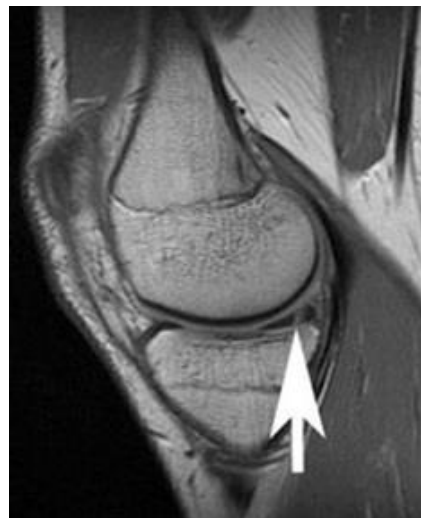

Figure 2: Sagittal MRI image shows a vertical tear in the posterior horn of the medial meniscus (white arrow).

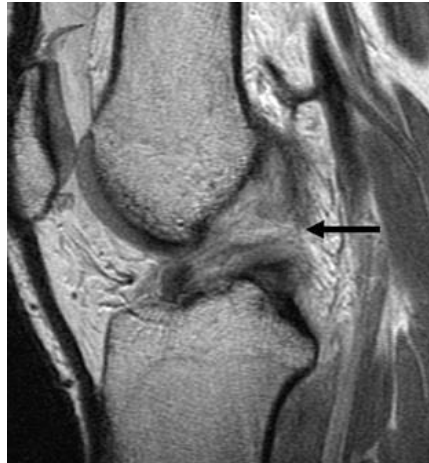

Figure 3: Sagittal MRI image shows an acute complete tear in the anterior cruciate ligament. High signal with discontinuity of the fibers (black arrow).

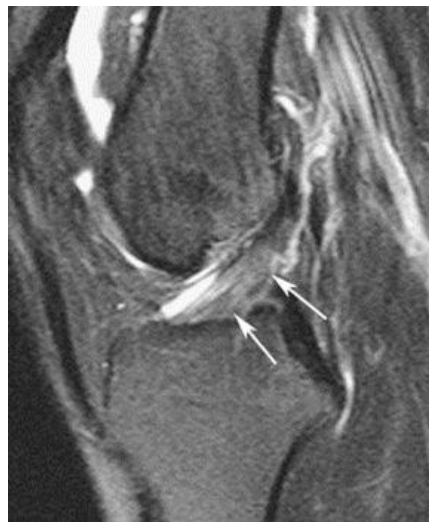

Figure 4: Sagittal MRI image shows a partial tear in the anterior cruciate ligament. High signal in the distal segment of the ligament with continuity of the fibers (white arrows).

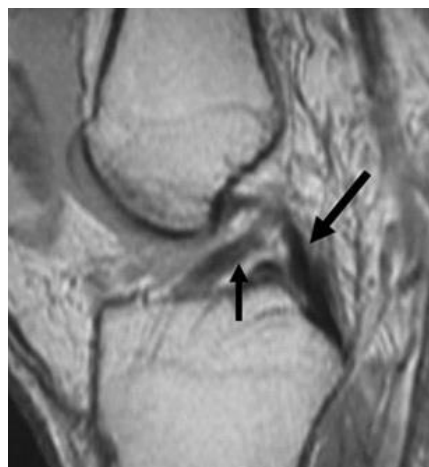


Figure 5: Sagittal MRI image shows a chronic tear in the anterior cruciate ligament. ACL appears retracted and angular (thin arrow), and normal PCL (thick arrow).



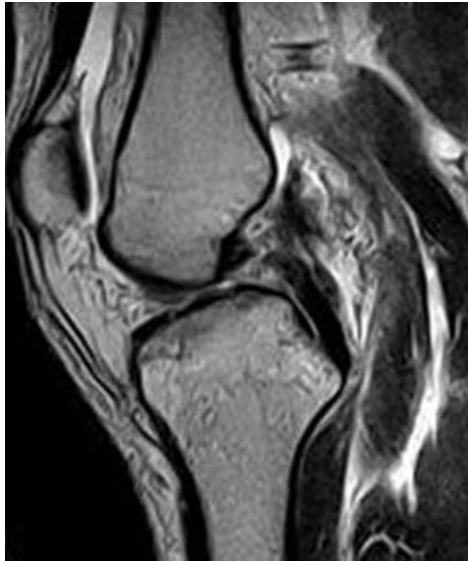

Figure 6: Sagittal MRI image shows a complete tear in the posterior cruciate ligament.  
Discontinuity of the fibers.

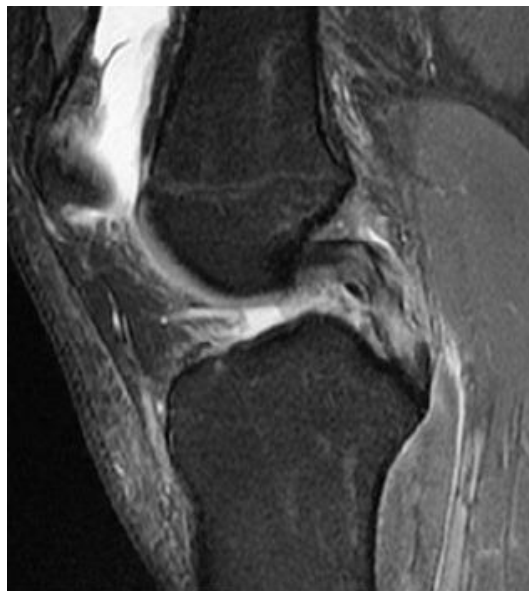

Figure 7: Sagittal MRI image shows a partial tear in the posterior cruciate ligament.  
Thickening and high signal with continuity of the fibers.