

INTRAOSSEROUS MUCOEPIDERMOID CARCINOMA RADIOGRAPHICALLY MIMICKING A CYSTIC LESION: A CASE REPORTSelvam Sruthi¹, Radhakrishnan Sankari², Venkatapathy Ramesh³, Mariappan Jonathan Daniel⁴

1. Postgraduate Resident, Department of Oral Medicine and Radiology, Mahatma Gandhi Postgraduate Institute of Dental Sciences Puducherry, Puducherry (U.T), India.

2. Postgraduate Resident, Department of Oral Pathology and Microbiology, Mahatma Gandhi Postgraduate Institute of Dental Sciences Puducherry, Puducherry (U.T), India.

3. Dean, Professor and Head, Department of Oral Pathology and Microbiology, Mahatma Gandhi Postgraduate Institute of Dental Sciences Puducherry, Puducherry (U.T), India

4. Associate Dean (Academics), Professor and Head, Department of Oral Medicine and Radiology, Mahatma Gandhi Postgraduate Institute of Dental Sciences Puducherry, Puducherry (U.T), India.

ABSTRACT:

A 42 year old man presented with pain and swelling in the left lower back tooth region. He underwent uneventful extraction of impacted tooth 1 year before. There was a well-defined dome shaped swelling of size 1.5×2.5 cm in the left side posterior alveolar ridge. Lesional aspiration revealed a thick mucus aspirate. Computed tomography revealed significant buccal and lingual cortex destruction with an isodense mass similar in density to adjacent soft tissues was noticed. CECT revealed an ill-defined heterogeneously enhancing soft tissue lesion measuring 1.8 × 2 cm, in the left retromolar trigone causing expansion and cortical thinning of the left mandibular ramus. Incisional biopsy of the lesion confirmed the diagnosis of the lesion as MEC of mandible. To date, only one case series and two case reports have focused strictly on the diagnostic imaging characteristics of IMC. This case report focuses on the diagnostic imaging characteristics of IMC.

Key words: salivary gland neoplasm, mucoepidermoid carcinoma, intraosseous, diagnostic imaging.

**INTRODUCTION**

Mucoepidermoid carcinoma is a malignant epithelial tumor, first studied and described as a separate entity by Stewart, Foote and Becker in 1945. Mucoepidermoid carcinoma represents 20-34 % of malignant tumors originating in both major and minor salivary glands. This carcinoma of salivary glands accounts for 5 % of all salivary gland tumors [1]. Eversole reviewed 815 cases and found that of the major salivary gland tumors, 89.6% involved the parotid, 8.4% submandibular and 0.4% sublingual gland. In 1991, after a systematic review of its histology and degree of differentiation

the WHO classification recommended that the term "mucoepidermoid tumor" be changed to "mucoepidermoid carcinoma" [2].

CASE DETAIL:

A 42 year old male reported with complains of pain and swelling in the left lower back tooth region since 5 months. 5 months back patient noted a small swelling in the left lower back tooth region which has gradually increased to the present size. He also complained of pain over the swelling for past 4 months, which was continuous, dull, relieved on medication. There was no history of

trauma or numbness and he underwent uneventful extraction of impacted tooth 1 year before. In medical history, patient was known case of hypothyroid and bronchial asthma for past 4 years.

Extra oral examination showed no gross facial asymmetry and there was no evidence of swelling [figure 1]. On palpation of lymph nodes, left side single palpable submandibular lymph node of size 1.5×1.5 cm in diameter, soft to firm, mobile and non-tender. Intraoral examination showed a well-defined dome shaped swelling of size 1.5×2.5 cm present in relation to left side posterior alveolar ridge extending from distal of 37 to retromolar region [figure 2]. Buccolingually from buccal vestibule to 1 cm short of floor of the mouth. The surface covering the swelling shows no secondary changes like sinus opening or pus discharge and no visible pulsations. On palpation, inspectory findings were confirmed. The swelling was soft to firm in consistency, compressible, non-fluctuant and tender. Hard tissue examination revealed missing 38, no tooth discoloration or hypoplasia seen.

Based on above history and clinical findings, provisional diagnosis was given as residual odontogenic cyst most probably dentigerous cyst in relation to extracted 38. The differential diagnosis were radicular cyst, paradental cyst, odontogenic keratocyst, calcifying epithelial odontogenic cyst, simple bone cyst, pleomorphic adenoma and its variants. Ameloblastoma, ameloblastic fibroma, odontogenic myxoma, salivary

gland tumors like mucoepidermoid carcinoma, adenoid cystic carcinoma, intraosseous squamous cell carcinoma, metastatic tumors to jaws from lungs, kidney, prostate.

Vitality test revealed immediate response in relation to 36, 37. Lesional aspiration was attempted using 23 gauge needle and 2 drops of thick mucus aspirate was obtained. Routine haemogram showed normal range of all the blood cells. Intraoral periapical radiograph in relation to 36, 37, edentulous 38 revealed a well-defined, corticated, homogenous radiolucency extending from distal aspect of 37 and the posterior extent was not covered. Orthopantomogram revealed a well-defined, corticated homogenous radiolucency extending from distal aspect of 37 to level of ascending ramus. The inferior alveolar nerve canal was traceable and not displaced [figure 3]. Lateral occlusal radiograph revealed no evidence of cortical expansion.

Computed tomogram axial view bone window revealed significant buccal and lingual cortex destruction. An isodense mass similar in density to adjacent soft tissues was noticed. No evidence of impacted tooth. Computed tomogram coronal section bone window [figure 4] revealed buccal and lingual cortical destruction extending from left angle to ramus of the mandible. Computed tomogram 3D reconstruction [figure 5] revealed through and through buccal and lingual cortical expansion. Inferior border of mandible is intact without any destruction /expansion. CECT [figure 6]

revealed an ill-defined heterogeneously enhancing soft tissue lesion measuring 1.8 × 2 cm is seen in the left retromolar trigone causing expansion and cortical thinning of the left mandibular ramus surrounding the apices of 2nd and 3rd molars. Medially there is focal loss of fat plane with the medial pterygoid muscle and extension to masticator space.

Incisional biopsy was done and the section [figure 7] basically consist of mucous and epidermoid type of cells. Low cuboidal type of cells representing intermediate kind of cells but scanty in nature. But some areas stromal components and clear cell changes too. Few mitotic changes noticed in solid area. There is not much of inflammatory changes noticed suggestive of intermediate grade mucoepidermoid carcinoma. The patient was referred to a regional cancer centre for further treatment where radical excision of the lesion with adjuvant radiotherapy was carried out.

DISCUSSION:

Mucoepidermoid carcinomas arising within the jaws as primary central bony lesions are termed central mucoepidermoid carcinomas and are extremely rare, comprising 2–3% of all mucoepidermoid carcinomas. The origin of these lesions in the jaws is thought to be due to neoplastic transformation of the sinus epithelium; entrapped retromolar mucous glands and developmental embryonic remnants of the submandibular gland within the mandible or neoplastic transformation of

the mucous-secreting cells commonly found in the pluripotential epithelial lining of dentigerous cysts associated with impacted third molars [3-5]. The origin of the lesion in our case could be from entrapped retromolar mucous glands since the lesion was more involving the retromolar region. In 1974, Alexander et al introduced the following criteria for diagnosing intraosseous MEC:

- Absence of any primary lesion in the salivary glands
- Absence of any odontogenic tumors
- Radiographic evidence of bone destruction
- Retention of cortical plate integrity
- Positive mucin staining and
- Microscopic confirmation of the diagnosis.

This case fulfilled all of these criteria .In the study by He Y et al, the average age range of the 24 patients was 40-50 years with male-female ratio of 1.67:1 which was consistent with the present case. These intraosseous MEC had 1.18:1 predilection for the maxilla, and in the mandible, whereas in our case the lesion was in mandibular body. To better characterize this tumor, a literature search was conducted in the PubMed database to survey the published case reports of intraosseous mucoepidermoid carcinoma in the last 3 years, as described in [7-8] [Table I]

Based on the history, age, site of occurrence provisional diagnosis was given as residual odontogenic cyst most probably dentigerous cyst in relation to extracted 38. The differential diagnosis of

unicystic/multicystic lesions in the mandible or maxilla usually includes ameloblastoma and keratocystic odontogenic tumor; however, it should not exclude less common, but more serious conditions, as metastatic tumors; malignant osseous tumors; primary intraosseous carcinoma and malignant salivary glands tumors [Table I].

Brookstone and Huvos [6] have proposed a staging class for intraosseous MEC.

- Stage I: Lesions with intact cortical plates with no evidence of bone expansion
- Stage II: Neoplasms with intact plates, but intrabony expansion seen.
- Stage III: Lesions associated with cortical perforation or nodal disease.

According to these categories, the current case can be fitted in stage III.

Radiographic features are diverse and not exclusive of CMC. Usually, it appears as a unilocular or multilocular radiolucent lesion with sclerotic and well-defined margins. Da Silva LP *et al* [9] reported mixed radiopaque-radiolucent lesion in mandible, Chundru *et al* [10], Kechagias *et al* [11], reported multilocular radiolucent lesion in maxilla and Nallamilli *et al* [12] reported unilocular radiolucent lesion in mandible; whereas our case present unilocular radiolucent lesion.

In the classification proposed by Waldron and Mustoe [13] (Table II) our case was a type-4 PIOC, based on the representative histological findings. Common diagnostic imaging features of intraosseous mucoepidermoid carcinoma are well-

defined sclerotic periphery, amorphous sclerotic bone internally, multiple small loculations internally, loculations with and without peripheral septa, expansion and perforation of the outer cortex with extension into surrounding soft tissues [7]. In the present case the figure 8: Cropped a. panoramic, b.CT bone window and c.CECT shows a well defined unilocular radiolucency with sclerotic border (straight arrows) in the left mandible. The buccal cortex exhibits considerable cystic expansion and perforation with extension into the surrounding soft tissues (curved arrows).

The MEC are usually graded as low grade/well differentiated (tumor exhibiting greater than 50% of mucous elements), intermediate grade (10– 50% of mucous elements and high grade (less than 10% of mucous elements). Present case showed 10-50 % of mucous elements and fits under intermediate grade of mucoepidermoid carcinoma. The histopathologic grading is usually used as the main prognostic indicator. Presence of mucous cells, cells with foamy/clear cytoplasm, intermediate cells and lymphocytes in a mucinous background are diagnostic indicators of MEC [8]. Radical resection of the primary tumor should be used for patients with high-grade or intermediate-grade tumors, and adjuvant therapy after surgery is necessary to consolidate the therapeutic effect. The survival rate of patients with radiotherapy was 72.7%; therefore, radiotherapy should be recommended as routine treatment during the postoperative period [5].

CONCLUSION:

Intraosseous mucoepidermoid carcinoma are rare in the jaws, and the clinical presentation of this tumor varies. Therefore, symptoms, such as swelling and paresthesia, and radiographic examination, including computerized tomography, magnetic resonance imaging, or even fine-needle aspiration cytology, are important to clinically confirm the diagnosis. In this case the short duration was also uncommon for a malignant lesion. Clinically and radiographically, since the lesion's behavior was different, it is important that the clinician be aware of the various clinical presentations of a particular disease process. This case report adds a new dimension to the features revealed by a central mucoepidermoid carcinoma.

REFERENCES:

1. William G. Shafer, Maynard K. Hine and Barnet M Levy: Textbook of oral pathology, ed 7, pp. 235-237, 1983, Mosby.
2. Deepti Simon, Thara Somanathan, K Ramdas and Manoj Pandey Central Mucoepidermoid carcinoma of mandible – A case report and review of the literature *World Journal of Surgical Oncology* 2003, 1:1.
3. S Sherin, N Sherin, V Thomas, N Kumar and KP Sharafuddeen Central mucoepidermoid carcinoma of maxilla with radiographic appearance of mixed radiopaque–radiolucent lesion: a case report *Dentomaxillofacial Radiology* (2011) 40, 463–465.
4. Atarbashi Moghadam S., Atarbashi Moghadam F. Intraosseous Mucoepidermoid Carcinoma: Report of Two Cases. *J Dent Shiraz Univ Med Sci.*, June 2014; 15(2): 86-90.
5. Yue He, Jun Wang, Hong-hai Fu, Zhi-yuan Zhang, and Qian-wei Zhuang, Intraosseous mucoepidermoid carcinoma of jaws: report of 24 cases. *Oral Surg Oral Med Oral Pathol Oral Radiol* 2012; 114:424-429.
6. Mitchell S. Brookstone, and Andrew G. Huvos. Central Salivary Gland Tumors of the Maxilla and Mandible: A Clinicopathologic Study of 11 Cases with an Analysis of the Literature *Oral Maxillofac Surg* 50:229-236, 1992.
7. KC Chan, M Pharoah, L Lee, I Weinreb and B Perez-Ordenez. Intraosseous mucoepidermoid carcinoma: a review of the diagnostic imaging features of four jaw cases. *Dentomaxillofacial Radiology* (2013) 42, 20110162
8. Harry L. Evans, *Mucoepidermoid Carcinoma of Salivary Glands: A Study of 69 Cases with Special Attention to Histologic Grading* *A.J.C.P.* June 1984 vol. 81. No. 6.
9. Da Silva LP, Serpa MS, da Silva LA, Sobral AP. Central mucoepidermoid carcinoma radiographically mimicking an odontogenic tumor: A case report and literature review. *J Oral Maxillofac Pathol* 2016; 20:518-22.
10. Naga Sirisha Venkata Chundru, T. Prasanth, S. R. K. Nandan, A. Rajesh. Central mucoepidermoid carcinoma E-JCRT Correspondence.
11. Nikos Kechagias, Aris Ntomouchtsis, Alexandra Mavrodi, Barbara

Christoforidou & Antonis Tsekos, Kostas Vahtsevanos Central mucoepidermoid carcinoma of the anterior region of the mandible: report of an unusual case and review of the literature. *Oral Maxillofac Surg* DOI 10.1007/s10006-015-0483-8.

12. S. M. Nallamilli, R. Tatapudi, R. S. reddy, M. Ravikanth and N. Rajesh Primary Intraosseous

mucoepidermoid Carcinoma of the maxilla *Ghana medical journal* .June 2015Volume 49 Number 2.

13. Y-J Lin, C-H Chen, W-C Wang, Y-K Chen, and L-M Lin, Primary intraosseous carcinoma of the mandible *Dentomaxillofacial Radiology* (2005) 34, 112–116.

TABLES:

Table 1: Features of intraosseous mucoepidermoid carcinomas described worldwide in the last three years (2015-2017)

Authors	Age	Gender	Symptoms	Anatomic site	Radiographic findings	Diagnosis hypotheses
Chundru et al(2015) ¹⁰	37	Male	Asymptomatic	Mandible	Multilocular radiolucent	Ameloblastoma/ KCOT
Kechagias et al(2015) ¹¹	37	Female	Pain	Mandible	Multilocular radiolucent	Ameloblastoma
Nallamilli et al (2015) ¹²	36	Male	Pain	Maxilla	Unilocular radiolucent	Odontogenic tumor
Da Silva et al(2016) ⁹	28	Male	Pain	Mandible	Multilocular radiolucent	Ameloblastoma
Present case(2017)	42	Male	Pain	Mandible	Unilocular radiolucent	Cystic lesion

Table II: Classification of primary intraosseous carcinoma (PIOC) according to Waldron and Mustoe

Type 1	PIOC ex odontogenic cyst
Type 2a	Malignant ameloblastoma
Type 2b	Ameloblastic carcinoma arising de novo, ex ameloblastoma or ex odontogenic cyst.
Type 3	PIOC arising de novo (a) Keratinizing type (b) Non-keratinizing type
Type 4	Intraosseous mucoepidermoid carcinoma

FIGURES:

Figure 1: Extra oral examination showed no gross facial asymmetry and there was no evidence of swelling

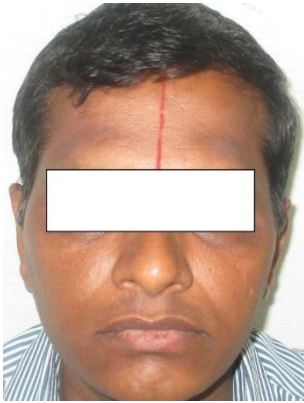

Figure 2: Well-defined dome shaped swelling in relation to left side posterior alveolar ridge extending from distal of 37 to retromolar region.

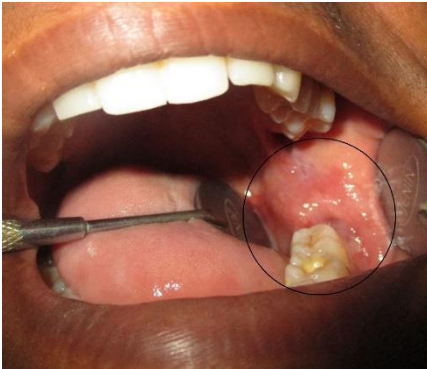

Figure 3: Cropped panoramic image reveals well-defined, corticated homogenous radiolucency extending from distal aspect of 37 to level of ascending ramus.

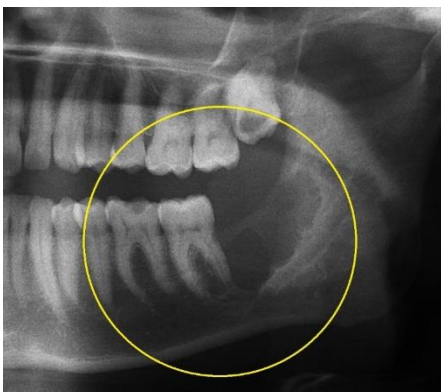

Figure 4: Computed tomogram coronal section bone window revealed buccal and lingual cortical destruction extending from left angle to ramus of the mandible.

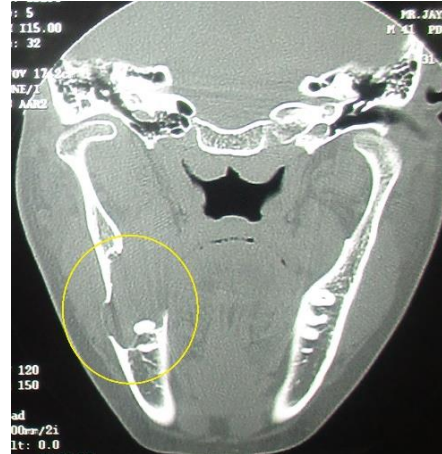


Figure 5: Computed tomogram 3 D reconstruction reveal through and through buccal and lingual cortical expansion. Inferior border of mandible is intact without any destruction /expansion.

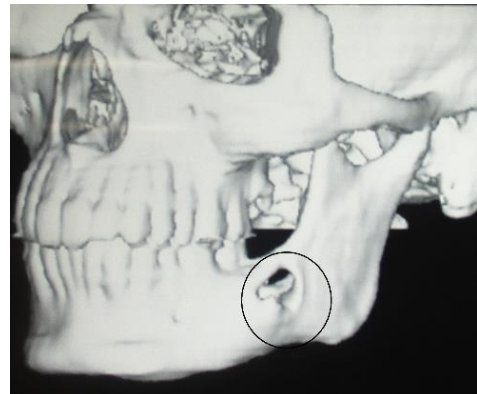


Figure 6: CECT reveal an ill-defined heterogeneously enhancing soft tissue lesion measuring 1.8 × 2 cm is seen in the left retromolar trigone causing expansion and cortical thinning of the left mandibular ramus surrounding the apices of 2nd and 3rd molars. Few discrete enhancing level 1a bilateral level 1b and 2 cervical nodes noted

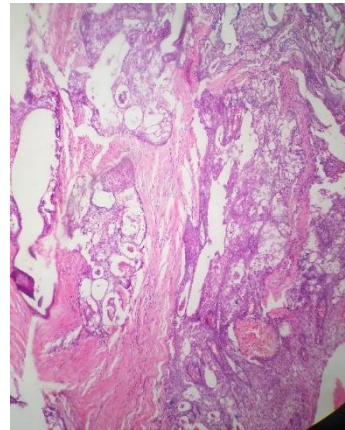


Figure 7: 10x view shows mucous and epidermoid type of cells. Low cuboidal type of cells representing intermediate kind and few mitotic changes were also noticed in solid area.

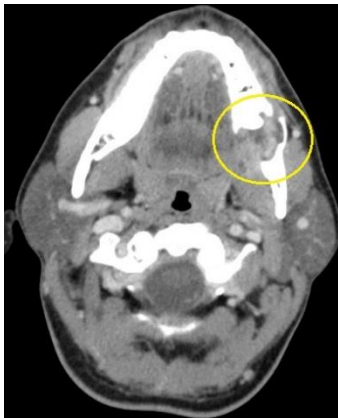
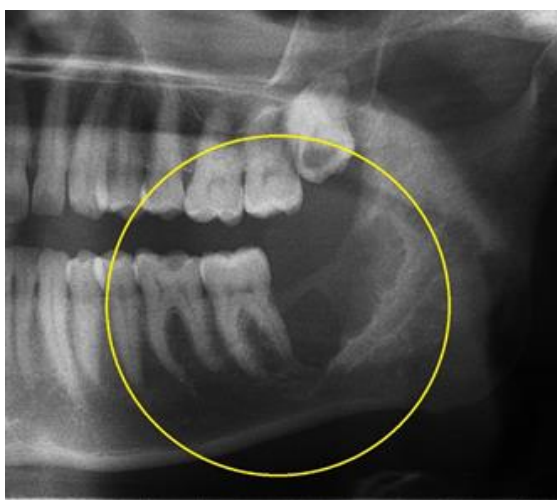
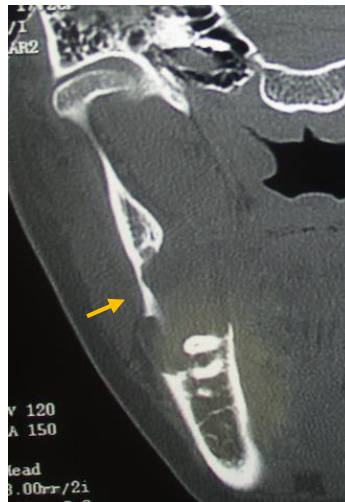
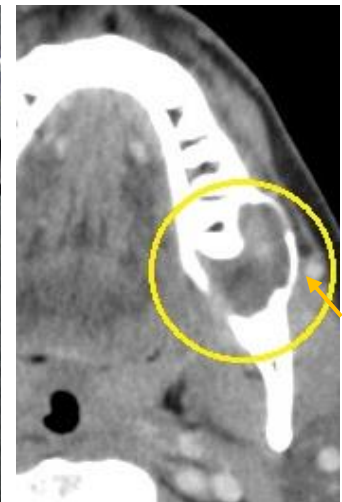Figure 8: Cropped a. panoramic, b.CT bone window and c.CECT shows a well defined unilocular radiolucency with sclerotic border (straight arrows) in the left mandible. The buccal cortex exhibits considerable cystic expansion and perforation (curved arrows).



a



b



c