

Study of Liver Lesions using Computed Tomography

Mohamed Hasaneen^{1,3}, Mohamed Yousef^{1,2}, Ahmed Abukonna¹, Zinab Mohamed⁴

¹College of Medical Radiological Sciences, Sudan University of Science and Technology, Khartoum, Sudan

²Radiologic Sciences Program, Batterjee Medical College, Jeddah, Saudi Arabia

³Al-Ghad International College of Applied Medical Science, Medical Imaging Technology Department, Dammam, KSA

⁴Federal ministry of health –Sudan -Khartoum

Abstract: The purpose of this study was to evaluate the role of CT in the diagnosis of liver lesions. And furthermore to determine which lesion in the liver with high incidence, and to find out the Geographic distribution of the liver lesions in Sudan. This is a retrospective study was conducted in Fedail, Khartoum and Royal scan center to study the liver lesions using computed tomography, included Sixty patients with focal tumoral liver lesions were recruited for four months period, and their triphasic CT scans findings were evaluated and later correlated with final Diagnosis. Sensitivity, specificity, positive predictive value, negative predictive value and diagnostic accuracy of triphasic CT scan were calculated. The results of the study revealed that the high incidence of liver lesions was (45%) in the age group between (41-60) years old (Figure 2). The high incidence of was liver metastasis (33.3%) and solid mass (33.3%), and was commonest in age group (41-60) years old which had an incidence of (45%), it commonest in male, had an incidence of (60%) (Figure 3), the most patients came from center, north, and west of Sudan (Figure 4). The solid mass of the liver was commonest in age group (61-80) years old had an incidence of (45%), it commonest in male, had an incidence of (65%), most patients came from central of Sudan had incidence (50%) and it commonest in right lobe of the liver had incidence (50%). Triphasic CT scan is a good non-invasive tool and can be used as the first line imaging modality for differentiating benign and malignant focal liver lesions. Benign lesions like haemangioma can be reliably differentiated from malignant liver lesion; therefore unnecessary biopsies can be avoided.

[Mohamed Hasaneen, Mohamed Yousef, Ahmed Abukonna, Zinab Mohamed. **Study of Liver Lesions using Computed Tomography.** *Biomedicine and Nursing* 2018;4(2): 31-37]. ISSN 2379-8211 (print); ISSN 2379-8203 (online). <http://www.nbmedicine.org>. 6. doi:[10.7537/marsbnj040218.06](https://doi.org/10.7537/marsbnj040218.06).

Key Word: Triphase, Computed Tomography, Liver Lesions

Introduction

Focal liver lesions can be defined as any lesion in the liver other than the typical parenchyma and can be of unpredictable size. These lesions can be benign or malignant. Prevalence of various liver lesions has marked differences across geographic regions and ethnic groups. [1] Although the recent evolution of diagnostic radiologic technologies has changed the setting of hepatic imaging, misdiagnoses during early disease development may prevent patients from obtaining advantageous management. There is the insufficient diagnostic performance for both the early detection and the characterization of small liver lesions even with computed tomography (CT) and magnetic resonance (MR) imaging techniques. As such, there is a need to improve on morphology-based CT and MR imaging using contrast agents for the early detection and characterization of hepatic disease. [2-4] Spiral computed tomography (CT) has rapidly gained acceptance as the preferred CT technique for routine liver evaluation because it provides image acquisition at peak enhancement of the liver parenchyma during a single breath hold [5-8] In addition, the fast data acquisition allows successive

scanning of the entire liver at different moments after injection of contrast material, thus creating the possibility of multiphase liver CT. Recent studies have reported an improvement in lesion detection if arterial phase imaging is performed in addition to portal venous imaging, especially in the presence of hyper vascular neoplasms, such as hepatocellular carcinoma (HCC). [9-12]

The liver lesions have increased significantly in the last few years and still represent major health problem, with difficulty in diagnosis and invasive biopsy test, this study aimed to study the role of CT in diagnosis of the liver lesions, determine which lesion in the liver with high incidence and to find out the Geographic distribution of the liver lesions.

Materials and Method

This is a retrospective study has been conducted in Fedail, Khartoum and Royal scan center to study the liver lesions using computed tomography.

Subjects

A review of 60 patients referred for liver CT scan with variable ages, symptoms, and residence.

Inclusion criteria

- All ages and sexes Patients.
- Contrast-enhanced abdominal CT.
- Patients with innumerable lesions in both liver lobes.

Exclusion criteria

- Inappropriate contrast medium injection (for example contrast medium extravasation).
- Patients with contraindication for iodinated contrast medium c) Incomplete images.
- Images with artifacts (for example respiratory

artifacts) which would make density measurements inaccurate or unreliable.

Study variables

A clinical sheet filled for each patient's age, residence, the computed tomography appearance for lesions with different shapes, sizes and contents and the suggested diagnosis.

Machine used

Multi detectors computed tomography with the automatic injector for contrast media, and they are Toshiba, GE, and Siemens table (1).

Machine Type	Number of detectors	Slice sickness	Amount of CM/ml	Arterial phase delay time/sec	Porto/Venus phase delay time/sec
Toshiba	64	Thin as Possible	70	25	45
GE	2	5	95	27	48
Siemens	16	3-5	80	25	46

Technique used

The entire liver scanned successively; in arterial, portal and equilibrium phases. A 5mm collimation and 5mm/sec table speed will be used. All scans will be taken in the craniocaudal direction and during a single breath hold. After obtaining a digital scout view, the unenhanced scan of the liver will be obtained. 100-200 ml of 65% iodinated contrast material will be given by using a power injector at a rate of 1.5 to 2ml/sec. After 22 or 27seconds, the entire liver will be scanned in arterial phase. 22 seconds after the end of the arterial phase; the liver will be scanned in portal venous phase. The 20 second can delays for the patient to breath and reposition the scan plane cephalad to the liver. After these two phases, the third scan will be taken in the equilibrium phase, 8-10 minutes after injection of contrast the images acquired in different phases will be evaluated in detail to identify lesions.

Measurement

Primary data were collected from patient's sheets, interview, and the computed tomography done for each patient.

Analysis

The results were picked up about the incidental findings. And with different figures, graphs, and groups it explained the role of computed tomography to detect the liver lesions.

Ethical consideration

The data collected from the patients and it kept secret, and it recorded as it collected from the patients, all this data collected according to the patient satisfaction and agreement.

Results

The study includes 60 patients with different age and gender; they were investigated in different computed tomography departments in Khartoum state.

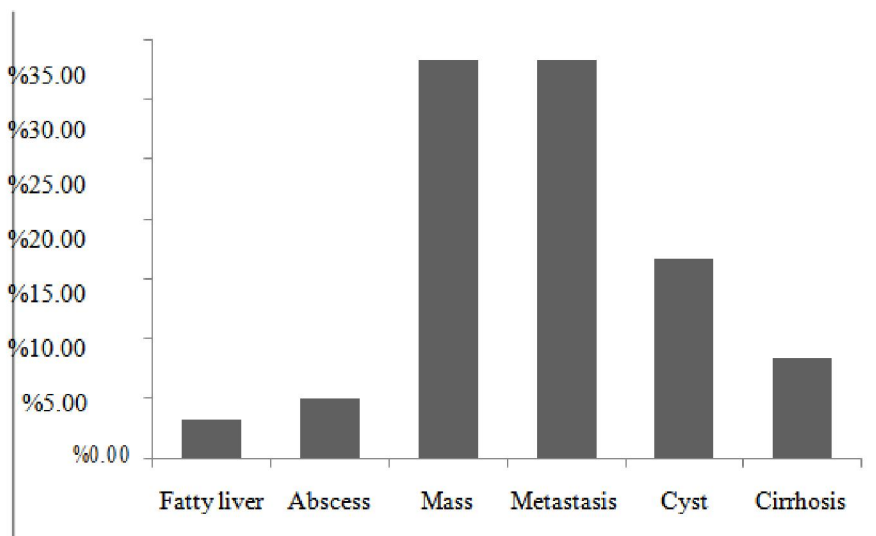


Figure 1. Liver lesions

Table 2: Characteristic Features of Detected Hepatic Lesions on CT

Pattern of Enhancement	The phase of Acquisition with maximum lesion conspicuity	No of Cases	Suggested Diagnosis
The attenuation of the liver is at least 10 HU less than that of the spleen or if the attenuation of the liver is less than 40 HU	Non-enhanced	2	Fatty liver
	Portal venous phase		
	Delay phase		
Multifocal lesions with arterial phase enhancement and portal venous phase washout of contrast	Arterial phase	14	Metastasis
	Portal venous phase	6	
	Delay phase		
Multiple lesions with thick wall and central necrosis nor daughter cyst	Arterial phase		Abscess
	Portal venous phase	2	
	Delay phase	1	
Single lesion with sharp margins and near water density in the center and does not show enhancement in the center	Arterial phase		Cyst
	Portal venous phase	6	
	Delay phase	4	
Single heterogeneous lesion with hyperdense component	Arterial phase	17	Mass
	Portal venous phase	3	
	Delay phase		
Multiple regenerative nodules are isodense to rest of liver with lobar atrophy	Arterial phase		Cirrhosis
	Portal venous phase	4	
	Delay phase	1	

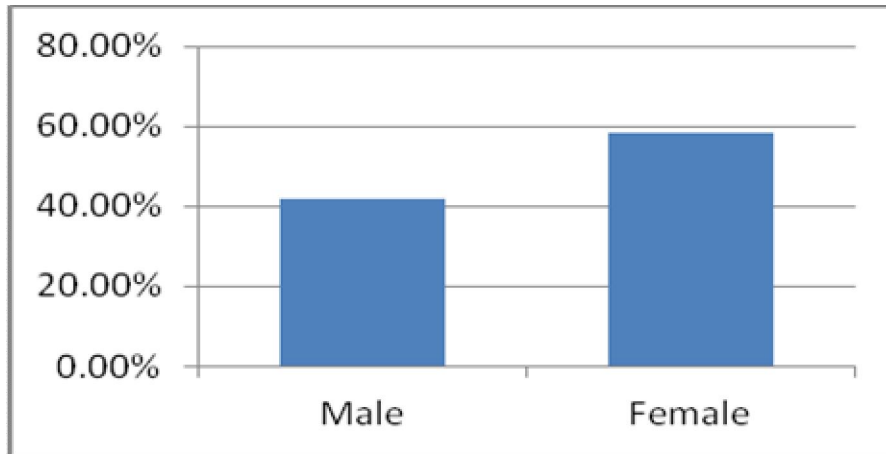


Figure 2. Gender distribution

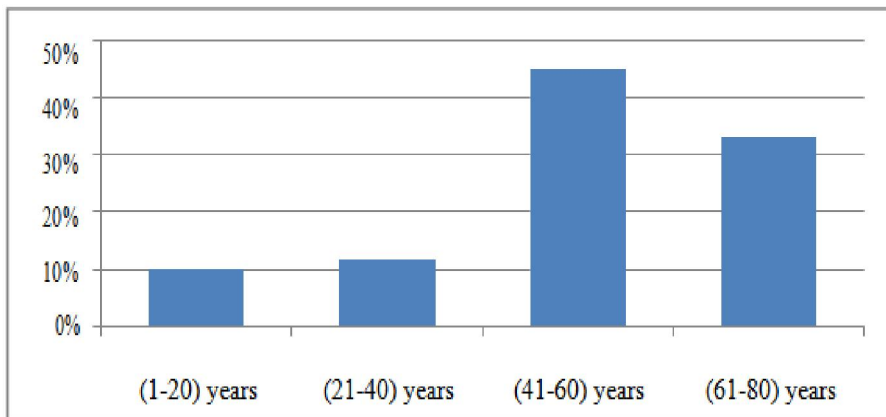


Figure 3. Age distribution

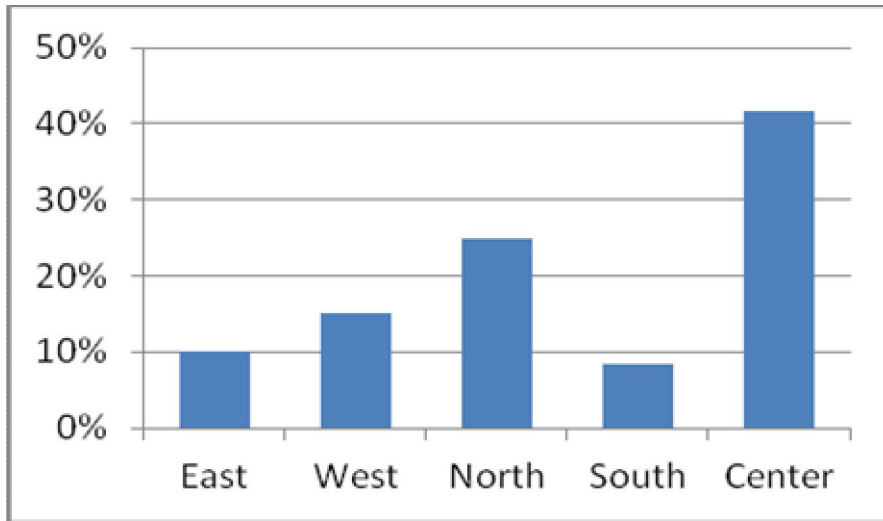


Figure 4. Distribution of residence.

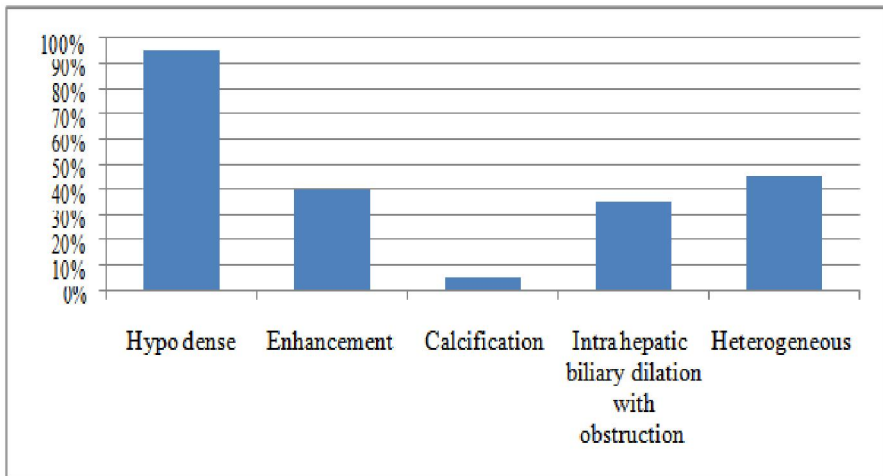


Figure 5. Distribution of the appearance of the solid mass

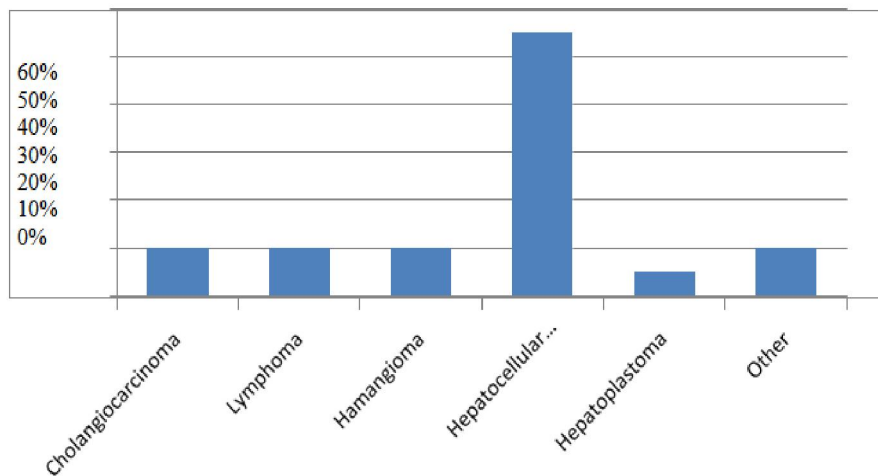


Figure 6. Distribution of the probability of the solid mass in the liver.

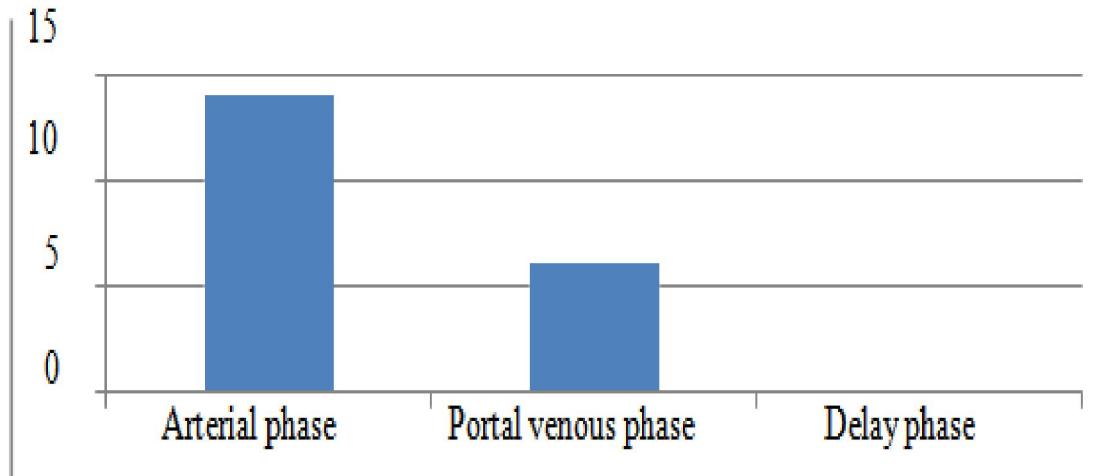


Figure 7. Distribution of the appearance of Metastasis in Phase of Acquisition

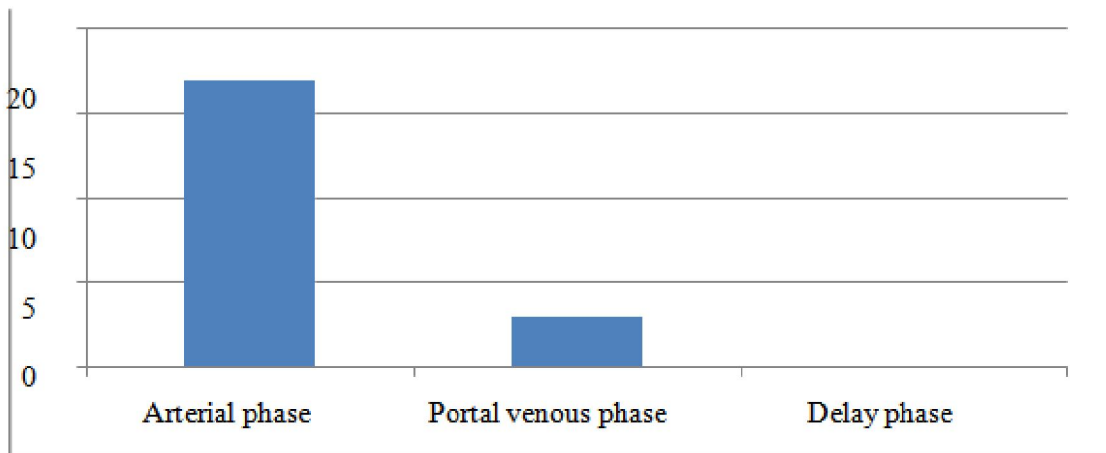


Figure 8. Distribution of the appearance of in Mass Phase of Acquisition

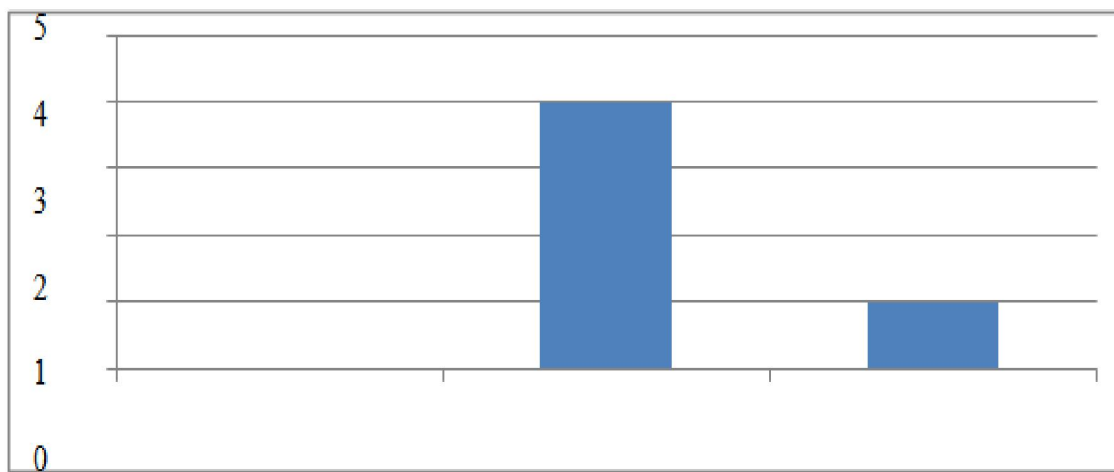


Figure 9. Distribution of the appearance of Cirrhosis in Phase of Acquisition

Discussion

Triphasic spiral liver Computed Tomography (CT) is a standardized procedure for the detection and characterization of a large variety of benign and malignant liver lesions. This helps in the decline of mortality and morbidity rates among patients with liver disease. Spiral computed tomography has gained acceptance as the preferred computed tomography technique for routine liver evaluation because it provides image acquisition at peak enhancement of liver parenchyma during a single breath hold.^[15,16] Also fast data acquisition allows successive scanning of the entire liver at different intervals after injection of the iodinated contrast material, thus creating the possibility of multiphase liver computed tomography.^[17,18]

This was seen in the result of the study which showed that (3) cases were the liver abscess, 10 cases were liver cysts, 20 cases were liver masses, 20 cases were liver metastases, 5 cases was liver cirrhosis and (2) case was fatty liver (Figure 1).

Most metastatic lesions were hypo vascular with more lesions being detected on portal venous phase and most of the primary malignancies were hyper vascular and detected on hepatic arterial phase (Figure 7). However, haemangiomas, focal nodular hyperplasia, and hepatocellular adenoma are benign lesions which are seen to enhance in the arterial or hyper vascular phase. In our study, 14 metastatic lesions were hypervascular, and six lesions were hypovascular, Most of the hypervascular metastatic lesions (n =20) were best visualized on arterial phase images rather than on port venous phase (Figure 8). Most of them become iso or hypodense on portovenous and equilibrium phases making it difficult to diagnose on single phase thus signifying the importance of additional arterial phase images (Figure 5).^[19]

Advanced or poorly differentiated hepatocellular carcinomas are usually hypervascular lesions that derive most of their blood supply from the hepatic artery with the portal venous contribution decreasing as the grade of malignancy increases. Similarly, cirrhosis and its associated altered portal venous blood flow may help reveal more lesions on the hepatic arterial phase than on the portal venous phase (Figure 9). In our study, all the 60 hepatomas presented as hyper/mixed; 31 detected only in the arterial phase; 21 were hypo attenuating in the portal phase, and eight were better seen in portal phase. These findings are in keeping with the well-known hypervascularity of HCC. All hyper/mixed/mixed lesions occurring in patients with chronic liver disease truly represent HCC lesions (Figure 6).^[14, 16, 20] Therefore; lesions seen during only the hepatic arterial phase may require biopsy. In patients with hypervascular malignancies

such as hepatoma, detection of small lesions especially if solitary is important because these lesions are more likely to be respectable or respond to therapy than the larger lesions.^[13,21]

Focal nodular hyperplasia and adenomas may appear hyperdense during the hepatic arterial phase and may rapidly become isodense to the liver or invisible during the portal venous phase and equilibrium phase, simulating hepatomas or hypervascular metastases.^[19,22]

The triphasic helical CT examination can create certain diagnostic dilemmas, including the inability to specifically characterize some lesions seen only on the hepatic arterial phase and not on the equilibrium or portal venous phase. Although high accuracy (95%) was noted in our results, we had two false positive results; In spite of this, our study showed the sensitivity of triphasic helical CT scan to be hundred percent for differentiation of benign and malignant liver lesions.

Conclusion

For practical purposes using triphasic CT technique in all patients referred for work up of focal hepatic lesions seem justified as it improves the chances of detection of focal hepatic lesions, like haemangioma which can be reliably differentiated from malignant liver lesion; therefore unnecessary biopsies can be avoided.

This study included (60) patients (58.3%) of them were female, and the other was male, the high incidence of liver lesions was (45%) in age group between (41-60) years old, the high incidence of liver lesions was liver metastasis (33.3%), the solid mass of the liver was commonest in age group (61-80) years old had an incidence of (45).

References

1. Méndez-Sánchez N, Villa AR, Chávez-Tapia NC, Ponciano-Rodríguez G, Almeda-Valdés P, González D, et al. Trends in liver disease prevalence in Mexico from 2005 to 2050 through mortality data. *Annals of Hepatology* 2005;4: 52-5.
2. Kamel IR, Choti MA, Horton KM, et al. Surgically staged focal liver lesions: accuracy and reproducibility of dual-phase helical CT for detection and characterization. *Radiology*. 2003;227:752-757.
3. Reimer P, Jahnke N, Fiebich M, et al. Hepatic lesion detection and characterization: the value of nonenhanced MR imaging, superparamagnetic iron oxide-enhanced MR imaging, and spiral CT-ROC analysis. *Radiology*.2000;217:152-158.
4. Hammering R, Adam G, Ayuso JR, et al. Comparison of 1.0 M gadobutrol and 0.5 M

- gadopentetate dimeglumine-enhanced magnetic resonance imaging in five hundred seventy-two patients with known or suspected liver lesions: results of a multicenter, double-blind, interindividual, randomized clinical phase-III trial. *Invest Radiol*. 2009;44:168-176.
5. Bluemke DA, Fishman EK. Spiral CT of the liver. *AJR* 1993; 160:787-792.
 6. Zeman RK, Fox SH, Silverman PM, et al. Helical (spiral) CT of the abdomen. *AJR* 1993; 160:719-725.
 7. Zeman RK, Zeiberg AS, Davros WJ, et al. Routine helical CT of the abdomen: image quality considerations. *Radiology* 1993; 189:395-400.
 8. Bluemke DA, Urban BA, Fishman EK. Spiral CT of the liver: current applications. *Semin Ultrasound CT MR* 1994;15:107-121.
 9. Baron RL, Dodd GD III, Holbert BL, Oliver JH III, Cam B. Helical biphasic contrast CT in evaluation of hepatocellular carcinoma (abstr). *Radiology* 1994; 193(P):435.
 10. Murakami T, Kim T, Oi H, et al. Detectability of hypervascular hepatocellular carcinoma by arterial phase images of MR and spiral CT. *Acta Radiol* 1995; 36:372-376.
 11. Hollett MD, Brooke Jeffrey R, Nino-Murcia M, Jorgensen MJ, Harris DP. Dual-phase helical CT of the liver: value of arterial phase scans in the detection of small (< 1.5 cm) malignant hepatic neoplasms. *AJR* 1995; 164:879-884.
 12. Bonaldi VM, Bret I'M, Reinhold C, Atni M. Helical CT of the liver: value of an early hepatic arterial phase. *Radiology* 1995; 197: 357-363.
 13. Schwartz LH, Gandras EJ, Colangelo SM, Ercolani MC, Panicek DM. Prevalence and importance of small hepatic Lesions Found at CT in Patients with cancer. *Radiology* 1999; 210:71-4.
 14. Iannaccone R, Laghi A, Catalano C, Rossi P, Mangiapane F, Murakami T, et al. Hepatocellular carcinoma, role of unenhanced and delayed phase multi detector row helical computed tomography in patients with cirrhosis. *Radiology* 2005; 234: 460-7.
 15. Foley WD, Mallisee TA, Hohenwarter MD, Wilson CR, Quiroz FA, Taylor AJ. Multiphase hepatic computed tomography with a multirow detector computed tomography scanner. *AJR Am J Roentgenol* 2000; 175: 679-85.
 16. Oliver JH 3rd, Baron RL, Federle MP, Rockette HE Jr. Detecting hepatocellular carcinoma, value of unenhanced or arterial phase computed tomography imaging or both used in conjunction with conventional portal venous phase contrast-enhanced computed tomography imaging. *AJR Am J Roentgenol* 1996; 167: 71- 7.
 17. Miller FH, Butler RS, Hoff FL, Fitzgerald SW, Nemcek AA Jr, Gore RM. Using triphasic helical computed tomography to detect focal hepatic lesions in patients with neoplasms. *AJR Am J Roentgenol* 1998; 171: 643-9.
 18. Vallis C, Andia E, Rocca Y, Cos M, Figueras J. Computed tomography in hepatic cirrhosis and chronic hepatitis. *Semin Ultrasound, CT MRI* 2002; 23: 37-61.
 19. Sheafor DH, Frederick MG, Paulson EK, Keogan MT, DeLong DM, Nelson RC. Comparison of unenhanced, hepatic arterial-dominant and portal venous-dominant phase helical CT for the detection of liver metastases in women with breast carcinoma. *AJR Am J Roentgenol* 1999; 172: 961-8.
 20. Johnson PT, Fishman EK. IV Contrast selection for MDCT: Current thoughts and practice. *AJR Am J Roentgenol* 2006; 186: 406-15.
 21. Takayasu K, Moriyama N, Muramatsu Y, Makuuchi M, Hasegawa H, Okazaki N et al. The diagnosis of small hepatocellular carcinomas efficacy of various imaging procedures in 100 patients. *AJR Am J Roentgenol* 1990; 155:49-54.
 22. Carlson SK, Johnson CD, Bender CE, Welch TJ: CT of focal nodular hyperplasia of the liver. *AJR Am J Roentgenol* 2000; 174: 705-12.

6/22/2018