

## **ATRAUMATIC NEEDLE HUB TECHNIQUE: A TECHNICAL NOTE ON PEDIATRIC FRACTURE MANAGEMENT**

**Supriya.G.Bhandage<sup>1</sup>, Manjunath Kurki<sup>2</sup>, Garima Sachdeva<sup>3</sup>, Shravya Kalavant<sup>4</sup>, Veena Yogeesh<sup>5</sup>**

1. Reader in Department of Oral and Maxillofacial Surgery, Sri Hasanamba Dental College and Hospital, Hassan

2. Prof and HOD Department of Oral and Maxillofacial Surgery, Sri Hasanamba Dental College and Hospital, Hassan

3. Post graduate student in Dept of Oral and Maxillofacial Surgery, Sri Hasanamba Dental College and Hospital, Hassan

4. Post graduate student in Dept of Oral and Maxillofacial Surgery, Sri Hasanamba Dental College and Hospital, Hassan

5. Senior Lecturer in Dept of Pedodontics and Preventive dentistry, Sri Hasanamba Dental College and Hospital, Hassan

### **ABSTRACT:**

Paradoxically, facial injuries in children are much less common than in adults, particularly during the first 5 years of life. In children traditional use of arch bar fixation and interdental ligature wires is not possible due to various reasons like absence of sufficient number of teeth due to primary teeth exfoliation, pre-shedding mobility of existing teeth and unfavourable anatomic features like poor retentive shape of deciduous teeth crown. Thus splinting the pediatric mandible with customized acrylic splints with circum-mandibular wires is the preferred treatment modality, as, apart from being a simple technique it doesn't hamper the growth as well. Through this article we highlight an atraumatic technique of securing the occlusal splint in its position by using 18 gauge needle hub as a substitute for conventional bone awl for passing the circum-mandibular wires. This technique resulted in decreased post-operative sequelae of pain and edema.

**Keywords:** needle-hub technique, circum-mandibular wiring, paediatric fracture



### **INTRODUCTION**

Paediatric fractures are rare as compared to fractures in the adult population and is estimated to occur in 5% of all maxillofacial traumas.<sup>[1,2]</sup> Mandibular fractures are the most common (56%) facial skeletal injury in paediatric patients.<sup>[3]</sup> Boys are affected twice as frequently as girls.<sup>[2]</sup> Dentoalveolar injuries occur more frequently and accounts to 60% cases of paediatric facial injuries. In paediatric patients symphysis and parasymphysis fractures account for 15%–20% of cases and body fracture is rare.<sup>[2]</sup> Hyperactivity of the child, fall, road traffic accidents

(RTA), and child abuses are the most frequent causes of facial bone fractures in children.<sup>[4]</sup> Majority of the body and symphysis fractures in children are undisplaced because of elasticity of mandible and embedded tooth buds that hold the fragments together “like glue”.<sup>[5]</sup> The treatment choice of fracture management in paediatric patients depends on the age, the state of tooth development, fracture type, child behaviour and socio-economic status.<sup>[6]</sup> Various methods available for fracture management include closed and open reduction. In pediatric patients with

undisplaced and minimally displaced fractures, the preferred method of choice is closed reduction and fixation. The main advantage of closed reduction in paediatric patients is that it prevents injury to the developing dentition and also avoids growth disturbances. Most undisplaced or minimally displaced fractures can be treated conservatively by using either dental splints with rubber elastics or occlusal splint (open or closed cap) with circum-mandibular wires; which is a relatively simple technique for management of such fractures in children. Through this paper we would like to highlight a minimally traumatic technique to carry out circum-mandibular wiring which results in less post-operative pain, edema and discomfort.

### **CASE DETAILS:**

A 3 years old boy reported to our unit with complaint of pain in the lower jaw following fall from the bed 3 days ago. The patient's medical and dental history was non-contributory. Clinical examination extra-orally revealed moderate tenderness over lower front tooth region of jaw. Intra oral examination revealed 3mm laceration in the marginal gingiva area between 83 and 84. Mobility of the dento-alveolar fractured segment was noted from 73 to 83 with lingual displacement of fracture fragment (FIG 1).

Pre operative Orthopantomogram (FIG 2) of the patient was not clear as the patient was extremely un-cooperative

despite oral sedation. The radiograph revealed a horizontal radiolucent line running in the dento-alveolar segment above anterior permanent tooth buds spanning from 73 to 83 indicating dento-alveolar fracture.

Impressions of both the jaws were made with alginate impression material. The fracture line was simulated on the cast by cleaving it.

An acrylic closed cap splint was constructed on the model of the patient's arches after reducing the fracture on the model (FIG 3). Following which, two grooves were made on occlusal surface of the splint to keep the wires in the place. The procedure was carried out under general anesthesia. An 18 gauge syringe needle hub was inserted percutaneously below the lower border of mandible, exited intraorally in the labial vestibule in relation to 73, 74 region taking care to stay as close as possible to the splint. Then a 26 gauge wire was passed extra-orally through the lumen of hub and held intra-orally. The needle was then withdrawn partially until the lower border. It was traced along the lower border of the mandible and brought lingually (FIG 4). The wire was cut to the desired length and secured to the splint over the groove. Same procedure was repeated on the right side in the region of 83, 84 (FIG 5).

### **DISCUSSION AND CONCLUSION:**

Mandibular fracture is a common facial skeletal injury seen in paediatric cases and accounts for about 5% of all facial

fractures.<sup>[7]</sup> The goal of the treatment is to stabilise the fracture segment and to restore the bony architecture to pre-injury position using minimally invasive technique to reduce the aesthetic and functional impairment ; keeping in mind the continuity of the path of eruption of succedaneous teeth.

For minimally displaced fractures, conservative closed reduction is the most commonly recommended treatment modality. The closed reduction and immobilization approach can be achieved by acrylic splints, circumferential wiring and arch bars.<sup>[8]</sup>

Several studies have recommended the use of customized splints as a treatment modality in children. This splint is retained with circum mandibular wiring which is the most common used conservative treatment in children .The advantages of opting for conservative methods are: a) no risk of damaging the roots of the teeth b) sub-periosteal reflection of tissues is avoided. c) cost effectiveness, d) ease of application and removal, e) reduced operation time, f) satisfactory stability during healing period, g) minimal trauma to adjacent anatomic structures and h) comfort for young patients.

Conventionally Kelsey fry bone awl is used for introducing the wire but in this case 18 gauge needle was used for passing the wire as the wound created using this technique is discreet. Advantages of needle hub technique over awl is reduced postoperative

oedema, reduced scarring(FIG 6), less technique sensitive, less time consuming and minimal injury to adjacent structures. When the awl travels through the tissue, with the wire crimped, the twisted end of the wire might cause trauma to the surrounding soft tissue unlike the needle hub technique.

In recent times open reduction and internal fixation has become standard care for treatment of displaced fractures, however suitability of this treatment in context of paediatric groups remains controversial.<sup>[9]</sup> Currently, open reduction and fixation with bio-resorbable plates are increasingly being used for treating paediatric fracture cases. However few authors have quoted the disadvantage of bone resorption around the plate <sup>[10]</sup> and about it's placement being technique sensitive.

While the basic principles for mandibular fracture treatment are the same as that for the adults, certain anatomical features of the paediatric mandible warrant special attention. The main objective for management of paediatric fractures is to achieve anatomic reduction and restore occlusion to allow fracture healing without any alteration in the developing dentition and the growing facial skeleton. Therefore, closed reduction using circumferential wiring over customized cap splint, employing the above mentioned atraumatic needle hub technique proves to be an indigenous method for minimally and undisplaced fracture management. Open reduction and

internal fixation should be retained for severely displaced and complicated

cases.

## REFERENCES:

1. Guven O. Fractures of the maxillofacial region in children. *J Craniomaxillofac Surg* 1992; 20: 244-247.
2. Sodhi SPS, Brar G, Brar RS, Bhardwaj J, Jain A. Modified Circummandibular Wiring Fixation Using Acrylic Splint For The Treatment Of Displaced Mandibular Parasymphysis Fracture: A Case Report. *J Stomatognathic Sci* 2015;5(1):10-13.
3. S. Iida and T. Matsuya, "Paediatric maxillofacial fractures: their aetiological characters and fracture patterns," *Journal of Cranio- Maxillofacial Surgery*, vol. 30, no. 4, pp. 237– 241, 2002.
4. R. Laloo, "Risk factors for major injuries to the face and teeth," *Dental Traumatology*, vol. 19, no. 1, pp. 12–14, 2003.
5. J. B. Mulliken, L. B. Kaban, and J. E. Murray, "Management of facial fractures in children," *Clinics in Plastic Surgery*, vol. 4, no. 4, pp. 491– 502, 1977.
6. Kumar N, Singh AK, Pandey A, Verma V. An indigenous method of closed reduction of pediatric mandibular parasymphysis fracture. *Natl J Maxillofac Surg* 2015;6:206-8.
7. Aizenbud D, Hazan-Molina H, Emodi O, Rachmiel A. The management of mandibular body fractures in young children. *Dental Traumatol* 2009;25:565-70
8. Laster Z, Muska EA, Nagler R. Pediatric mandibular fractures: introduction of a novel therapeutic modality. *J Trauma*. 2008;64:225–9.
9. C.E. Zimmermann, M.J. Troulius, L.B. Kaban. Pediatric facial fracture: recent advances in prevention, diagnosis and management. *Int J Oral Maxillofac Surg* vol 51, 1993, pp. 722-729.
10. R. Bali, P. Sharma, S. Jindal, R. Sharma. Bone resorption after bioresorbable fixation of a fractured paediatric mandible—a case report. *Oral Surg*, vol 4, 2011, pp 48-50.

## FIGURES:

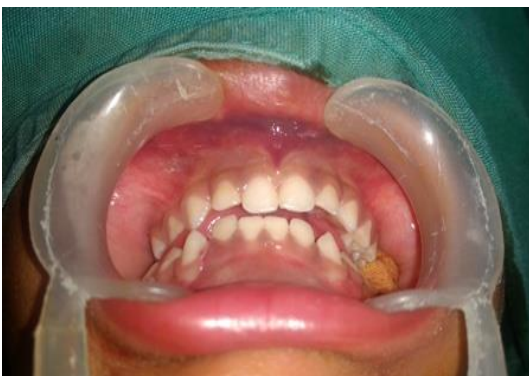

FIG 1 PRE-OPERATIVE CLINICAL PICTURE DEPICTING LINGUAL DISPLACEMENT OF FRACTURED FRAGMENT

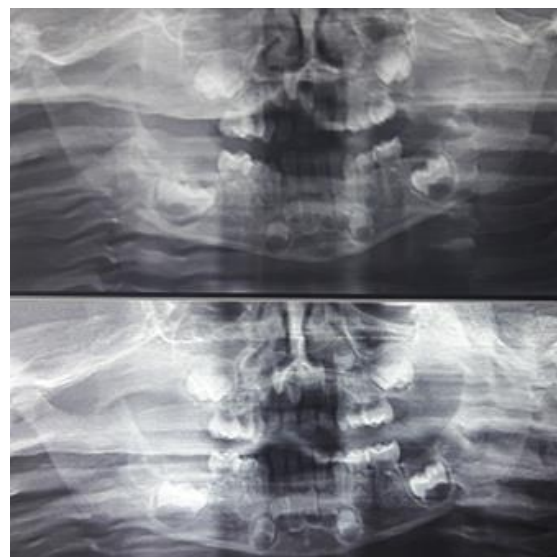


FIG2:PREOPERATIVE ORTHOPANTOMOGRAM

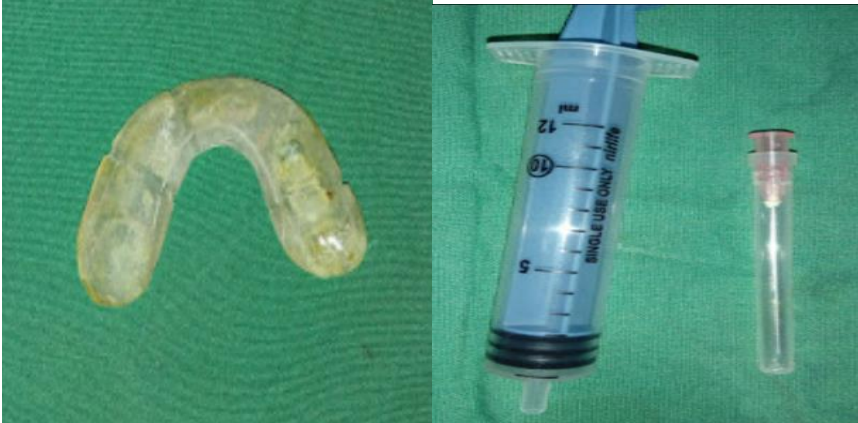

FIG 3 CUSTOMIZED CLOSED OCCLUSAL SPLINT AND 18 GAUGE NEEDLE HUB

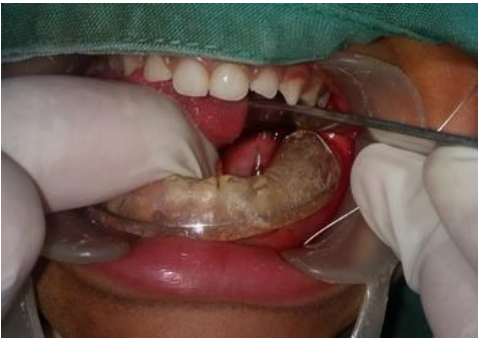

FIG 4 PERCUTANEOUS ENTRY OF NEEDLE HUB WITH THE WIRE IN THE LINGUAL VESTIBULE

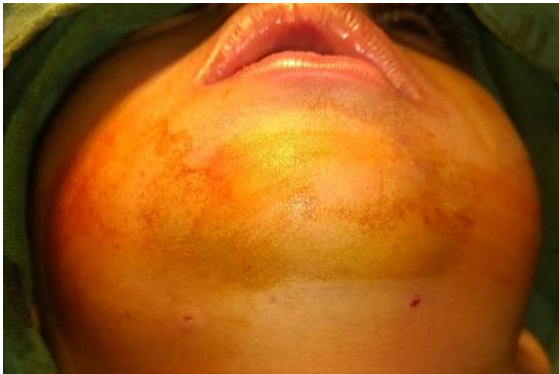

FIG 6: PERCUTANEOUS ENTRY SITES OF THE NEEDLE HUB

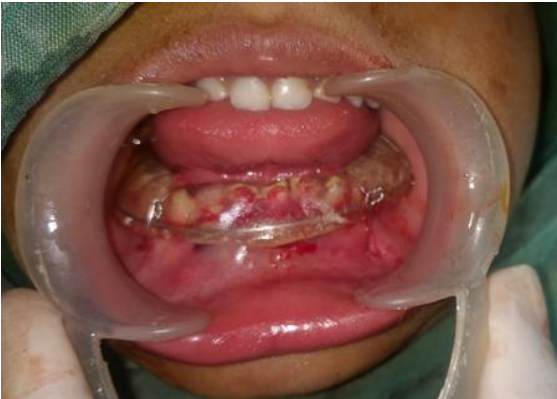

FIG 5 SPLINT SECURED IN PLACE AFTER WIRING

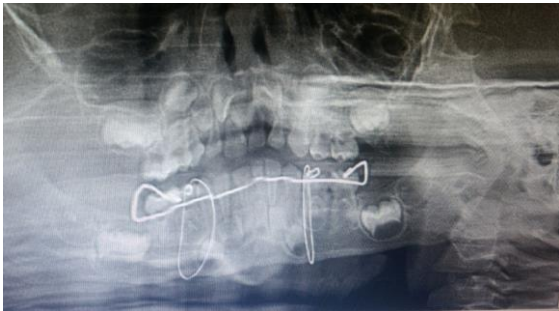


FIG 7: POST OP OPG