

PennHIP Report

Referring Veterinarian: Dr Jessica Kirkpatrick	Clinic Name: Cottonwood Veterinary Hospital MT
Email: cvhbozeman@gmail.com	Clinic Address: 450 N. Cottonwood Rd. Bozeman, MT 59718
	Phone: (406) 582-0555
	Fax: (406) 582-4496

Patient Information

Client: COOKE, KELLY	Tattoo Num:
Patient Name: PIPER	Patient ID: 16835
Reg. Name: NUMBER ONE LABAKAN SLOVAKIA (SLOVAK REPUBLIC)	Registration Num: DN53024103
PennHIP Num: 121320	Microchip Num:
Species: Canine	Breed: AUSTRALIAN SHEPHERD
Date of Birth: 05 Dec 2017	Age: 8 months
Sex: Female	Weight: 34.9 lbs/15.8 kgs
Date of Study: 21 Aug 2018	Date Submitted: 21 Aug 2018
Date of Report: 22 Aug 2018	

Findings

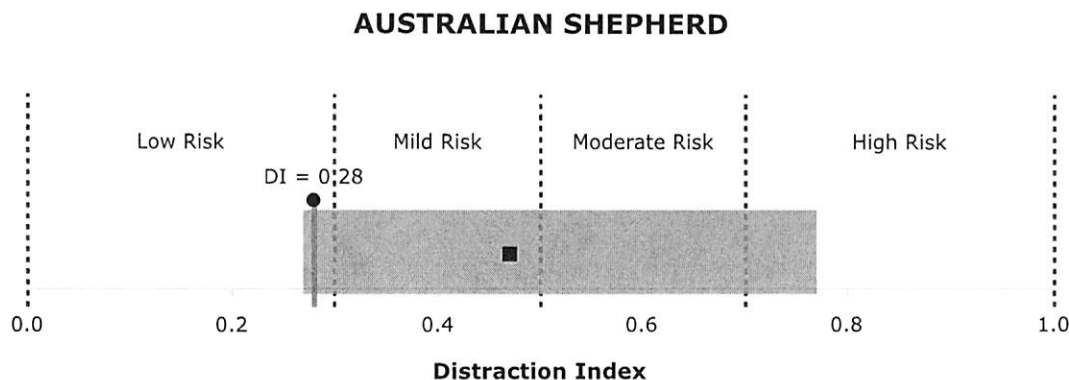
Distraction Index (DI): Right DI = 0.25, Left DI = 0.28.
 Osteoarthritis (OA): No radiographic evidence of OA for either hip.
 Cavitation/Other Findings: No cavitation present.

Interpretation

Distraction Index (DI): The laxity ranking is based on the hip with the greater laxity (larger DI). In this case the DI used is 0.28.

OA Risk Category: The DI is less than or equal to 0.30. This patient is at minimal risk for hip OA.

Distraction Index Chart:



BREED STATISTICS: This interpretation is based on a cross-section of 1329 canine patients of the AUSTRALIAN SHEPHERD breed in the AIS PennHIP database. The gray strip represents the central 90% range of DIs (0.27 - 0.77) for the breed. The breed average DI is 0.47 (solid square). The patient DI is the solid circle (0.28).

SUMMARY: The degree of laxity (DI = 0.28) falls within the central 90% range of DIs for the breed. This amount of hip laxity places hip at a minimal risk to develop hip OA. No radiographic evidence of OA for either hip.