



## Retinal microvascular alterations related to diabetes assessed by optical coherence tomography angiography

Mahmoud Ahmed Kamal, Ragai Magdi Hatata, Khalid Abd Arhaman, Shaimaa Hamada Mostafa

Ophthalmology Department, Faculty of Medicine, Fayoum University, Egypt  
[dr.shaimaahamada@yahoo.com](mailto:dr.shaimaahamada@yahoo.com)

**Abstract: Aim:** To investigate foveal avascular zone (FAZ) changes in eyes with nonproliferative diabetic retinopathy (NPDR) using optical coherence tomography angiography (OCTA). **Methods:** Cross sectional study of the eyes of diabetic patients with NPDR. All patients underwent medical history, best-corrected visual acuity measurement, slit-lamp and fundus examination. OCTA was performed in order to assess foveal avascular area and perimeter. **Results:** Seventy-two eyes of 40 patients and twenty eyes of 10 of control ones were included in this study. Among diabetic patients, 50% of cases had mild NPDR, 27.8% had moderate NPDR and 22.2% had severe NPDR. There was a significant progression between NPDR stages for FAZ grade. **Conclusion:** OCTA shows progressive increase of FAZ area.

[Mahmoud Ahmed Kamal, Ragai Magdi Hatata, Khalid Abd Arhaman, Shaimaa Hamada Mostafa. **Retinal microvascular alterations related to diabetes assessed by optical coherence tomography angiography.** *Biomedicine and Nursing* 2020;6(1): 39-42]. ISSN 2379-8211 (print); ISSN 2379-8203 (online). <http://www.nbmedicine.org>. 5. doi:[10.7537/marsbnj060120.05](https://doi.org/10.7537/marsbnj060120.05).

**Keywords:** Retinal; microvascular; alteration; diabetes; assessed; optical; coherence; tomography; angiography

### 1. Introduction

Diabetic retinopathy, also known as diabetic eye disease, is a medical condition in which damage occurs to the retina due to diabetes mellitus. It is a leading cause of blindness. [1] Diabetes mellitus is a disease that affects the retina and can also cause systemic microcirculatory disorders. When such microvascular complications progress, the risk of developing macroangiopathy also increases. [2,3]

Various methods have been used to assess FAZ as fundus photography, and fluorescein angiography. [4]

The technology of optical coherence tomographic angiography (OCT-A) is a major advance in ophthalmology and offers the opportunity to non-invasively visualize different retinal capillary layers without the need for injection of fluorescein dye [5]

In our study, we performed detailed quantitative analysis of FAZ to assess DMI in patients with NPDR using OCTA, a novel noninvasive technique that facilitates imaging of perfused retinal vascular structures within specific layers.

### 2. Materials and Methods

Cross-sectional study of 40 patients and 20 control persons were included in our study, which has been conducted at The Hospital of Fayoum University. We included adult patient older than 18 years old and had NPDR. The exclusion criteria were as follows:

media opacities preventing reliable retinal imaging, Macular edema with retinal thickness preventing good visualization of the FAZ by OCTA, Other retinal diseases (age-related macular degeneration, macular hole, epiretinal macular membrane, foveoschisis, and foveal hypoplasia), history of vitreoretinal surgery and history of macular laser grid.

#### Data collected included:

demographic information consisting of **age** and **gender** and clinical information consisting general medical history (smoking, high blood pressure); Diabetic medical history (type of diabetes, disease duration, oral diabetes medication, and insulin therapy); Ophthalmologic history (cataract surgery, intravitreal anti-vascular endothelium growth factor injections); Best corrected Snellen visual acuity; slit-lamp biomicroscopic and fundus examination; Spectral-Domain Optical Coherence Tomography (centered on the fovea) and Optical Coherence Tomography Angiography for macular retinal vascularization assessment.

#### Optical coherence tomography angiography

Optical Coherence Tomography angiography images were obtained using the prototype AngioVue OCTA software of the commercially available RTVue Spectral domain OCT device. This instrument has an A-scan rate of 70,000 scans per second, using a light source centered on 840nm and a band-width of 45nm. The tissue resolution is 5µm axially, and the beam is 22-µm wide.

The “en face” image was then automatically segmented with an inner boundary 3µm beneath the internal limiting membrane and an outer boundary 15µm beneath the inner plexiform layer (IPL) to obtain images of the superficial capillary plexus. The segmentation was carried out with an inner boundary 15µm beneath the IPL and an outer boundary 70µm beneath the IPL in order to obtain deep capillary plexus images. A 3×3mm and 6 x6 mm OCTA acquisition centered on the fovea was performed.

#### Statistical methods

Data were collected and coded to facilitate data manipulation and double entered into Microsoft Access and data analysis was performed using Statistical Package of Social Science (SPSS) software version 18 in windows 7.

Simple descriptive analysis in the form of numbers and percentages for qualitative data, and arithmetic means as central tendency measurement, standard deviations as measure of dispersion for quantitative parametric data.

Quantitative data included in the study was first tested for normality by One-Sample **Kolmogorov-Smirnov test** in each study group then inferential statistic tests were selected.

#### - For quantitative parametric data:

- In-depended **student t-Test** used to compare measures of two independent groups of quantitative data.

- One way **ANOVA** test in comparing more than two independent groups of quantitative data with

**benferroni** Post-HOC to test significance between each two groups.

- **Paired t-test** in comparing two dependent quantitative data.

#### For qualitative data

- **Chi square** test to compare two of more than two qualitative groups.

- **Bivariate Pearson correlation test** to test association between variables.

- The **P-value** ≤ 0.05 was considered the cut-off value for significance.

### 3. Results:

**This prospective observational study included** Seventy-two eyes of 40 patients with NPDR and 20 eyes of 10 normal patients. They were 15 men and 35 women. the mean disease duration of diabetes mellitus was (8.74 ±3.8) years and 50% depend on insulin treatment versus 50% uses oral hypoglycemic. Mean visual acuity (Log Mar) in diabetic patients was 0.5. Among the 72 included eyes, 50% of cases had mild NPDR, 27.8% had moderate NPDR and 22.2% had severe NPDR.

#### 1. FAZ measurement in diabetic and control patients:

Mean FAZ area with OCTA in patients affected with diabetes was 0.419 mm while in the control group was 0.157 mm and we found statistically significant difference with p-value <0.05 between diabetic patients and normal subjects as regards FAZ measures (Area, and perimeter ) with **high** mean value among cases of diabetes mellitus as shown in table 1.

**Table 1: Comparisons of FAZ measures in different study groups**

FAZ	Cases (n=72)		Control (n=20)		p-value	Sig.
	Mean	SD	Mean	SD		
FAZ-Area	0.419	0.06	0.157	0.08	<0.001	HS
FAZ-Perimeter	2.755	0.26	1.588	0.39	<0.001	HS

Considering patients affected by DR, FAZ area was 0.39±0.05 mm<sup>2</sup>, 0.40±0.03 mm<sup>2</sup> and 0.51±0.01 mm<sup>2</sup> in mild NPDR group, moderate and severe NPDR group respectively.

After comparing diabetic patient groups, there is statistically significant difference with p-value <0.05 between severe stage and both mild and moderate stages as regards FAZ area a with **high** mean FAZ among severe stage figure 1 and 2.

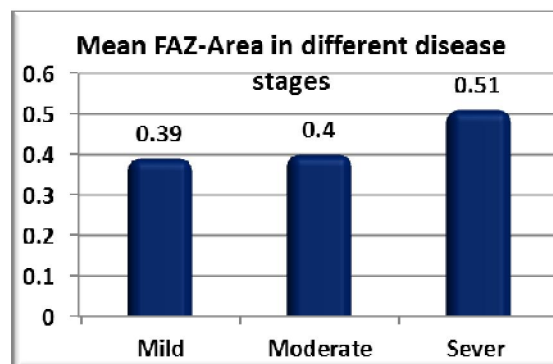
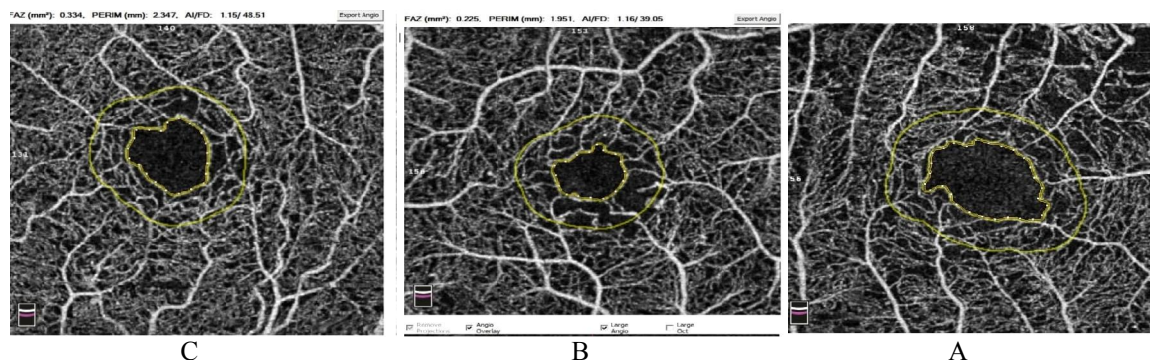


Figure (1)



**Figure 2** Representative OCTA images 3x3 scan of diabetic patients. There is increase in FAZ area in mild NPDR (a), moderate NPDR (b) and severe NPDR (C)

#### 4. Discussion:

Diabetic retinopathy represents one of the leading causes of visual impairment and blindness in the world. It is essentially microangiopathy that causes capillary occlusion, vascular hyperpermeability and neovascularization in the retina. It is crucial to detect non-perfusion areas or retinal neovascularization in order to evaluate diabetic retinopathy progression and decide on courses of treatment.

OCTA is a noninvasive technique that facilitates imaging of perfused retinal and choroidal vascular structures within specific layers. One of the most widely recognized uses of the OCTA concerns its capability to accurately assess the shape and size of the foveal avascular zone among diabetic patients with a different stage of disease severity.

We observed an enlargement of FAZ area and perimeter as the disease progresses. FAZ area was  $0.390 \pm 0.05 \text{ mm}^2$ ,  $0.400 \pm 0.03 \text{ mm}^2$  and  $0.510 \pm 0.01 \text{ mm}^2$  in mild NPDR group, moderate and severe NPDR group respectively. This was statistically significant.

Takase *et al.* [6] were the first to report an enlargement of the FAZ area, evaluated by en face OCTA in diabetic patients with or without DR compared to healthy subjects. In their study, the FAZ area in the superficial layer was  $0.25 \pm 0.06 \text{ mm}^2$  in healthy eyes ( $n = 19$ ), whereas it was  $0.37 \pm 0.07 \text{ mm}^2$  in diabetic eyes without retinopathy ( $n = 24$ ) and  $0.38 \pm 0.11 \text{ mm}^2$  in eyes with diabetic retinopathy ( $n = 20$ ).

The same results were obtained by Di *et al.* [7], Freiberg *et al.* [8], Rodolfo [9].

In contrast, the study done by Lun *et al.* (2018) [10] showed no significant change in the FAZ area during progression of DR. This could be related to the high variability of the FAZ area. There is considerable variation in the FAZ area between normal individuals and patients with diabetes.

A previous report by Balaratnasingam *et al.* [11] observed a significant correlation between FAZ area and visual acuity in diabetic eyes with macular edema. Furthermore, Samara *et al.* (2017) [12] observed similar results in an evaluation of the correlation between FAZ area and visual function in diabetic eyes without macular edema, as patients with larger FAZ area exhibited decreased visual acuity. Our results indicate a significant positive correlation between FAZ area and LogMAR VA in diabetic eyes, whereas eyes with larger FAZ area exhibited decreased VA (with  $p$ -value  $< 0.05$ ).

#### References:

1. Ruta LM, Magliano DJ, Lemesurier R, Taylor HR, Zimmet PZ, Shaw JE. Prevalence of diabetic retinopathy in Type 2 diabetes in developing and developed countries. *Diabet Med* 2013; 30:387–398.
2. Fuller JH, Stevens LK, Wang SL. Risk factors for cardiovascular mortality and morbidity: the WHO Multinational Study of Vascular Disease in Diabetes. *Diabetologia* 44(Suppl 2) 2001: S54–S64.
3. Adler AI, Stevens RJ, Manley SE, Bilous RW, Cull CA, Holman RR, UKPDS GROUP. Development and progression of nephropathy in type 2 diabetes: the United Kingdom Prospective Diabetes Study (UKPDS 64). *Kidney Int* 2003 63(1):225–232.
4. Ahmad Fadzil M, Ngah NF, George TM. Analysis of foveal avascular zone in colour fundus images for grading of diabetic retinopathy severity. *Conf Proc IEEE Eng Med Biol Soc* 2010; 5632–5.
5. Spaide RF, Klancnik JM Jr, Cooney MJ. Retinal vascular layers imaged by fluorescein angiography and optical coherence tomography

- angiography. *JAMA Ophthalmol.* 2015; 133(1):45-50.
6. Takase N, Nozaki M, Kato A, Ozeki H, Yoshida M, Ogura Y. Enlargement of foveal avascular zone in diabetic eyes evaluated by enface optical coherence tomography. *Retina.* 2015;35(11):2377–2383.
  7. Di G, Weihong Y, Xiao Z, Zhikun Y, Xuan Z, Yi Q, Fangtian D. A morphological study of the foveal avascular zone in patients with diabetes mellitus using optical coherence tomography angiography. *Graefes Arch Clin Exp Ophthalmol.* 2016;254(5):873–879.
  8. Freiberg FJ, Pfau M, Wons J, et al. Optical coherence tomography angiography of the foveal avascular zone in diabetic retinopathy. *Graefes Arch Clin Exp Ophthalmol* 2016; 254:1051-8.
  9. Rodolfo A, Toto L, Aloia R, Nicola CD, Mattei PA, Maizo GD, Nicola DM. Foveal avascular area and parafoveal vessel density measurement by OCTA. *Int J Ophthalmol.* 2017; 10(10):1545-1551.
  10. Lun Liu, Jian Gao, Weili Bao, Chengyang Hu, Yajing Xu, Lingling Fan, and Yehuan Sun. Analysis of Foveal Microvascular Abnormalities in Diabetic Retinopathy Using Optical Coherence Tomography Angiography with Projection Artifact Removal.
  11. Balaratnasingam C, Inoue M, Ahn S, Mccann J, Dhrami Gavazi E, Yannuzzi LA, Freund KB. Visual acuity is correlated with the area of foveal avascular zone in diabetic retinopathy and retinal vein occlusion. *Ophthalmology* (2016) 123 (11): 2352-2367.
  12. Samara WA, Shahlaee A, Adam MK, Khan MA, Chiang A, Maguire JI, Hsu J, Ho AC. Quantification of diabetic macular ischaemia using OCTA and its relationship with visual acuity. *Ophthalmology* (2017) 124(2):235-244.

3/9/2020