

IMMEDIATE LOADING WITH MINI DENTAL IMPLANTS IN THE FULLY EDENTULOUS MANDIBLE

Abdulgani Azzaldeen *, Abusalih Ahmet, Hakki Ismail, Chlorokostas Georges, Abu-Hussein Muhamad
Al-Quds University, Faculty of Dentistry, Jerusalem, Palestine

ABSTRACT:

Mini dental implants (MDI) have become increasingly popular in the past decade and have been approved for many long-term uses in dentistry. There are many advantages of the use of mini dental implants from both a practitioner and patient perspective. For the general dentist starting out in implant dentistry, their placement can be more challenging than conventional implants. It requires a different skill set, but one which can be learned with proper guidance and practice. In the study are presented clinical cases with mini implants with spherical joints for retention of removable overimplant mandibular dentures.

Key words: mini dental implants, immediate loading implants Prosthetics, overdenture

INTRODUCTION:

The key features and the prime requisites of an ideal prosthesis for the rehabilitation of the stomatognathic system include the restoration of normal contour, function, esthetics, comfort, speech, and health. Assimilation of these features in any prosthesis delivered to the patient is the ideal goal of modern dentistry. However, with the highly complicated and challenging clinical situations which are commonly encountered in the general practice, an ideal replacement of the lost tissues using the conventional techniques may not be always possible. Answer to such a clinical dilemma would probably be Implant therapy.^[1,2]

Implant dentistry is unique because of its ability to achieve an ideal replacement of the lost tissues, regardless of the atrophy, disease, or injury of the stomatognathic system^[2,3]. This has significantly increased the acceptance of osseointegrated supported prosthesis by

the patients. However, greater the destruction of the stomatognathic system, the more challenging is the task of rehabilitation. As a result of the current availability of the advanced diagnostic tools which aid in treatment planning, the improved implant designs, materials, and techniques as a result of continuous research, many challenging clinical situations can be successfully managed with predictable success.^[1,2,4,5,6]

Recently, mini-implant has been used as transitional implants to support dentures during the healing phase of implant denture restoration. It is also used as a permanent single implant crown in inadequate space for standard implants and limited bone availability situations.^[4,5]

The use of dental implants of smaller diameters in various forms has been present for almost 20 years. Those are

generally 2.75 mm to 3.3 mm in diameter, and they are frequently used in cases of limited bone volume. Mini dental implants (MDIs) are even smaller, with diameters ranging from 1.8 mm to 2.4 mm [4,5,6].

In the last few years mini-implants became widely used as an orthodontic anchorage, single and multiple tooth fixed replacement, bridge repair and removable prosthesis retention, where they became a key solution for many challenging situations [7,8]. Further, the evolution of the dental implantology science generates technological breakthroughs in the miniimplant design. This development includes enhancement of the implant shape, thread patterns and its surface treatments, which have considerably improve primary stability and lead to faster osseointegration [9,10]. Implant size influences the area of possible retention in bones. Additionally, factors such as occlusion, masticatory forces, number of implants and their position within the prosthesis affect the forces acting on the bone adjacent to the implants [11,12]

. Holmgren et al., added that load direction in addition to implant diameter and shape influence stress distribution. [13]

They are simply placed into the jawbone. and have several advantages over standard-size implants:

a-Minimum trauma to the implant site,

b- immediate stability upon completion of placement.

c- Mini-dental implants are surprisingly affordable and are usually available at a fraction of the cost of traditional implants.

In the study are presented clinical cases with mini implants with spherical joints for retention of removable overimplant mandibular dentures

MATERIALS AND METHODS:

Patient in the age of 54 came for examination in our clinical department. He was not satisfied with the existing removable dentures, especially the lower one. He had been informed about the possibilities of implant therapy and fixed prosthodontic construction, but he could not afford it. **Figure 1,2**

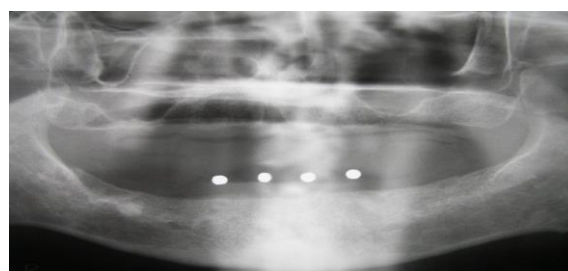


Figure 1; Orthopantomograph with visible lead markers

The orthopantomograph (with the tray) was taken in order to evaluate the possibility of mini-implant insertion, and to determine their position and size,. The prosthetic expertise with financial construction was made for the patient. Since it was much cheaper than previously suggested implant supported by fixed prosthetic appliance, the patient

decided to make lower removable denture (overdenture) supported with four MDIs Sendax type with ball attachments.

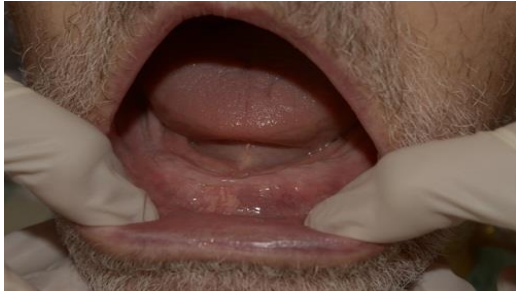

Figure 2;Pre-operative mandibular arch

According to the orthopantomograph findings, correction of future implant sites was performed. The tray was punctured on selected spots by grinding bur and placed into the patient's mouth. The implant sites were marked through the holes in acrylic baseplate with surgical marker and transgingival implantation was performed. The gingiva was punctured on the marked spots, and the bone was initially drilled with the locator drill according to the marks made with surgical marker **Figure 3**. The bone drilling was performed by using disposable surgical drill of 1.1 mm diameter to the depth of 1 length of implant as recommended by the manufacturer. Parallelization of the implants was achieved with the insertion of sterile, previously used, surgical drills into each drilled implant site. After drilling, the MDIs Sendax Classic Standard, O-Ball dimensions 1,8 mm (diameter) x 15 mm (length) were screwed firstly by using manual screwing instrument, and afterwards

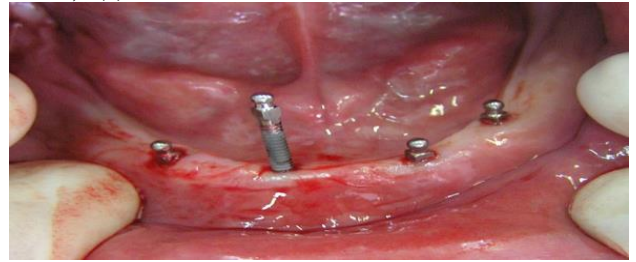


Figure 3 Implantation of mini dental implants with ratchet (torque 35 N/cm). Since it was not possible to screw MDI to the end of the length, it was unscrewed and displaced. For that reason, the primarily drilled holes were deepened to the depth of 2/3 of the implants length, and in repeated screwing, it was possible to screw MDI to the end. **Figure 4**

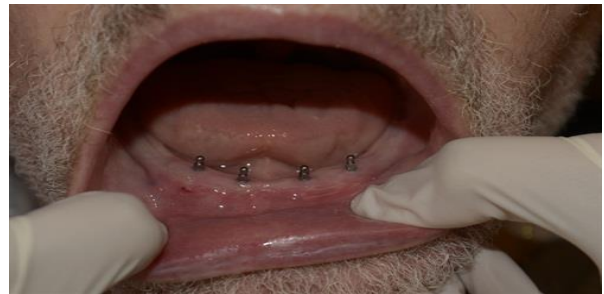

Figure 4.; Placed mini dental implants

The laboratory implants were inserted into the impression copings (Figure 6), and the models were poured in hard stone. Micro metal housings were placed onto the laboratory implants, and the metal base of the lower overdenture was produced. Further clinical and laboratory procedures were performed according to the routine procedure for lower denture production. **Figure 5,6**

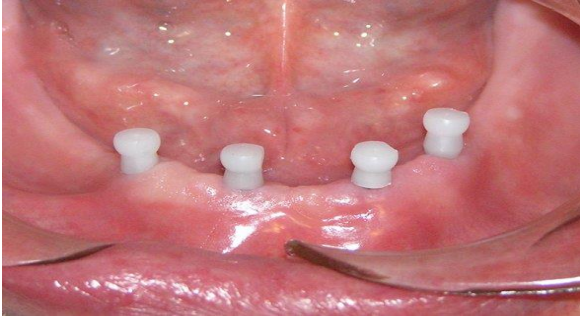


Figure 5; Positioning of transfer (impression) copings onto implants




Figure 6; laboratory implants and placed metal housings

RESULTS:

Usual and adequate retention and stability of upper denture was obtained, but with the use of MDIs they were obtained for the lower denture, too. That resulted with the satisfactory function and phonation, and with unavoidable esthetics. **Figure 7a,b**

There is no swelling or pain in the postoperative period. The patients feel comfortable, because of the immediate denture placement and the chance to eat right after the surgery. Three years later there is no clinical or X-ray evidence about bone resorption. The retention rings are changed every 12 months.

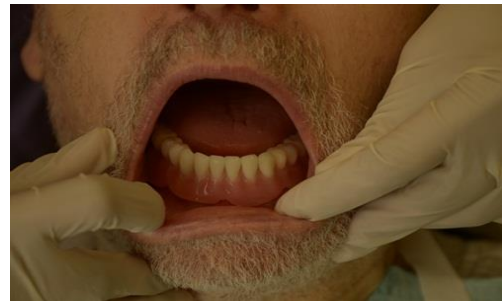
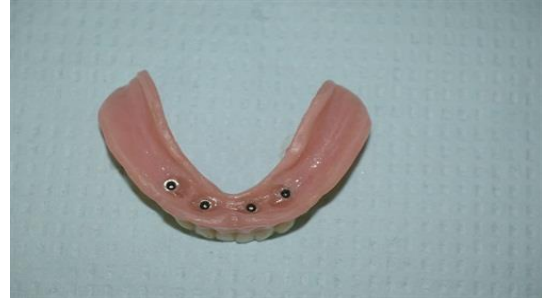
Figure 7a,b;(a) Metal housings built in metal base lower denture (b) Dentures in patient's mouth

DISCUSSION:

This approach is particularly suitable for elderly patients or for ones with serious general disorders. It is a way to avoid highly invasive surgical interventions. The surgical and prosthetic protocol is easy to perform, even for general dental practitioners. It is important to pay attention to the necessity of high initial stability of the implant. On the other hand, the insufficient instrumentation of the osteotome opening could lead to implant's breaking (due to its small diameter).^[1,2,4,11]

Jefferies et al., (2008) studied the detachment retentive forces of both conventional and mini-implants by evaluating their detachment speed. However, the values were not indicative whereas the detachment force showed some relevance in certain speeds.^[14]

Ahn et al., investigated miniimplants as retentive aid for overdenture. Their study revealed a high success rate and a favorable prosthetic outcome that augment their use in edentulous arches. They also emphasized that miniimplant could be a good solution for those patients suffering from discomfort and less functional dentures.^[15]

Several researches showed the success of mini-implant overdentures, however long term evaluation is lacking . More studies need to be carried out to provide additional rigorous scientific evidence to support this therapeutic paradigm. Away from the rush of using and deliberating these implants as a substitution for conventional implants, further studies should be carried out to accredit this substitution.^[16,17]

Mini dental implants have many benefits such as expanding the bone as they are placed, minimal osteotomy size required as well as immediate stabilization and loading on the day of placement and so fewer treatment visits. Moreover, flapless placement leads to minimal surgical trauma, easier removal and healing in case of failure. Their cost is also significantly less than conventional implants.

Flanagan conducted several studies regarding mini-implants and debated that the use of small diameter implants when a standard implant could be used. He clarified that the smaller the implant size used the lesser the surface area in contact with the bone and so more occlusal force controlling factors are

required. Conversely, he added that very small diameter implants might have physiological preference. He clarified that the circumference of a 2 mm implant is 6.28 mm whereas the circumference of a standard 4 mm diameter implant is 12.56 mm. Accordingly, the small implant has half of the linear percutaneous exposure thus exposing less of the implant-gingival attachment to bacterial attack. He also expected an extra available osseous blood supply for the implant supporting bone and so better angiogenesis. In larger diameter implant a barrier to blood supply may hinder angiogenesis and subsequent osteogenesis around a newly placed implant compared to the smaller implants .

Study of Balkin et al. , in which they used histological analysis, revealed that the quality of MDIosseointegration could be compared with the quality of larger diameter implants osseointegration^[18]. Ertugrul et al. , in their in vitro study, revealed that implants of larger diameter are more stable under lateral forces than MDIs. But it is logical, because of their almost doubly bigger surface area. In clinical practice, this „disadvantage“ of MDIs can be solved with successful planning and using more implants^[19]

Griffitts et al. were evaluating the patients' satisfaction with overdentures supported with MDI (comfort, retention, chewing ability and speaking ability), and they found that patients' satisfaction was excellent. Taking into consideration

all advantages of MDI (success rates, surgical technique, financial advantages, possibilities of immediate loading), it can be concluded that MDI are highly successful implant option for edentulous mandible.^[20]

Shatkin et al , in their retrospective analysis over five years of 2514 MDIs, which equally supported fixed and removable prostheses, found the overall implant survival rate of 94.2%. Initial stability is important for the successful osseointegration and high implant success rate. It is stipulated with bone quality, implant design, and surgical technique that is used.^[21]

A recent study in which six mini-implants were installed to stabilise full maxillary dentures with or without palatal coverage also reported high implant failure rates; 21,6% and 46,2%, respectively ^[22] . The authors attributed the high failure rate to facial angulations of maxillary implants, a thick masticatory mucosa that necessitated longer implant abutments, and disparallelism of the unsplinted implants that may have produced micromovements in conjunction with multiple insertions and removals of the prosthesis.^[22]

The original implant dimension, as described by Branemark, was 3.7 by 10mm. Branemark felt this dimension fulfilled the need for all implant therapy. In today's practice, implants of varying dimensions are now available. Implants with a diameter of 3.75 mm have been considered standard, below and above which have been considered as narrow

and wide diameter, respectively. Implants with a length of less than 10mm are considered short. A reduction of implant diameter and length results in a proportional decrease of implant surface area. This infers a decreased implant-to-bone contact area^[23].

The biomechanical impact of smaller dimensional implants was discussed earlier in this paper with there being higher crestal strain, lower pull out force and lower structural integrity as the implant dimension is reduced. Theoretically, this could translate to lower clinical success rates for implants of lesser dimensions.^[24]

The use of CBCT scans for treatment planning of dental implants has become largely recognized as a high quality, time and cost effective, imaging method . Several studies have confirmed that linear measurements on CBCTs images present the necessary accuracy for use in dentistry). In well controlled studies, Mozzo et al. (1998) and Moreira et al. assessed the CBCT's geometric accuracy and reported that differences between simulated mandibular bone and dry human skulls to images generated from CBCT's ranged from 0.15 to 2 %, for linear measurements (in width and height, respectively) and 0.33 % for angular measurements). Based on the ability of the system to reconstruct anatomic structures with dimensions considered "close to real", the data obtained with CBCT scans were used in the present investigation as reference

for comparisons with the data assessed with the Conventional method.^[25,26]

Two categories of complications can occur in implant therapy: biological and technical or mechanical. Biological complications refer to any disturbance in the peri-implant tissue that results in a decrease of function or eventual loss of the implant fixture. This includes peri-implantitis/progressive bone loss, peri-implant mucositis, periapical implantitis, or sensory disturbance. Technical or mechanical complications refer to mechanical damage of the implant fixture and/or implant components and its suprastructures. This can include screw loosening, screw fracture, fixture fracture, and prosthetic issues. Review of the reported complications revealed more reports on complications of technical or mechanical nature than complications biological in nature.^[27,28,29]

The short- and medium length mini-implants (7– 10 mm) presented a higher failure rate than the long mini-implants (14 mm), 38% versus 3%. The fact that the use of the long implants in the replacement of the lost implants resulted in maintenance of the implants in proper function throughout the observation period further indicates that long implants should be selected for the best prognosis of the treatment ^[1].

An insertion torque of 35 N/cm is necessary for narrow implants to achieve a degree of primary stability sufficient for immediate loading. In the present case, an insertion torque of 35 N/cm was

achieved without fracture of the mandible or implants.^[1,2]

The biomechanical aspects of the narrow implant, such as the distribution and control of the forces and movement of the prosthesis, should also be considered and evaluated. Masticatory forces produce axial forces and bending moments that could result in stress on the implant as well as on the bone, thereby compromising the longevity of the implant. Narrow implants have a smaller surface and, therefore, an overall increase in the magnitude of stress and strain experienced by the load-carrying system compared to conventional implants. However, this aspect does not contraindicate the use of narrow implants in older patients, because, in most cases, occlusal forces are slightly reduced owing to age-related deterioration of the dentition. The masticatory forces and the quality of cancellous bone should always be evaluated before narrow-implant-retained overdentures are selected as a treatment .^[2,31,32]

It is necessary to relines the complete dentures on a regular basis and to perform occlusal adjustments for better force and movement distribution in all narrow implant-supported overdentures in order to avoid implant fracture and overload-induced bone loss around the implants. These steps were followed in the present case and were essential for the longevity of the success.^[1,32,33,34]

Although mini-implant overdenture is a successful alternative for conventional two-implant overdenture, the conventional overdenture treatment option exhibited more favorable clinical and radiographic outcome than mini-implant overdenture.

CONCLUSION:

The use of implants in the edentulous arch has changed the way in which patients can be treated. Standard diameter implants have been utilized successfully for more than twenty years for overdenture patients, and more recently narrow-diameter implants

have been utilized. Both standard and narrow-diameter implants have demonstrated high success and survival rates and are associated with improvements in function and patient comfort.

In conclusion, the placement of mini-implants as retentive elements for full dentures with poor functional stability had a marked positive effect on the patients' perception of oral function and comfort as well as security in social life. However, the treatment approach may be less predictable in the maxilla and with the use of short implants .

REFERENCES:

1. Abu-Hussein M. , Abdulgani A., Bajali M., Chlorokostas G .; The Mandibular Two-Implant Overdenture. *Journal of Dental and Allied Sciences* , 2014 , Vol 3,1; 58-62
2. Abu-Hussein M ., Abdulgani A . ;MANDIBULAR IMPLANT OVERDENTURE RETAINED WITH O-RING BALL, *Int J Dent Health Sci* 2014; 1(6):984-991
3. Bressan E, Tomasi C, Stellini E, Sivoletta S, Favero G, Berglundh T. Implant-supported mandibular overdentures: a cross-sectional study. *Clin Oral Implants Res.* 2012;23:814–819.
4. Christensen GJ, Swift EJ Jr. Mini implants: good or bad for the long-term service? *J Esthet Restor Dent.* 2008;20:343– 348.
5. LaBarre EE, Ahlstrom RH, Noble WH. Narrow diameter implants for mandibular denture retention. *J Calif Dent Assoc.* 2008;36:283–286.
6. Flanagan D. Implant-supported fixed prosthetic treatment using very small-diameter implants: a case report. *J Oral Implantol.* 2006;32:34–37.
7. Bryant SR, MacDonald JD, Kim K. Does the type of implant prosthesis affect outcomes for the completely edentulous arch? *Int J Oral Maxillofacial Implants.* 2007; 22(Suppl):117-139.
8. Shawneen MG. Cortical bone thickness of the maxilla and mandible for mini-implant placement. PhD thesis, The University of Iowa August 2008

9. Jones AA, Cochran DL. Consequences of Implant Design. Dent Clin of North Am 2006; 50(3):339-360.
10. Sakoh J, Wahlmann U, Stender E, Nat R, Al- Nawas B, Wagner W. Primary stability of a conical implant and a hybrid, cylindrical screwtype implant in vitro. International Journal of Oral & Maxillofacial Implants. 2006; 21(4):560-566.
11. Christensen GJ. The mini-implant has arrived. J Am Dent Assoc 2006;137(3):387-90.
12. Froum SJ, Simon H, Stuart J, Cho SC, Elian N, Michael DR, Tarnow DP. Histologic evaluation of bone implant contact of immediately loaded transitional implants after six to 27 months. J Oral Maxillofac Implants 2005;20:54-60.
13. Holmgren EP, Seckinger RJ, Kilgren LM, Mante F. Evaluating parameters of osseointegrated dental implants using finite element analysis; a two dimensional comparative study examining the effects of implant diameter, implant shape, and load direction. J Oral Implantol 1998; 24:80-88
14. Jefferies SR, Boston DW, Damrow MP, Galbraith CT. Comparison of detachment forces of two implant overdenture attachment types: effect of detachment speed. Am J Dent. 2008;21(4):244-250.
15. Ahn MR, An KM, Choi JH, Sohn DS. Immediate Loading With Mini Dental Implants in the Fully Edentulous Mandible. Implant Dent 2004; 13: 367-72.
16. Mazor Z, Steigmann M, Leshem R, Peleg M. Mini-implants to reconstruct missing teeth in a severe ridge deficiency and small interdental space: a 5 year case series. Implant Dent. 2004;13:336-341.
17. Vigolo P, Givani A. Clinical evaluation of single mini-implant restorations: a five year retrospective study. J Prosthet Dent. 2000;84:50-54.
18. Balkin BE, Stefl ik DE, Naval F. Mini-dental implant insertion with the auto-advance technique for ongoing applications. J Oral Implantol. 2001;27(1):32-7.
19. Ertugrul HZ, Pipko DJ. Measuring mobility of 2 dental implant fixtures of different configurations: an in vitro study. Implant Dent. 2006;15(3):290-7.
20. Griffiths TM, Collins CP, Collins PC. Mini dental implants: an adjunct for retention, stability, and comfort for the edentulous patient. Oral Surg Oral Med Oral Pathol Oral Radiol Endod. 2005;100(5):e81-4.
21. Shatkin TE, Shatkin S, Oppenheimer AJ. Mini dental implants for the general dentists: A novel technical approach for small-diameter implant placement. Compend Contin Educ Dent. 2003;24(Suppl 1):26-34.
22. Elsyad MA, Ghoneem NE, El-Sharkawy H. Marginal bone loss aroundunsplinted mini-implants supporting maxillary overdentures: a preliminary comparative study between partial and full palatal

- coverage. *Quintessence Int.* 2013;44:45–52.
23. Malo P, De Araujo Nobre M, Rangert B. Short Implants placed one stage in maxillae and mandibles: a retrospective clinical study with 1 To 9 Years of follow---up. *Clin Implant Dent Relat Res* 2007;9(1):15---21.
24. Allum SR, Tomlinson RA, Joshi R. The Impact of loads on standard diameter, small diameter and mini implants: a comparative laboratory study. *Clin Oral Implants Res*, 2008;19(6):553---9.
25. Mozzo P, Procacci C, Tacconi A, Martini PT, Andreis IA. A new volumetric CT machine for dental imaging based on the cone-beam technique: preliminary results. *Eur Radiol* 1998;8(9):1558-64.
26. Moreira CR, Sales MA, Lopes PM, Cavalcanti MG. Assessment of linear and angular measurements on three-dimensional cone-beam computed tomographic images. *Oral Surg Oral Med Oral Pathol Oral Radiol Endod* 2009 Sep;108(3):430-6
27. Dilek OC, Tezulas E. Treatment of a narrow, single tooth edentulous area with mini-dental implants: a clinical report. *Oral Surg Oral Med Oral Pathol Oral Radiol Endod.* 2007;103(2):e22-5.
28. Bulard RA, Vance JB. Multi clinic evaluation using mini-dental implants for long term denture stabilization: a preliminary biometric evaluation. *Compend Contin Educ Dent.* 2005;26:892–897.
29. Linkevicius T, Apse P, Grybauskas S, Puisys A. The influence of soft tissue thickness on crestal bone changes around implants: a 1-year prospective controlled clinical trial. *Int J Oral Maxillofac Implants.* 2009; 24:712–719.
30. Scepanovic M, Calvo-Guirado JL, Markovic A, Delgado-Ruiz R, Todorovic A, Millicic B, et al. A 1-year prospective cohort study on mandibular overdentures retained by mini dental implants. *Eur J Oral Implantol* 2012; 5: 367-79.
31. Cehreli MC, Akca K. Narrow-diameter implants as terminal support for occlusal three-unit FPDs: a biomechanical analysis. *Int J Periodontics Restorative Dent.* 2004;24(6):513-519.
32. Morneburg TR, Proschel PA. Success rates of microimplants in edentulous patients with residual ridge resorption. *Int J Oral Maxillofac Implants.* 2008;23(2):270-276.
33. Singh RD, Ramashanker, Chand P. Management of atrophic mandibular ridge with mini dental implant system. *Natl J Maxillofac Surg.* 2010;1(2):176-178.
34. Bidra AS, Almas K. Mini implants for definitive prosthodontic treatment: a systematic review. *J Prosthet Dent.* 2013;109(3):156-164.