

Case Study Phase II: Tumor Treatment using 3% Hydrogen Peroxide in Ornamental Koi Carp

Copyright © 2017 Laurel Nason

All Rights Reserved



www.desertrainbowkoi.com

Introduction

In Phase I of this case study, injections of 3% hydrogen peroxide directly into an aggressive tumor in a Shiro Utsuri koi were able to reduce the tumor but not eradicate it. On June 25th (see Figure 1 and Figure 2 at end of Phase I) the koi tumor had shrunk and exhibited a much improved facial contour.



Figure 1. End of Phase I - Koi

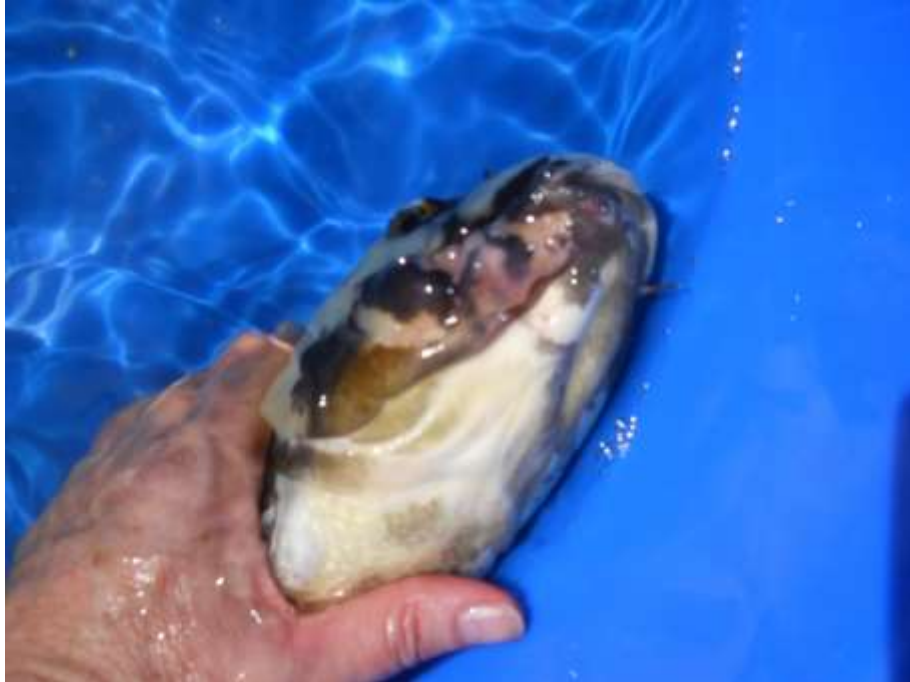

Figure 2. End of Phase I – Much improved contour

In Figure 2, there is evidence on the right underside part of the right jaw, of pink fleshly-like areas where the tumor was still visible but showed significant shrinkage. No further injections were performed from June 25th through July 8th. On July 8th, the koi was re-examined and it was obvious that without the injections, the tumor had indeed grown in size and there were many localized areas of small tumors (tapioca-like growths), see Figure 3 and Figure 4. The Phase II trial study was initiated on July 8th with additional injections of 3% hydrogen peroxide using the same protocol that was used in phase I.

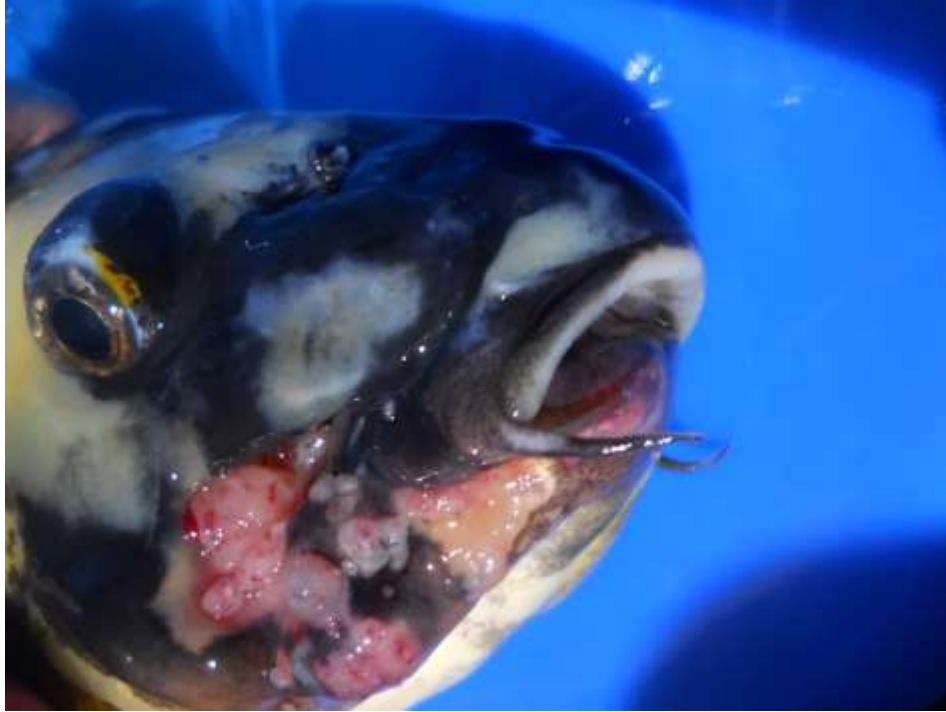


Figure 3. July 8th Re-examination of koi showing regrowth of tumors



Figure 4. Phase II Tumor location approx. 1.5 inches in length (mouth to gill)

Protocol/Methodology

On July 9th the koi was injected with a syringe (approx. 3 ccs total) of hydrogen peroxide in multiple areas within the lower jaw. Several soft fatty tumor areas (within 1 minute after the injection) show various responses to the hydrogen peroxide. Not as visible in Figure 5 is the hard tumor mass located in the bottom right jaw (below and to the left of the injection site showing the largest reaction). Some injections did not appear to bother the koi, yet at other injection sites the koi would make jerking movements for several seconds afterward. The hard tumor seems to shrink the most initially after an injection and cause the most reaction from the koi during the injection.

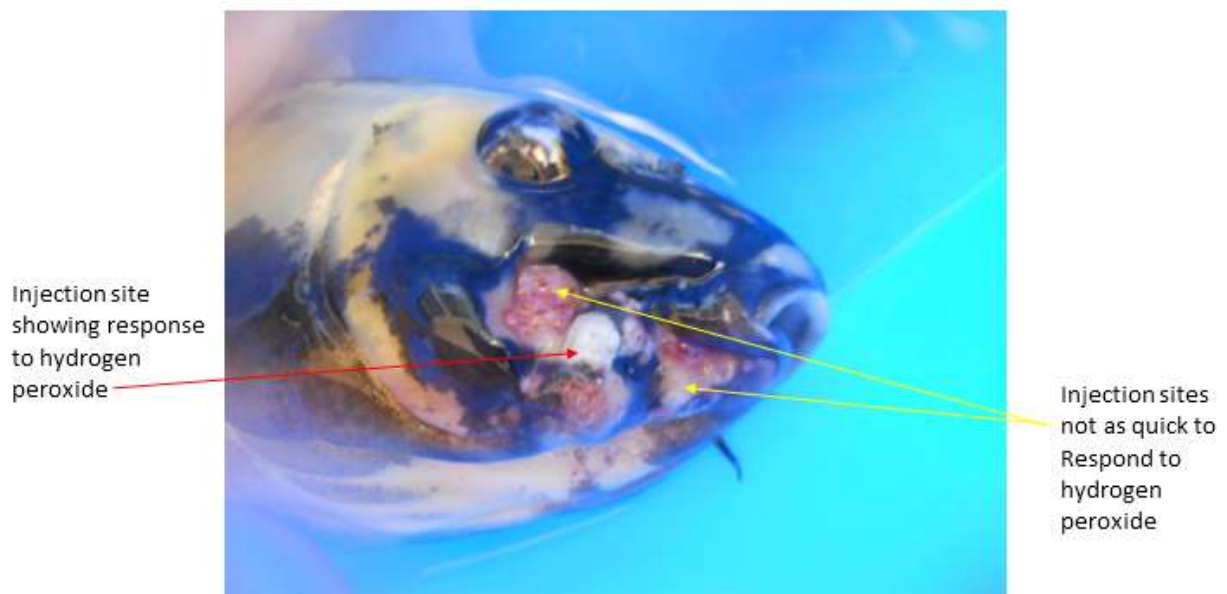


Figure 5. Tumor Reaction to Hydrogen Peroxide – July 9th

The koi was injected with a syringe of 3% hydrogen peroxide once a week or once every two weeks through Sept 10th. The koi was placed in a plastic bag with enough water to cover the gills and body but wrapped tight enough to allow the injections and minimize movement. Each time the fish was injected in 3 or 4 different locations. During this phase, the tumors seemed more resistive to the hydrogen peroxide. For these two months the treatments prolonged the koi's life. Pictures of the koi were taken on Sept 10th (see Figure 6 and Figure 7). The tumors are still present and have grown larger in some areas and have been reduced in other areas, see Figure 7.

Several new tumors have emerged along the jawbone and mouth area. After these photographs were taken, the koi was injected with another round of hydrogen peroxide.

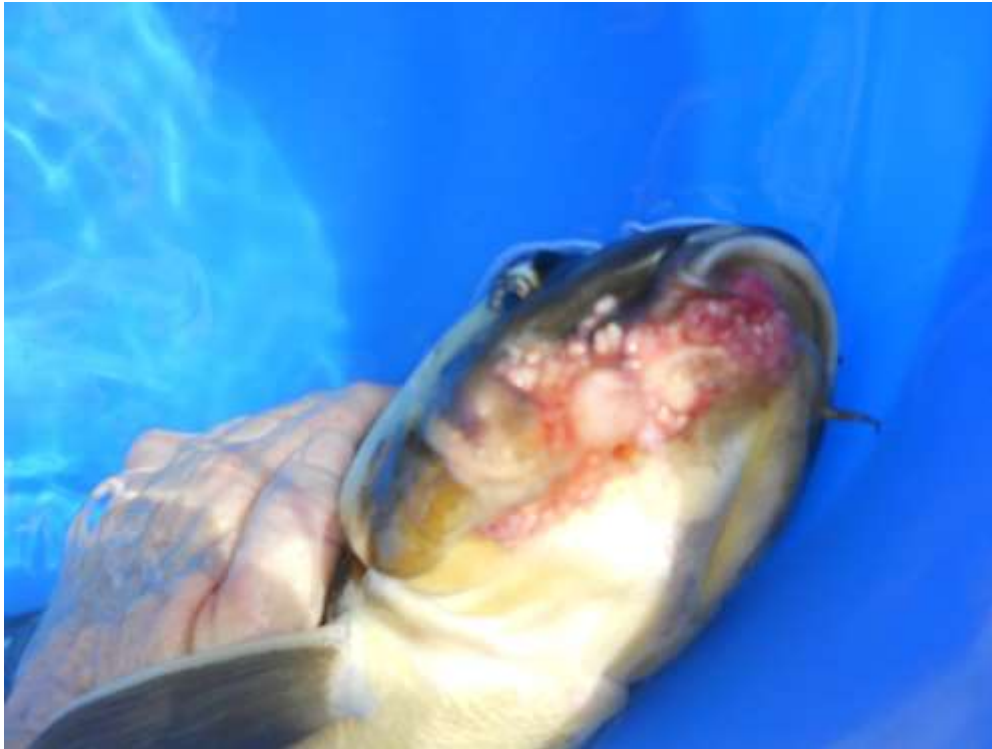

Figure 6. Tumor Growth on Sept 10th

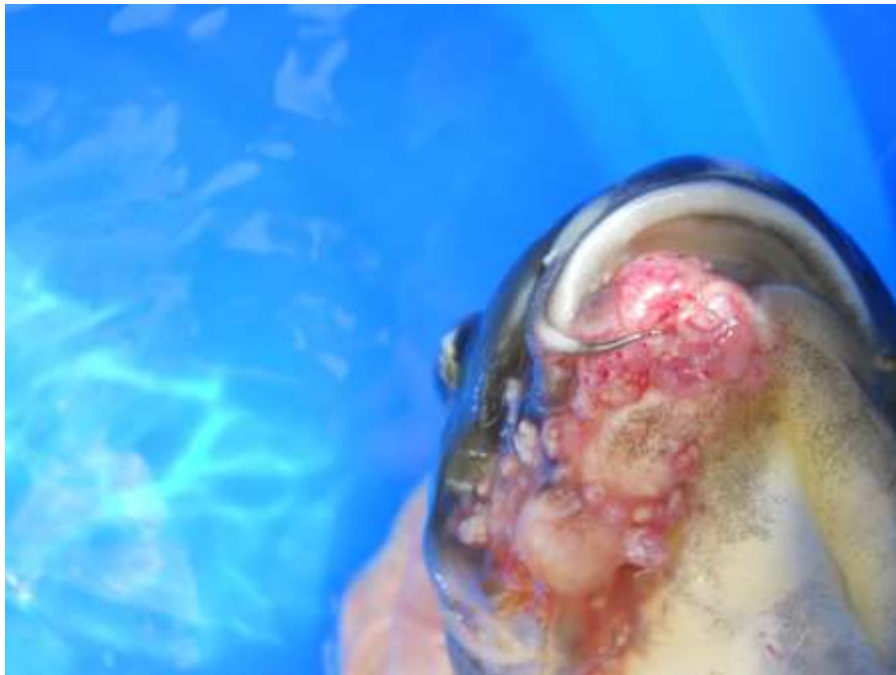

Figure 7. End of Phase II – Tumor growth in areas outside the immediate injection site

Summary

In Phase II, the 3% hydrogen peroxide infrequent injections (weekly or twice a week) have not eliminated the tumor(s). Results are somewhat disappointing. Regrowth has occurred, but injections have prolonged the koi's life and the fish continues to swim and eat small/medium pellet food. There is no visible evidence of the tumor spreading to other areas of the koi. The Phase III trial, which will begin Sept 16th, higher strength hydrogen peroxide will be used. The koi will be injected with 35% hydrogen peroxide into the hard tumor areas and larger soft tumor areas. Less hydrogen peroxide will be injected since the strength (oxygen content) is significantly higher. The injection locations (see Figure 8) will be lower jaw, fleshy cheek and mouth area. The koi will be reexamined on Oct 1st.

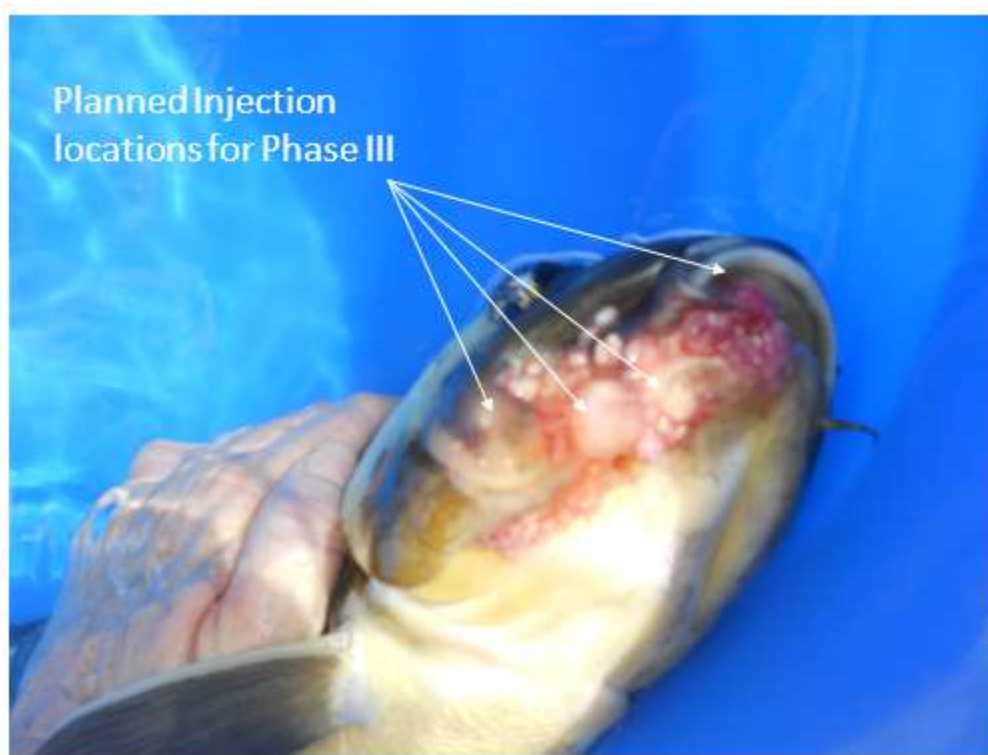

Figure 8. Phase III Planned Initial Injection Locations