

## RACZ Catheter Lysis of Adhesions

### OVERVIEW

Also called Lysis of Adhesions, this procedure is performed to remove excessive scarring in the epidural space otherwise inaccessible by normal epidural. The epidural space is a thin area between the inside of the spine and the protective layer around the spinal cord. Scar tissue may restrict the natural movement of nerves causing inflammation therefore creating pain.

### STEP 1

A local anesthetic numbs the skin and tissue below.

### STEP 2

The physician inserts the catheter into the epidural space under fluoroscope at the nearest convenient region usually the caudal canal, via the sacral hiatus. The sacral hiatus is a natural opening in the spine near the end of the tailbone. Aided by fluoroscopy the catheter can be seen and directed to the affected nerve root.

### STEP 3

A contrast solution is injected so the physician can use the fluoroscope to locate and confirm the correct location of the catheter.

### STEP 4

A steroid-anesthetic solution is injected to relieve pain, dissipate scar tissue and reduce inflammation.

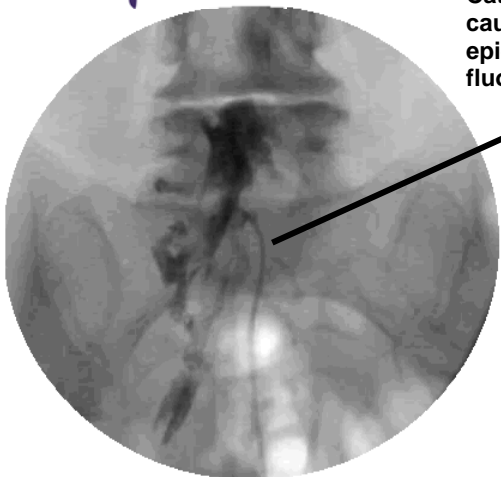
### STEP 3

You will be observed in the patient recovery area. It is important to remember that this procedure is only part of your treatment. The steroid anesthetic solution help to break up scarring around the nerve root and reduce swelling. This procedure may need to be repeated if scar tissue returns.

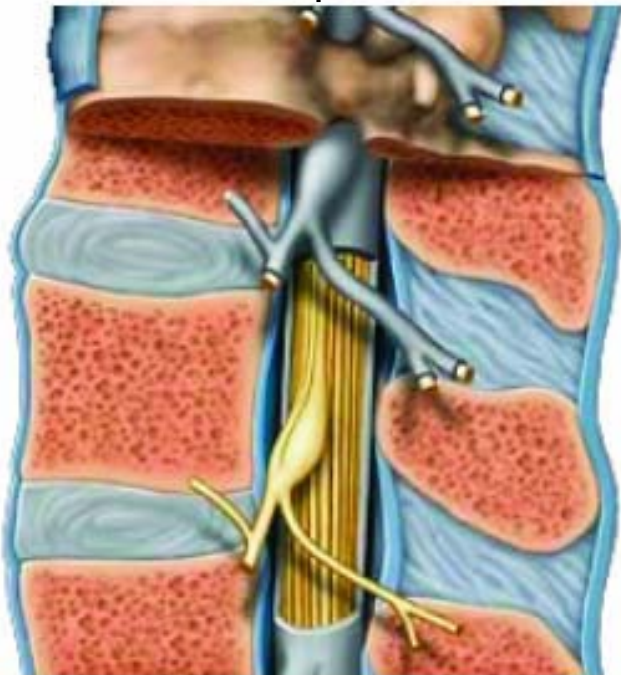
### INDICATIONS

Post-laminectomy syndrome, Epidural adhesions, Vertebral body compression fracture, Disc disruption, Radiculopathy

Catheter is inserted into caudal canal and guided to epidural space under fluoroscopy



Section view of the spine and nerve roots



Catheter is inserted and directed to the area of excessive scarring, dissipating scar tissue around nerve to provide relief of pain.

