

AIS PennHIP

(877) 727-6300 www.antechimaging.com

Owner's Copy

PennHIP Report

Referring Veterinarian: Dr Jessica Kirkpatrick	Clinic Name: Cottonwood Veterinary Hospital MT
Email: cvhbozeman@gmail.com	Clinic Address: 450 N. Cottonwood Rd. Bozeman, MT 59718
	Phone: (406) 582-0555
	Fax: (406) 582-4496

Patient Information

Client: Cooke, Kelly	Tattoo Num:
Patient Name: G	Patient ID: 18696
Reg. Name: MAKPASO'S DARK SECRET	Registration Num: DN54785607
PennHIP Num: 132107	Microchip Num: 934000011201464
Species: Canine	Breed: AUSTRALIAN SHEPHERD
Date of Birth: 28 May 2018	Age: 14 months
Sex: Male	Weight: 57.8 lbs/26.2 kgs
Date of Study: 03 Jul 2019	Date Submitted: 03 Jul 2019
Date of Report: 04 Jul 2019	

Findings

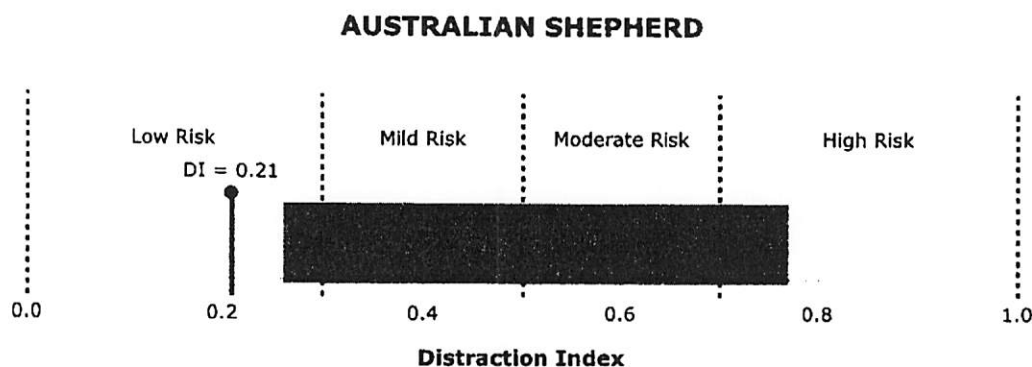
Distraction Index (DI): Right DI = 0.21, Left DI = 0.21.
 Osteoarthritis (OA): No radiographic evidence of OA for either hip.
 Cavitation/Other Findings: No cavitation present.

Interpretation

Distraction Index (DI): The laxity ranking is based on the hip with the greater laxity (larger DI). In this case the DI used is 0.21.

OA Risk Category: The DI is less than or equal to 0.30. This patient is at minimal risk for hip OA.

Distraction Index Chart:



BREED STATISTICS: This interpretation is based on a cross-section of 1393 canine patients of the AUSTRALIAN SHEPHERD breed in the AIS PennHIP database. The gray strip represents the central 90% range of DIs (0.26 - 0.77) for the breed. The breed average DI is 0.47 (solid square). The patient DI is the solid circle (0.21).

SUMMARY: The degree of laxity (DI = 0.21) ranks the hip within the tightest 5% of DIs for the breed. This amount of hip laxity places the hip at a minimal risk to develop hip OA. No radiographic evidence of OA for either hip.