

Research Article

Effect of methanolic crude and purified root extracts of *Moringa oleifera* on Liver enzymes activities, Kidney function and Histopathology in poloxamer 407-induced hyperlipidemic albino rats

Inalegwu Bawa, Itodo Matthew Ocheleka*, Ogli Itolo

Department of Biochemistry, Federal University of Agriculture Makurdi, Benue State, Nigeria.

*Corresponding author's e-mail: ocheleka1@gmail.com

Abstract

The research was aimed To evaluate the effect of methanolic Root Extract of *Moringa oleifera* on Liver enzymes activities, Kidney function and Histopathology in Poloxamer 407 induced Hyperlipidemic Albino rats. albino rats were grouped into 8; Group 1: Normal control given only food and water, Group 2: Hyperlipidemic control not treated, Group 2 to 8 were induced with Poloxamer 407 1000 mg/Kg body weighty, however group 3 was treated with standard drugs atorvastatin (10 mg/kg). Group 4 treated with crude root extract (200 mg/kg) of *Moringa oleifera* and group 5 to 8 were treated with purified fraction from column chromatography. The study showed Methanolic root extract at 200 mg/kg body weight significantly ($p>0.05$) decrease Alanine aminotransferase (ALT), Aspartate aminotransferase (AST), Alkaline phosphatase (ALP), Creatinine, Urea, of the treated groups, and extract of *moringa oleifera* has demonstrated strong anti-lipidemic and hepatoprotective tendency. The work thus provides the phytotherapeutic potential of methanolic root extract of *Moringa oleifera* that may be needed by scientists and researchers in nutraceutical industry.

Keywords: *Moringa oleifera*; Poloxamer 407; Enzymes liver activities; Kidney function; Histopathology.

Introduction

Plants has been a source of medicinal agents for thousands of years, and an impressive number of modern drugs have been isolated from natural sources, many based on their use in traditional medicine. These plants continue to play an essential role in health care, with about 90% of the world's inhabitants depending mainly on traditional medicines for their primary health care. Recently, there has been an upsurge of interest in the therapeutic potentials of medicinal plants antioxidants reducing free radical related diseases. It has been mentioned that the antioxidant activity of plants might be due to their phenolic compounds [1].

Moringa, a native plant from Africa and Asia, and the most widely cultivated species in Northwestern India, is the sole genus in the family Moringaceae. It comprises 13 species from tropical and subtropical climates, ranging in size from tiny herbs to massive trees. The most widely cultivated species is *Moringa oleifera* (MO). MO is grown for its nutritious

pods, edible leaves and flowers and can be utilized as food, medicine, cosmetic oil or forage for livestock. Its height ranges from 5 to 10 m [2].

It has been proved that elevated higher lipids level, especially cholesterol and triglycerides leads to hyperlipidemia and plasma levels of cholesterol and of LDL are responsible for atherosclerosis in man, and epidemiological data suggests that elevated plasma levels of HDL have a protective effect. So they have been developed many methods previously using some plants extract to increase the protective effect [3].

Cholesterol levels below 200 mg/dl are classified as desirable blood cholesterol. Those 200 to 239 mg/dl as borderline high blood cholesterol and those 240mg/dl and above as high blood cholesterol. Cholesterol levels are fairly constant but triglycerides level fluctuate considerable from day to day and are highly 1 to 4 hrs after meal [4]. Poloxamer 407 cause hypercholesterolemia and hypertriglyceride is in

rats. Possibly by inhibiting heparin-releasable lipoprotein lipase and or by stimulating the release of free fatty acids from Adipocytes [5].

Researchers are showing interest in finding out an alternative medicine that is affordable, efficacious and with little or no side effects that was available to low income earners for the treatment of diseases that are associated with cardiovascular diseases [6]. The aim of this study is to investigate the effects of methanolic crude and purified root extract of *Moringa oleifera* on liver enzymes activities, kidney function and histopathology in poloxamer 407 induced hyperlipidemic albino wistar rats.

Materials and Methods

Plant material

The *Moringa oleifera* plants was harvested from its natural habitat at the University of Agricultural Makurdi, Benue State, Nigeria in the month of July 2019, and authenticated at the Botany Department of College of Sciences, University of Agriculture Makurdi, Benue State, Nigeria.

Extraction

Extraction was carried out on the powdered sample using the method [7]. The collected plant sample was rinsed in clean water and dried at room temperature for two weeks. The dried plant sample was ground into powder using a mortar and pestle, the powder obtained was used to prepare the extracts. Based on the sample to solvent ratio of 1:10 (w/v), 50g of each of the ground samples root was suspended in 500ml of 70% methanol on a shaker for 48 hours at room temperature. Each extract was filtered using a sterilized Buchner funnel and Whatman No. 1 filter papers. The filtrates was concentrated by drying in a water bath maintained at a temperature of 45°C until a brownish black residue was obtained.

Column chromatography

Fractionation was carried out as reported in a literature [8], the crude extract derived from methanolic root extract was dissolved in n-Hexane and 6g of the weighed extract placed on top of 2x30cm silica gel column. The mobile phase was used as illustrated in table 1. Compounds were eluted with the mobile phase. Collected fractions were checked by thin layer chromatography (TLC) and those with similar

solvent front were recombined to yield four fractions.

Acute toxicity of the plant (LD50)

The acute toxicity (LD50) test of the extract was carried out to define the range of the lethal dose and the safe range for the extract. This was done using up and down method [9]. This method involves the sequential dosing of a single animal with a test substance within a time interval of 48 hours. After the administration of the first dose, the next dose is determined by the outcome of the subsequent dose administered. If the animal survives the sequent dose is adjusted upward, but when mortality is recorded, subsequent dose is adjusted downward. The adjustment is by a constant factor. Testing is terminated when the upper limit (2000 – 5000 mg/kg) have been reached without mortality or when the LD50 established from the test.

Induction of hyperlipidemia

The poloxamer 407 solution was prepared by dissolving 1 g in 10 ml of cold normal saline. Then kept overnight in a refrigerator to facilitate its homogeneity. The syringes and needles are kept in the fridge likewise. Hyperlipidemia was induced in wister albino rats by single intraperitoneal injection of freshly prepared solution of poloxamer 407 (1000 mg/kg) in physiological saline after overnight fasting for 24 hrs by a method [10]. After 48 hrs of induction hyperlipidemia and liver damage was confirmed to be 245 mg/dl of total cholesterol and 198 mg/dl of triglyceride, there was no reversal of hyperlipidemia and liver damage using 1000 mg/kg body weight of poloxamer 407 for induction [11].

Groupings and treatment of rats

A total of 32 rats were randomly divided into 8 groups of 4 rats each. The rats weighing between 135 – 200g, group 4 – 8 were treated orally with crude and purified extract.

Group 1: Normal Rats control were given feed and water only. This served as the normal control group (NC)

Group 2: Hyperlipidemic Rats induced with P407 (1000mg/kg b.wt) hyperlipidemic control (HYPER C) [11]

Group 3: Hyperlipidemic Rats were treated with 10 mg/kg b.wt atorvastatin (HYPER + SD) standard control

Group 4: Hyperlipidemic Rats were treated with 200 mg/kg b.wt methanolic crude extract (HYPER + Crude)

Group 5: Hyperlipidemic rats, administered 200mg/kg b.wt of fraction 1 (F1)

Group 6: Hyperlipidemic rats, administered 200mg/kg b.wt of fraction 2 (f2)

Group 7: Hyperlipidemic rats, administered 200mg/kg b.wt of fraction 3 (F3)

Group 8: Hyperlipidemic rats, administered 200mg/kg b.wt of fraction 4 (F4)

Preparation of standard drugs

Atorvastatin was purchased in a tablet form at a strength of 10 mg. Tablet was dissolve in 10 ml of normal saline to desired concentrations and administered orally. This preparation was done daily at time of administration. Treatments were done with a standard drug (atorvastatin) 10 mg/kg for 21 days served as standard [10].

Collection and preparation of samples

At the end of 21 days of treatment, the rats were sacrificed by decapitation after using chloroform anesthesia and blood samples were collected from the heart puncture in a plain bottles for biochemical parameters (Alanine aminotransferase (ALT), Aspartate aminotransferase (AST), Alkaline phosphatase (ALP), Creatinine and Urea). Blood samples collected in plain tubes was allowed to clot and the serum separated by centrifugation using Labofuge 300 centrifuge Heraeus) at 3000 rpm for 10 minutes and the supernatant (serum) collected was subjected to biochemical screening. Immediately after the blood was collected, the liver was quickly excised, trimmed of connective tissue, the liver tissue was fixed in 10% formalin, and was kept in the freezer for histopathology.

Biochemical parameters

Liver enzyme activities (ALT, AST, ALP) and kidney function (creatinine and urea) was assayed by the method [12] using Randox assay kits and instruction based on the randox manual.

Histopathology

Histopathology was carried out according to histological procedure described previously in literature [13]. Histopathology of the liver tissue on day 21, the animals was sacrificed after blood samples are extracted, and the liver was collected, the liver tissues was fixed in 10% formalin, routinely processed, and embedded in paraffin wax. A paraffin section (5 μ m) was cut on a glass slide, stained with hematoxylin and eosin (H&E), and examined under a light microscope by a pathologist blinded to the group studies.

Statistical analysis

The results were expressed as mean \pm standard deviation (SD). The data was analyzed by the analysis of variance (ANOVA) using SPSS program (version 16.0 SPSS Inc., Chicago, IL, USA). P-value less than 0.05 was considered as significant ($p < 0.05$). The difference between the various extracts and animal groups was compared using the Duncan Multiple Range Test.

Results and discussion

Mobile phase used for column chromatography of methanolic crude root extract of Moringa oleifera

Methanolic crude root extract of *Moringa oleifera* plant exhibits strong effect on liver enzymes activities and kidney function in the poloxamer 407 induced hyperlipidemic albino rats. Therefore, the fractionation of the extract was done using silica gel as the stationary phase while hexane and ethanol is the solvent. The column was run repeatedly with which compounds were eluted with the mobile phase shown in table 1. The collected fractions were checked by TLC and those with the solvent front were recombined yielding four fraction.

Effect of Moringa oleifera root extract and purified fractions on liver function parameters of poloxamer 407 induced hyperlipidemic albino rats

The effect of *Moringa oleifera* root extract and purified fractions on liver function parameters of Poloxamer 407 induced Hyperlipidemic rats is presented in Table 2. The result shows that hyperlipidemia significantly ($p \leq 0.05$) increased the serum level of AST, ALT and ALP of hyperlipidemic rats when compared to normal

rats. All the hyperlipidemic treated rats significantly ($p \geq 0.05$) lowered the serum levels of AST, ALT and ALP when compared with the hyperlipidemic control rats. The serum ALT, AST and ALP significantly ($p \leq 0.05$) higher in all the extract treated groups when compared with normal control. Four fractions (F1-F4) and standard drug show significantly ($p \geq 0.05$) lower AST, ALT and ALP when compared to normal control.

Table 1. Mobile phase used for column chromatography of methanolic crude root extract of *Moringa oleifera*

Mobile Phase	Relation	Volume (ml)	Fractions
Hexane	100%	90	F1
Hexane:ethanol	90:10	90	F1
Hexane:ethanol	80:20	90	F2
Hexane:ethanol	70:30	90	F2
Hexane:ethanol	60:40	90	F2
Hexane:ethanol	50:50	90	F3
Hexane:ethanol	40:60	90	F3
Hexane:ethanol	30:70	90	F4
Hexane:ethanol	20:80	90	F4
Hexane:ethanol	10:90	90	F4
Ethanol	100%	90	F1

On day 1, when the hyperlipidemia and liver damage have been confirmed before treatment after 48 hours of induction the ALT (67.15±31.1, 57.10±11.8, 67.20±9.7, 67.34±35.10, 73.33±12.33, 69.11±13.55, 67.14±17.11) were recorded in the hyperlipidemic group (HYPER C) to fraction 4 (HYPER+F4). AST (31.12±11.9, 40.51±7.11, 25.22±44.33, 35.27±21.13, 33.51±5.07, 39.58±4.74, 32.11±11.78) were recorded in hyperlipidemic group (HYPER C) to fraction 4 (HYPER+F4). ALP (61.25±10.15, 56.87±9.65, 66.40±13.23, 65.60±17.01, 64.40±17.34, 59.20±39.11, 60.25±65.11) were recorded in the hyperlipidemic group (HYPER C) to fraction 4 (HYPER+F4). These result shown significant ($p \leq 0.05$) increase in ALT, AST, ALP of hyperlipidemic group (induced and non treated group) from day 1 to day 21 recorded in table 2 while there is significant ($p \geq 0.05$) decrease recorded across the induced and treated group

In this study, the elevated levels of AST, ALT and ALP observed in the serum of

hyperlipidemic control may be due to injuries inflicted to the liver. This could be the accumulation of cholesterol, triglycerides and other fats in the liver cells and is in line with this work [14]. Ameh [15] found no effect on ALT except on AST, while Johnston [16] reported that P407 does not cause hepatic injury or damage. The discrepancy in the serum levels of the enzymes could be attributed to the levels and duration of hyperlipidemia [17].

There was a significant ($p \leq 0.05$) restoration of these liver marker enzyme levels in all the induced treated groups on administration of the extract, and atorvastatin. The significant ($p \geq 0.05$) reductions observed in the activity of ALT and AST indicate that the crude extract and purified fraction of *Moringa oleifera* was able to reverse the liver damage. The reversal of this liver marker enzyme towards normal range by the extract and fractions observed in this study may be due to the prevention of the leakage of intracellular enzymes by the presence of bioactive components in the crude extract, purified fractions and their membrane stabilizing activity. This is in agreement with the previous study that serum levels of aminotransaminases return to normal with the healing of hepatic parenchyma and the regeneration of hepatocytes [18].

Effect of Moringa oleifera root extract and purified fractions on kidney function parameters of poloxamer 407 induced hyperlipidemic rats

The effect of *Moringa oleifera* root extract and purified fractions on kidney function parameters of Poloxamer 407 Induced Hyperlipidemic rats are presented in Table 3. The results showed that creatinine and urea concentration significantly ($p \leq 0.05$) increased in hyperlipidemic control when compared with all other groups. The crude extract and the four fraction (F1-F4) significantly ($p \geq 0.05$) decreased the creatinine and urea concentration when compared to hyperlipidemic control group and significant ($p \leq 0.05$) increase was recorded when compared to the normal control.

On day 1, when the hyperlipidemia and liver damage have been confirmed before treatment after 48 hours of induction the creatinine (15.31±2.95, 19.00±15.31, 25.13±9.11, 21.20±3.55, 14.10±2.13, 23.15±6.01, 15.20±8.17). Urea (9.11±3.12,

7.20±1.11, 10.00±3.55, 11.33±5.32, 8.50±16.74, 7.55±6.11, 9.25±4.15) were recorded in the hyperlipidemic group (HYPER+F4) to fraction 4 (HYPER+F4). This result shows significant ($p \leq 0.05$) increase in creatinine and urea of

hyperlipidemic group (induced and not treated group) from day 1 to day 21 recorded in table 3 while there is significant ($p \geq 0.05$) decrease recorded across the induced and treated group

Table 2. Effect of *Moringa oleifera* root extract and purified fraction on liver function parameters of poloxamer 407 induced hyperlipidemic albino rats

Group N = 8	ALT (UL)	AST (UL)	ALP (UL)
NC	48.80 ± 8.87 ^a	13.00 ± 4.74 ^a	47.80 ± 8.72 ^a
HYPER C	82.80 ± 8.70 ^c	47.00 ± 9.02 ^d	76.20 ± 17.03 ^d
HYPER + SD	43.20 ± 7.12 ^a	27.20 ± 6.65 ^b	40.90 ± 5.17 ^a
HYPER + Crude (200 mg/kg BW)	61.20 ± 9.26 ^b	20.40 ± 10.83 ^c	61.20 ± 9.26 ^c
HYPER + F1 (200 mg/kg BW)	58.60 ± 17.01 ^b	11.60 ± 7.64 ^a	58.60 ± 17.01 ^b
HYPER + F2 (200 mg/kg BW)	59.20 ± 13.20 ^b	16.20 ± 5.07 ^b	59.20 ± 13.20 ^b
HYPER + F3 (200 mg/kg BW)	60.20 ± 11.78 ^b	26.60 ± 7.64 ^b	52.60 ± 25.68 ^b
HYPER + F4 (200 mg/kg BW)	55.80 ± 17.46 ^b	10.00 ± 4.74 ^a	55.80 ± 17.46 ^b

Values are means ± SD of four determinations. Values with different superscripts in the column are significantly different ($p < 0.05$). NC: Normal Control Rat, HYPER C: Hyperlipidemic Control Rat, HYPER + SD: Hyperlipidemic + Standard Drugs (atorvastatin 10mg/kg), HYPER + Crude: Hyperlipidemic Rat + Crude Extract (200mg/kg), Hyper + F1: Hyperlipidemic Rat + Fraction 1 (200mg/kg), Hyper + F2: Hyperlipidemic Rat + Fraction 2 (200mg/kg), Hyper + F3: Hyperlipidemic Rat + Fraction 3 (200mg/kg), Hyper + F4: Hyperlipidemic Rat + Fraction 4 (200mg/kg). ALT: Alanine Aminotransferase, AST: Aspartate Aminotransferase, ALP: Alkaline Phosphatase

Studies have shown that poloxamer (407) is non-toxic, safe for chronic administration and capable of inducing hyperlipidemia in experimental animals [19]. Hyperlipidemia is one of the disease conditions that are injurious to the kidney. Kidney helps in maintaining homeostasis of the body by reabsorbing important materials and excreting waste products [20]. Its functionality is assessed by determining the serum concentration of excretory constituents [21]. Creatinine is a waste product formed in muscle by creatine metabolism. Creatinine is the major catabolic product of the muscle and it is excreted in the kidneys. It has been found to be capable of inducing glomerular injury [22]; [23]. The elevated levels of creatinine and urea observed in the serum of hyperlipidemic control compared with the group treated with purified fraction is in line with the work reported [24] that the accumulation of triglycerides and other fats in the kidney may be as a result of injuries or damage of the nephron structural integrity. However, there was a restoration of the kidney

serum levels of creatinine and urea in all the induced treated groups on administration of the crude extract and purified fraction. This study agrees with the work reported in the literature [25] where ethanolic leaf extract of *Commiphora africana* (Burseraceae) was shown to decrease creatinine and urea in the serum blood. High blood urea is associated with increased tissue protein catabolism, excess break-down of blood protein and diminished excretion of urea.

Effect of *Moringa oleifera* Root Extract and Purified Fractions of Histopathology of the Liver of Poloxamer 407 Induced Hyperlipidemic Albino Rats

Histological examination of the liver showed that the extract of both crude and purified fractions of *Moringa oleifera* markedly protected against hypercholesterolemia induced micro-vesicular steatosis (Figure 2) compared with the rats of normal control diet (Figure 1). Liver enzymes such as Alanine amino transferase (ALT), Aspartate amino transferase (AST) and

Alkaline phosphatase (ALP) are marker for liver function and integrity [26]. These enzymes are usually elevated in acute hepatotoxicity or mild hepatocellular injury and membrane damage as a result of oxidative stress variety of cytosolic enzymes are release into the blood stream [26]. The biochemical analysis of serum liver enzymes from this study shows significant decrease in levels of all the enzymes in both crude and purified extract (Figure 4, Figure 5,

Figure 6, Figure 7 and Figure 8) which is also effective as the standard drugs atorvastatin (Figure 3) when compared with Hyperlipidemic group (Figure 2).

Extract of *moringa oleifera* has demonstrated strong anti-lipidemic and hepatoprotective tendency which suggested that the plant should be investigated further to determine its possible mechanism of action.

Table 3. Effect of *Moringa oleifera* root extract and purified fraction on kidney function parameters of poloxamer 407 induced hyperlipidemic rats

Group N = 8	Creatinine (mg/dl)	Urea (mg/dl)
NC	6.48 ± 3.29 ^a	3.90 ± 3.50 ^a
HYPER C	31.68 ± 9.95 ^e	13.68 ± 2.03 ^d
HYPER + SD	7.40 ± 3.21 ^a	4.14 ± 1.64 ^b
HYPER + Crude (200mg/kg BW)	15.40 ± 9.19 ^c	5.00 ± 1.48 ^c
HYPER + F1 (200mg/kg BW)	20.25 ± 8.31 ^d	6.67 ± 3.21 ^c
HYPER + F2 (200mg/kg BW)	6.91 ± 2.98 ^a	4.91 ± 1.69 ^b
HYPER + F3 (200mg/kg BW)	12.21 ± 5.74 ^b	4.74 ± 1.55 ^b
HYPER + F4 (200mg/kg BW)	8.57 ± 5.15 ^a	6.76 ± 2.39 ^c

Values are means ± SD of four determinations. Values with different superscripts in the column are significantly different (p<0.05). NC: Normal Control Rat, HYPER C: Hyperlipidemic Control Rat, HYPER + SD: Hyperlipidemic + Standard Drugs (atorvastatin 10mg/kg), HYPER + Crude: Hyperlipidemic Rat + Crude Extract (200mg/kg), Hyper + F1: Hyperlipidemic Rat + Fraction 1 (200mg/kg), Hyper + F2: Hyperlipidemic Rat + Fraction 2 (200mg/kg), Hyper + F3: Hyperlipidemic Rat + Fraction 3 (200mg/kg), Hyper + F4: Hyperlipidemic Rat + Fraction 4 (200mg/kg).

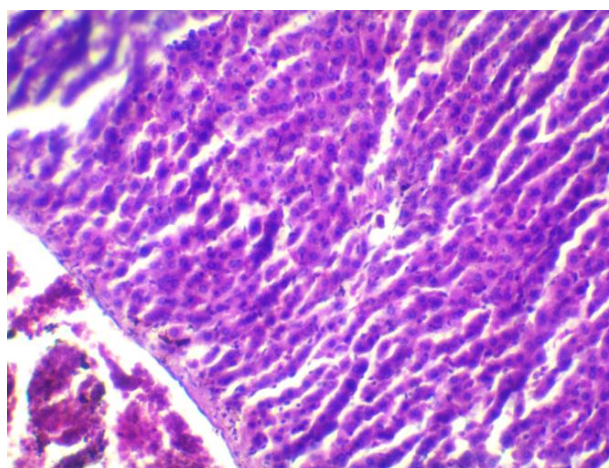


Figure 1. Photomicrograph of liver of the rat with normal diet (control) (10X)

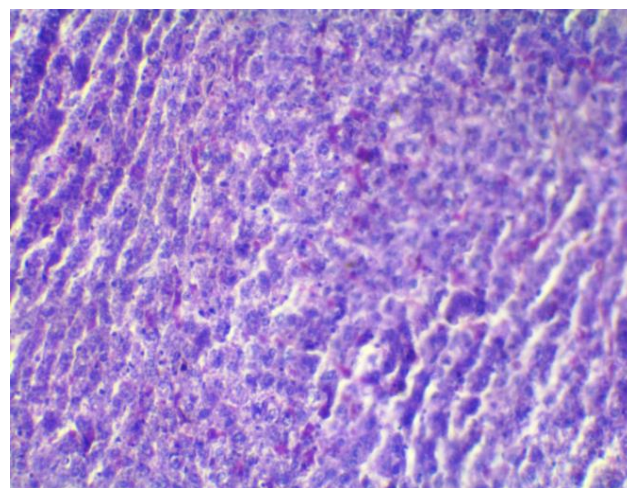


Figure 2. Photomicrograph of the liver of rat induced with hyperlipidemia without treatment showing micro-vesicular steatosis (control) (10X)

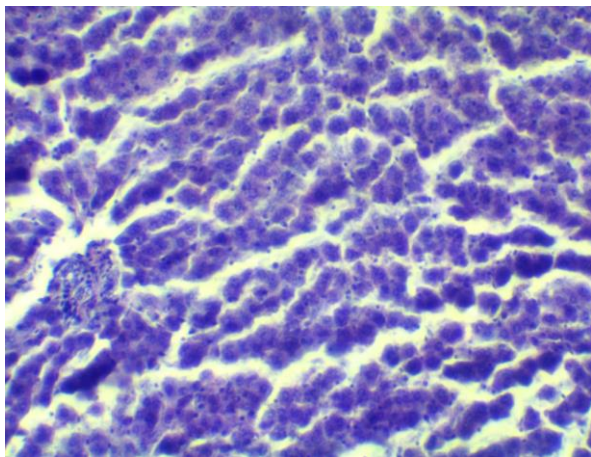


Figure 3. Photomicrograph of liver of rat induced with hyperlipidemia and treated with atorvastatin (10 mg/kg) showing no lesion (control) (10X)

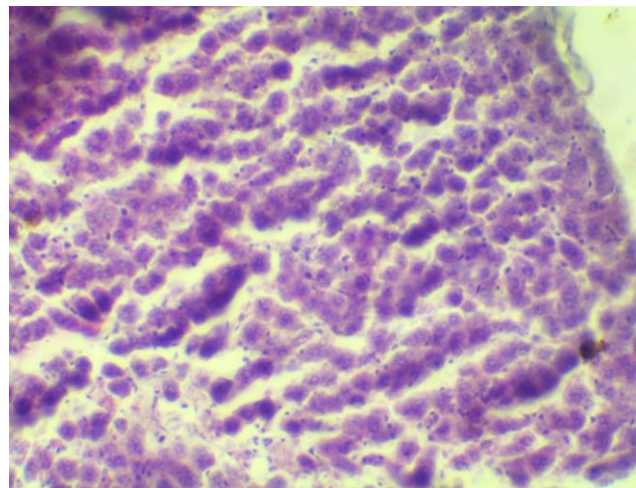


Figure 6. Photomicrograph of the liver of rat induced with hyperlipidemia and treated with fraction 2 (200 mg/kg) showing no lesion (10X)

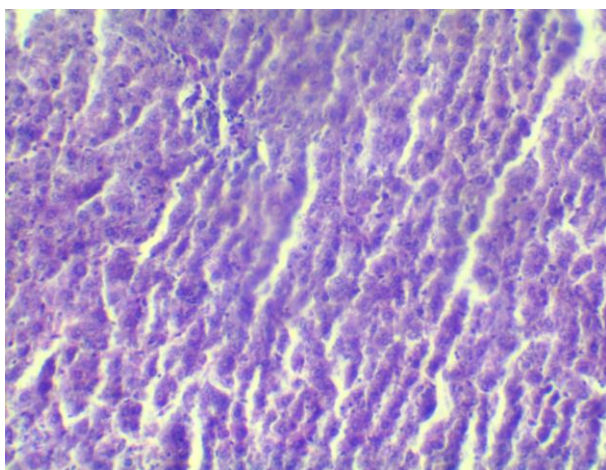


Figure 4: Photomicrograph of the liver of rat induced with hyperlipidemia and treated with crude extract (200 mg/kg) showing no lesion (10X)

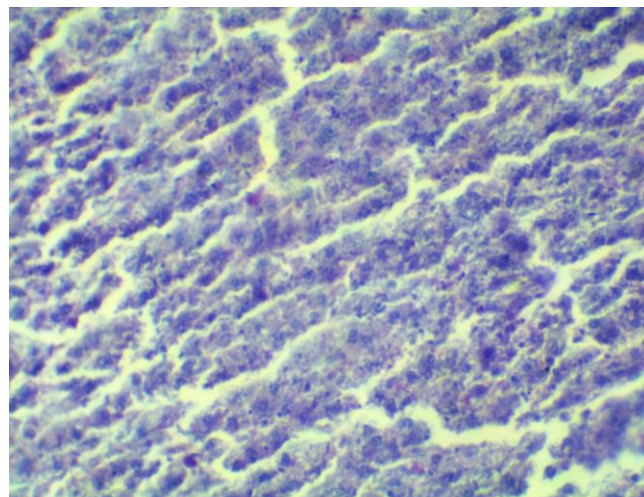


Figure 7. Photomicrograph of liver of rat induced with hyperlipidemia and treated with fraction 3 (200 mg/kg) showing no lesion (10X)

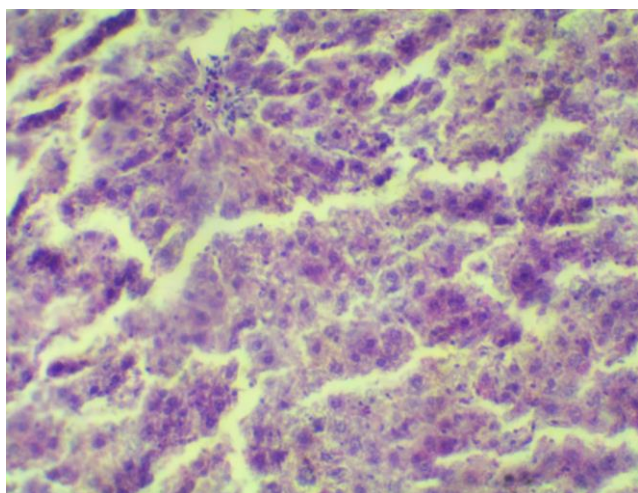


Figure 5. Photomicrograph of liver of rat induced with hyperlipidemia and treated with fraction 1 (200 mg/kg) showing no lesion (10X)

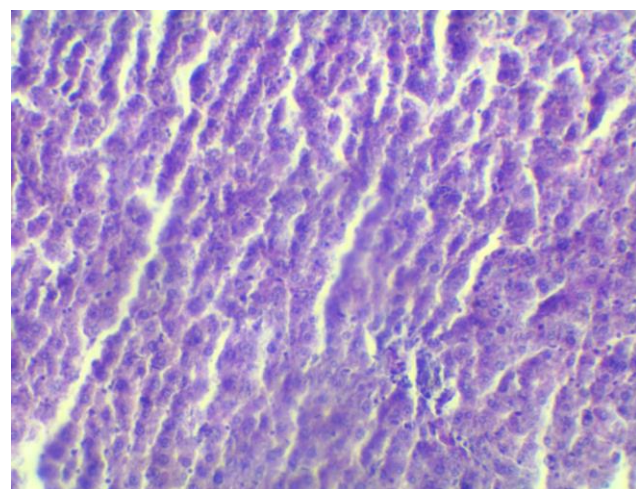


Figure 8. Photomicrograph of the liver of rat induced with hyperlipidemia and treated with fraction 4 (200 mg/kg) showing no lesion (10X)

Conclusions

The present research work, demonstrated that the crude and all the fractions enhanced Liver enzyme activities (ALT, AST and ALP), kidney function parameters (creatinine and urea) as evident in the reduction of serum ALT, AST, ALP, creatinine and urea for hyperlipidemic rats, and no significant ($p \geq 0.05$) effects on normal control. Extract of *moringa oleifera* has demonstrated strong anti-lipidemic and hepatoprotective tendency which suggested that the plant should be investigated further to determine its possible mechanism of action. The work thus provides the phytotherapeutic potential of methanolic root extract of *Moringa oleifera* that may be needed by scientists and researchers in nutraceutical industry.

Conflict of interest

Authors declared no conflict of interest.

Acknowledgement

The author wish to acknowledge the management of Biochemistry Department Federal University of Agriculture Makurdi, Benue State, Nigeria, for granting the authors permission to embark on the project. The authors also appreciate Dr. Bawa Inalegwu for his contribution towards the research.

References

- [1] Asheneni VP. Anti-Hyperlipidemic potential of vitex doniana Ethanol Extracts on Poloxamer 407 Induced Hyperlipidemic and Normal Rats. M.Sc. Thesis Report. Department of Biochemistry, Ahmadu Bello University, Zaria, Nigeria 2014; pp 21.
- [2] Vergara-Jimenez M, Almatrafi MM, Fernandez ML. Bioactive Component in *Moringa Oleifera* Leaves Protect against Chronic Diseases. *Antioxidants* 2017;6, 91.
- [3] Radha R, Eyed M, Rao OS. Evaluation of Anti-Hyperlipidemic Activity of Methanolic Extract of *Carica papaya* seeds on wistar Rats. *Info American Journal of pharmaceutical sciences* 2014;1(5):328-32.
- [4] Hill RD, Smith RB. Examination of the Extremities: The history, physical, and laboratory examination; Boston, Butter worths 1990;
- [5] Subhashi D, Singh J. Safety assessment of Poloxamer 101 – 407, 405 Benzoate, and used Poloxamer 182 Dibenzoates as used in cosmetics. *International Journal of Toxicology* 2008;27(2):93-128
- [6] Yokozowa M, Origassa H, Sasaki S. The protective role of Chinese prescription. Kangen-Karyu Extract on diet-induced hyper cholesterol emus in rats. *Biological and Pharmaceutical Bulletin* 2006;29:760-5.
- [7] Das K, Tiwari RKS, Shrivastava DK. Techniques for evaluation of medicinal plant products as antimicrobial agent: Current methods and future trends. *Journal of Medicinal Plants Research* 2010;4(2):104-11.
- [8] Seeling M, Popesco R, Seephonkai P, Singhube J, Giessrigl B, Unger C. Fractionation of an extract of *Pluchea odorata* separate a property indicative for the induction of cell plasticity from one that inhibit neoplastic phenotype. *Evid Based Complement Alternat Med* 2012;2012:701927.
- [9] Chinedu E, Arome D, Ameh SF. A new Method Determining Acute Toxicity in animal Models. *Toxicology International* 2013;20(3):224-6.
- [10] Inalegwu B, Ornuga G, Etim EE. Effect of the Aqueous Extracts of *Grewia venusta* leaves on poloxamer 407 Induced Hyperlipidemic rats. *International Journal of science and Research* 2018;7(5):398-404.
- [11] Chaudhary HR, Brocks DR. The single Dose Poloxamer 407 Model of Hyperlipidemia. Systemic Effects on Lipids Assessed using Pharmacokinetic Methods and its Effects on Adipokines. *J pharmaceut Sci* 2013;16(1):65-73.
- [12] Reitman S, Frankel AS. A colorimetric method for the determination of serum glutamic oxaloacetate and glutamic pyruvic transaminase. *American Journal of Pathology* 1957;28:56-63.
- [13] Slaoui M, Fiette L. Histopathology procedure: From tissue sampling to histopathological evaluation. *Methods in Molecular Biology* 2011;691:69-80.
- [14] Hyeung S, Hyo CA, Sae K. Hypolipemic effect of aqueous extracts of *Picrorrhiza zarithizoma* in Poloxamer-407 induced

- hyperlipidemic mouse. *Journal of Ethnopharmacology* 2006;105:380-6.
- [15] Ameh DA, Adejo EB, James DB. Effect of Garcinal kola biflavonoid fractions on some biochemical parameters of P407-induced hyperlipidemia rats: A phytopreventive and phytotherapeutic studies. *Journal of Comparative Clinical Pathology* 2013;2(3):23-25.
- [16] Johnston TP, Palmer WK. Mechanism of poloxamer 407-induced hypertriglyceridemia in the rat. *Biochemical Pharmacology* 2003;46:1037-42.
- [17] Lu LS, Wu CC, Hung LM, Chiang MT, Lin CT, Lin CW, Su MJ. Apocynin alleviated hepatic oxidative burden and reduced liver injury in hypercholesterolaemia. *International Journal of Biomedical Toxicology* 2007;27:529-537.
- [18] Chavan SD, Patil SB, Naikwade NS. *Biochemical and Histopathological Studies (Retz) Nees* [family ACANTHACEAE]. Royal Botanical Gardens; 2012.
- [19] Johnston TP. The Poloxamer (407) induced murine model of dose controlled hyperlipidemia and atherosclerosis: A review of findings to date. *Journal of Cardiovascular Pharmacology* 2004;43:595-606.
- [20] Cheesbrough M. *District Laboratory practice in Tropical countries: Tropical Health Technology*. Cambridge University Press. 2006; pp. 333-363.
- [21] Ochei JO, Kolhatkar AA. *Medical Laboratory Science: Theory and Practical*. Tata McGraw-Hill Publishing Company Limited. 2008;169-287.
- [22] Tolins C, Miller B, Keane WF. Lipid-induced glomerular injury. *Nephron* 1992;67(1):1-6.
- [23] Gröne EF, Walli AK, Gröne HJ, Miller B, Seidel D. The role of lipids in nephrosclerosis and glomerulosclerosis. *Atherosclerosis* 1994;107(1):1-13.
- [24] Khan MR, Siddique F. Antioxidant effects of *Citharexylum spinosum* in CCl₄ induced nephrotoxicity in rat. *Experimental Toxicology and Pathology*, 2012;64:349-355.
- [25] Aliyu R, Adebayo AH, Gatsing D, Garba IH. The Effects of Ethanolic Leaf Extract of *Commiphora Africana* (Burseraceae) on Rat Liver and Kidney Functions. *Journal of Pharmacological Toxicology* 2006;2(1):373-9.
