

APEXUM PROCEDURE: CLEANING INFLAMED PERIAPICAL REGION THROUGH ROOT CANAL

Karan Bansal¹, Rahul Bansal²

1. Associate Dentist, Singla Dental Clinic, Chandigarh.

2. General Practitioner, Smiling Tooth Dental Care, Hisar.

ABSTRACT:

The ultimate goal of endodontic treatment should be to return the involved teeth to a state of health and function without surgical intervention. In nonsurgical endodontic procedures, the healing of apical periodontitis is achieved by treatment provided within the root canal system. Now a new system, Apexum procedure, is introduced based on advancing the debridement one step further by minimally invasive removal of the inflamed periapical tissues through root canal access.

Key-words: Apexum, Periapical, Minimal Invasive Endodontics.

INTRODUCTION:

Lesions of apical periodontitis represent an inflammatory response to bacterial infection of the root canal.^[1] These are generally diagnosed either during routine dental radiographic examination or following acute toothache. Various methods can be used in the nonsurgical management of periapical lesions: the conservative root canal treatment, decompression technique, active nonsurgical decompression technique, aspiration-irrigation technique, method using calcium hydroxide, lesion sterilization and repair therapy and newly introduced the Apexum procedure.^[2] The ultimate goal of endodontic therapy, when applied to teeth with periapical lesions, is to induce complete bony healing of the lesion and restoration of the periodontal ligament.^[3] All inflammatory periapical lesions should be initially treated with conservative nonsurgical procedures.^[4] Monitoring the healing of periapical lesions is essential through periodic follow-up examinations.

Complete healing of bone tissue may take up to 24 months.^[3]

The basic concept of treatment of apical periodontitis comprises of debridement, disinfection, and lastly entombment. This treatment is commonly carried out as far as the working length, ie, 0.5–1.0 mm short of the apical foramen, to maintain the apical constriction.^[5] The Apexum protocol was designed to carry the debridement concept further into the apical foramen proper and beyond it into the periapical lesion itself.^[6] This new procedure has been designed to be applied during, and as a supplementary stage to, conventional root canal treatment. It is aimed to add the faster healing kinetics that typically occurs with apical surgery, but without the use of scalpels, periosteal elevators, or sutures.^[7-9]

Apexum Kit

The Apexum kit consists of two devices, the Apexum NiTi Ablator and Apexum PGA Ablator, designed to be used sequentially (Fig. 1). Both instruments are for single use.

The Apexum NiTi Ablator consists of a specially preshaped Nitinol wire. One end is bent and is designed to enter the periapical tissues through the root canal and apical foramen, whereas the other end has a latch-type connector to allow its operation by a low-speed contra-angle handpiece. The bent part is initially concealed in a straight super elastic Nitinol tube that serves as a sheath allowing its introduction up to the apical foramen (Fig. 1A). When pushed, the wire emerges from its sheath and through the apical foramen and resumes its preshaped form (Fig. 1B, C). The special retrograde design of the bent part allows

it to rotate in the periapical soft tissues at 200 to 250 rpm and coarsely grind them while being deflected from the surrounding bone (Fig. 1C). The Nitinol sheath is used first to allow the introduction of the prebent Nitinol wire to the apical foramen and second to allow unobstructed rotation of the wire in the root canal without twisting of the wire.

The second device is the Apexum PGA Ablator, built from a Nitinol shaft, equipped on one end with a latch-type connector to allow its operation by a low-speed contra-angle handpiece (Fig. 1D). At the other end, a bioabsorbable filament is attached, which is designed to enter the periapical bony crypt and rotate at 5,000 to 7,000 rpm, turning the tissue that was initially minced with the NiTi Ablator into a thin suspension that may be flushed through the root canal.

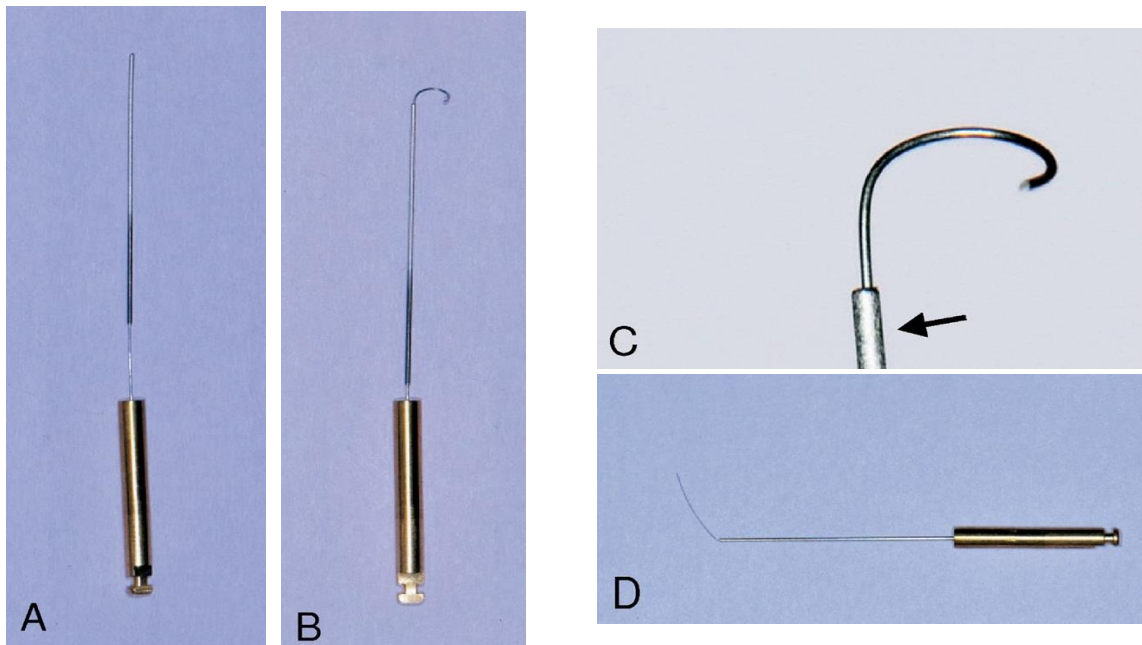


Fig. 1 the Apexum device. (A) The Apexum Ni-Ti Ablator in its sheath. (B) The Apexum NiTi Ablator pushed in and extruded from its sheath (arrow). (C) An enlarged view of the active part of the Apexum NiTi Ablator. (D) The Apexum PGA Ablator.

Treatment protocol

The treatment protocol is identical to that of the conventional treatment with the addition of the Apexum procedure. [8] First visit is similar to that of conventional protocol comprising access opening and initial biomechanical preparation. In the second visit, biomechanical preparation is performed until the stage at which the root canal was ready for obturation. At this stage, the Apexum procedure is performed. #20 K-file is passed through the apical foramen and beyond the apex to verify patency. It is followed by a rotary #30 file that was passed 1 mm beyond the apical foramen, creating a passage for Apexum device.

The Apexum NiTi Ablator was then inserted, while encased in its sheath, to the working length as established at the cleaning and shaping stage (Fig 2A). A periapical radiograph is taken to ensure that the NiTi Ablator is in the correct position. Holding the latch-type connector with 2 fingers, the NiTi Ablator is gradually pushed out of its sheath and into the periapical lesion. (Fig

2B, C) It is manually rotated to verify that it met no solid obstruction. The NiTi Ablator sheath is then secured to the tooth crown and stabilized by using composite resin or GIC. Next, the NiTi Ablator is connected to a contra-angle, low-speed handpiece and rotated in the periapical lesion for 30 seconds at 200 –250 rpm. The Apexum Ablator sheath is then disconnected from the tooth, either by applying light force with forceps or by gently touching with a high-speed drill around the cement margins. The NiTi Ablator is removed from the root canal system while still being connected to the contra-angle handpiece and the blade is inspected if deformed or broken. The root canal is thoroughly rinsed with saline to remove debris. The PGA Ablator is then manually introduced through the root canal and into the lesion and then connected to the contra-angle handpiece and rotated for 30 seconds at 5000 –7000 rpm. (Fig 2D) It is thereafter removed from the root and inspected for deformity or tear. Each device is used once.

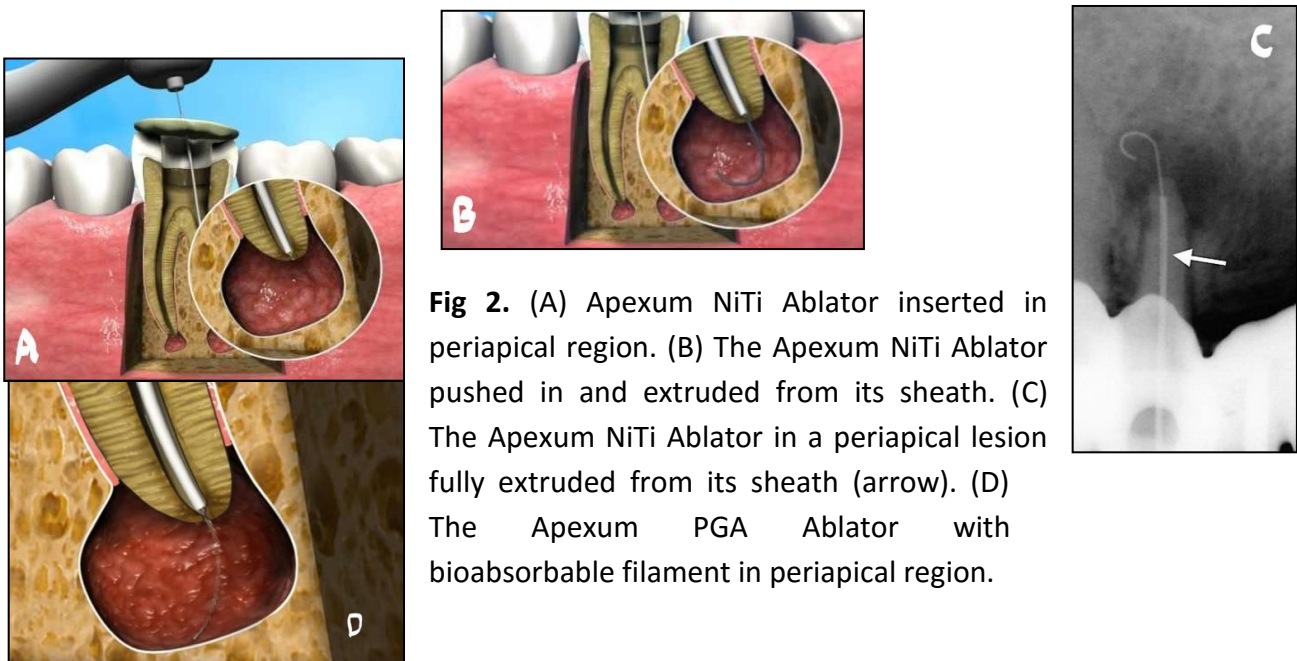


Fig 2. (A) Apexum NiTi Ablator inserted in periapical region. (B) The Apexum NiTi Ablator pushed in and extruded from its sheath. (C) The Apexum NiTi Ablator in a periapical lesion fully extruded from its sheath (arrow). (D) The Apexum PGA Ablator with bioabsorbable filament in periapical region.

The periapical bony crypt is thoroughly washed with saline that was gently administered by using a syringe with a 30-gauge needle that passed through the apical foramen. This is done while continuously visually monitoring the backflow to prevent excessive pressure from building up in the periapical crypt. The root canal is dried with sterile paper points, and root canal filling is performed by using lateral condensation with gutta-percha and AH-26 sealer. External filling of GIC is placed to seal the coronal access cavity. Finally, the root is radiographed again postoperatively.

DISCUSSION:

The Apexum represents the era of minimal invasive endodontic treatment. It not only removes the cause and leave the host to heal at its own but enters the periapical lesion beyond the apical foramen. It previously used to result in flare-up. The apical procedure is different from over instrumentation during root canal

treatment as latter traumatized the tissue and also may introduce the bacterial antigen into tissues containing immunoglobulin against them which may result in flare up. In Apexum, due to debulking of periapicalt chronically inflamed tissues, the mechanism which may lead to flare-up was also removed.

Apexum can also be used in condition which require debulking of periapical tissue such as small periapical cyst^[10] and in case where implants are to be given in areas of large periapical lesion.^[1]

CONCLUSION:

Apexum procedure is a step toward managing periapical lesion in a minimal invasive manner. Further studies are required for better and safe understanding and usage of this system.

REFERENCES:

1. Raisingani D. Apexum: A minimum invasive procedure. Int J Clin Ped Dent. 2011; 4(3): 224-7.
2. Fernandes M, de Ataide I. Nonsurgical management of periapical lesions. J Conserv Dent. 2010 Oct; 13(4):240-5
3. Metzger Z et al. Enhancement of healing kinetics of periapical lesions in dogs by the Apexum procedure. J Endod. 2009; 35(1):40-5
4. Lin LM, et al. Proliferation of epithelial cell rests, formation of apical cysts, and regression of apical cysts after periapical wound healing. J Endod. 2007; 33:908-16.
5. Weine FS. Endodontic therapy. 6th ed. St Louis, MO: Mosby; 2004
6. Metzger Z, Abramovitz I. Periapical lesions of endodontic origin. In: Ingle JI, Bakland LK, Baumgartner JC, eds. Ingle's endodontics. 6th ed. Hamilton, ON, Canada: B C Decker, 2008:494 –519
7. Metzger Z et al. Healing kinetics of periapical lesions enhanced by the Apexum procedure; a clinical trial. J Endod. 2009; 35(1):153-9.
8. Deepak B.S et al. Apexum Ablator: A Minimal Invasive Periapical Procedure. J Dent Pract Res 2013;1(1): 13-15.
9. Mortman RE. Technologic advances in endodontics. Dent Clin North Am. 2011; 55(3): 461-80
10. Bansal R et al. Endodontic Management of a Periapical Cyst- A Review. J Adv Med Dent Scie 2013;1(1):7-16