

MORPHOMETRIC ANALYSIS OF SELLA TURCICA AND ITS CLINICAL SIGNIFICANCE

Priya Damodaran¹, Yuvaraj.M², Priyadarshini.A³, Sankaran.P.K⁴, Kalaiarasi.P⁵, Madhu Radhakrishnan⁶

1. Student, Compulsory Rotarory Residential Internship, Ragas dental college and hospital, Tamil nadu

2. Tutor, Department of Anatomy, Saveetha medical college and hospital, Thandalam, Tamil nadu

3. Tutor, Department of Anatomy, Saveetha medical college and hospital, Thandalam, Tamil nadu

4. Associate professor, Department of Anatomy, Saveetha medical college and hospital, Thandalam, Tamil nadu

5. Student, Compulsory Rotarory Residential Internship, Ragas dental college and hospital, Tamil nadu

6. Student, Compulsory Rotarory Residential Internship, Ragas dental college and hospital, Tamil nadu

ABSTRACT:

Sella turcica is an important and commonly used cranial landmark in many ventures. This work aims to measure and study sella turcica size and shape variations which is important for neurologists and neurosurgeons to avoid any damage to the sellar region and in identifying any pathological signs involving pituitary gland.

The study was done with 102 dried human skulls where the gender of the skulls was not taken into consideration. The study was mainly concentrated to analyze the parameters of sella turcica. The average of sella turcica length, breadth and depth were calculated to be 10.59mm, 10.76mm and 9.23mm respectively. Most commonly found shape of sella turcica is normal (56.8%). These observations are essential in providing reference standard values.

Keywords: Sella turcica, Sella size, Sella shape, Hypophyseal fossa

INTRODUCTION

The Sella turcica, a saddle shaped depression, is an important bony entity which is located in the body of the sphenoid bone of the middle cranial fossa and is bounded by the two anterior and two posterior clinoid processes. The seat of the saddle, the deepest part of the sella turcica, known as the hypophyseal fossa along with tuberculum sellae and dorsum sellae forms the whole of the sella turcica. The hypophyseal fossa lodges the Pituitary gland, the master endocrine gland also known as the 'conductor of endocrine orchestra'. The roof is diaphragm sella, which is circular fold of duramater attached to anterior clinoid process and posterior clinoid process. ^[1] Sella turcica is surrounded anteriorly by optic

chiasma, inferiorly by sphenoid sinus, medially by cavernous sinus, oculomotor nerve, trochlear nerve, abducent nerve, ophthalmic nerve, maxillary nerve, internal carotid artery.

The prenatal and postnatal formation of pituitary gland and sella turcica are complex processes. During prenatal formation, pituitary gland and sella turcica, the two important structures are located in the boundary region, separating tissues of different origin and development. Origin of the pituitary gland is a result of interaction between oral ectoderm which gives rise to anterior pituitary and neural ectoderm gives rise to posterior pituitary. The pituitary fossa differentiates directly from the hypophyseal cartilage which in

turn is derived from the cranial neural crest cells of the early chondrocranium.

During embryological development, sella turcica area is the key point for the migration of the neural crest cells to the fronto nasal and maxillary developmental fields. Formation and development of the anterior part of the pituitary gland, sella turcica, and teeth share in common, the involvement of neural crest cells, and dental epithelial progenitor cells differentiate through sequential and reciprocal interaction with neural crest-derived mesenchyme. Posterior part of the pituitary gland develops from the paraxial mesoderm which is closely related to notochordal induction.^[2]

During the postnatal development, deposition of bone on the anterior part of the interior surface of the sella turcica ceases at an early age, whereas resorption on the distal part of the sella floor and on the posterior wall continues for a longer period of time. Deposition of bone was seen on the tuberculum sellae and resorption at the posterior boundary of sella turcica up to 16-18 years of age.^[2]

The purpose of this study is to analyze predominant morphological parameters and various shapes and abnormalities of sella turcica and contributing to establish reference standard values.

MATERIALS AND METHODS

The study was conducted on 102 dried human skulls obtained from the

Department of Anatomy of Ragas Dental College and Hospital, Uthandi, Chennai, Tamilnadu. Sex of the skulls was not taken into consideration but skulls of extreme ages were avoided. Any abnormalities or fusion of anterior, middle and posterior clinoid processes were noted and excluded.

The morphometric parameters concentrated in this study are the length, breadth, depth (in mid-sagittal plane) and also the shape variations of sella turcica. The linear measurements are calculated with Digimatic vernier caliper and scale. And the measurements from columella to hypophyseal fossa and glabella to hypophyseal fossa are also measured. These values are vital to the neurosurgeons operating in that area.

SIZE OF SELLA TURCICA:

Numerous studies have been done on the size of sella turcica, however the methods differ widely. Due to difference in the method of measurement, comparisons to other studies should be done with caution.

In this current study the parameters are determined with the reference methods of Silverman. Figure 1(a) and (b)

Sella turcica length is obtained by measuring the distance between the midpoint of tuberculum sellae and midpoint of dorsum sellae.^[3]

Sella turcica depth is measured at the deepest part of the sella and is at right

angles to the direction of the length of sella turcica.

Sella turcica breadth is measured from the midpoint of the medial margin of carotid sulcus of both sides.

SHAPE OF SELLA TURCICA:

The study by Axelsson^[4] was used to determine the shape of sella turcica, according to which 5 variations in morphology of sella turcica are described apart from normal morphology.

The different morphological types of sella turcica are (a) normal sella turcica (b) oblique anterior wall (c) double contour of the floor (d) irregularity in the posterior part of sella turcica (e) pyramidal shape of dorsum sellae. Illustrated in figure 2.

OBSEVATION AND RESULTS:

Size of sella turcica:

The morphometric parameters of the sella were measured on 102 study skulls in terms of millimeters. Sex comparison or age factors were not noted in this study. Measurements were taken and mean values and standard deviation were calculated in table 1.

The measurements needed for trans nasal and trans sphenoidal approach (needed during surgery) is also taken in this study and their average values and standard deviation were calculated and tabulated in table 2.

Shape of sella turcica:

The morphological variations in sella turcica have been reported by many researchers through time. The study done by Axelsson^[4] in 2004 is used as comparative standards for this study and the variations in shape of sella turcica is observed in our study skulls. Frequency of each shape is tabulated in Table 3.

DISCUSSION :

The anatomy of sellar region is very much vital for neurosurgeons and the discussion about the parameters measured in our study is done below.

Size of sella turcica:

A microsurgical anatomical study on 250 spheroidal blocks from cadavers of different ages was performed by Quakinine and Hardy and found that the average transverse width of sella turcica was 12 mm, length was 8 mm, and the average height was 6 mm.^[5] Silverman^[3] in his extensive longitudinal radiographic investigation of 320 subjects from 1 month to 18 years of age reported that sella turcica was larger in males than in females except during puberty. Axelsson^[4] studied the size of Norwegian males and females longitudinally from 6 to 21 years of age with normal facial appearance and normal occlusion. The depth and diameter in males and females were similar but the length was larger in males. Alkofide^[6] studied the lateral cephalograms of 180 Saudi subjects with an age range of 11-26 years with different skeletal types.

Diameter of sella turcica was larger in class III subjects and smaller in class II subjects. It was found that there were no statistically significant differences between males and females in all the three linear dimensions. When linear dimensions were compared with age, the size of sella turcica was larger in older age group than in the younger age group. According to Preston,^[7] pituitary fossa increased in size with age and found a positive correlation of the area of the sella to age. After 26 years of age, no significant increase was observed on the size. The dimensional changes in the sella turcica had a significant positive linear trend to length, depth, and diameter until 25 years of age.

Our current study gives the mean of sella turcica length, breadth and depth which aids in obtaining the morphological knowledge of sella. These mean data can be used as reference values. This knowledge of the sella turcica is important for neurologists and neurosurgeons operating in the region of cavernous sinus or the surrounding structures helping them to avoid injury to structures in the vicinity to the sella turcica. Endoscopical surgery with trans nasal and trans sphenoidal approaches are the most commonly used approaches by neurologists and neurosurgeons while operating in the hypophyseal or its adjacent area and since sella turcica serves as an important landmark, it is essential to know the size variations of this region. The distance from columella to hypophyseal fossa and the distance from glabella to

hypophyseal fossa were measured and the average was found to be 85 mm and 80 mm respectively. These measurements are very helpful to the surgeons during procedure.

Shape of sella turcica:

The shape of sella turcica was classified by Gorden and Bell in 1922 by examining radiographs of children of age ranging from 1 year to 12 years as circular, oval, and flattened or saucer-shaped and majority of the subjects had either a circular or oval shaped sella.^[17] Other classifications were based on the contours of the sella floor, the angles formed by the contours of anterior and posterior clinoid processes and tuberculum sellae and the fusion of both clinoid processes as sella turcica bridge.^[2] In a recent study by Axelsson et al in 2004, shape of the sella turcica was divided into six main types [fig 2]; normal sella turcica, oblique anterior wall, double – contoured sella, sella turcica bridge, irregularity (notching) in the posterior part of the sella and pyramidal shape of the dorsum sellae.

In our study the normal variation was observed in 56.8% of the subjects whereas 39.2% were seen different variation. The finding of oblique anterior wall in the current study and Axelsson study is similar. The pyramidal shape of the dorsum sella was more frequent in the current study than Axelsson study. The presence of sella turcica bridge was seen in 6% -16 % of the subjects, however none were found in our study.

Similarly the double contour of the floor was not found in our study. Irregularity in the posterior part of sella turcica i.e. a notched appearance is seen in 17.64% whereas in Axelsson study it was found in 11% of the subjects. The shape variations is a significant factor since it helps in identifying any enlargement or erosions of the bone which throws some light into diagnosing any pathologies of the gland.

Some pituitary adenomas can extend inferiorly, growing downward and invading the sphenoid bone and cavernous sinus. Adenomas greater than 10mm (macroadenomas) can cause remodeling of the underlying sphenoid bone altering the shape of the sella turcica. In such cases it is essential to know the normal variations of the shape of sella turcica for an appropriate diagnosis and in strategizing treatment plans.

CLINICAL SIGNIFICANCE:

Sella turcica is an important landmark readily seen on lateral cephalograms and acts as a noteworthy reference point in cephalometric analysis which is commonly done prior to skull based procedures.^[14,15] In orthodontics, sella point which is located at the center of sella turcica is one of the most commonly used landmarks in cephalometrics. Such landmarks are used to measure the positions of maxilla and mandible in relation to the cranium

and to themselves. These relationships provide the orthodontist with a perfect study tool in determining the growth of an individual through superimposition of structures on a longitudinal basis, and during evaluation of orthodontic treatment results.

It is traceable for metric analysis which makes it an excellent source of information^[15] and thorough knowledge of anatomy of this region is important to neurologists and neurosurgeons dealing with the pathologies and anomalies of this region. Pathological enlargement of the pituitary fossa can be detected by this technique and in diagnosing anomalies or tumors of the pituitary gland, like pituitary adenoma which is the commonest tumor of the pituitary gland. Recognizing variations of the morphology is important in preventing damage during surgery.^[11]

CONCLUSION:

Approximately 57 percent of the study had a normal sella turcica. The results of the current study of sella size and shape may be used as reference guide in doubtful cases of pathological enlargement of the pituitary fossa. Identifying the variations helps in preventing damage during surgery. Growth of the individual can be assessed based on the size of the sella turcica at different age period which can be used as a diagnostic tool in orthodontic treatment.

REFERENCES:

1. Study of sella turcica with associated anomalies in the human skulls by Dr.A. K. S. Bilodi Department of Anatomy Nepalgunj Medical College, Chisapani, Nepal. 2005; 27: 3-6
2. Sella turcica-Its importance in orthodontics and craniofacial morphology Haritha Pottipalli Sathyanarayana, Vignesh Kailasam, and Arun B Chitharanjan 2013; 10(5): 571–575.
3. Silverman FN. Roentgen standards for-size of the pituitary fossa from infancy through adolescence. Am J Roentgenol Radium Ther Nucl Med. 1957;78:451–60.
4. Axelsson S, Storhaug K, Kjaer I. Post-natal size and morphology of the sella turcica. Longitudinal cephalometric standards for Norwegians between 6 and 21 years of age. Eur J Orthod 2004;26:597-604
5. Quakinine GE, Hardy J. Microsurgical anatomy of the pituitary gland and the sellar region the pituitary gland. Am Surg. 1987;53:285–90.
6. Alkofide EA. The shape and size of the sella turcica in skeletal Class I, Class II, and Class III Saudi subjects. Eur J Orthod. 2007;29:457–63.
7. Preston CB. Pituitary fossa size and facial type. Am J Orthod. 1979; 75:259–63
8. Friedland B, Meazzini MC. Incidental finding of an enlarged sella turcica on a lateral cephalogram. Am J Orthodont Dentofac Orthoped. 1996; 110:508-12.
9. Feldkamp J, Santen R, Harms E, Aulich A, Mödder U, Scherbaum WA. Incidentally discovered pituitary lesions: high frequency of macroadenomas and hormone-secreting adenomas: results of a prospective study. Clin Endocrinol. 1999;51:109-13.
10. Alkofide E. Pituitary adenoma: a cephalometric finding. Am J Orthodont Dentofac Orthoped. 2001;120:559-62.
11. Gulsen S, Dinc AH, Unal M, Cantürk N, Altinors N. Characterization of the anatomic location of the Pituitary stalk and Its relationship to the Dorsum Sellae, Tuberculum Sellae and Chiasmatic Cistern, J Korean Neurosurg Soc. 2010;47 :169-173.
12. Subhadra Devi V, Baburao S. Age and sex related morphology and morphometry of sellar region of sphenoid in prenatal and postnatal human cadavers. Int. J. Res. Dev. Health. 2013; 1 (3): 141-148.
13. Dionyssios Venierators, Sophia Anagnostopoulou, Anna Garidou, New morphometric method for Hypophyseal fossa and its clinical relevance, Department of Anatomy, University of Athens, Greece.
14. Proffit, William R. Contemporary Orthodontics, 4th Edition. C.V. Mosby

15. Morphometric analysis of sella turcica in North Indian population: a radiological study by Puja Chauhan, Shashi M. Mongia, Sadakat Ali, Anurag, Department of Anatomy, Shri Guru Ram Rai Institute of Medical and Health Sciences, Dehradun, Uttarakhand, India and, Sunita Kalra Department of Anatomy, University College of Medical Sciences, Delhi-110095, India.
16. M.Andredaki, A.Koumantanou, D.Dorotheou, D.J.Halazonetis, Morphometric study of sella turcica, orthodontic department, university of Athens, Greece.
17. Ahsan Mahmood Shah, Ulfat Bashir(Orthodontics), Tasleemilyas, The shape and size of sella turcica in skeletal class I, II, III in patients at Islamic International Dental Hospital, Islamabad.

TABLES:

	Length of sella turcica	Breadth of sella turcica	Depth of sella turcica
Mean value	10.59mm	10.76mm	9.23mm
Standard deviation	1.77	2.24	1.45

Table 1: Mean and standard deviation for length, breadth and depth of sella turcica

	Distance from columella to hypophyseal fossa	Distance from glabella to hypophyseal fossa
Mean value	85mm	80mm
Standard deviation	2.11	1.72

Table 2: Mean and standard deviation required for trans nasal and trans sphenoidal approaches.

SELLA TYPE	FREQUENCY
Normal sella turcica	58
Oblique anterior wall	14
Double contour of the floor	0
Irregularity in the posterior part of sella turcica	18
Sella turcica bridge	0
Pyramidal shape of dorsum sellae	12
Total	102

Table 3: Frequency of morphological shapes of sella turcica

FIGURES:

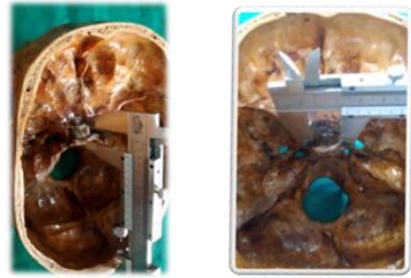
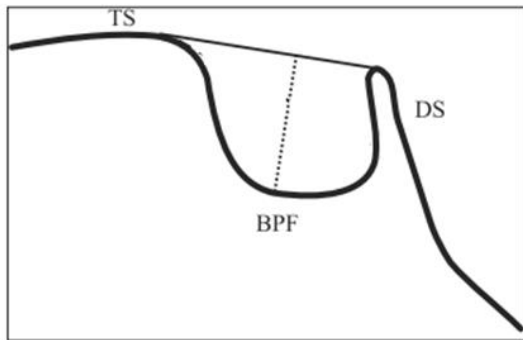


Figure 1: (a) Reference lines used for measuring sella size: TS Tuberculum sellae, DS Dorsum sellae, BPF Base of pituitary fossa; Black line- length of sella; dotted line- depth of sella

Figure 1: (b) Measuring length and breadth of sella using a digital vernier caliper

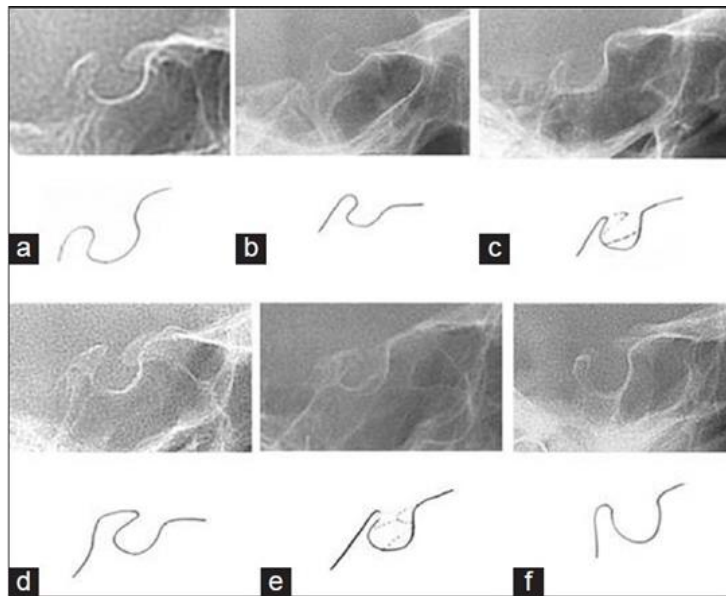


Figure 2: Morphological types of sella turcica