Telemetry and ECG Basics
Make Arrhythmia Great Again!

Joseph J. Gard MD FACC FHRS

Oklahoma Heart Institute

No pertinent disclosures

Systematic Approach

- Determine the atrial rhythm
- Determine the ventricular rhythm
- Assess conduction

Rules of thumb

- Start with what you recognize / know
- Regular or irregular
- P’s and QRS’s
- Don’t miss an emergency

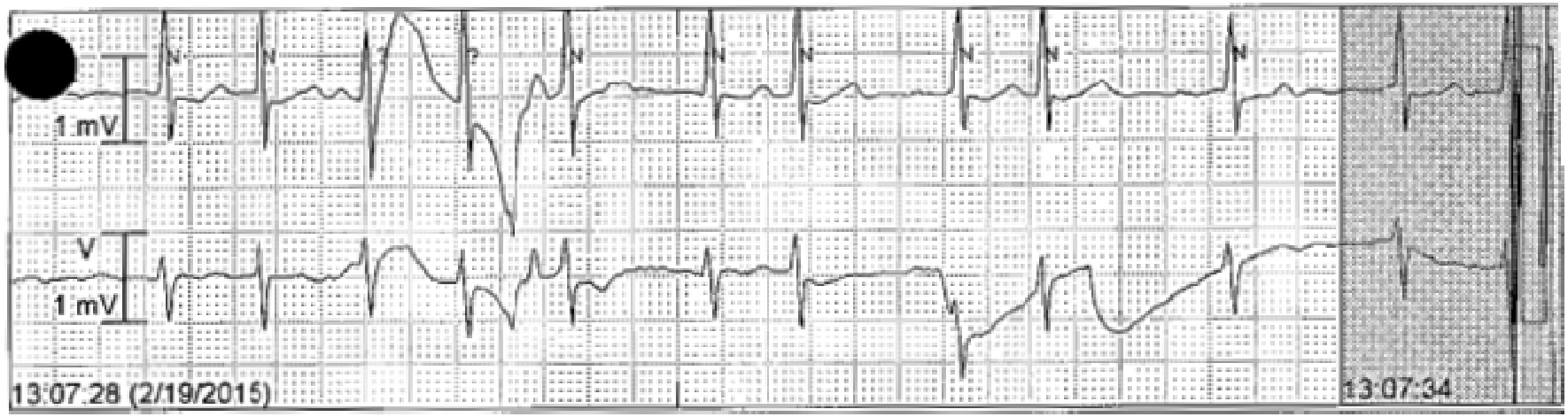
1 mV
V
1 mV
13:07:28 (2/19/2015)
13:07:34

Cardioversion

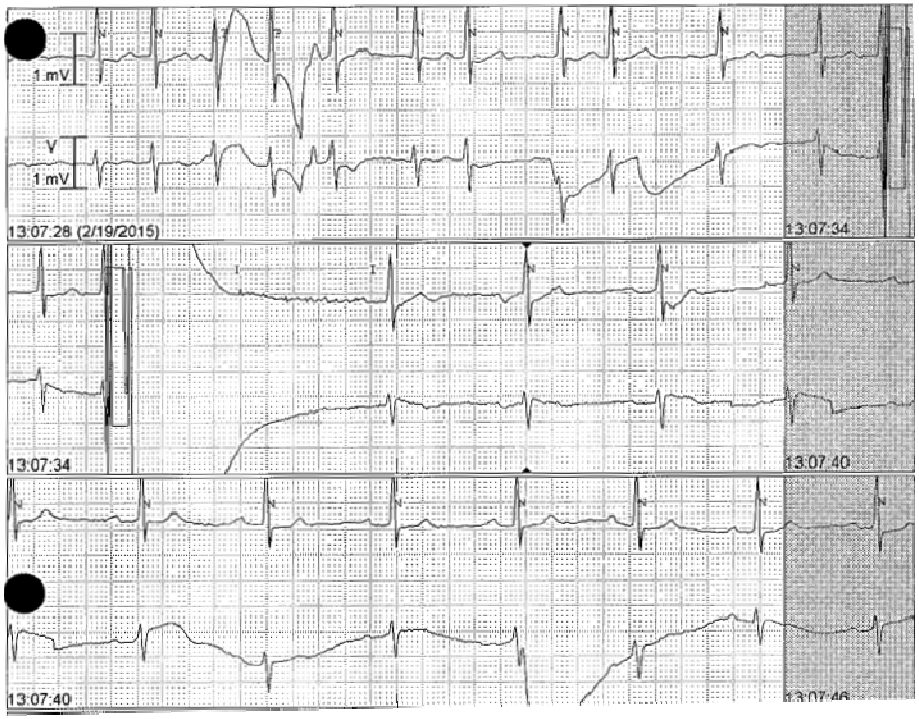

Normal heart rhythm

Electrical activity starts in the SA node. The atria contract, and blood empties into the ventricles.

Atrial fibrillation

Electrical activity in the atria is disorganized. The atria quiver, and blood may pool and form clots.

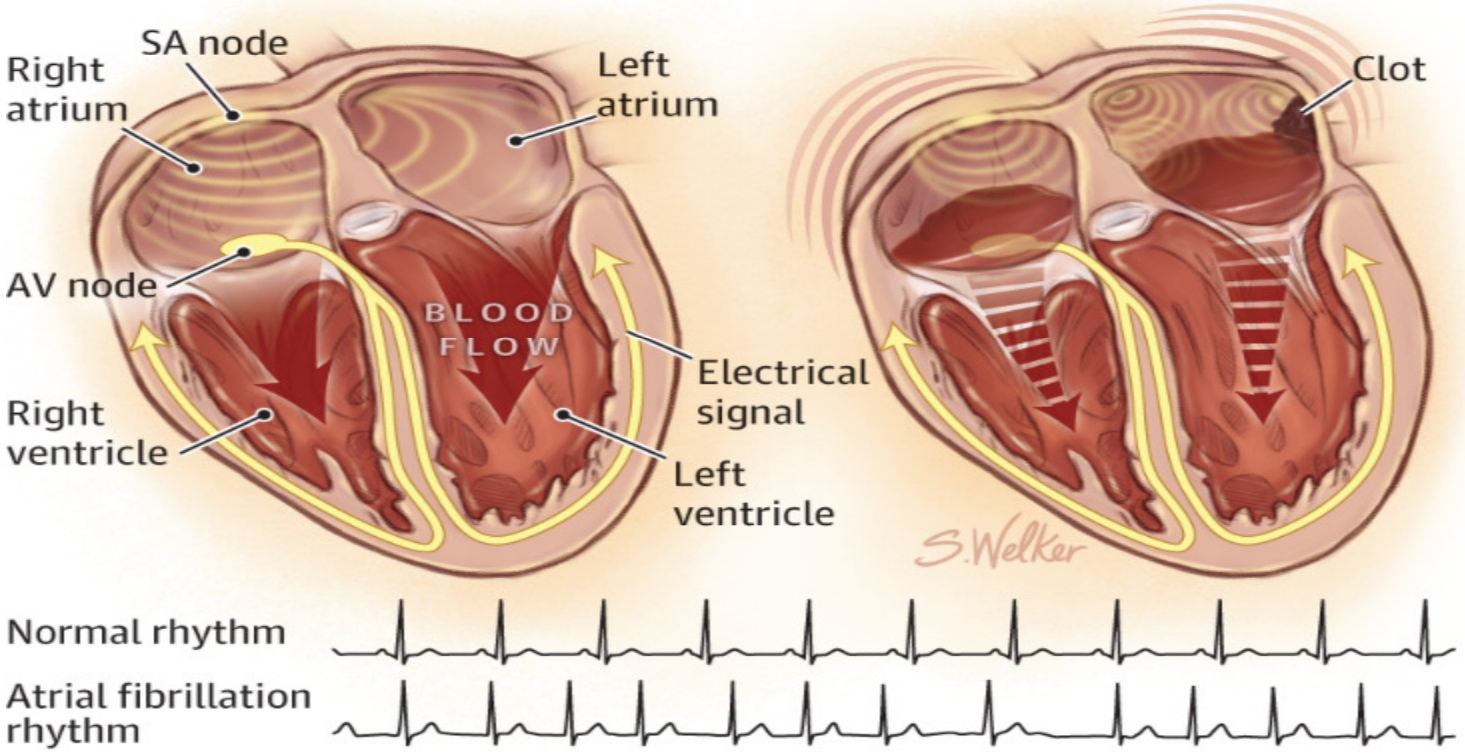

JAMA. 2015;313(10):1070. doi:10.1001/jama.2015.1337

A Tracing from Einthoven in 1906
"Pulsus Inaequalis et Irregularis."
(Atrial Fibrillation)

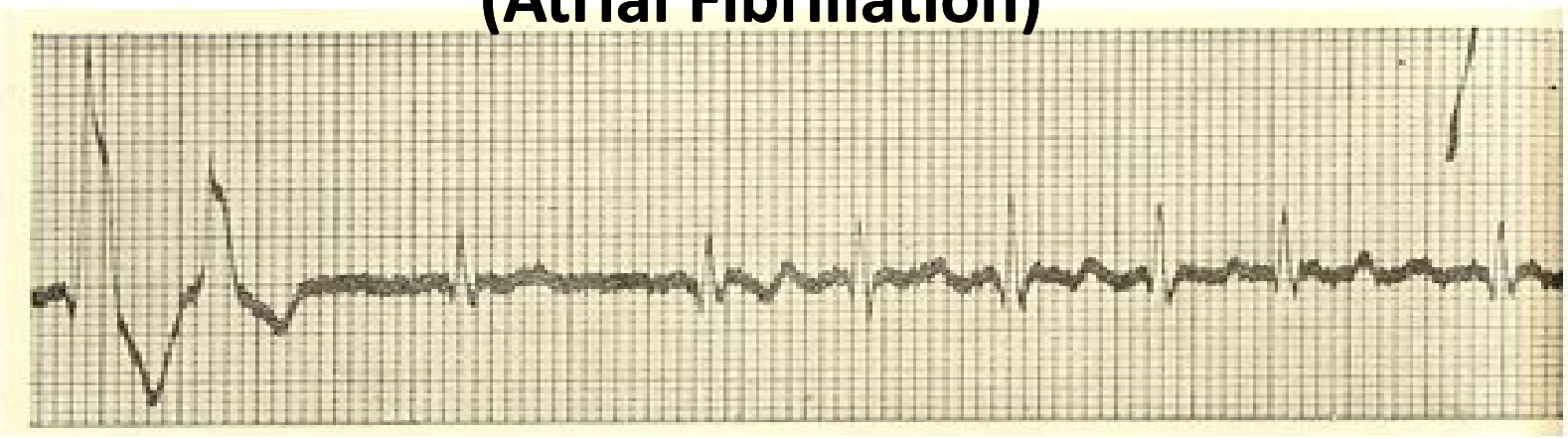

Fye WB. N Engl J Med 2006;355:1412-1414.

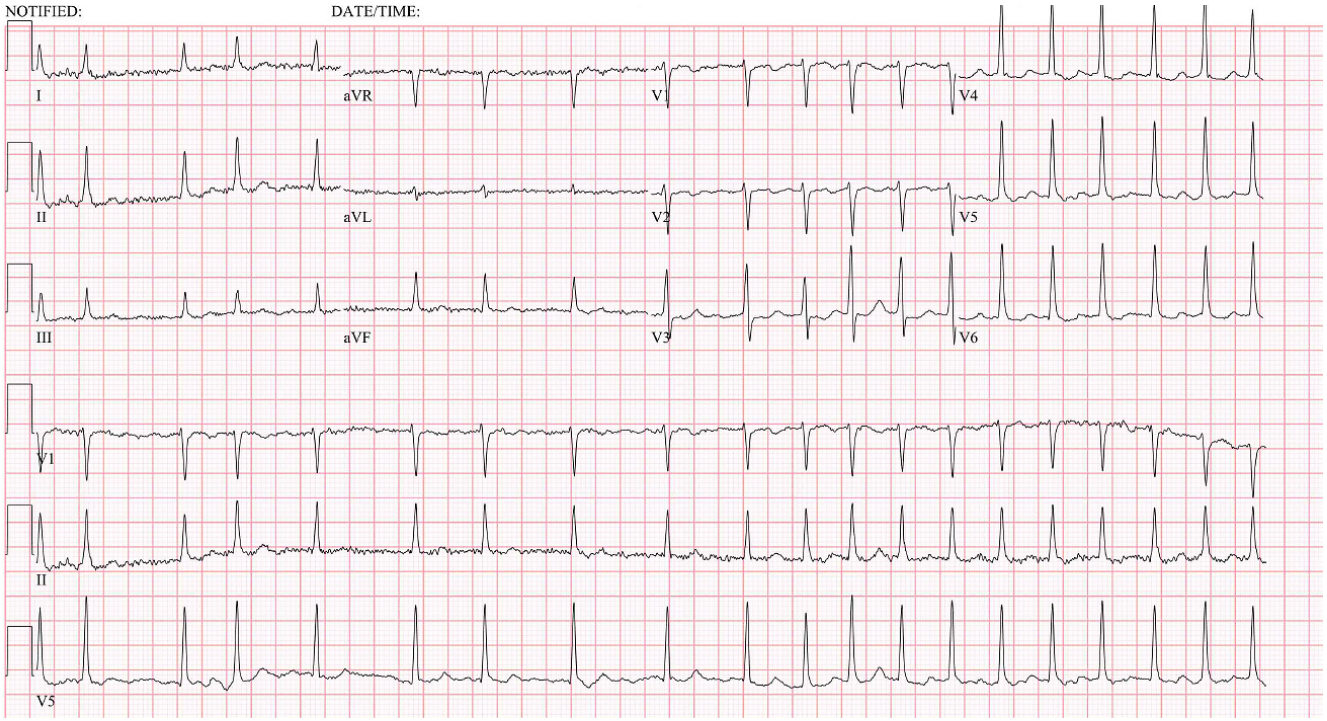
NOTIFIED:
DATE/TIME:
I
aVR
V1
V4
II
aVL
V2
V5
III
aVF
V3
V6
V1
II
V5

AF RVR
Nonspecific ST & T abnl

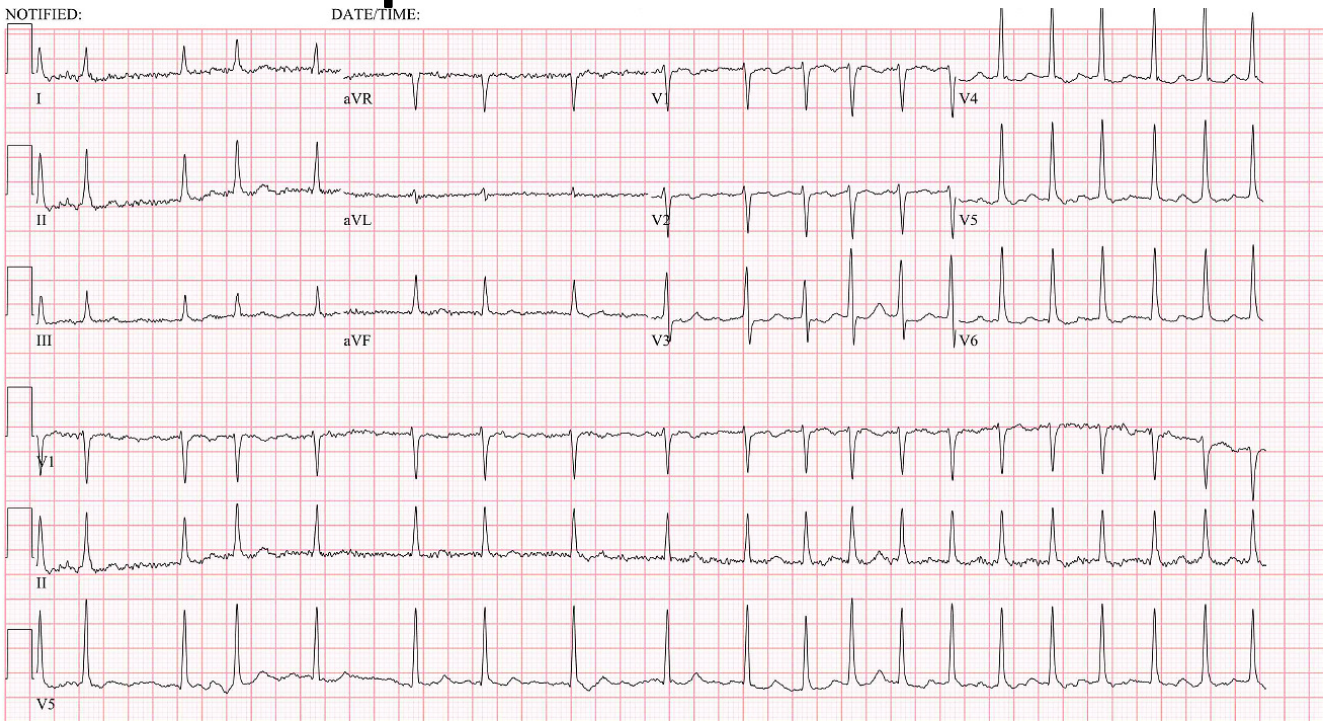

Fibrillation or Flutter

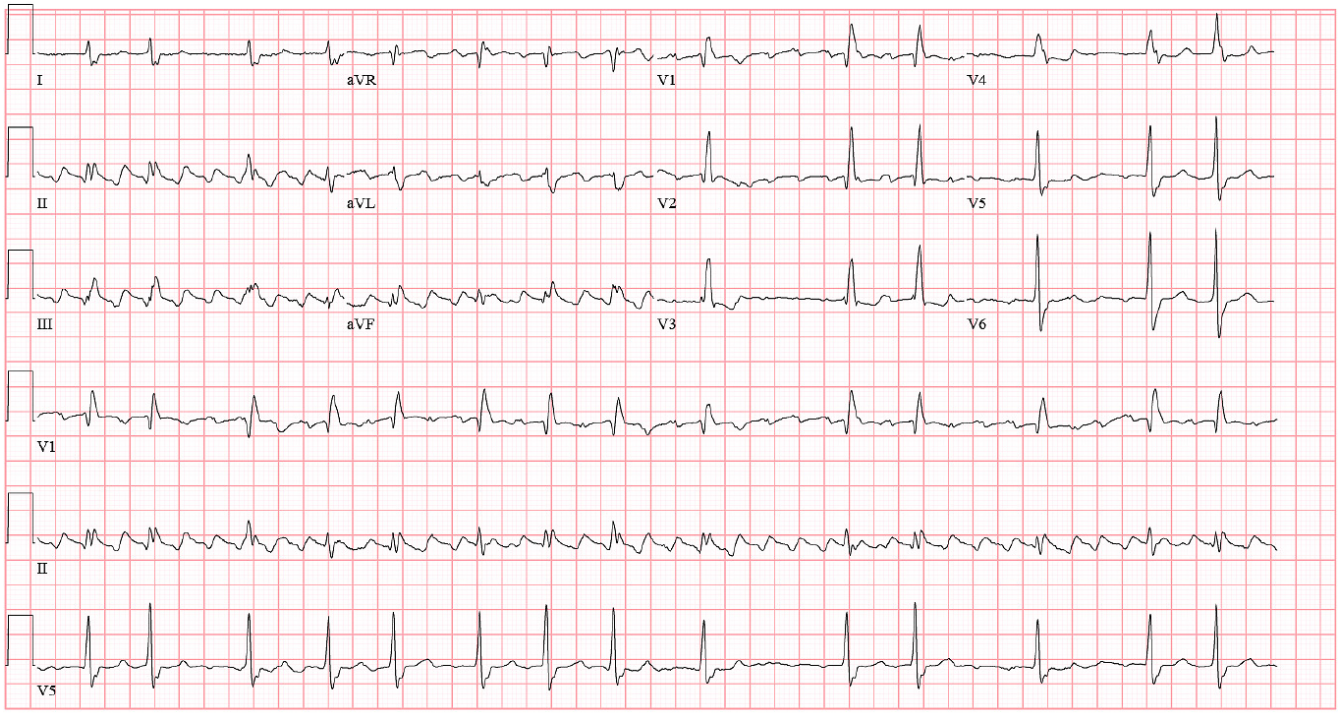
I
aVR
V1
V4
II
aVL
V2
V5
III
aVF
V3
V6
V1
II
V5



Typical AFL

RBBB

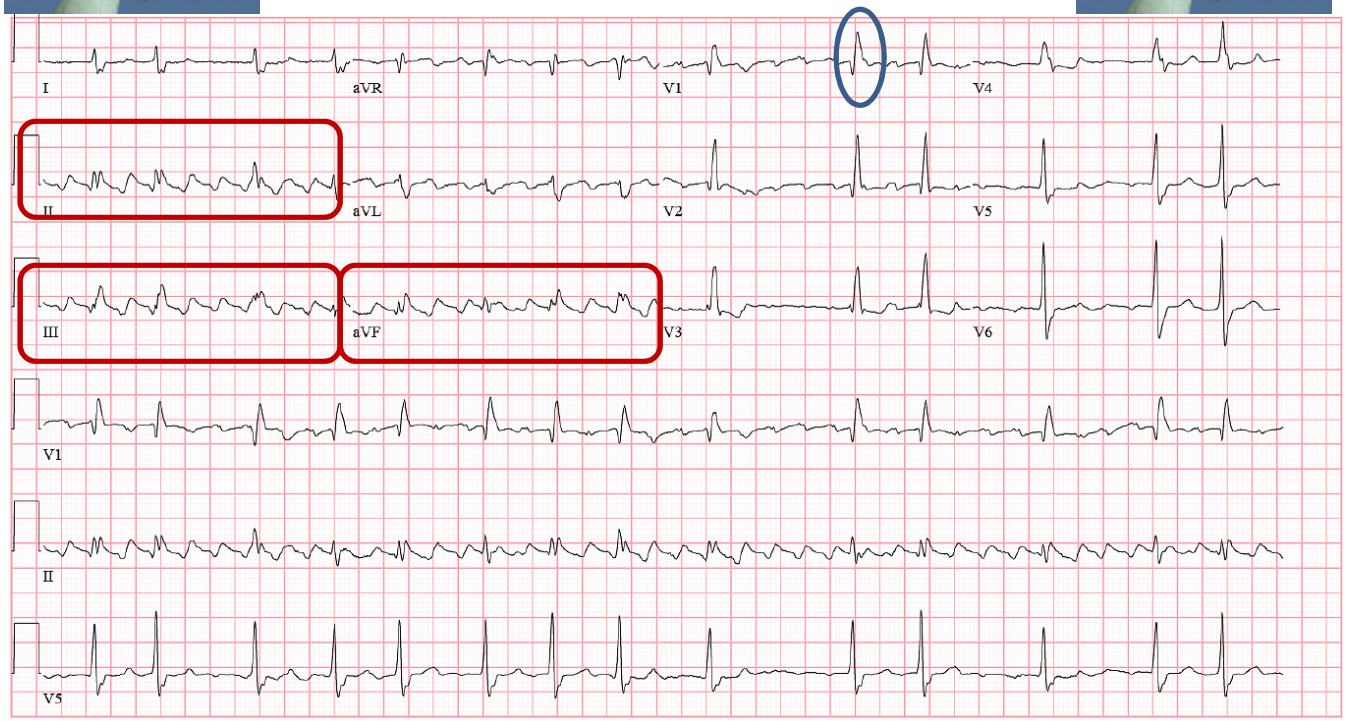

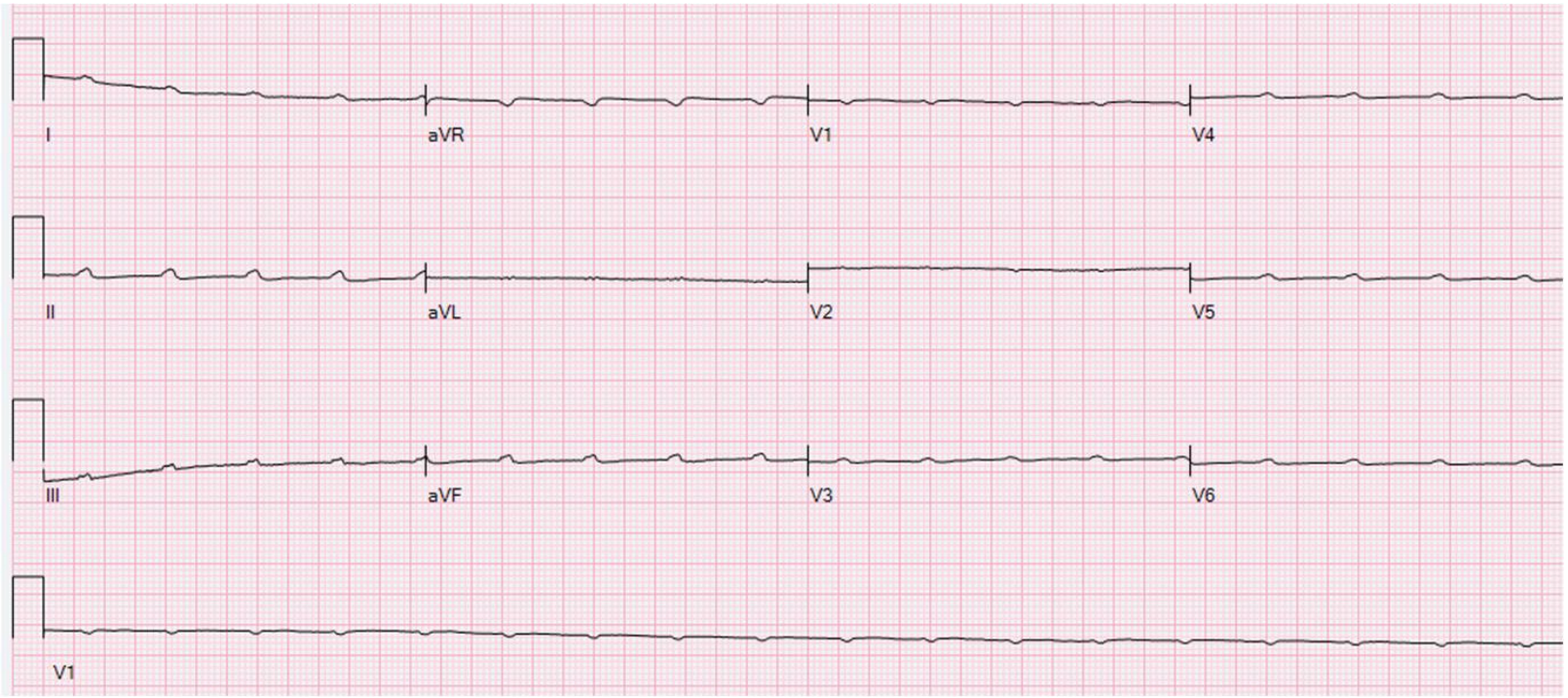
I
aVR
V1
V4
II
aVL
V2
V5
III
aVF
V3
V6
V1

Recommendation:

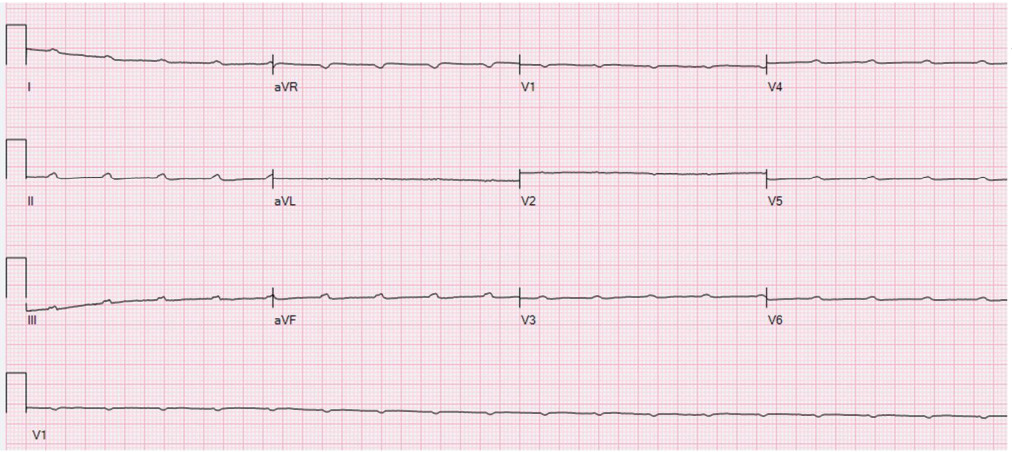

A. Cardioversion
B. Defibrillation
C. Pacemaker
D. Coronary angiogram

Complete Heart Block
Every P wave deserves a QRS

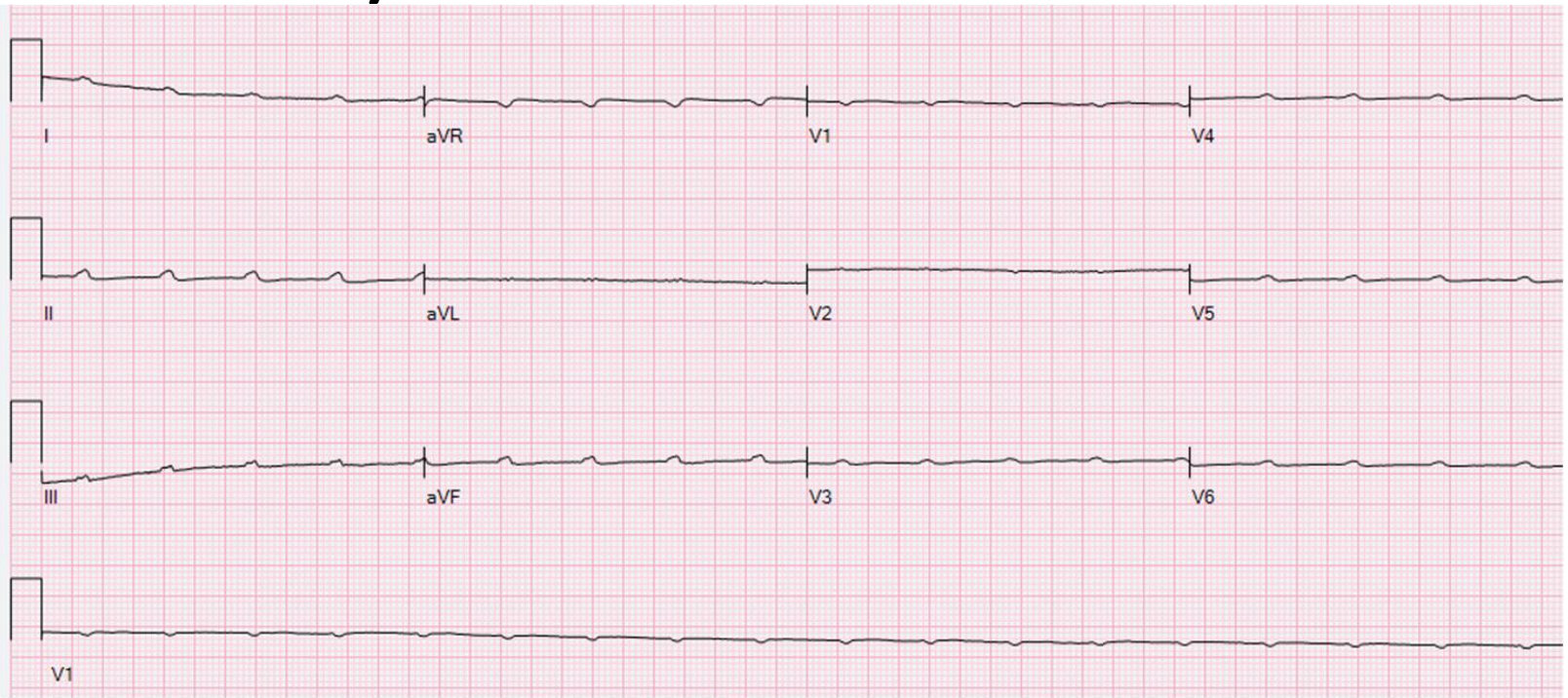

Recommendation:

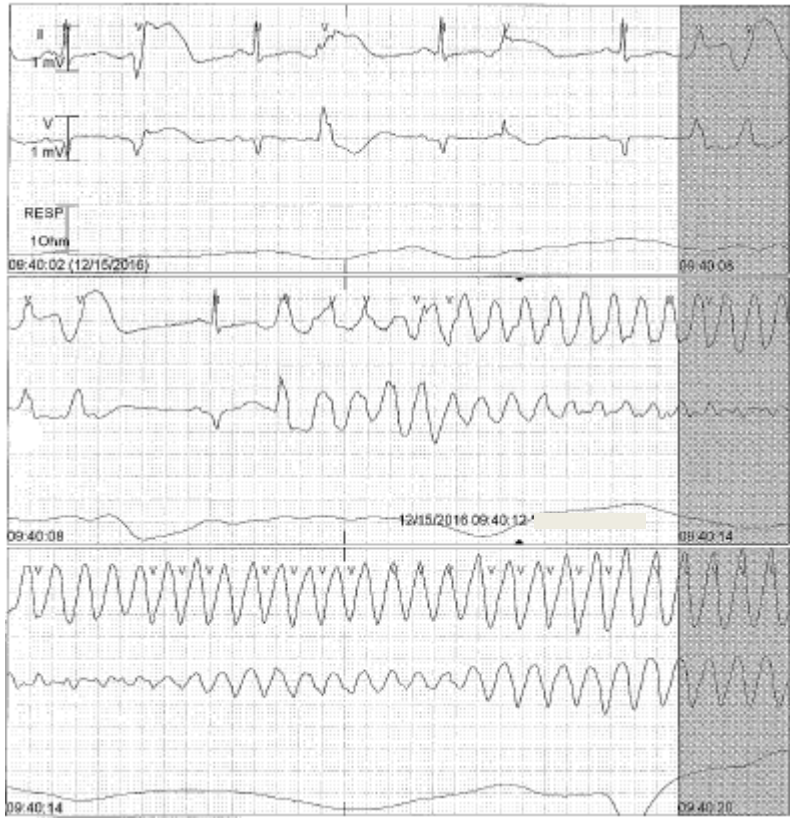

A. Amiodarone
B. Tikosyn
C. Defibrillation
D. Dialysis

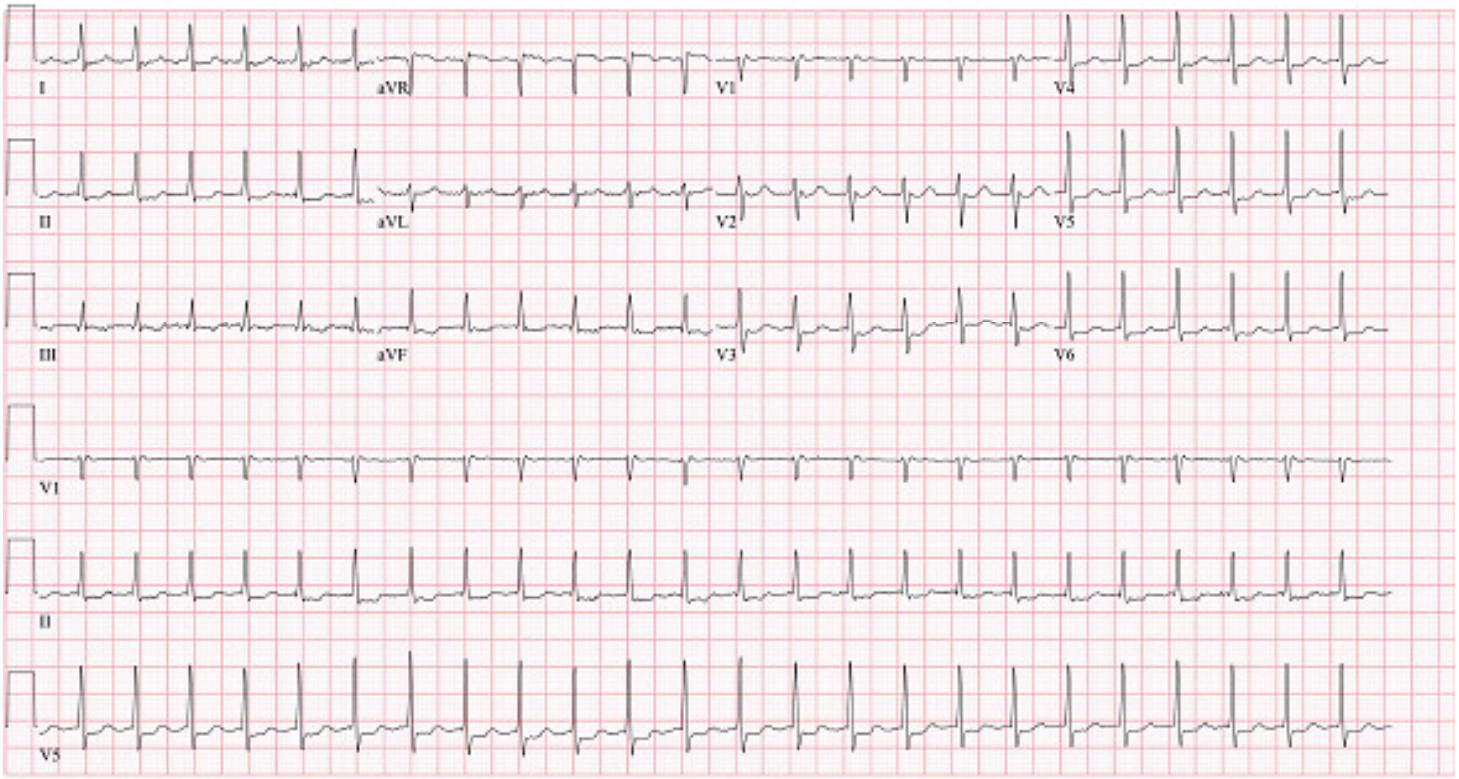
I
aVR
V1
V4
II
aVL
V2
V5
III
aVF
V3
V6
V1
II
V5

SVT (AVNRT)

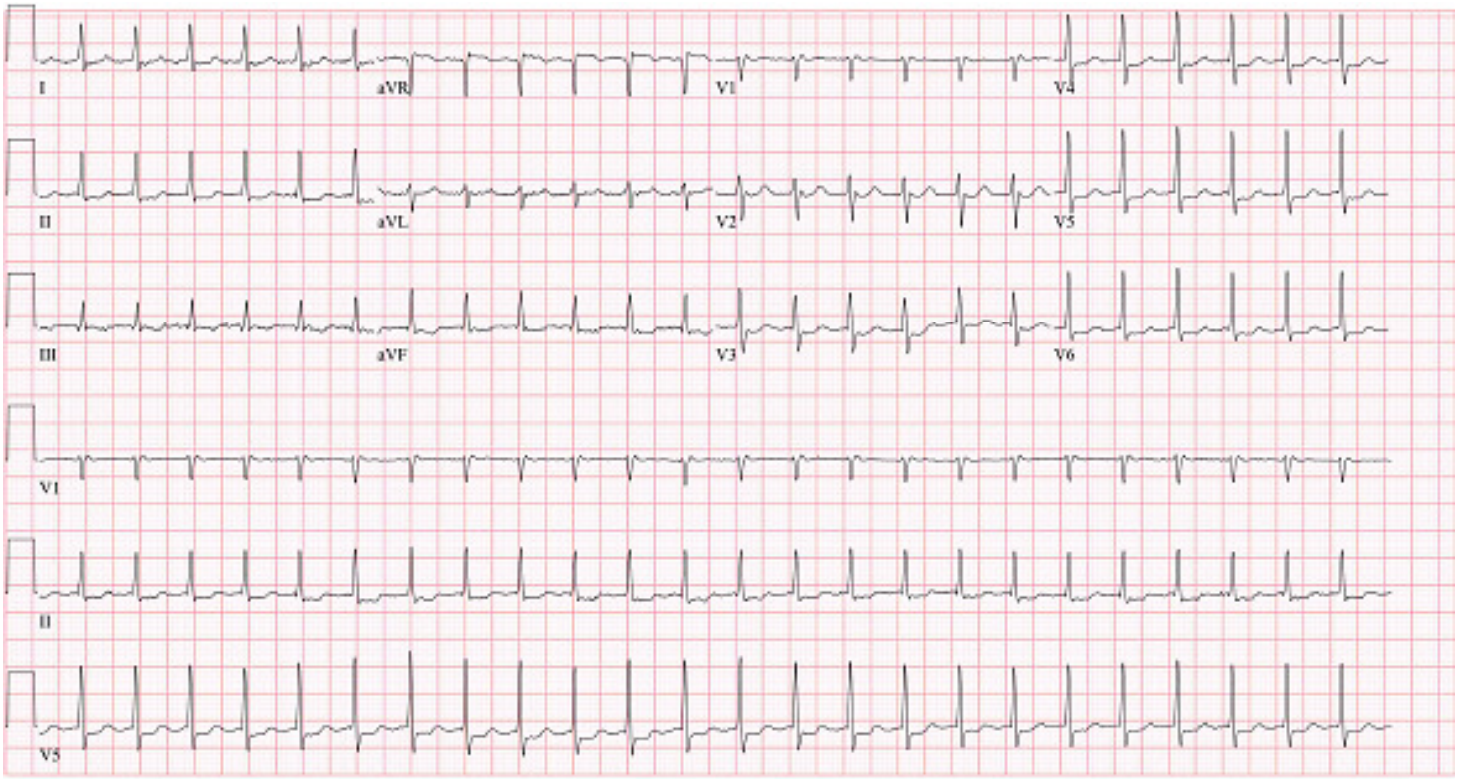

Pause

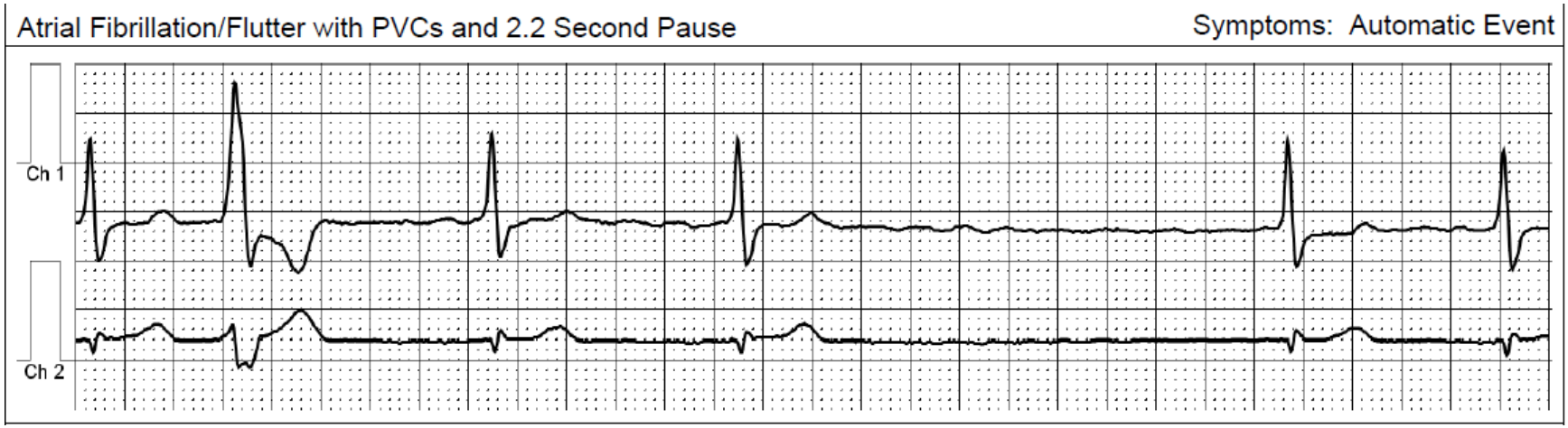
Atrial Fibrillation/Flutter with PVCs and 2.2 Second Pause
Symptoms: Automatic Event
Ch 1
Ch 2

Pause

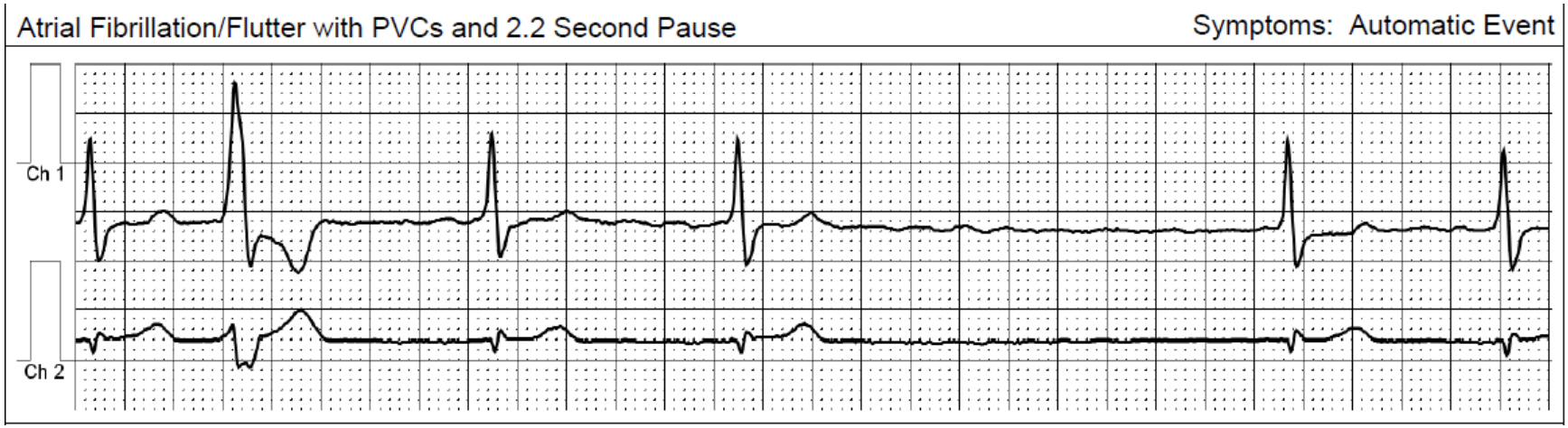

Rule of thumb for pauses:

Sx; SR ≥3sec; AF ≥5sec; trigger malignant arrhythmia

Wide QRS complexes

- IVCD, RBBB, LBBB, Aberrancy
- Ventricular ectopic
- WPW
- Ventricular pacing

ECG: RBBB IMI ASMI

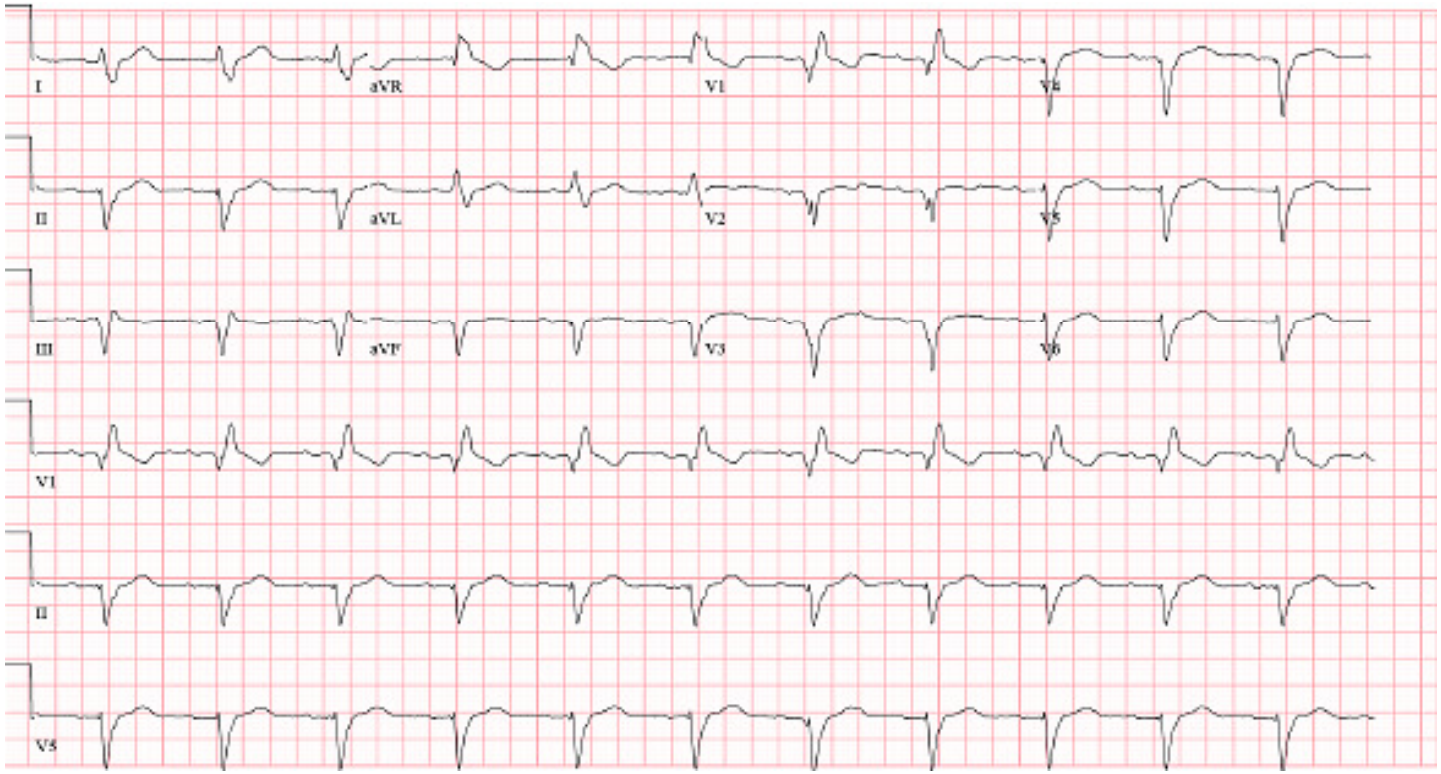

ECG: LBBB

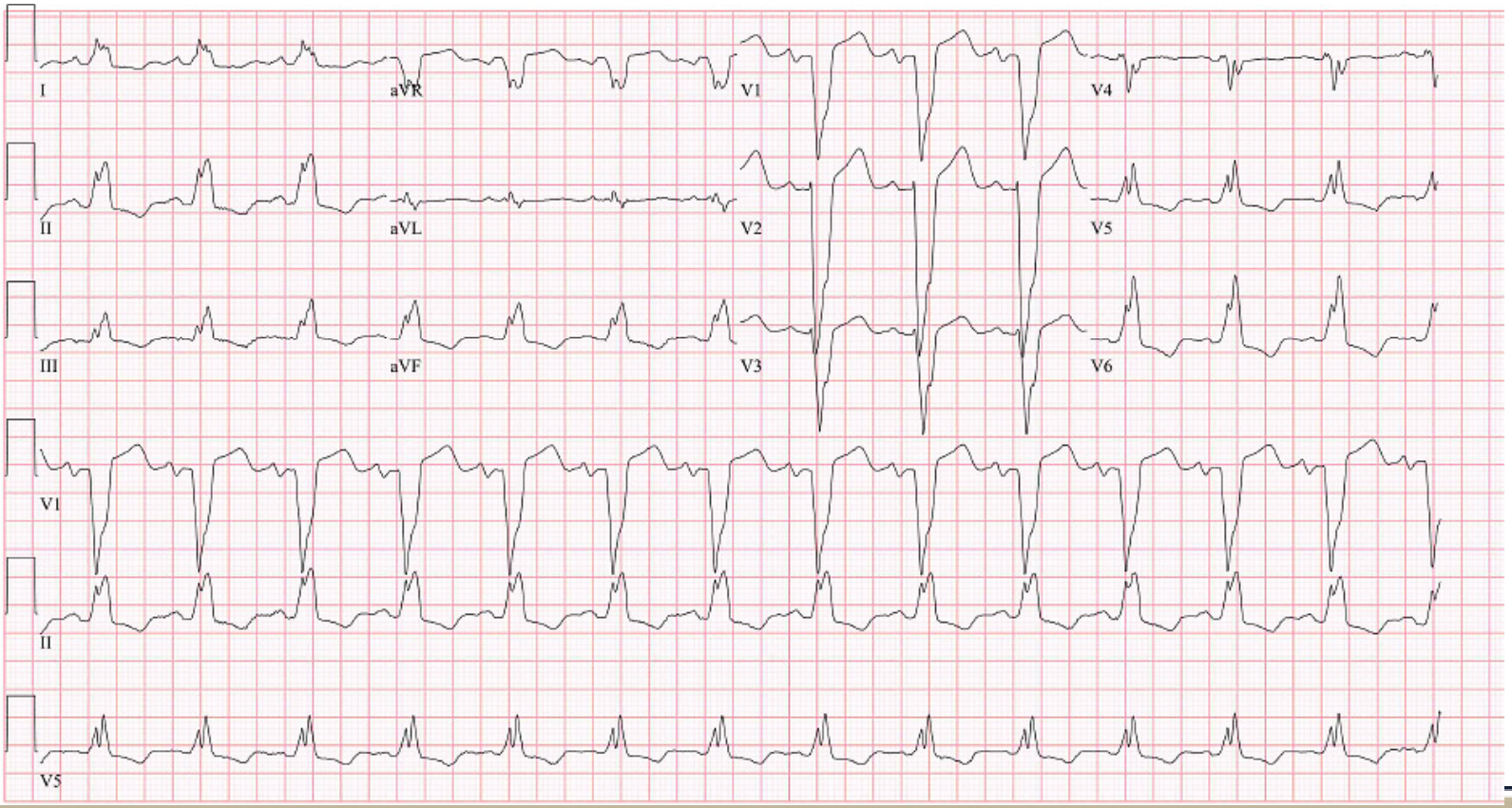

s/p CRT-D Implant

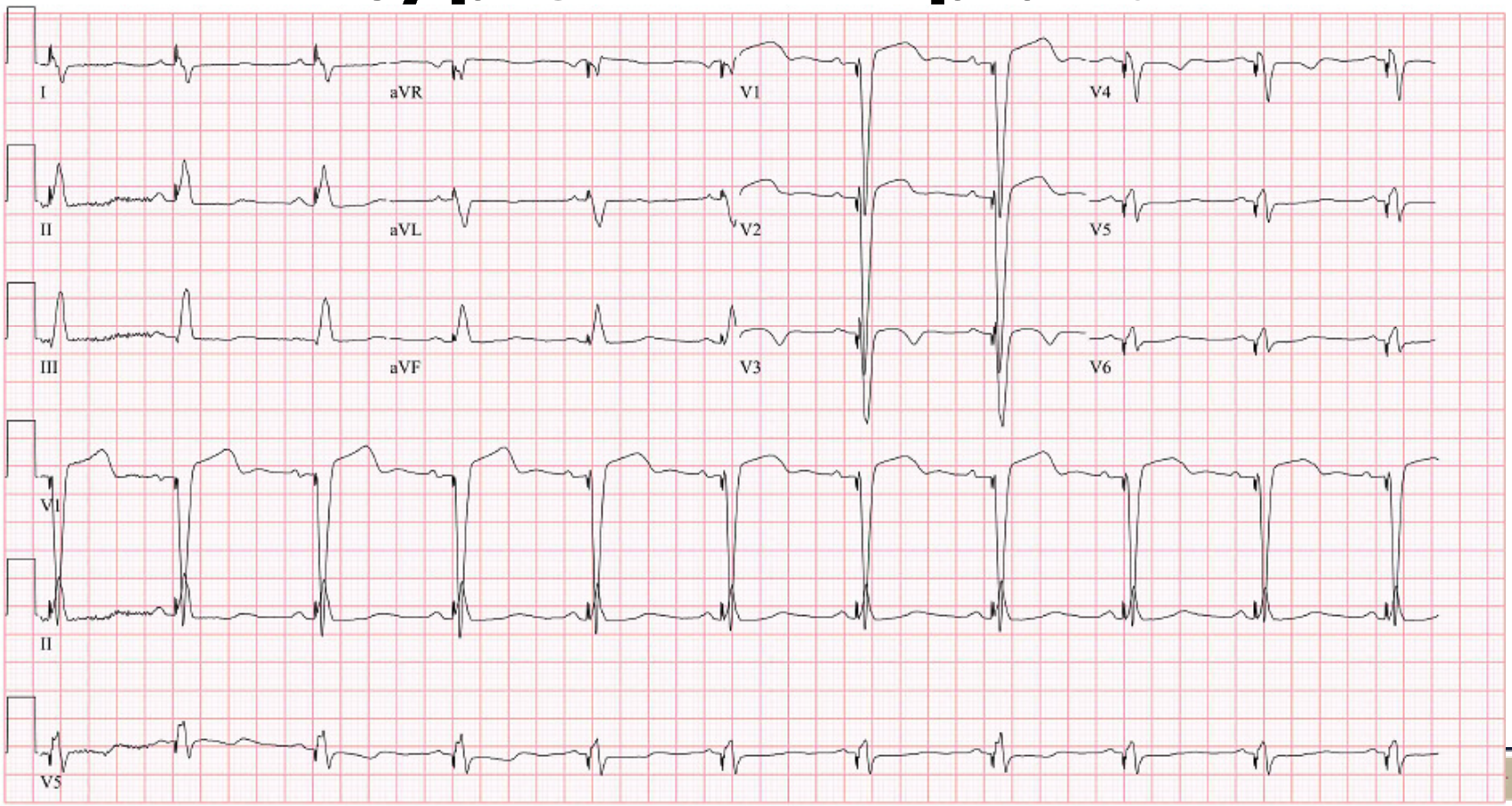

CRT-D

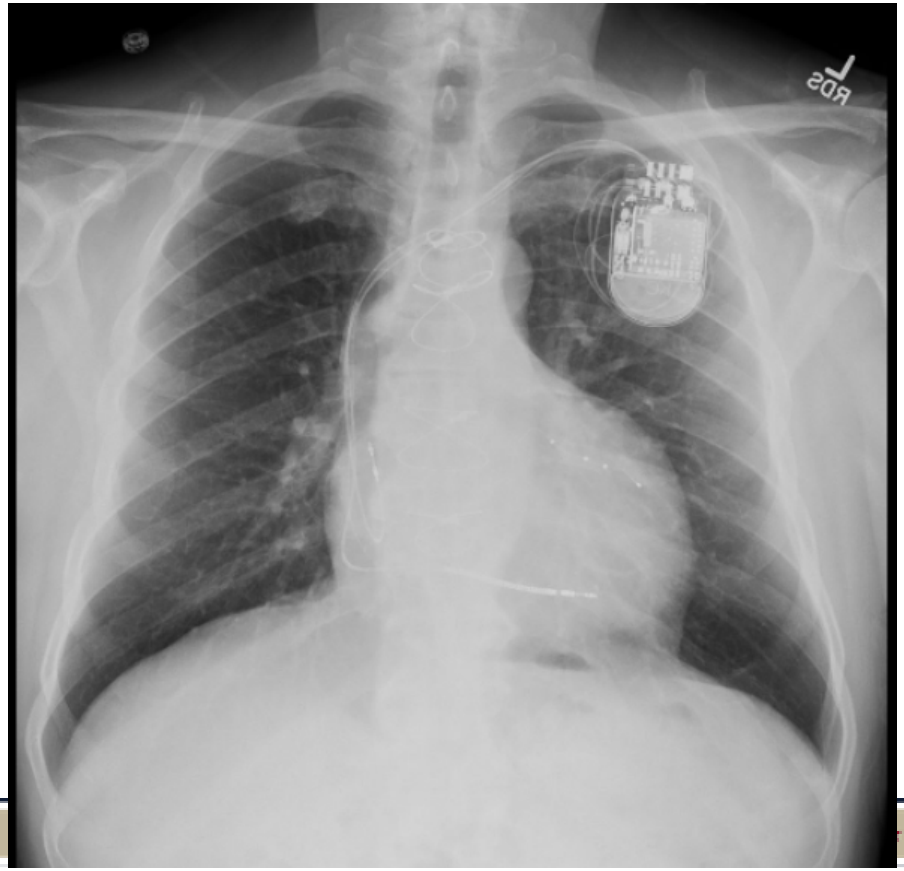

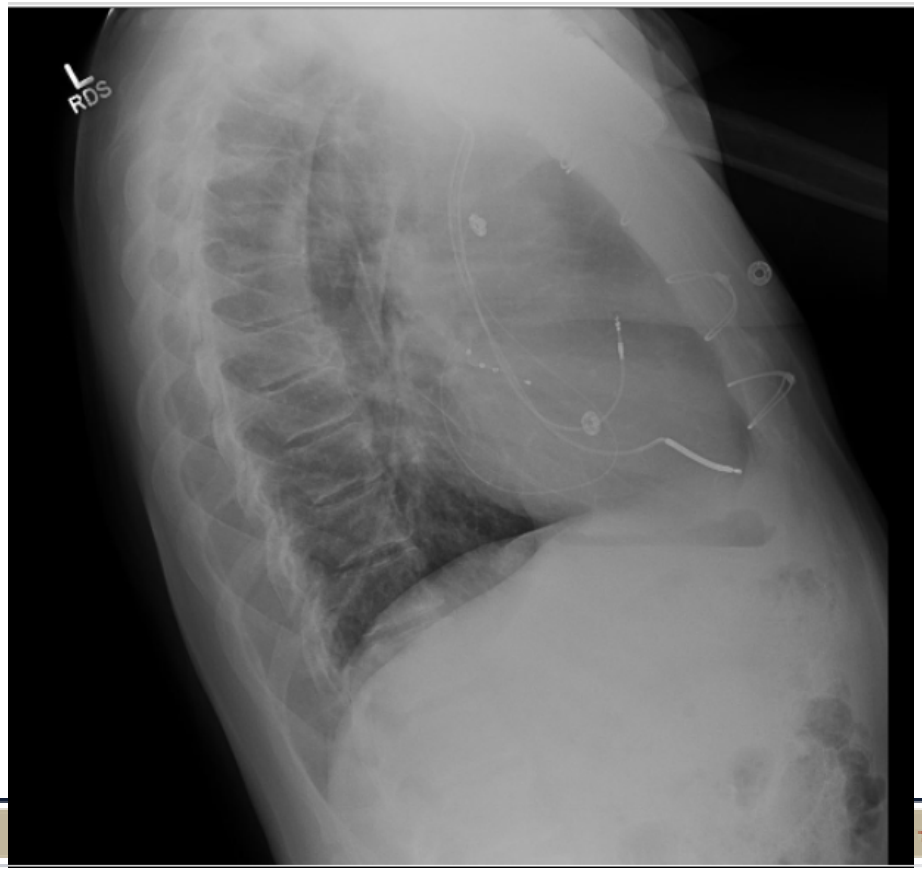

CRT-D

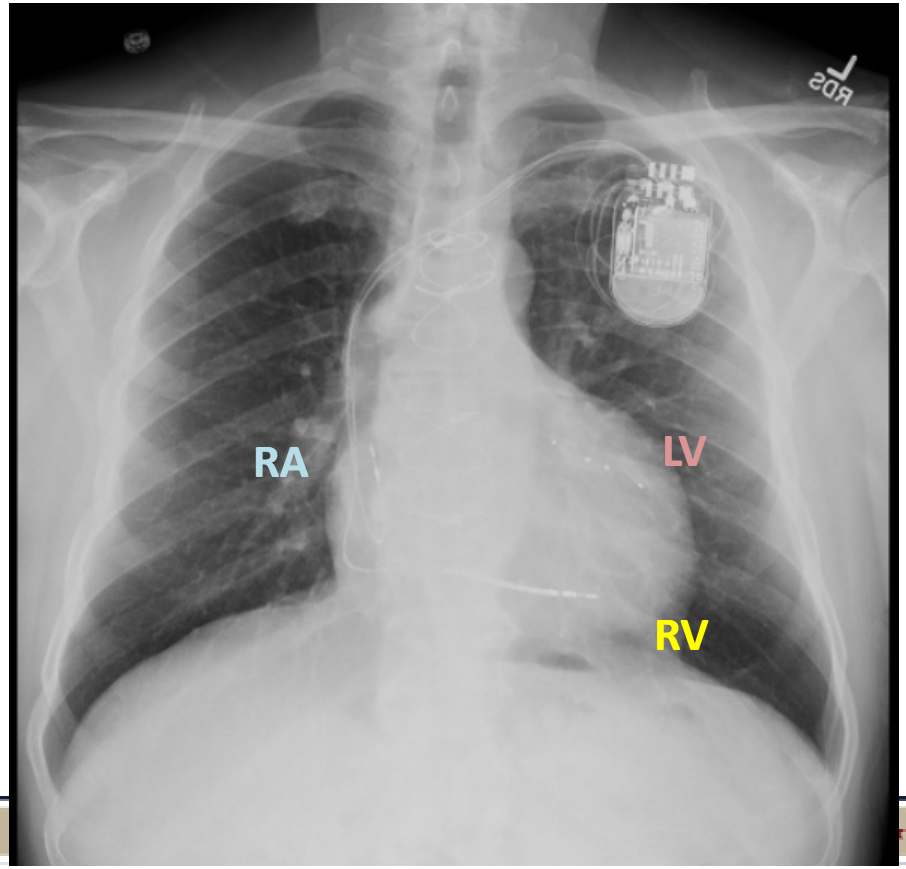

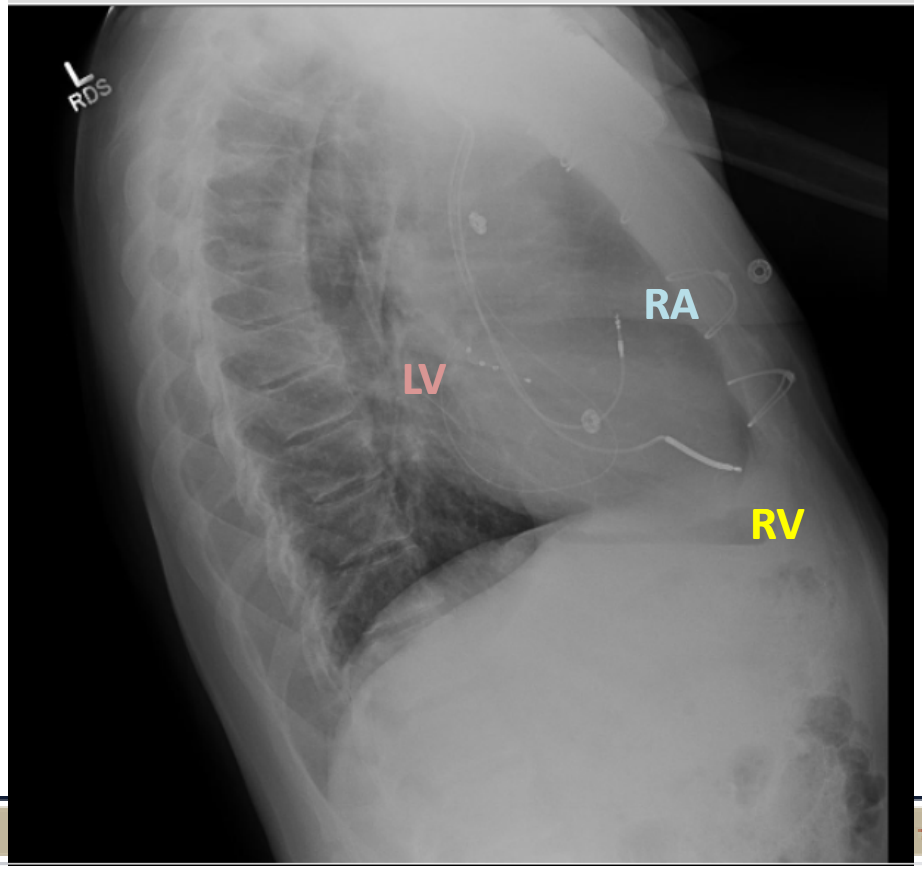

Wide QRS complexes

- IVCD, RBBB, LBBB, Aberrancy
- Ventricular ectopic
- WPW
- Ventricular pacing

Remember your L's

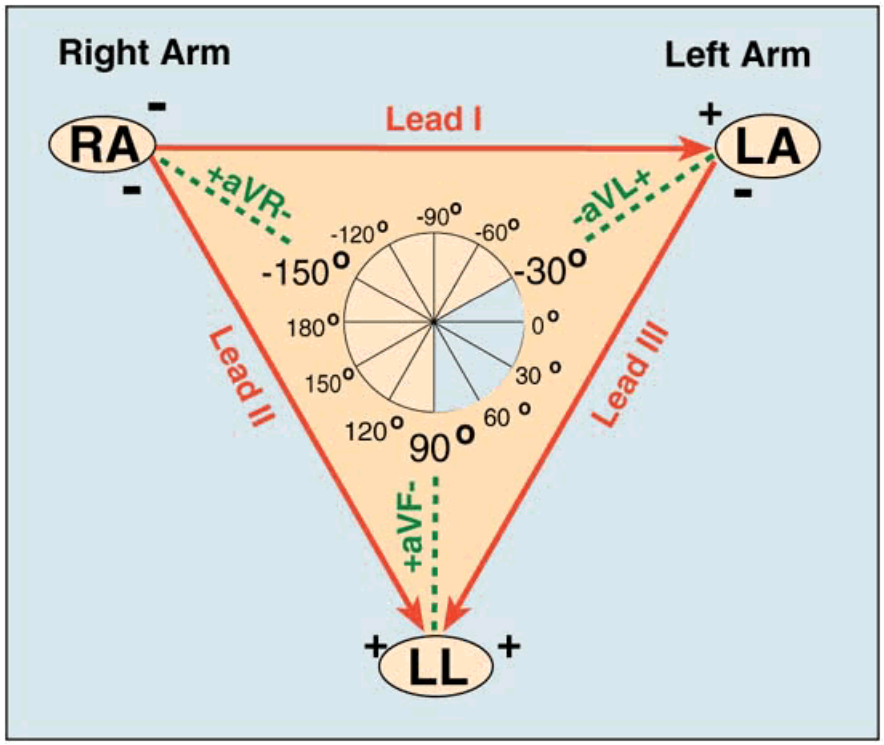

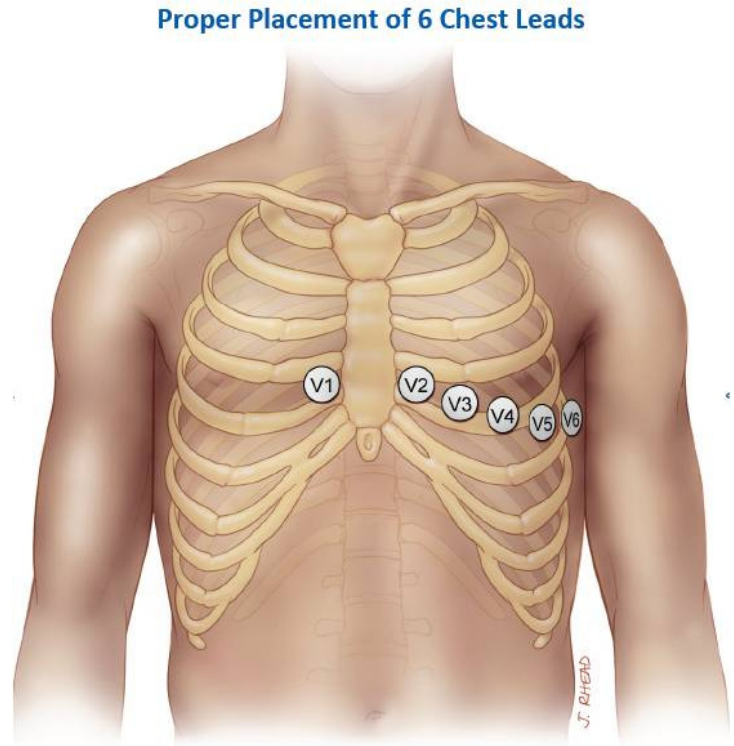

http://ecg.utah.edu/

- V1: right 4th ICS
  V2: left 4th ICS
  V3: halfway b/n V2&V4
  V4: left 5th ICS MCL
  V5: horizontal to V4, anterior axillary line
  V6: horizontal to V5, mid-axillary line

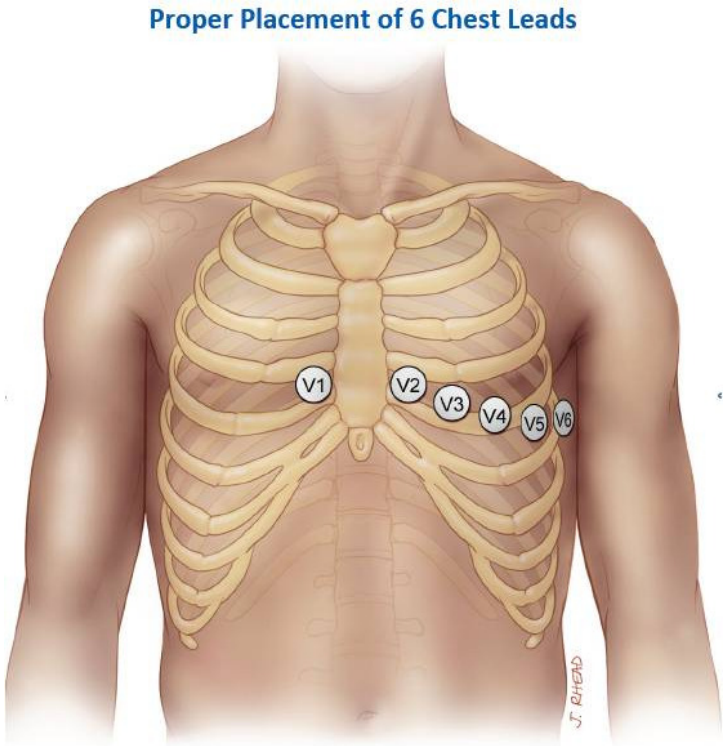

http://ecg.utah.edu/

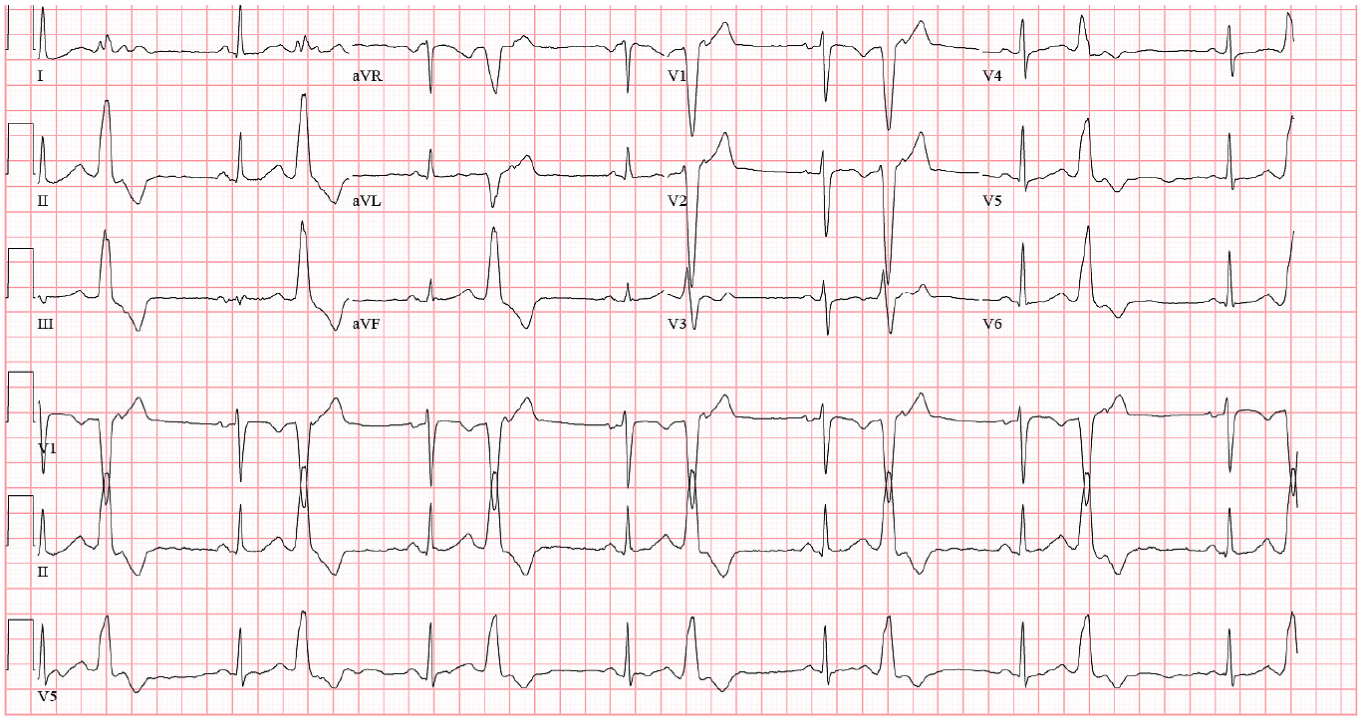
I
aVR
V1
V4
II
aVL
V2
V5
III
aVF
V3
V6
V1
II
V5

RVOT PVC

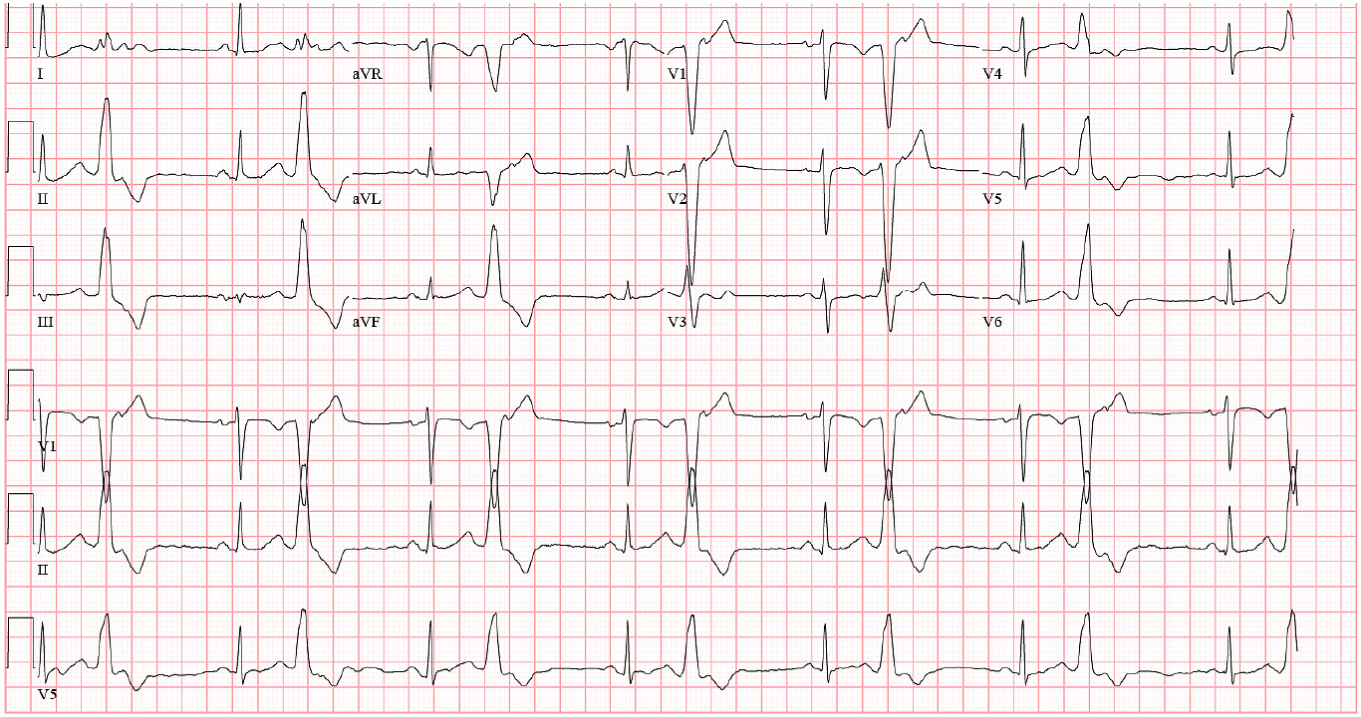

RVOT PVC

- Upright in II, III, aVF
- Negative in V1

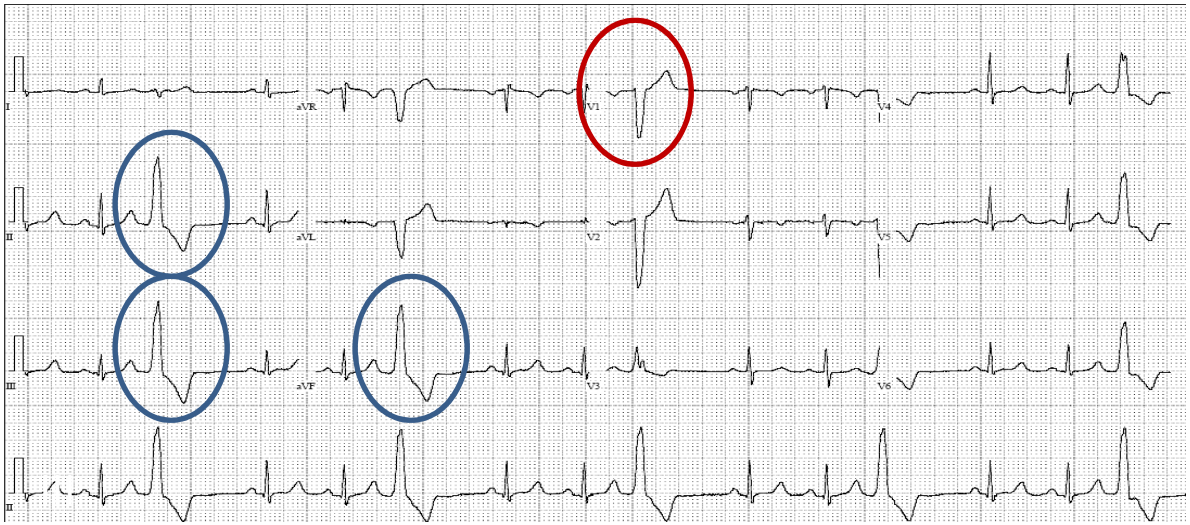

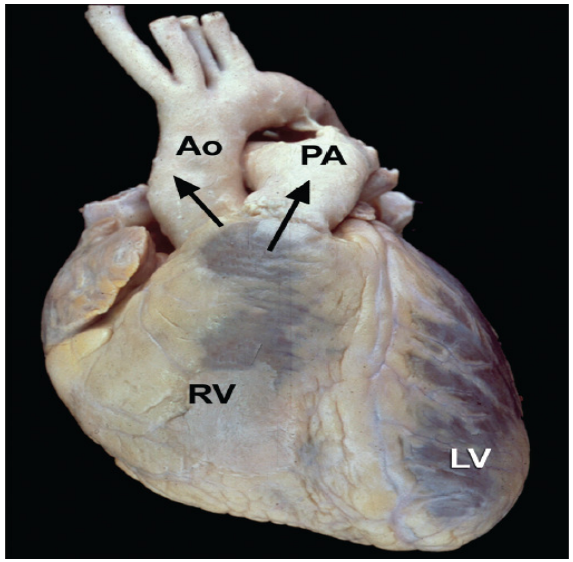

Successful RVOT PVC Ablation

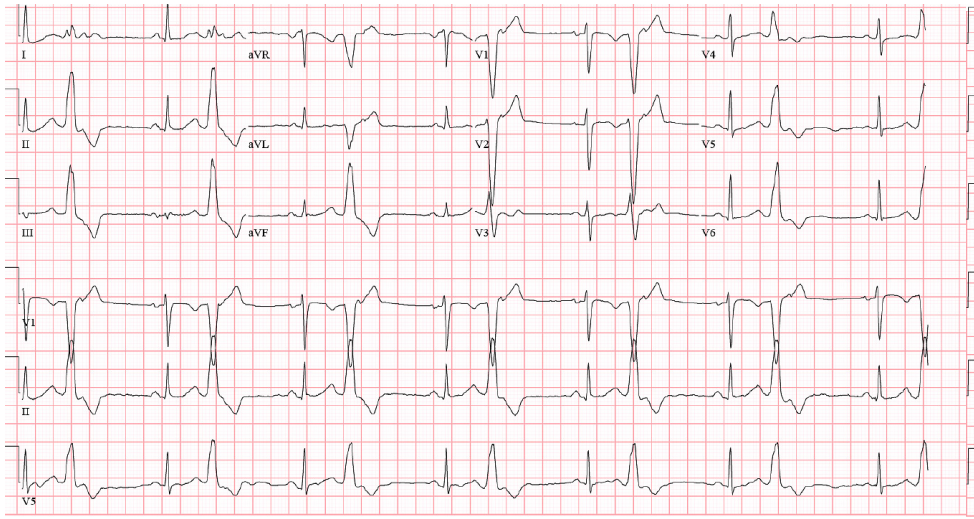

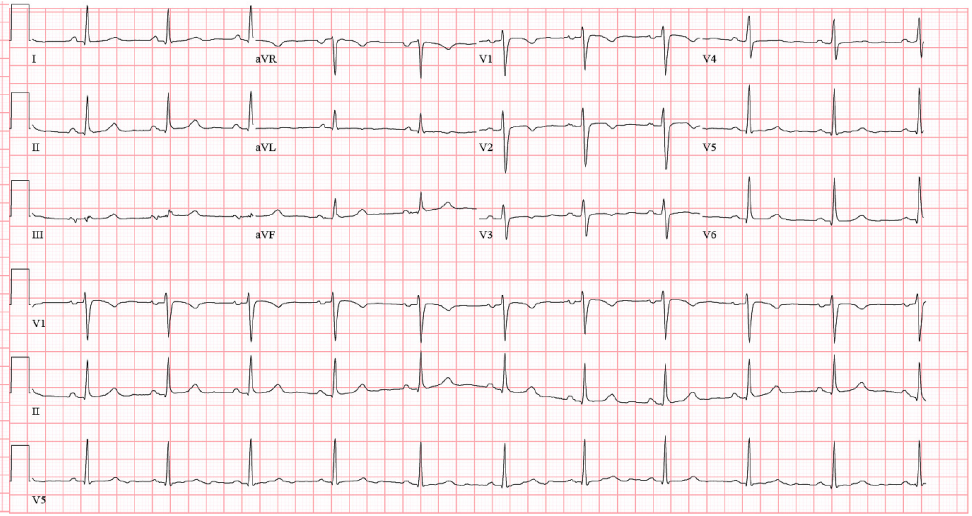

Wide QRS complexes

- IVCD, RBBB, LBBB, Aberrancy
- Ventricular ectopic
- WPW
- Ventricular pacing

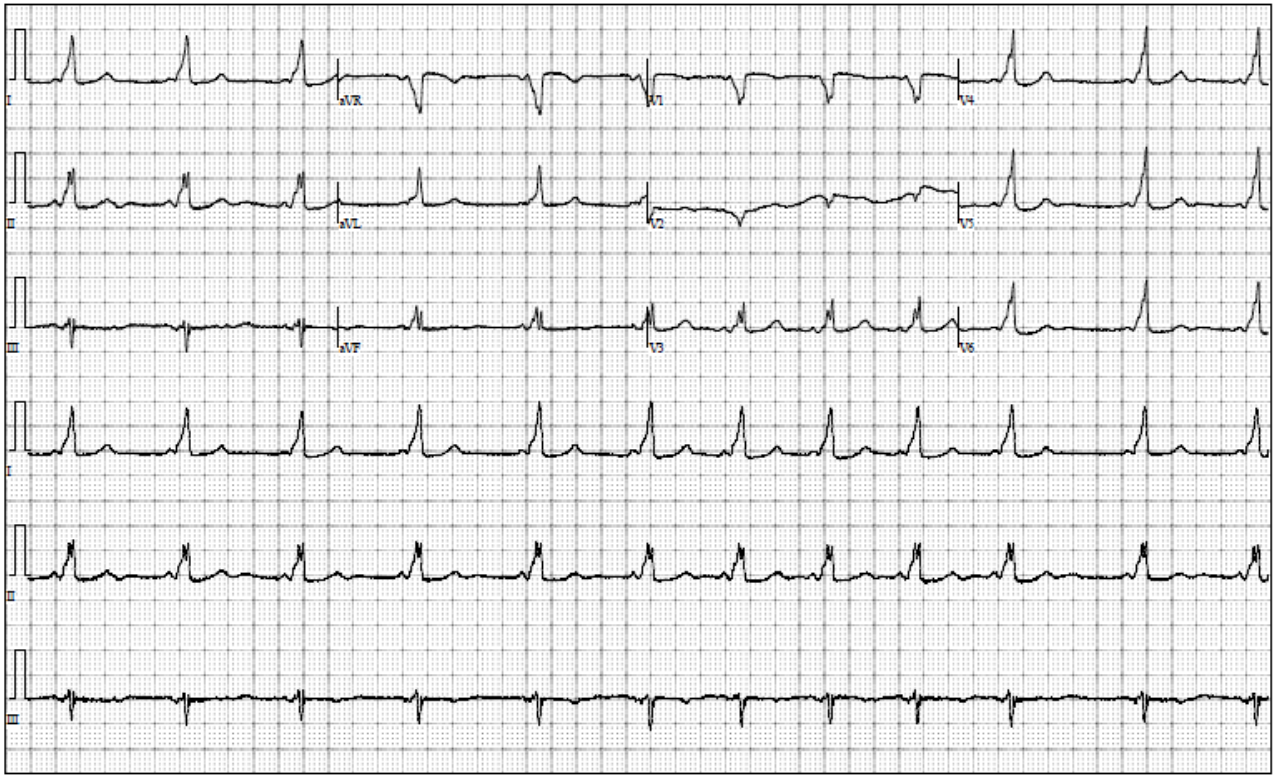
I
aVR
V1
V4
II
aVL
V2
V5
III
aVF
V3
V6
I
II
III



WPW (Midseptal AP)

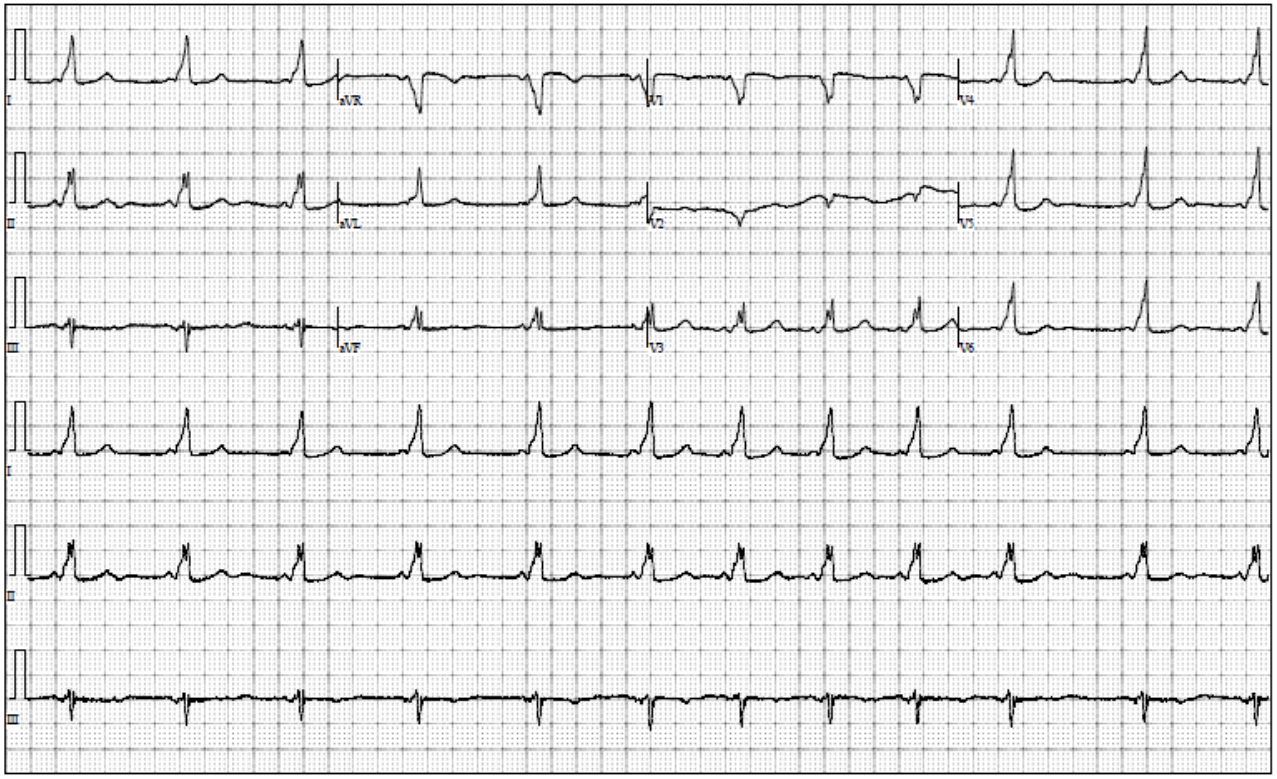



Pre and Post WPW ablation

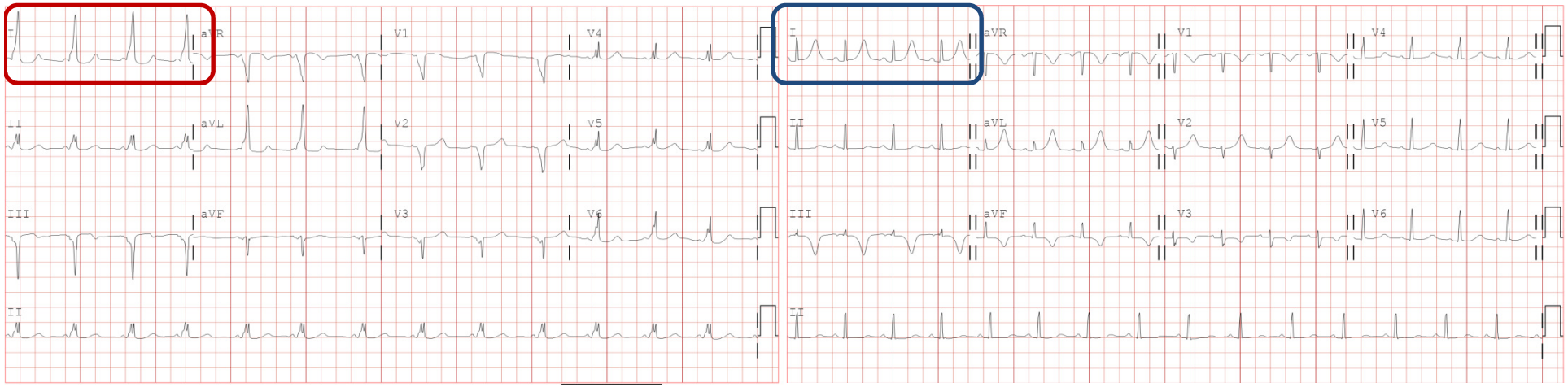

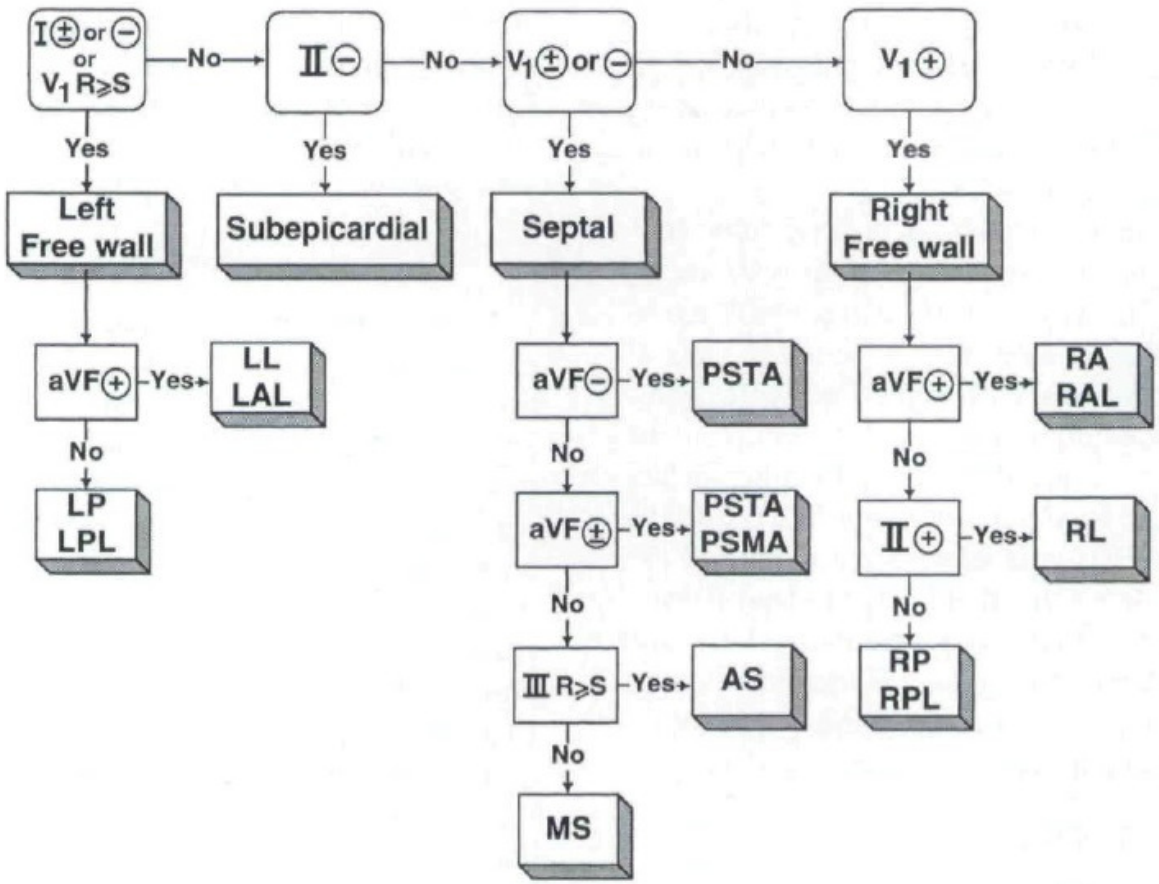
I ± or − or V1 R≥S
No
II −
No
V1 ± or −
No
V1 +
Yes
Left Free wall
Yes
Subepicardial
Yes
Septal
Yes
Right Free wall
aVF +
Yes
LL LAL
No
LP LPL
aVF −
Yes
PSTA
No
aVF ±
Yes
PSTA PSMA
No
III R≥S
Yes
AS
No
MS
aVF +
Yes
RA RAL
No
II +
Yes
RL
No
RP RPL

Wide QRS complexes

- IVCD, RBBB, LBBB, Aberrancy
- Ventricular ectopic
- WPW
- Ventricular pacing

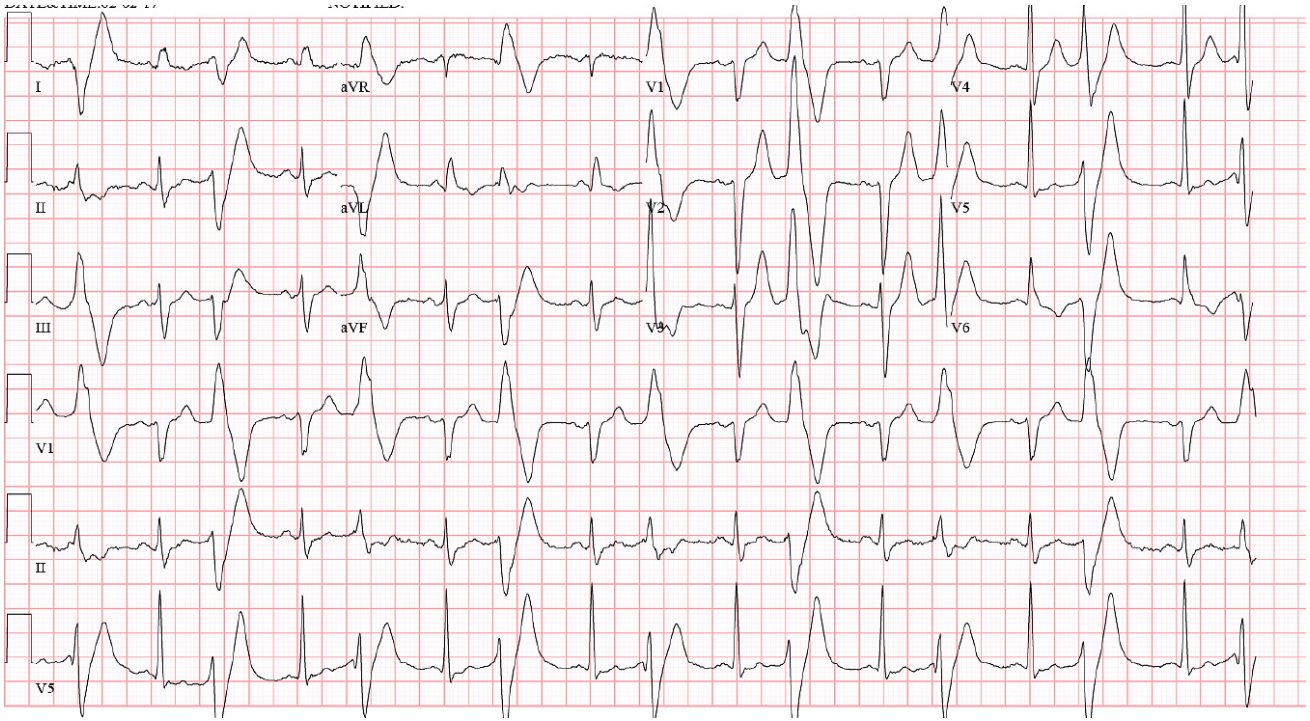
I
aVR
V1
V4
II
aVL
V2
V5
III
aVF
V3
V6
V1
II
V5

Left Anterior Papillary Muscle PVC

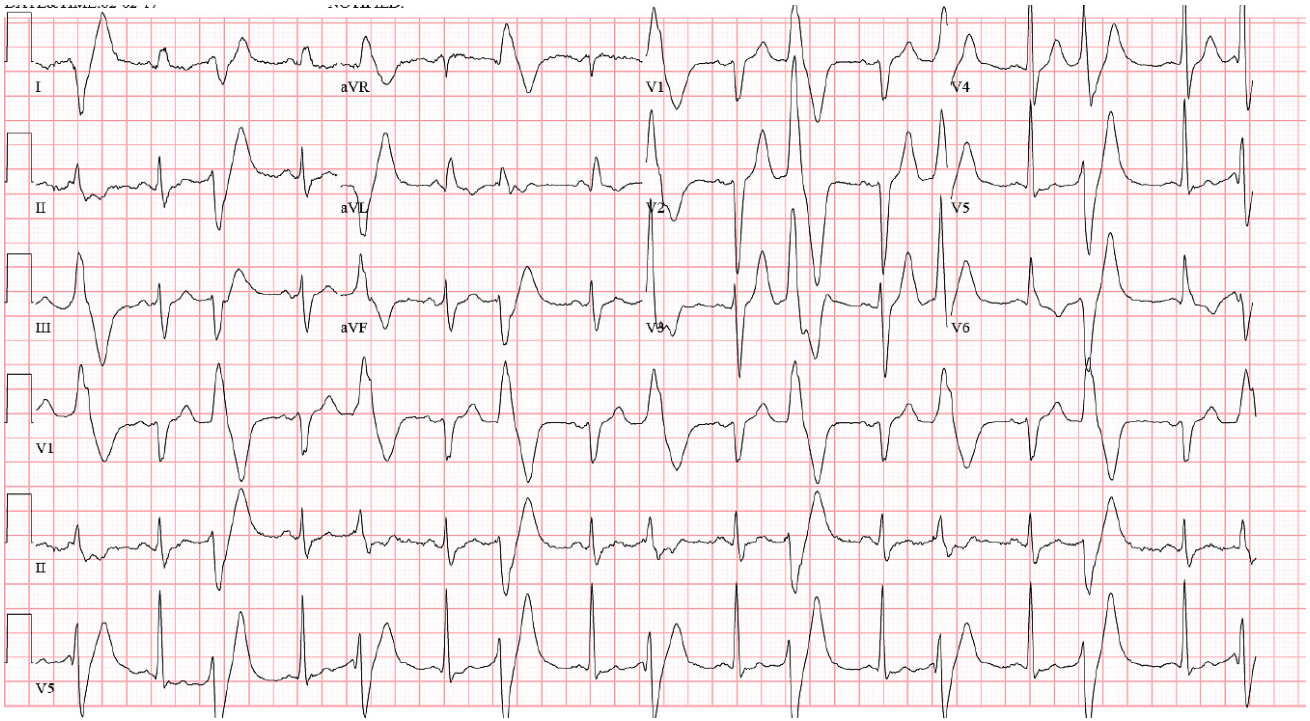

S/P PVC RFA
Left anterior papillary muscle

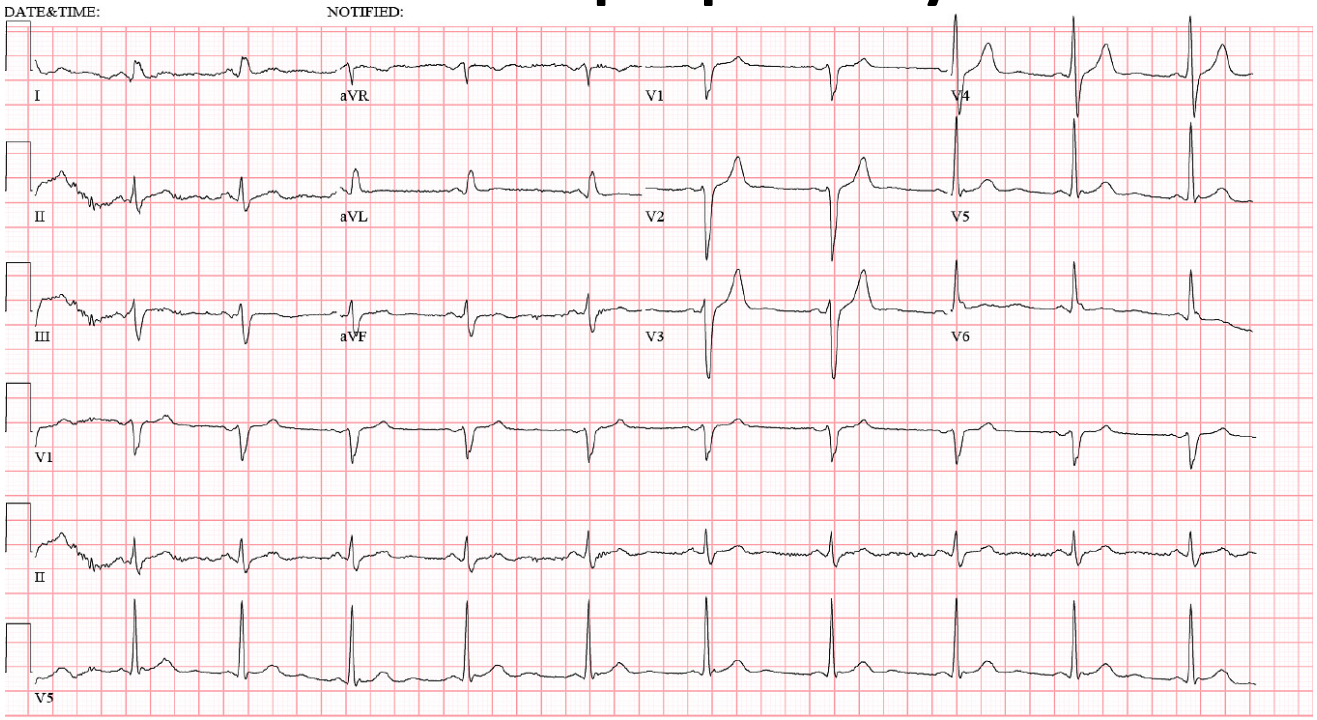

Wide QRS complexes

- IVCD, RBBB, LBBB, Aberrancy
- Ventricular ectopic
- WPW
- Ventricular pacing

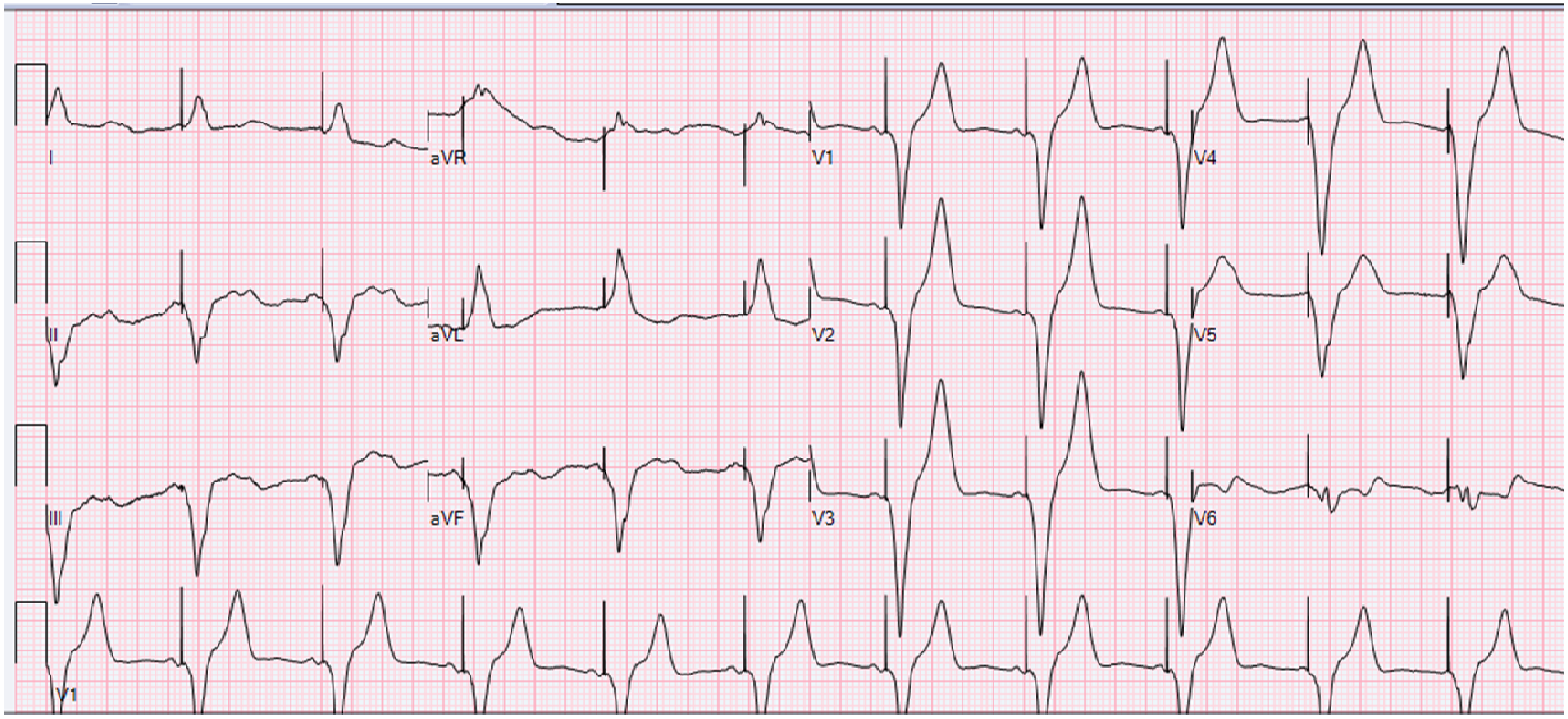
I
aVR
V1
V4
II
aVL
V2
V5
III
aVF
V3
V6
V1

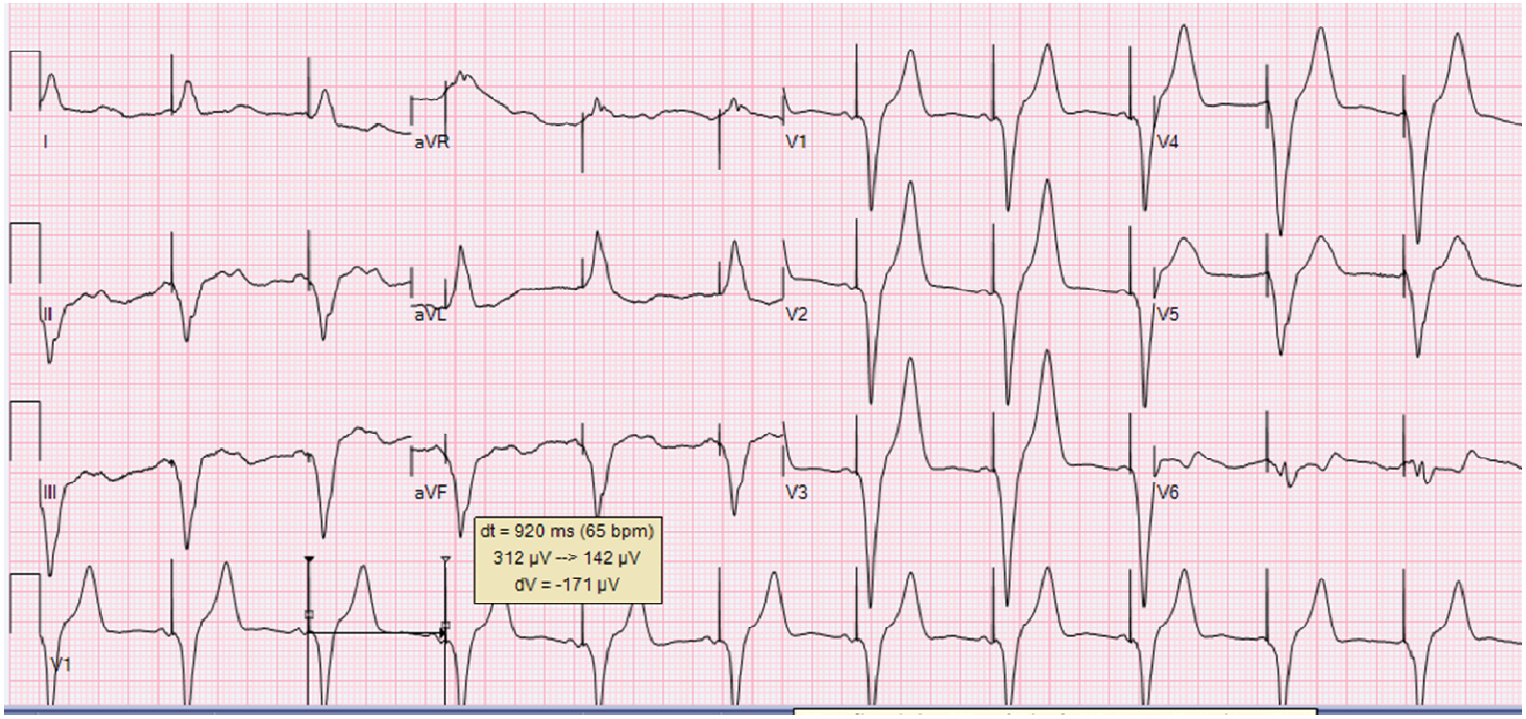
I
aVR
V1
V4
II
aVL
V2
V5
III
aVF
V3
V6
V1
dt = 920 ms (65 bpm)
312 µV --> 142 µV
dV = -171 µV

MDT PPM at ERI VVI 65

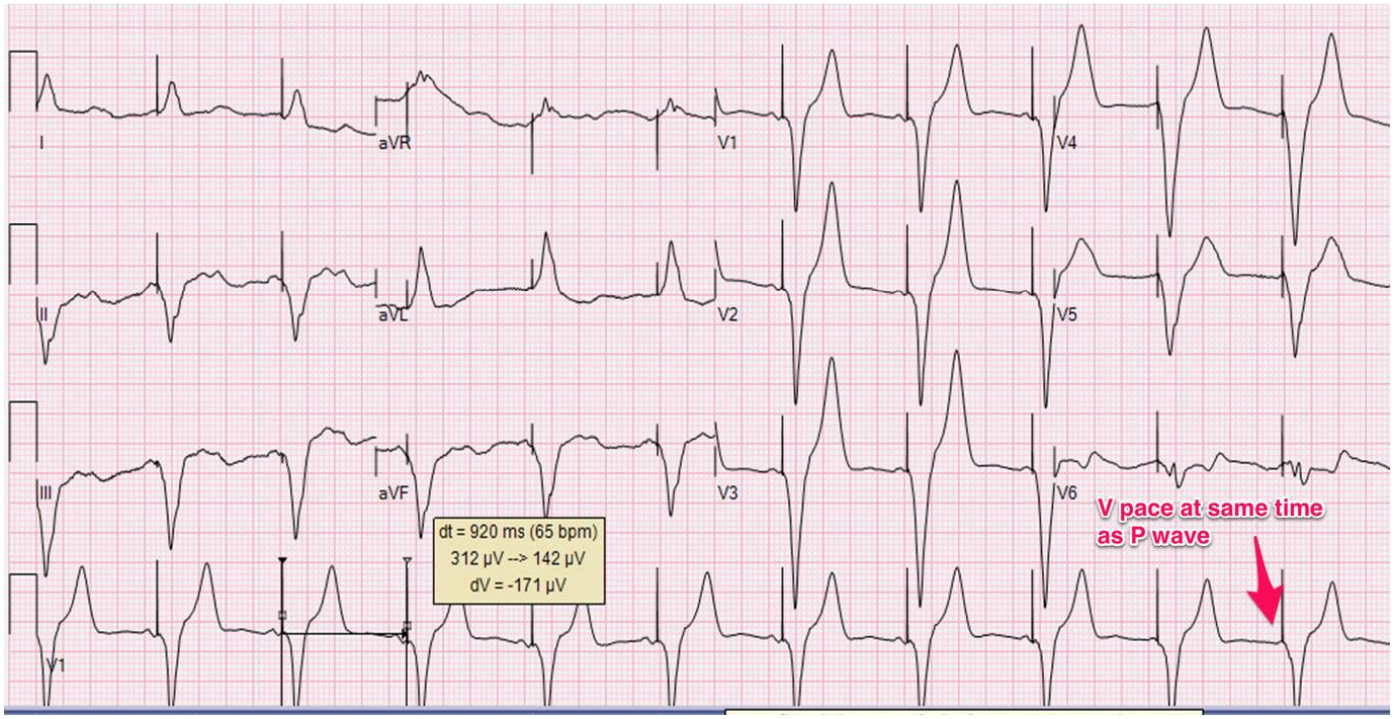

Pearls

- Pauses: Sx; SR ≥3sec; AF ≥5sec; Trigger
- PPM for syncope with LBBB
- Ablation for WPW

gard@oklahomaheart.com

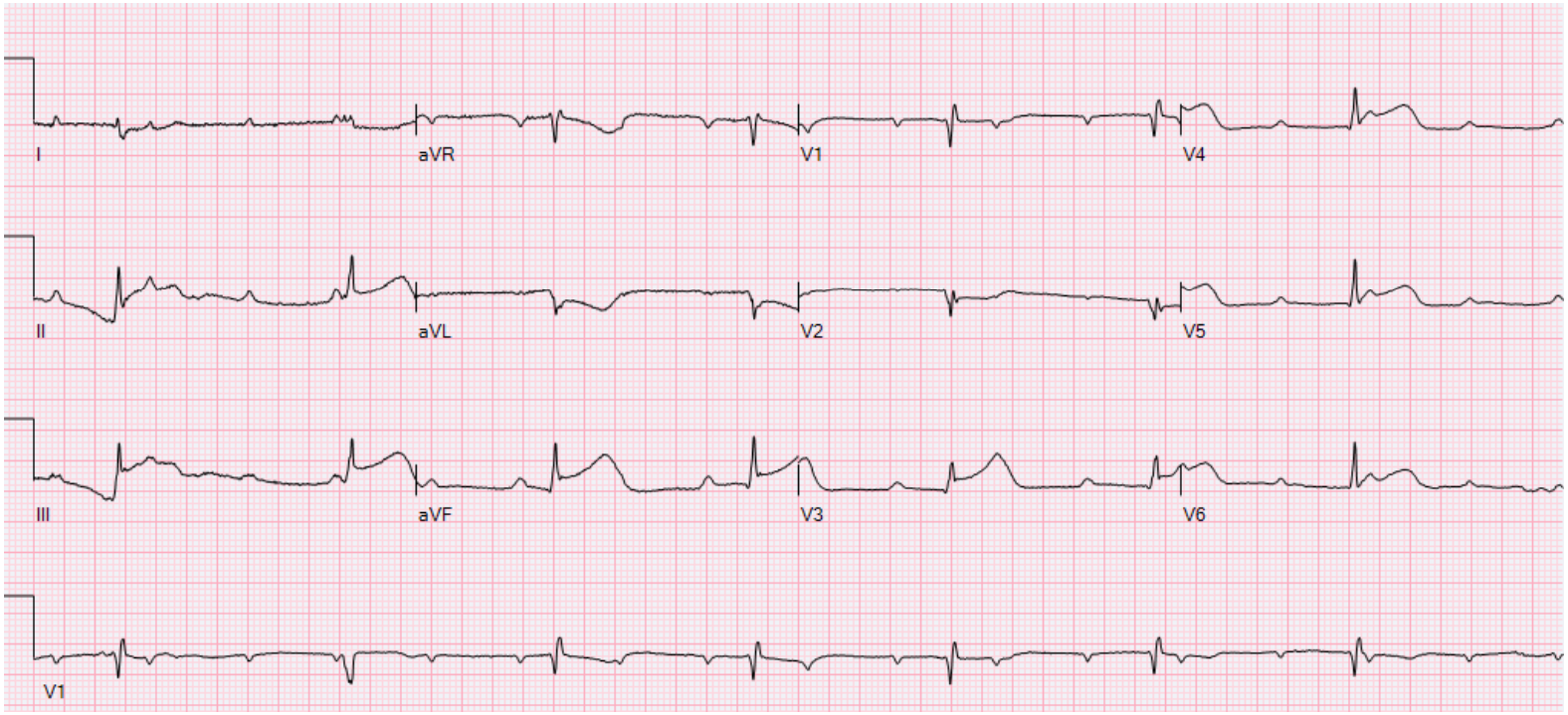
I
aVR
V1
V4
II
aVL
V2
V5
III
aVF
V3
V6
V1

Inferior MI with CHB

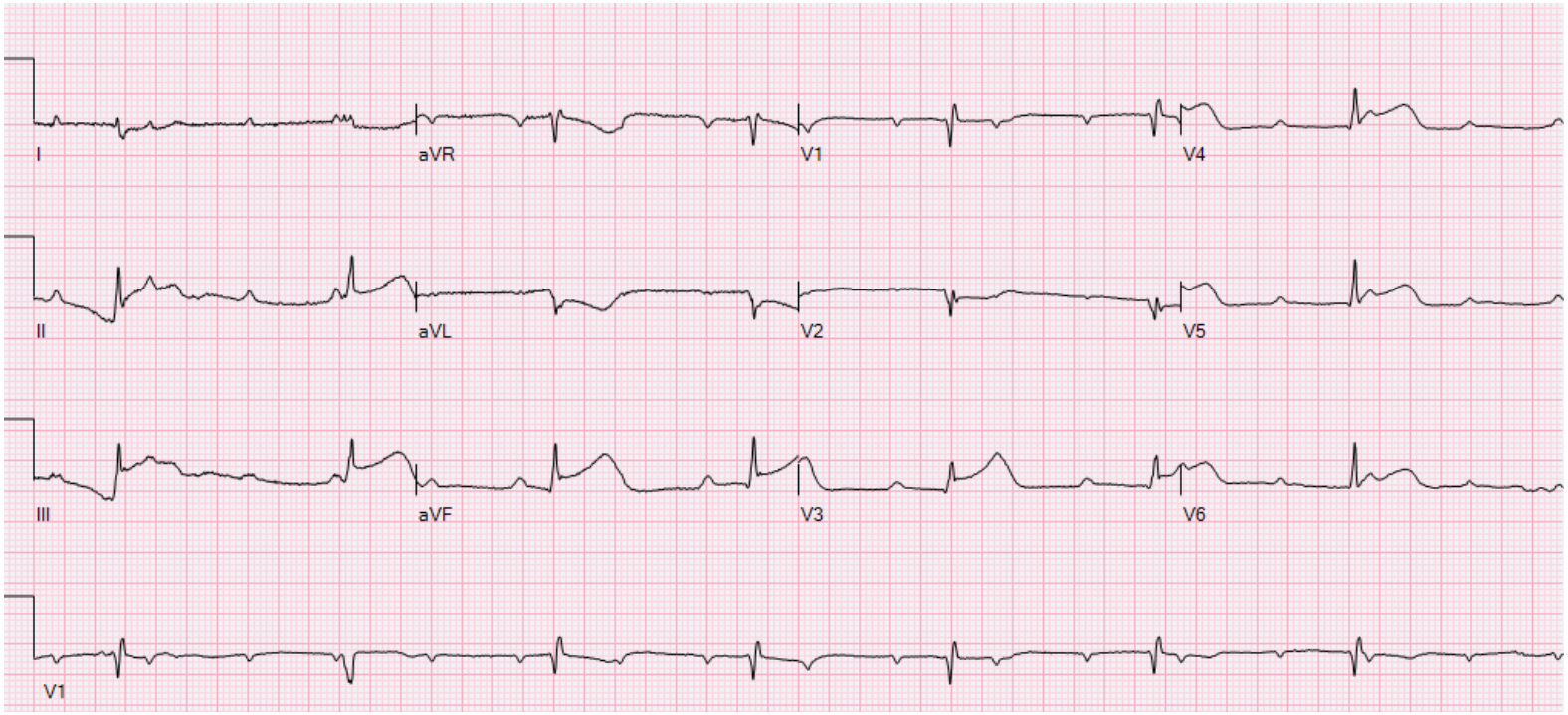

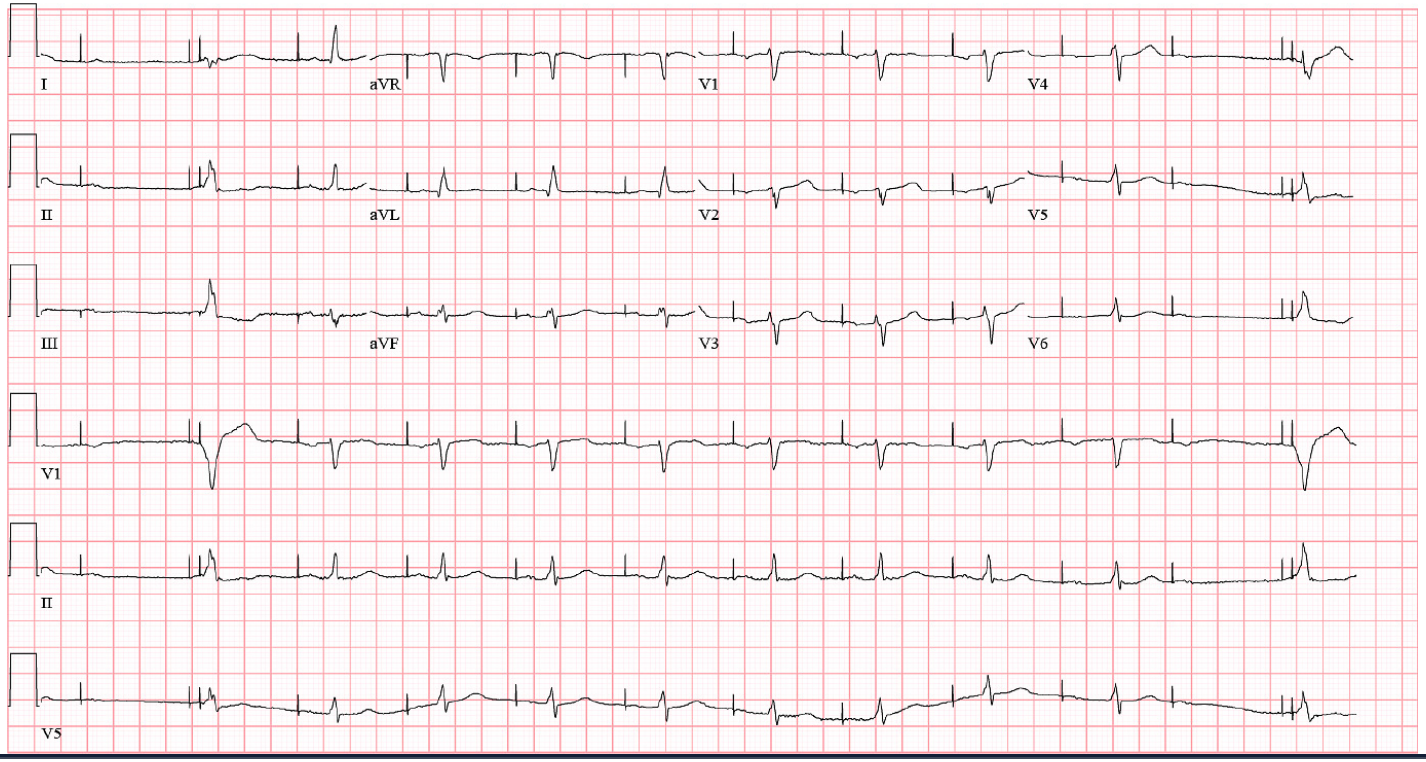
I
aVR
V1
V4
II
aVL
V2
V5
III
aVF
V3
V6
V1
II
V5

AV nodal Wenckebach with MVP

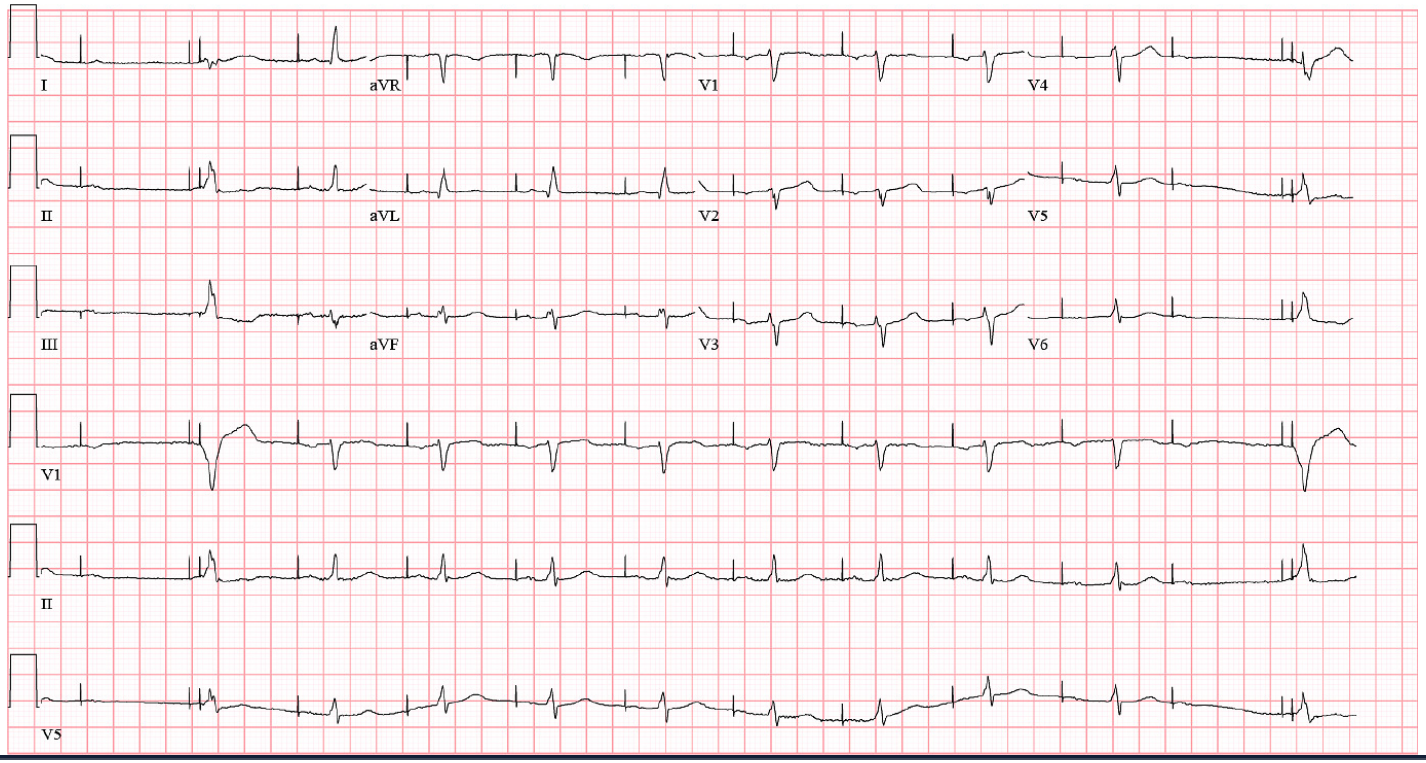

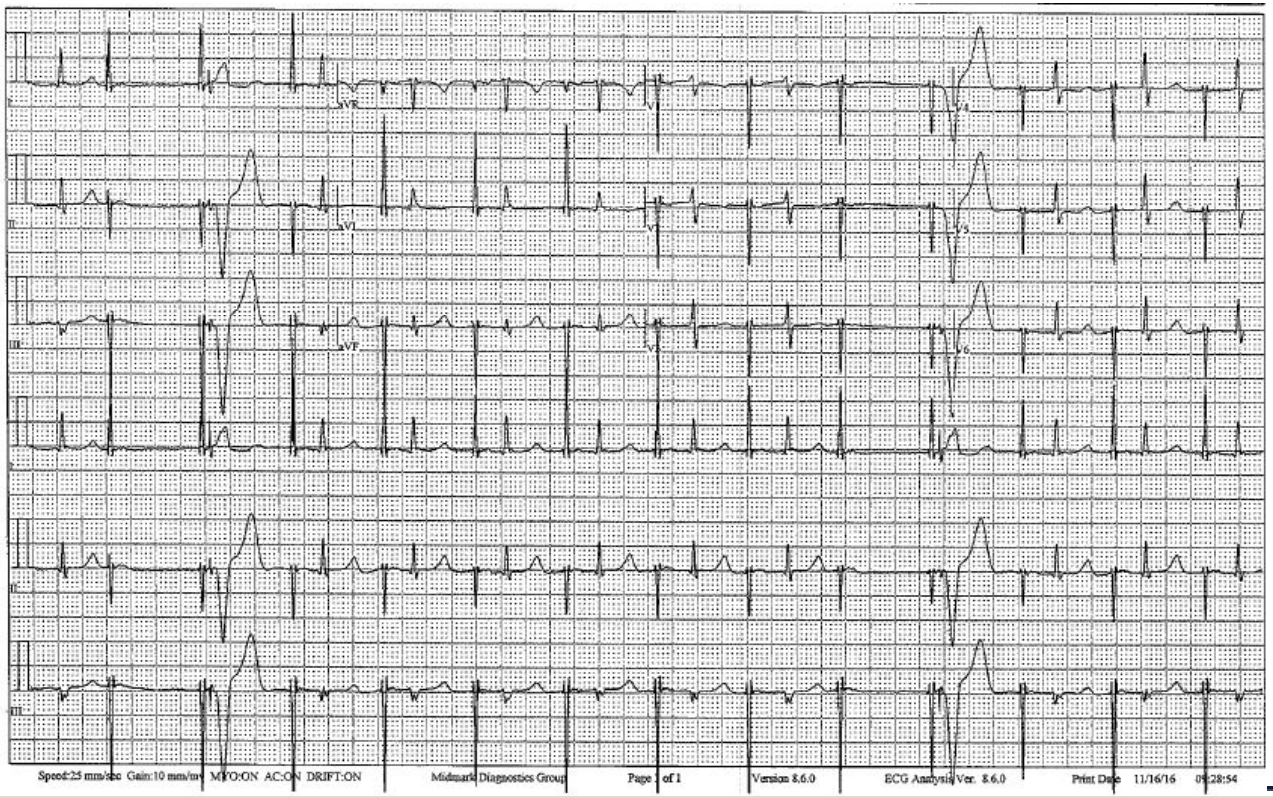
aVR
V1
V4
aVL
V2
V5
aVF
V3
V6
Speed:25 mm/sec Gain:10 mm/mv MFO:ON AC:ON DRIFT:ON
Midmark Diagnostics Group
Page 1 of 1
Version 8.6.0
ECG Analysis Ver. 8.6.0
Print Date 11/16/16 09:28:54

Consider pacing algorithms for complex cases: Medtronic MVP

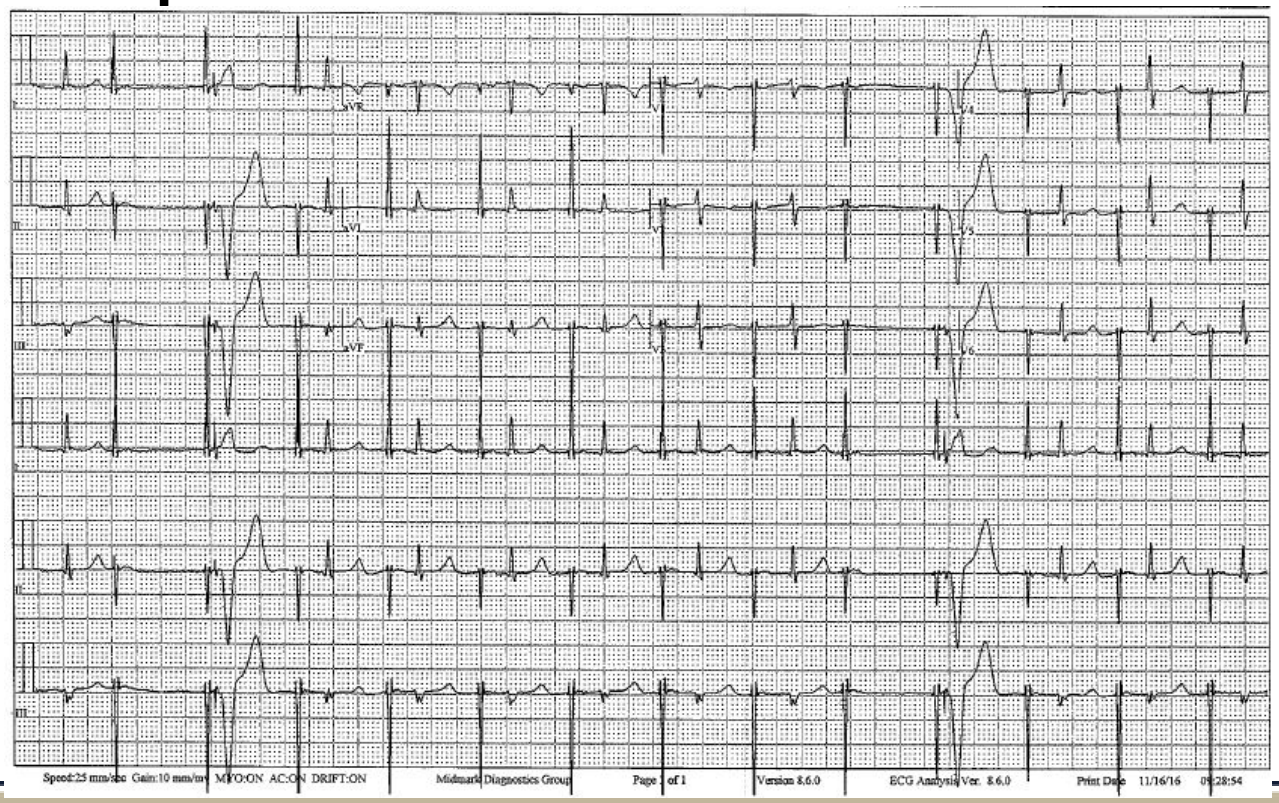

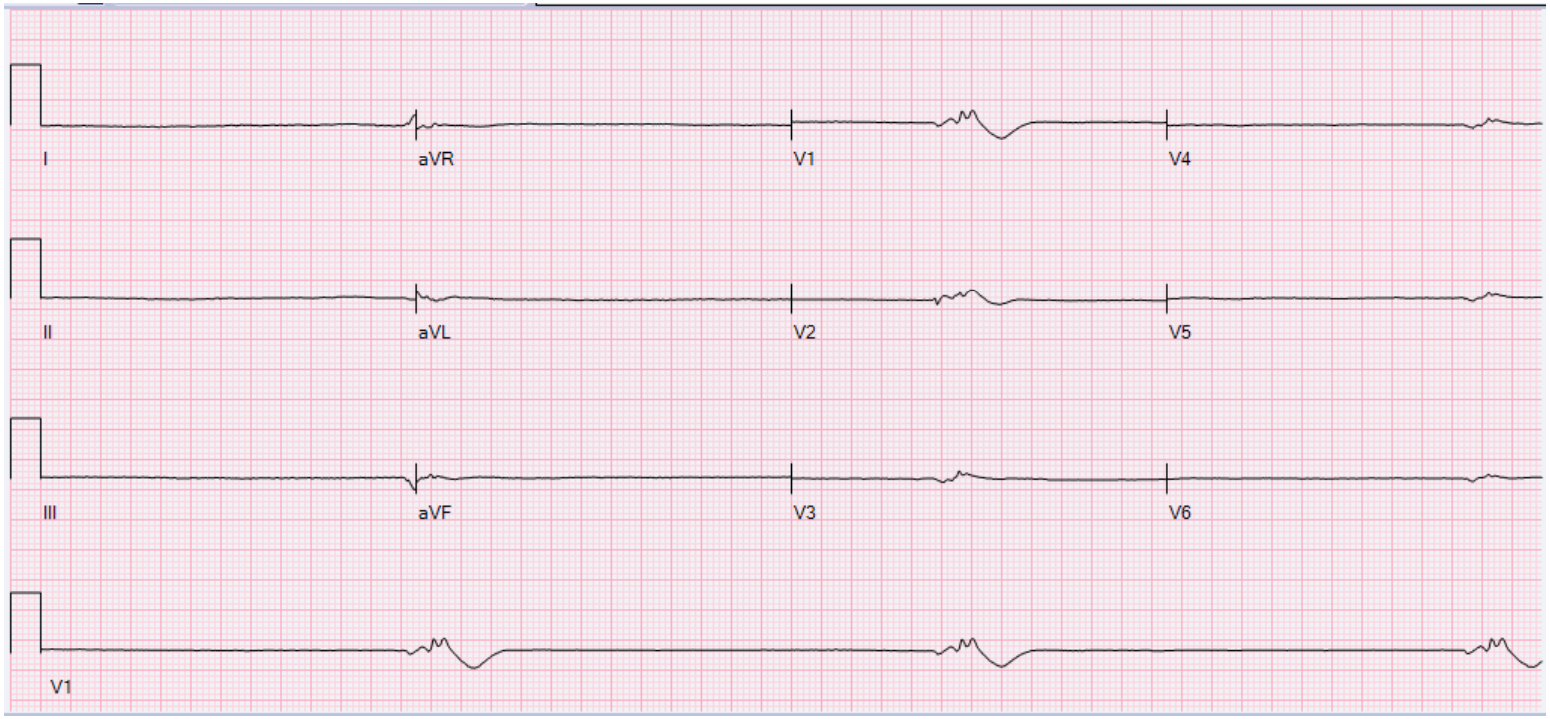
I
aVR
V1
V4
II
aVL
V2
V5
III
aVF
V3
V6
V1