

Review On Oestrosis On Sheep And Goat

Abere Dawud and *Asmamaw Aki

Regional Veterinary Diagnostic, Surveillance, Monitoring and Study Laboratory, P.O.Box:326, Asossa, Ethiopia;
email address: asmamawaki@gmail.com; Cele phone: +251902330029

Abstract: Oestrosis is form of myiasis caused by larvae of the fly *Oestrus ovis*. Myiasis is the infection of life human and vertebrate animals with dipterous larvae. *Oestrus ovis*, the sheep bot fly, is a widespread species of fly of the genus *Oestrus*. It is known for its parasitic predation and damage to sheep, deer, goat, camel, dog, and human. The aim of this manuscript is to review available literature on oestrosis in sheep and goat with its economic and zoonotic importance. *Oestrus ovis* larvae usually inhabit in the nasal cavities and sinuses of sheep and goats, and subsequently cause myiasis. This myiasis severely impairs health condition, causes difficult breathing, mouth breathing, emaciation, weight loss and sometimes, the larvae may migrate into brain causing false gid. *Oestrus ovis* is an economically important parasite of nasal cavities in sheep and goats worldwide include Ethiopia with occurrence of 94.6% and 75.10 % in central Oromia and Debre Zeit, central Ethiopia respectively. The adult fly is grayish brown and ~12 mm long. The female deposits larvae in and about the nostrils of sheep. These small, clear-white larvae (initially <2 mm long) enter to the nasal cavity and develop. When mature, the larvae leave the nasal passages, drop to the ground, burrow down a few inches, and pupate. The pupal period lasts 3–9 week, depending on the environmental conditions, after which the fly emerges from the pupal case and pushes its way to the surface. Mating soon occurs, and the female begins to deposit larvae. Ivermectin is effective against all stages of *Oestrus ovis*. Control of nasal bot can be done by application of insecticide and treatment with Ivermectin. This disease has Zoonotic importance in addition of its high economic loss but the disease mostly neglected and physician not well informed about disease. Its economic loss also not well understood especially in Ethiopia so, more research should be done with objective of zoonosis and economic importance.

[Abere Dawud and Asmamaw Aki. **Review On Oestrosis On Sheep And Goat.** *Biomedicine and Nursing* 2018;4(4): 46-56]. ISSN 2379-8211 (print); ISSN 2379-8203 (online). <http://www.nbmedicine.org>. 8. doi:[10.7537/marsbnj040418.08](https://doi.org/10.7537/marsbnj040418.08).

Keywords: Oestrusovis, Fly, Sheep, Goat

1. Introduction

Africa has a population of 205 million sheep and 174 million goats representing approximately 17% and 31% of the world total, respectively. Within Africa, the distribution of small ruminants varies widely, with a higher concentration found in dry areas than in humid areas (Ezana, 2008). In Ethiopia approximately 30 million small ruminants are present (Basaznew, 2007). Disease causes extensive financial wastes as a result of direct and indirect economic losses, because disease is the major concern to small ruminant's industry (Ezana, 2008). In the arid and semi-arid extensive grazing areas in the eastern, western and southern lowlands cattle, sheep, goats, and camels are managed in migratory pastoral production systems (CSA, 2015).

Myiasis is the infection of live human and vertebrate animals with dipterous larvae. Three main fly families are responsible for causing myiasis are Oestroidae (botflies), Calliphoridae (flesh flies) and Sarcophagiadae (flesh flies). Oestrosis is the form myiasis caused by larvae of Species: *Oestrus ovis*. Under Genus: *Oestrus* Family: Oestridae, order Diptera. Class: *Insect*, Phylum: Arthropoda. Infestation of sheep with the larvae of the nasal botfly, *Oestrus ovis*, has been recognized since early times,

the first case was recorded in Australia in 1906. Although there is considerable controversy about its pathogenic significance (some regard it as benign) but many others hold that the wellbeing of infested animal may profoundly be affected. *Oestrus ovis* its larvae are well known as myiasis producing agents. The fly is small grey green with black spots on the thorax, and covered with short brown hairs. *Oestrus ovis* achieving world-wide distribution by being spreaded throughout the world via sheep exportation it is widely spread in the tropics throughout the year especially in the hot season (Widad, 2010).

A female fly deposits young larvae around the nostrils of sheep or goats. When the eggs hatch the larvae, armed with two hooks on the anterior end crawl up the nostrils feeding on the nasal mucosa and enter the sinuses where they grow. After 1-10 months, they pass through second stage of development and migrate to become mature in the frontal sinuses and finally they are sneezed out. The larvae, yellow white in colour, drop to the ground, then burrow into the soil. Pupation takes place during 3-9 weeks after which the young fly emerges (Alahmed, 2004).

Infestation of the nasal bot (*Oestrus ovis*) in sheep and goats causes great irritation to the host

animal. The irritation is usually milder in goats than in sheep. Once the grubs gain a hold in the host, the irritation can cause the animal to shake its head, rub its nose, sneeze violently, and stomp its feet. Airflow may decrease and the animal may develop rhinitis. If the host is affected by generations of bots, it may develop hypersensitivity and produce excessive clinical signs. Sometimes the sheep or goat will develop secondary interstitial pneumonia. Rarely, a bot will migrate into the sheep or goat's brain (false gid), causing ataxia (incoordination) and Sometimes the larvae are discovered during dehorning. Death has even occurred in severe cases. Extensive nasal discharge, without the signs of pneumonia, is a good indication of nasal bot infestation (Bruna *et al.*, 2012).

Oestrosis in small ruminants causes widespread morbidity and sometimes mortality which in turn results in heavy economic losses to sheep and goat rearers. Public health significance of *O. ovis* infestation cannot be undermined as it is associated with human population, when bots are deposited on the aberrant sites causing catarrhal conjunctivitis, corneal opacity, visual impairment (ophthalmo-

myiasis) and even stomatitis in different regions of the world (Nitika *et al.*, 2014).

Treatment with Ivermectin 1% at dose rate of 0.2mg/kg bodyweight is effective. After treatment, the prognosis is good unless nervous signs are observed (Ali *et al.*, 2013). In addition of treatment control of oestrosis done by Application of insecticide in the environment of the target livestock where they are kept using organophosphorus or organochlorine compounds usually in a spray formulation, SIT and continuous moving from grazing area to another are also important control methods (Widad, 2010).

Even if the disease has high occurrence with economic and zoonotic importance in most country there is paucity of well documented information specifically in Ethiopia which deals with the economic and zoonotic importance of the disease and most of people neglected and not well aware about the disease so, the objective of this seminar paper is to review available literature on oestrosis in sheep and goat with its economic and zoonotic importance in the world.

2. Literature Review

2.1. Etiology




Figure 1: *Oestrus ovis* larvae, dorsal and ventral view

Source: (Widad, 2010).

Nasal myiasis or oestrosis is primarily a disease of sheep (but rarely in goats, camel, deer, dog and

man) caused by the infestation of nasal cavities by the larvae of botfly *Oestrus ovis* (Nitika *et al.*, 2014).

Oestrosis is a worldwide myiasis caused by larvae of the fly, *Oestrus ovis* which are obligatory parasites of the nasal and sinus cavities of sheep and goats. (Bruna *et al.*, 2012) *O. ovis* also affect human which causes ophthalmomyiasis by first-stage larvae in different parts of the world (Uslu and Dik, 2006). *Oestrus ovis* the sheep nasal bot, is a cosmopolitan myiasis producing fly whose larvae are well-recognized parasites in the nasal cavities and adjoining sinuses of sheep and goats. The first instar larvae (L1) are usually localized in the septum and turbinate while L2 and L3 are present in the ethmoidal area and sinuses (Basaznew, 2007).

Oestrus ovis has worldwide distribution and is associated with a severe parasitosis of small ruminants, with emphasis especially in the Mediterranean areas of Europe and Africa. The development of larvae in the nasal - sinus cavities can lead to severe clinical signs that together with the irritation caused by the adult fly may result into serious economic loose (Anane and Hssine, 2010). Furthermore, *O. ovis* infestation may be considered a zoonosis and have Classify in such like Phylum: Arthropoda, Class: Insect, order: Diptera, Family: Oestridae, Sub family: Oestrinae, Genus: Oestrus, Species: *Oestrus ovis*. The adult fly is small grey green with black spots on the thorax, and covered with short brown hairs. The larvae are broadly cylindrical or barrel-shaped, narrowing at their extremities when they are mature but never taper anteriorly. The body - wall is very tough with lateral swelling and a group of spinules in twelve segments are present. The first two are much reduced and annular see in figure 1 (Widad, 2010).

2.2. Epidemiology

Oestrus ovis is an economically important parasite of nasal cavities and the adjoining sinuses in sheep and goats worldwide (Fana *et al.*, 2009). Factor, such as the climatic conditions of each region, size of sheep flock and management, which can result in a variable occurrence, as demonstrated by numerous revisions conducted in slaughterhouses in different countries Among the climatic factors influencing the oestrid fly activity, temperature, light intensity, and wind are recognized as the most important, but in the case of *O. ovis*, it has been reported that temperature is the main factor in determining fly activity (Cepeda and scholl, 2000). During all years of the study, averages of maximum temperatures were between 20.8 °C and 29.8 °C. It was demonstrated that 20 °C was the minimum temperature for fly activity, while optimum temperature appears to range between 26 and 28 °C (Bruna *et al.*, 2012).

The overall occurrence of oestrosis in the sheep, in some other revisions conducted in various regions of the world with different climates, from

Mediterranean countries (Morocco, Tunisia, Spain, Greece etc.), in the West African countries (Senegal, Nigeria), in Europe countries such as Germany and in neighboring countries to the east of Turkey (Iraq, Iran), see table 1. The table tell as the adaptation of *O. ovis* to different climatic conditions, such as Mediterranean, continental and tropical climates but the occurrence vary from region to region it may be due to different climatic condition in different part of world (Nalan *et al.*, 2016).

Table 1: The occurrence of oestrosis in sheep in different part of the country

Country	Occurrence in %
Turkey	40.3
South France	43.4
Spain	46.03
Iran	49.7
Mexico	30.6
Greece	48.6
Iraq	20.96
Germen	50
Jordan	58
Senegal	95
Morocco	62.2
Central Oromia (Ethiopia)	94.6
Tunisia	93.6

Source: (Nalan *et al.*, 2016)

2.2.1. Risk factor

Animal risk factor

It is significant that goats appear to be more resistant to *O. ovis* infection than sheep and display less evident clinical signs. Because the clinical signs are more evident and parasite burden is higher in sheep than in goats. Variations in clinical sign among sheep all so observed that may be due to variation in genetic resistance and susceptibility exist in sheep (Angulo-Valadez *et al.*, 2008). In addition, genetic or antigenic variations in *O. ovis* larvae may influence clinical manifestations in their hosts (C. E. Angulo *et al.*, 2011).

Unlike in goats, high larval burden was obtained in older sheep and the difference between age groups is significant. In addition, sheep started to accumulate higher larval burden as early as March while in goats this occurred late in July. This signifies the absence of age-based resistance in sheep and that goats may develop resistance to subsequent re-infections during fly activity seasons (Yilma and Genet, 2000).

Environmental risk factor

Among the climatic factors influencing the oestrid fly activity, temperature, light intensity, and wind are recognized as the most important, but in the case of *O. ovis*, it has been reported that temperature is the main factor in determining fly activity (Cepeda

and scholl, 2000). Averages of maximum temperatures were between 20.8 °C and 29.8 °C. It was demonstrated that 20 °C was the minimum temperature for fly activity, while optimum temperature appears to range between 26 and 28 °C (Bruna *et al.*, 2012).

Pathogen risk factor

Oestrus ovis can thrive in different environments and can overwinter in a diapauses state, as larvae in the sinu-nasal passages of the host (Gunalan, 2011).

2.3. Life cycle

Like other flies, the sheep bot fly has four stages: egg, larva, pupa, and adult. Because the egg stage hatches within the female fly, it is not seen (John and Michael, 1992). The adult sheep bot fly which has a bee-like appearance is grey fly and about 10-12mm long; with small black spots on the abdomen and a covering of short brown hairs. The head is broad with small eyes. The segment of the antennae is small. The mouthparts are reduced to small knobs and non-functional and do not feed. The larvae are broadly cylindrical or barrel-shaped, narrowing at their extremities when they are mature. The body-wall is very tough with lateral swelling and a group of spinules in twelve segments are present. The first two are much reduced and annular thus larvae, in close contact with mucosa, play an essential role in accumulating nutrients for the free stages of the life cycle (Widad, 2010). The females are short lived, about two weeks, but during this time each can deposit up to 500 larvae (L1) in the nasal passages of sheep and goats Adult females do not lay eggs directly on the host. Instead, fertile eggs hatch within the female fly, and she deposits up to 25 newly hatched larvae at a time in the nostrils of the host during flight (first stage larvae). Larvae pass through three stages or instars: first (L1), second (L2) and third (L3) instars, of increasing size (Basaznew, 2007).



Figure 2: Early larval instars on nasal mucosa
Source: (Bruna *et al.*, 2012).

The female fly is viviparous and deposits larvae in or around the nostrils of its host; these early first instars attach to the mucous membrane inside the nasal cavities see figure 2, change to second instars, and move up to the sinuses where they develop into mature third instars, which are expelled by pupation in the soil. The duration of this parasitic portion of the life cycle varies considerably: from a few weeks to several months, depending on the season and climatic conditions (Bruna *et al.*, 2012).

The timing of the sheep bot fly life cycle is dependent upon climate. In areas where winters are moderate, adult flies are active during all months, and larvae continue to develop within the host during this winter. In areas, where they have very cooled winter adult flies are active only during the summer and early fall. In late fall and winter, first instar larvae are either in a suspended state of development or are growing slowly. In the warm days of summer, larval development time may require only 25 to 35 days. Larvae that overwinter, however, may require up to 10 months completing their development. The duration of the pupal stage varies between one and two months depending on weather conditions (John and Michael, 1992).

Temperatures below 10°C reduce the occurrence of the infection since adult flies are susceptible to low temperatures. Under these conditions, the larval stages may enter a hypobiotic state, arresting its development in the host. This mechanism is essential for the survival of the parasite until the arrival of the favorable period for the development of adults (Alejandro *et al.*, 2015). The larvae are obligatory parasites of nasal and sinus cavities of sheep and goats. The female are larviparous, depositing a number of first-instar larvae on the edge, or just inside the nostrils of sheep and goats. The peculiar feature of the *O. ovis* female is that it may larviposit while still in flight (Gunalan *et al.*, 2011).

2.3.1. Morphology

Pupae and adults

As with other oestridae flies, adults do not feed, they depend on the reserves accumulated as larvae to pupate, to enclose, to search for their specific mating site, to mate, to develop the infective larvae inside the females' uterus, and finally deposit their larva in or on nose of sheep. When they are fully developed, third stage larvae are expelled from the nasal cavities, begin pupation and wait for the right conditions, especially accumulated temperature, for adult eclosion. The lowest temperatures for the development of the *Oestrus ovis* flies are 12.1 °C for males and 11.5 °C for females. This indicated that the duration of pupation was variable. The pupa is 15-16mm, black, weakly wrinkled (Guillaume, 2001).

An extended pupation time is an efficient way to avoid the emergence of adults during adverse climatic conditions. This phenomenon may be considered as an external hypobiotic period. It may be assumed that when the percentages of each of the three instars found in nasal cavities are similar, the development of *O. ovis* takes place and several generations are produced during that period demonstrated there is no seasonal cycle if the three stages are present all throughout the year in favorable environmental conditions. If there is a limited favorable period during the year, some stages delay development in order to wait for the optimal season for breeding (Alahmed, 2004).

First stage larvae

They are spindle in shape 1-3mm long with relatively large cephaloskeleton. They are provided with strongly bent sclerites (gently curved mouth-hooks) and 22-25 terminal spines arranged in two groups. This enables this larva to be separated from that of the first instars of *R. purpurcus* which causes temporary myiasis especially ocular myiasis in humans. The third segment contains a row of denticles on the dorsal side. Ventrally the segments at their anterior margins show two to three rows of spine and hair like structures. Laterally, they have 22-25 hooks (Widad, 2010).

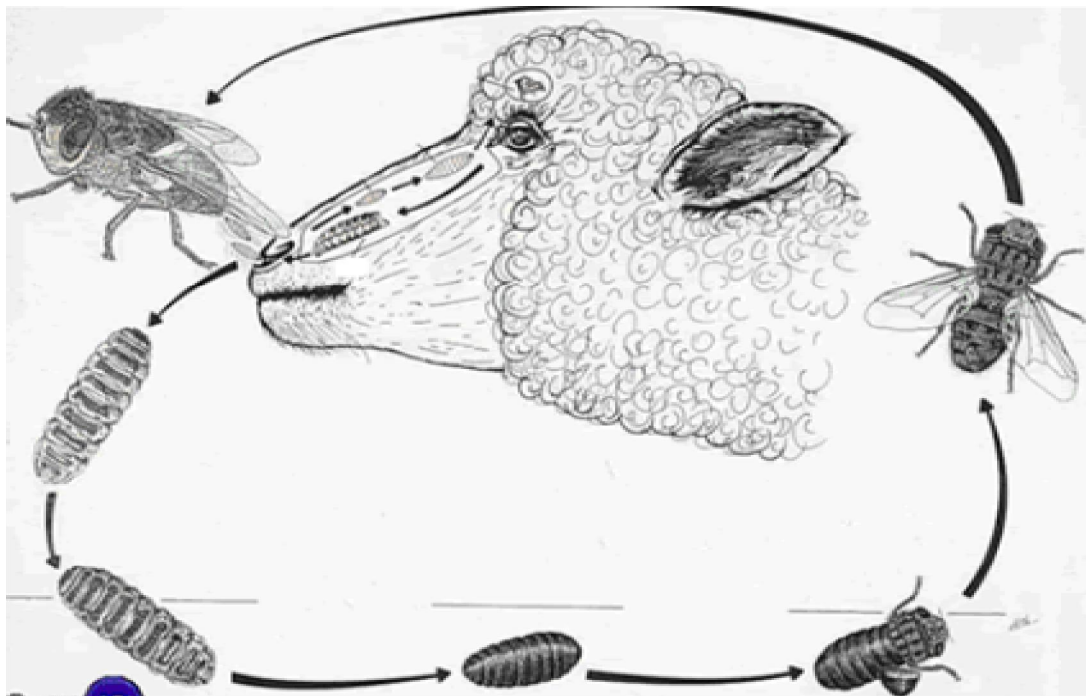


Figure 3: *Oestrus ovis* life cycle. Immature 3rd instar larva, Mature 3rd instar larva, Pupa in the ground, Adult fly emerges from the pupa and Mature fly respectively in anticlockwise direction

Source: (Widad, 2010).

Second stage larvae

There is limited information about second stage larvae. These L2 quickly develop in the sinuses of the host have 3.5-12mm length and induce a strong cellular reaction in this location with many mast cells and eosinophils. Their development is relative to L3 development and their subsequent elimination to the outside (Guillaume, 2001).

Third stage larvae

The third instar larvae are very similar to one another and are separable only by a feature showing a certain variability, the third stage larvae is 20-25mm long, white or yellowish in colour when it is young but changes with light to brown, then showing broad transverse blackish band dorsally after maturity. The

second segment is provided with a number of small denticles and the following segment with a rough leather-like skin pattern, the segment shows strong transverse rows of spines ventrally which are irregularly placed on the third segment, the post anal bulge shows less spines, the posterior peritremes are circular and without suture. The posterior spiracles are exposed, flat, D-shaped plates with the button enclosed with numerous small openings (Widad, 2010).

2.4. Pathogenesis

O. ovis females deposit their larvae in nostrils during the hotter periods of the day, which is a cause of stress in itself, due to the irritating action of the adult flies. Rafael *et al* (2014). The pathogenesis of *O.*

ovis infection is induced by spines on the larval cuticle and oral hooks, and biomolecules (enzymes and antigens) excreted or secreted by the larvae onto the mucosa (Dorchies *et al.*, 2006). The larvae migrate inside the host with the aid of their ventral cuticle spines and oral hooks, which cause mechanical mucosal irritation, and sometimes hereby leading to inflammation and production of mucous exudates, which makes it difficult for animals to breathe and possibly opens the way to secondary infections (Rafael *et al.*, 2014).

The importance of these structures is critical in first-instar larvae, the cuticle spines of which are numerous compared with those on L2 and L3. These spines and oral hooks allow for larval attachment, permit quick L1 displacement on the nasal mucosa and contribute to the rhinitis process. By contrast, L2 and L3 larvae lose their dorsal spines, indicating that spine-facilitated traits are not important for either the developing stages or for pathogenesis. The severity of lesions observed in the ethmoid bone and sinus is, partially a consequence of the strong trophic activity of L2, but mainly of L3 larvae (Angulo-Valadez *et al.*, 2009).

The biomolecules excreted/secreted by the larvae and those in the larval salivary gland comprise a complex array of enzymes necessary to degrade mucus and plasma proteins for larval feeding and nutrition (Angulo-Valadez *et al.*, 2007). Thus, when larval development increases, not only does protein production in excreted/secreted products increase, but proteolytic activity is augmented. Therefore, pathogenesis is amplified in the ethmoid and sinus mucosae when L2 and L3 are present. Specifically, larval enzymes (mainly serine proteases) are able to degrade Type I (extracellular matrix) and Type IV (basal blade) collagens, mucins, albumin and immunoglobulins. In this regard, microhistological studies have characterized ultrastructural pathology changes caused by *O. ovis*. This infection induces hyperplasia and metaplasia in the epithelium confirming an increase in the number of epithelial cells in the nasal and sinus cavities in infected sheep to twice the number found in non-infected sheep (C. E. Angulo *et al.*, 2011).

Infection occurs due to deposition of eggs by adult fly in the nostrils of the host. Infestation of *O. ovis* is usually not life threatening, but occasionally there is bacterial infection that causes encephalitis and death of the host. Secondary infections often lead to mucopurulent discharge, respiratory distress and sneezing fits in the affected animals (Urquhart *et al.*, 2003). Nervous form of *O. ovis* infestation in sheep and goats is quite infrequent. Rarely, these larvae penetrate into ethmoid bones and reach cranial cavity resulting in abnormal neurological signs such as a

high-stepping gait, in coordination and occasional death. The present documentation reports rare cases of aberrant infestation of goat brain with migrating *O. ovis* larvae resulting in sudden onset of episodes of neurological signs and fatal parasitic encephalomyelitis (Nitika *et al.*, 2014). There was a high correlation between the number of larvae and the macroscopic lesions observed in these animals' nasal cavities, such that sheep with more than 3 larvae may contain mucopurulent secretions or epistaxis (Siveira, 2015).

2.5. Clinical Sign

Clinical sign, depending on the infected area and larvae numbers (Ali *et al.*, 2013). Infestation of the nasal bot (*Oestrus ovis*) in sheep and goats causes great irritation to the host animal. The irritation is usually milder in goats than in sheep. Until the larvae begin to grow, there are no clinical signs unless the sheep or goat develops a secondary bacterial infection and/or sinusitis (inflammation of the sinus). Once the grubs gain a hold in the host, the irritation can cause the animal to shake its head, rub its nose, sneeze violently, and stomp its feet. Airflow may decrease and the animal may develop rhinitis (inflammation of the membranes in the nose). If the host is affected by generations of bots, it may develop hypersensitivity and produce excessive clinical signs. Sometimes the sheep or goat will develop secondary interstitial pneumonia. Rarely, a bot will migrate into the sheep or goat's brain (false gid), causing ataxia and sometimes death has even occurred in severe cases (Bruna *et al.*, 2012).

The *O. ovis* larvae elicit clinical signs of cavity myiasis as a seromucous or purulent nasal discharge, frequent sneezing, in coordination and dyspnea. This infection can result in serious economic losses in sheep and goat herds reared for meat and dairy produce. The development of larvae in the nasal-sinus cavities can cause severe clinical signs such as breathing difficulties, nasal discharge and emaciation, together with the annoyance caused by the adult flies. This may lead to production and economic losses (Dorchies *et al.*, 2006). *Oestrus ovis* can severely impair breathing because it induces tenacious nasal discharge to which grass, straw and dust adhere, clogging the air passages. Moreover, the infection may be complicated by sinusal tumor and lung abscesses (Gunalan *et al.*, 2011).

When the larvae are present in large numbers, a very severe cold like symptoms, purulent and sometimes bloody nasal discharge occurs. In addition, sneezing, head shaking, and difficulty breathing are among the visible symptoms. Heavier infestations may even result in death. When the adult flies attempt to deposit their larvae on the sheep and goats, the sheep and the goats take a defensive position by pressing

their noses on each other's wool or the soil see figure 4 thus also preventing themselves from grazing freely (B. Karatepe *et al.*, 2014).

2.6. Necropsy Finding

Gross pathological lesions associated with *O. ovis*, aresinusitis, rhinitis, catarrhal discharges, purulent exudates, pharyngitis, and bloody exudates were detected as gross pathological lesions. (Fana *et al.*, 2009). *O. ovis* larvae of different developmental stages in the nasal cavity and frontal sinuses can be observed (Basaznew, 2007).

2.7. Diagnosis

Oestrus ovis can diagnosis by clinically, hematological, and post mortem finding of the larva as well as by treatment in together help examined exactly. In clinical examination, clinical signs such as sneezing, serosanguinous nasal discharge, hyperemic nasal mucosa, depression circling, head pressing, aimless wandering, compulsive walking, blindness, and ataxia were observed. Vital signs including temperature, heart, and respiratory rates were normal. Sometimes the larvae are discovered during dehorning. Extensive nasal discharge, without the signs of pneumonia, is also a good indication of nasal bot infestation (Bruna *et al.*, 2012).

Hematological examination including RBC, PCV, and total and differentiated WBC was also in normal range. In necropsy, the larvae were found in nasal passage, frontal sinuses, and brain and the nasal mucosa was hyperemic. The herd was treated with Ivermectin 1% at dose rate of 0.2mg/kg bodyweight. After treatment, all patients without nervous sings were recovered. Patients with nervous signs did not respond to treatment, but new cases of disease did not occur (Ali *et al.*, 2013), in addition of the above the following method to diagnose oestrosis.

2.7.1. Serological diagnosis

The Hemagglutination Test (HAT) is one of the diagnostic tests but its sensitivity is less than 44%. Enzyme-Linked Immunosorbent Assay (ELISA) is more frequently used for the diagnosis of oestrosis. Its marked sensitivity enables to detect specific antibodies in the blood. (Basaznew, 2007).

2.7.2. Necropsy

The final diagnosis could be achieved by post-mortem examination on sheep and goats heads to detect *O. ovis* larvae of different developmental stages in the nasal cavity and frontal sinuses (Basaznew, 2007).

Differential diagnosis: Other conditions that should be considered and may resemble to Oestrosis are Listeriosis, coenuruses, verminous pneumonia, scrapie, and other respiratory disease should be consider.

2.8. Treatment

If the infestation is minor, many sheep and goat owners ignore the condition. However, when it interferes with feed consumption or the general health of the animal, treatment is necessary. Closantel at rate of 7.5 mg/Kg BW, macrocyclic lactones such as ivermectin at rate of 0.2 mg/Kg BW, Trichlorphon at the rate of 52-70 mg /kg BW and rafoxanide are effective in controlling the build-up of heavy infestations and for the removal of overwintering larvae of *O. ovis* However, treatment is not effective once the larvae migrate and reach the aberrant locations like the cranial cavity. Ivermectin is highly effective against all stages of *Oestrus ovis*, we can administer ivermectin oral or subcutaneously at the standard dose of 0.9 mg/10 lbs, except to animals producing milk for human consumption (Dorchies *et al.*, 2001).

In trials, therapeutic efficacies for the closantel, subcutaneous ivermectin injection and oral ivermectin treatments were 100, 100 and 98% respectively. The development of resistance against anthelmintics must always be considered in the treatment of *oestrus ovis* remembering that the drugs effective against nasal worm are also used to treat roundworms. Farmers often treat their livestock during the early fly activity period in about October (spring infestation) and again in March. There will be seasonal variation where treatment may also be required over mid-summer. Rams should be dosed prior to mating (Nitika *et al.*, 2014).

2.9. Control and Prevention

Prevention and control of oestrosis assumes greater significance owing to its public health significance and association of goat owners from economically and socially weaker sections of the world society (Nitika *et al.*, 2014). Control of the sheep bot fly is difficult because of minimum clinical sign observed in early infection, the location of the parasite in the host and the ability to adapt in different environment allows the natural persistence of infestation and the difficulties for its control (Gunalan *et al.*, 2011).

Currently, the most effective method is the use of an approved parasiticide on the larvae. The favored time for treatment is during late fall or early winters after one or more killing frosts have eliminated the adult flies. At that time larvae harbored by sheep are predominately first instars and are found mostly on the nasal mucous membranes. Sheep bots can be controlled if all sheep in any given area are treated annually with effective parasiticide. An oral drench of parasiticide has been shown to be an effective application method. See the label instructions to ensure proper dosage and administration. Cultural strategies to reduce the impact of this pest have not been developed nor have effective biological controls

been identified. The use of systematic treatments during the fly activity period and the beginning of the hypobiotic period were found to be efficient in *O. ovis* control (John and Michael, 1992).

SIT (sterile insect technique), significant numbers of artificially reared sterilized male flies were introduced in the field to compete with wild males for females in order to copulate and cause the females to lay batches of unfertilized eggs which cannot develop into larval stages. Application of wood tar to the nostrils of sheep, it acts as insects' repellent. Application must be repeated weekly. Repellent applied to the muzzles of the sheep are usually less effective because their effect does not last long on the hot sunny days when the flies are active. Because the life cycle of the fly is relatively short, continuous moving from grazing area to another is a very important way of prevention. This all method can help to control *oestrous ovis* infection (Widad, 2010).

2.10. Economic Importance

The parasitic relation which is induced with dipteran true fly larvae including feeding on ingested food, body materials and living/dead tissues of their hosts has been defined as myiasis disease (Ogbalu *et al.*, 2014). The pathogenic effects cause significantly reduced animal production and serious economical losses, which have been estimated at 1.1 - 4.6 kg of meat, 200 - 500 g of wool and up to 10 % milk per animal (Nalan *et al.*, 2016).

Oestrosis in small ruminants causes widespread morbidity and sometimes mortality which in turn results in heavy economic losses to sheep and goat rearers (Pathak, 1992). Public health significance of *O. ovis* infestation cannot be undermined as it is associated with human population, when bots are deposited on the aberrant sites causing catarrhal conjunctivitis, corneal opacity, visual impairment (ophthalmo-myiasis) and even stomatitis in different regions of the world (Nitika *et al.*, 2014). The larva of the sheep bot fly, *Oestrus ovis* is a parasite that lives on mucous surfaces of the nasal passages and sinuses of sheep and goats. It has been estimated that sheep bot fly larvae cause a 4 percent decrease in weight gain. Drummond in 1981 estimated annual losses in sheep production in the United States due to sheep bot fly to be \$13.5 mil per year (John and Michael, 1992).

The presence of the fly with its distinctive buzzing can alert mature animals, who may attempt to run away, walk with their noses near the ground or have been recorded forming a circle with their noses in the middle and near the ground. If the fly successfully places eggs in the nostril of sheep the animal may feel the larvae after a few days and attempt to remove them by tapping their muzzles on the ground. They will also snort and stamp their front feet in annoyance Once the larvae have infested the nasal passage and sinuses,

usually up to 15 larvae but can be up to 80, they cause irritation to the mucosa, which causes mucous discharge swelling of the internal membranes of the nose, possibly impairment of breathing but largely discomfort and distraction to the sheep who may reduce or stop grazing and subsequently lose weight and condition. This can in some cases lead to malnutrition and death Sometimes mature larvae care unable to escape from the nasal sinus and die. This may then lead to a septic sinusitis affecting the animal's condition and the possibility of death from general septicemia (Yilma and Genet, 2000).

2.11. Zoonotic Importance

Myiasis is the infestation of tissues and organs of animals or man by dipteran fly larvae. The most common site of infestation is the skin wound. Less common sites are eyes, nose, paranasal sinuses, throat, and urogenital tract. Myiasis appears to be fairly common but underestimated in many rural areas. In some areas of Fars Province in South of Iran, myiasis does occur in warm seasons. Ophthalmic myiasis is due to deposition of fly larvae in the human eye. Various species of flies are able to provoke ophthalmomyiasis, including *Oestrus ovis*, latrine fly (*Fannia*), house fly (*Muscadomestica*), and cattle botfly (*Hypoderma*). *Oestrus ovis* is by far the most common cause of ophthalmic myiasis in man (Mohsen and Keramatalah 2004).

Oestrosis can have Public health significance in addition to heavy economic losses to sheep and goat producer. *O. ovis* infestation cannot be undermined as it is associated with human population, when bots are deposited on the aberrant sites causing catarrhal conjunctivitis, corneal opacity, visual impairment (ophthalmo-myiasis) and even stomatitis in different regions of the world (Nitika *et al.*, 2014).

Globally, the most common cause of human ophthalmomyiasis is the sheep botfly *Oestrus ovis*. Humans become exposed when they are handling these animals and are contaminated with their odour. Adult *Oestrus ovis* flies typically incubate eggs internally until they hatch, then deposit, larvae on human corneal or conjunctival tissue (Homer *et al.*, 2016). Humans are accidental hosts. However, the tiny larvae do not develop any further in human eye beyond the first larval instar (Naima *et al.*, 2014). Farmers, sheep herds, or those living in rural areas are most at risk, but infection may also occur in urban dwellers. Other risk factors include advanced age, debilitation, ocular wounds and infections and poor general health (Homer *et al.*, 2016).

Ophthalmomyiasis, also known as ocular myiasis, is the infestation of the eye or periorbital tissue by larvae of the insect order Diptera. When larvae remain outside the eye it is called ophthalmomyiasis externa, while penetration of the eye

is termed ophthalmomyiasis interna. The latter is caused by the larvae of *Dermatobia hominis*, which can cause also blindness. Many Ophthalmomyiasis externa in humans is often caused by the larvae of the sheep nasal botfly (Sody and Kosta, 2014).

Predisposing factors for ophthalmomyiasis include eye infections, ocular wounds, aging, and immunocompromised conditions (Saeed *et al.*, 2015). Myiasis causing flies are generally attracted to soiled clothes, mats, mattresses, brassieres and wounds but a new source is being reported in this paper involving vulvar myiasis which occurs in the rural settings where prevailing unhygienic conditions and dirty habits promote myiasis-causing agents' infection. In some cases, promiscuous lifestyles have contributed to vulvar myiasis (Agbalu *et al.*, 2014).

External ophthalmomyiasis usually has an acute presentation and patients have ocular surface complaints such as tearing, itching, foreign body sensation, hyperemia, lid swelling, and chemosis. Extensive larval infestation of a compromised external eye results in the total destruction of orbital contents. Therefore, timely diagnosis and treatment of these patients are important for preventing the complication (Saeed *et al.*, 2015).

Misdiagnosis is common, with attribution of the acute conjunctivitis to other causes. Slit lamp examination is crucial for picking up the larvae. Treatment is centered on timely removal of the larva from the eye to prevent consequent inflammation and other sequelae. The topical anesthesia helps in extraction process by immobilizing the eye and decreasing patients' reactions. Systematic antiparasitic prescription is not needed; the mechanical removal of the larvae using forceps, a cotton bud extraction or saline irrigation is effective. The prescription of corticosteroids or nonsteroidal anti-inflammatory drugs and topical antibiotics are recommended to relieve the pain and inflammation and to prevent secondary bacterial infections respectively (Carrillo *et al.*, 2013); (Anane and Hssine 2010). Though prognosis is good, threatening complications with retinal detachment and pan uveitis have been reported. These may be avoided through prompt diagnosis and early treatment, which is possible only if proper slit lamp examination is performed (Naima *et al.*, 2014). For cases in which the larva cannot be isolated or removed, successful treatment with oral Ivermectin and corticosteroids has been reported (Homer *et al.*, 2016).

2.12. Status in Ethiopia

High occurrence of *O. ovis* infection (75.10 %) occurs in sheep and goat flocks in Debre Zeit area, central Ethiopia, suggesting the importance and endemicity of the disease in the region (Yilma and

Genet, 2000). *O. ovis* is also common and important parasite of sheep and goats in central Oromia. A very high overall occurrence of 88.4% in goats and 94.6% in sheep was recorded (Fana *et al.*, 2009).

Agitation of sheep and goat flocks by larvipositing female flies, especially during high fly activity seasons, and following infestation, the subsequent sneezing and copious secretion of mucus from the nostrils adversely affect feeding activities. Reported losses range from 1.1 - 4.6 kg of meat, 200-500 g of wool and up to 10 % of milk yield. It has also been demonstrated that weight gains of lambs improve in the absence of *O. ovis* infestation and mortality among animals recently introduced into endemic area (Yilma and Genet, 2000). This variation may be attributed to possible reasons like the differences in agro-ecology like altitude, moisture, and temperatures that determine the fly density, absence of treatments against this parasite, and inadequate veterinary services and variations in animal management and husbandry systems among various study areas in different studies (Fana *et al.*, 2009).

3. Conclusion And Recommendations

From above information oestrosis is form of myiasis which is caused by larvae of Species *Oestrus ovis* which common in the most country including Ethiopia but its occurrence is differing in different part of the world and in different season in same area due to the difference in climatic condition which is high in hot part and season that is characterized by shake its head, rub its nose, sneeze violently and difficult breathing. Serology, necropsy finding and clinical sign help to diagnosis oestrosis. This disease has Zoonotic importance in addition of its high economic loss but the disease mostly neglected and in human misdiagnosis as conjunctivitis its economic loss also not well understood especially in Ethiopia. So, from this conclusion the following recommendations are given; -

- Awareness should give to the people about the disease.
- Attention should give to control and prevention disease so that the productivity of sheep and goat increase and zoonotic effect also reduce.
- More research and further investigation in oestrosis should be done with the objective to determine its economic and zoonotic effect in Ethiopia.
- In addition, particular attention must be directed towards an accurate assessment of mortality and production losses due sub clinical cases of sheep nasal botflies as well as morbidity and mortality in preslaughter ages. Therefore, more studies are needed for planning for a control program for the disease.

Reference

1. Alahmed. (2004) Myiasis in sheep farm in Riyadh Region Saudi Arabia. The Egypt Soc. *Parasitol*, 34: 163-60.
2. Alejandro, H., Héctor, P., Carlos, O. and Flery, S. (2015). *Oestrus ovis* infection of grazing sheep during summer in southern Chile. *Pesq. Vet. Bras.* 35:6.
3. Ali, A.M., Saeedeh, S., Shahin, G. and Ghareh, C. (2013). High Mortality Rate due to False Gid in a Sheep Herd. *International Scholarly Research Notices*, 2013.
4. Anane, S. and Hssine, L.B. (2010). Conjunctival human myiasis by *Oestrus ovis* in southern Tunisia. *Bull Soc Pathol Exot.* 103: 299-304.
5. Angulo-Valadez, C. E, Cepeda-Palacios, R, Ascencio, F., Jacquiet, P., Dorchies and PRamirez Orduña, J.M. (2009b). Relationships of systemic Ig G antibody response and lesions caused by *Oestrus ovis* L. larvae (Diptera: Oestridae) in infected goats. *Revista Electrónica de Veterinaria*. 10: 1–13.
6. Arslan.M, O. Kara and M. Gicik. (2009). Epidemiology of *Oestrus ovis* infestation in sheep in Kars province of north-eastern Turkey. *Trop Anim Health Prod.* 41: 299–305.
7. B. Karaepe, M. Karatepe and S. Guler. (2014). Epidemiology of *Oestrus ovis* L. infestation in sheep in Nigde province, Turkey Nigde University, Bor Vocational School, Bor, Nigde/Turkey. *Revue Méd. Vét.* 165: 225-230.
8. Basazinew, B., (2007). *Studies on the Interactions between Oestrus Ovis (L1) and Haemonchus Contortus (L3) In Experimentally Infected Goats* (Doctoral Dissertation, Aau).
9. Bruna, F.S., César, C.B., Alessandro, F. and Talamini, A. (2012). Epidemiology of *Oestrus ovis* (Diptera: Oestridae) in sheep. Botucatu, State of São Paulo, Departamento de Parasitologia, Instituto de Biociências, Universidade Estadual Paulista. *Rev. Bras. Parasitol.* 22: 18-21.
10. C. E. Angulo, V.A., F. Ascencio, P. J Jacquiet, P., Dorchies, S. and R. Cepeda-palacio. (2011). Sheep and goat immune responses to nose bot infestation. *Medical and Veterinary Entomology*, 25: 117–125.
11. Carrillo, I., Zarratea, L., Suárez, M., Izquierdo, C., Garde, A. and Bengoa, A. (2013). External ophthalmomyiasis: a case series. *Int Ophthalmol.* 33: 167-169.
12. Cepeda-Palacios, R. and Scholl, P. (2000). Factors affecting the larvipositional activity of *Oestrus ovis* gravid females (Diptera: Oestridae). *Vet Parasitol.* 91: 93-105.
13. CSA. (2015): Central Statistical Authority, Federal democratic Republic of Ethiopia, Central Statistical investigatory, Statistical abstract. Addis Ababa, Ethiopia.
14. Dorchies, P., Jacquiet, P., Bergeaud, J., Duranton, C., Prévot, F., Alzieu, J. and Gossellin, J. (2001). Efficacy of doramectin injectable against *Oestrus ovis* and gastrointestinal nematodes in sheep in the southwestern region of France. *Vet. Parasitol*, 96: 147–54.
15. Ezana, G., (2008). Major diseases of export orintd livestock in export abattoirs in around Adalbenwoeda. *Faculty of veterinary medicine, Haramya Univeristy, Haramya Ethiopia*.
16. Fana, A., Bersissa, K. and Hailu, D. (2009). *Oestrus ovis* larval myiasis among sheep and goats in Central Oromia, Ethiopia. *Trop Anim Health Prod.* 42: 697–703.
17. Guillaume, T., Philippe, J., Philip, S. and Philippe, D. (2001). *Oestrus ovis* in sheep. Relative third-instar populations, risks of infection and parasitic control. *Vet. Res.* 32: 525-531.
18. Guitton. C., Dorches, P. and Morand. S. (1997). Morphological Comparison of Second Stage Larvae of *Oestrus Ovis* and *Rhinoestrus Usbekistanicus* (Oestridae) Using Scanning Elecron Microscopy. *Parasite.* 4:277–282.
19. Gunalan, S., Kamaliah, G., Wan, S., Rozita, A.R., Rugayah, M., Osman, M.A., Nabijah, D. and Shah, A., (2011). Sheep oestrosis (*Oestrus ovis*, Diptera: Oestridae) in Damara crossbred sheep. *Malays J Vet. Res.* 2: 41-49.
20. Homer, H.C., Rasanamar, K.S., Justin, B., David, J.W. and Andreas, K.L. (2016). A case of ophthalmomyiasis interna in the Pacific Northwest. *American Juornal of Optamology cases report.* 6: 11–14.
21. John, E.L. and Michael, J.B. (1992) Sheep Botfly Biology and Management. *Bulletin-Wyoming University, Cooperative Extension Service (USA)*.
22. Kettle D.S. (2000). Oestridae (Gad Flies, Worble Flies, and Stomach Bots). Medical and Veterinary Entomology. Second Edition. CABI Publication. Pp 265-266.
23. Mohsen, M. and Keramatalah, H. (2004). External Ophthalmomyiasis Caused by Botfly (*Oestrus Ovis*) Larva. *Arch Iranian Med.* 7: 136 – 139.
24. Naima, F., Kanza, N.Q., Syeda, A.B., Bushra, J. and Mohammad, A. (2014). Human ophthalmomyiasis externa caused by the sheep botfly *Oestrus ovis*. A case report from Karachi, Pakistan. *Asian Pac J Trop Biomed.* 4: 835-837.

25. Nalan, Ö., Pinar, T., Fatma, I. and Serdar, D. (2016). The prevalence of ovine oestrosis and risk factors in Eastern Turkey. Department of Parasitology, Faculty of Veterinary Medicine, Yuzuncu Yil University, Van, Turkey. *Veterinarski Arhiv*. 86: 323-333.
26. Nitika, S., Shivasharanappa, N., Rajveer, S.P., Surender, K., Waseem, A. T., Souvik, P., Anil, K. M., Kumaresan, G., Ashok, K., Vivek, K.G. and Vinay, C. (2014). Parasitic Encephalomyelitis in Goats due to Aberrant Infestation with Botfly Oestrous ovis Larvae Division of Animal Health. Central Institute for Research on goats, India. *Adv. Anim. Vet. Sci.* 2: 8 – 11.
27. Ogbalu, O. K. Orlu, E. E. Eze, C.N. And Wokem, G. (2014) Factors Associated with the Prevalence of Vulvar Myiasis Infection in Rural Nursing Mothers of The Niger Delta, Nigeria. Environmental/Medical Entomology Unit, Department of Applied and Environmental Biology, Rivers State University of Science and Technology, Nigeria. *IOSR-JPBS*.9: 81-87.
28. Pathak, K.M.L (1992). Incidence of *Oestrus ovis* in sheep and goats in Rajasthan state of India. *Indian J Anim. Sci.* 62: 50–53.
29. Rafael, S.C., Maycon, A.R., Marcos, H.A.C., Valdomiro, P., Antônio, C.M., Barbara, C.M., Breno, C.C., Willian, G.M., Gustavo, F., Weslen, F., Pires, T., Vando, E.S., Alvimar, J. and Welber Daniel Zanetti Lopes. (2014). Occurrences of *Oestrus ovis* parasitism in necropsied sheep in the Umuarama microregion, Paraná, Brazil. *Rev. Bras. Parasitol*, 24: 3.
30. Saeed, S.R., Seyedeh, F.I. and Sadeq, G. (2015). A Rare Case of Asymptomatic External Ophthalmomyiasis Manifesting with a Corneal Ulcer. *Patient Saf Qual Improv.* 4: 344-345.
31. Sardar, J.S., Amin, T., Shahram, N., Mohammad, A.B. and Saed, M.B. (2010). Seasonal infection rates of *Oestrus ovis*. Department of Clinical Sciences, School of Veterinary Medicine, Shiraz University, Shiraz, Iran. *OJVR*. 14: 302 - 310.
32. Silveira, C., Araújo, R., Alcantara, C.H., Campanha, M., Antônio, M., Barbara, C., Cayeiro, C., Giquelin, M., Willian, F., Pires, T., Weslen, F., Vando, E., Alvimar, J., Zanetti, L. And Welber, D. (2015). Occurrences of *Oestrus ovis* parasitism in necropsied sheep in the Umuarama microregion, Paraná, Brazil. *Revista Brasileira de Parasitologia Veterinária*. 24: 370-374.
33. Sody, A.N. and Kosta, Y.M. (2014). Diagnosis of ophthalmomyiasis externa by dermatoscopy. Parasitology Unit, Department of Microbiology and Molecular Genetics, the Kuvin Center for the Study of Infectious and Tropical Diseases, the Hebrew University Hadassah Medical School, Jerusalem, Israel. *Dermatol Pract Concept*. 4: 85–87.
34. Urquhart, G., Armour, J., Duncan J., Dunn, A. and Jennings FW (2003). *Vet. Parasitol.* Blackwell Science LTD, UK, pp 163–165.
35. Uslu, U. and Dik, B. (2006). Prevalence and intensity of *Oestrus ovis* in Akkaraman sheep in the Konya region of Turkey. *Medical and Veterinary Entomology*.20: 347–349.
36. Widad, A.H.O. (2010). Detection of Nasal Botfly Larvae in Slaughtered Sheeo Heads in Alselam Abattoir in Khartoum State-Sudan. Dissertation submitted to the University of Khartoum in partial fulfillment of the requirements for the Degree of Master of Tropical Animal Health (MTAH). Faculty of Veterinary Medicine University of Khartoum.
37. Yilma, J.M and Genet, A. (2000). Epidemiology of the sheep nasal bot, *Oestrus ovis* in central Ethiopia. *Revue Méd. Vét.* 151:143–150.