

## EVALUATION OF MANDIBULAR INCISIVE CANAL ANATOMY BY CONE BEAM COMPUTED TOMOGRAPHY

Anusha Avvaru<sup>1</sup>, Jyothirmai Koneru<sup>2</sup>, R.Sudhakara Reddy<sup>3</sup>, Ramesh Thatapudi<sup>4</sup>, Anand Babu Beeraboyina<sup>5</sup>, Rajesh Nallakunta<sup>6</sup>

1.MDS, Post Graduate, Vishnu Dental College, Bhimavaram, Andhra Pradesh

2.MDS, Reader, Vishnu Dental College, Bhimavaram, Andhra Pradesh

3. MDS, Professor and Head of the department, Vishnu Dental College, Bhimavaram, Andhra Pradesh

4. MDS, Professor, Vishnu Dental College, Bhimavaram, Andhra Pradesh

5. MDS, Reader, Vishnu Dental College, Bhimavaram, Andhra Pradesh

6. MDS, Assistant professor, Vishnu Dental College, Bhimavaram, Andhra Pradesh

### ABSTRACT:

**Objectives:** The study was aimed to assess the prevalence of mandibular incisive nerve canal and evaluate its average location and dimension by using cone beam computed tomography in patients attending dental institute.

**Methods:** The cone beam computed tomography scans of 50 patients were retrospectively assessed for the presence of mandibular incisive canal bilaterally. The axial, sagittal, cross-sectional and panoramic views of the scans were analyzed and the measurements were recorded using the tools given in the ON DEMAND 3D software.

**Results:** The mandibular incisive canal (MIC) was visible in 98% of CBCT images with a mean length of  $13 \pm 5.6$  mm. The mean length of the incisive canal on right and left side was  $13.4 \pm 4.6$  mm and  $14 \pm 6.4$  mm. The distance between the origin of incisive canal and buccal plate, as well as with the lingual plates were  $4.19 \pm 1.2$  mm and  $4.1 \pm 1.0$  mm, and the distance between the apex of incisive canal with buccal plate, as well as with the lingual plates were  $4.7 \pm 1.3$  mm and  $4.15 \pm 1.07$  mm.

**Conclusion:** There was high prevalence of MIC with variation in length and distance up to the cortical bone. The preoperative radiographic evaluation of the MIC with CBCT must be considered for presurgical assessment to prevent complications such as post operative bleeding and paraesthesia.

**Key words:** Cone-Beam computed tomography, anterior mandible, Mandibular incisive canal.



### INTRODUCTION:

The inferior alveolar nerve and the mental foramen are the important anatomical structures that should be taken into account during preoperative planning for surgical and implant placement in the posterior mandible.<sup>[1]</sup> Although numerous reports describe the vital anatomical structures of the posterior mandible, only few contemporary radiographic and histological studies are available about the anatomical structure of the anterior mandible. The region between the mental foramen has been considered a

safe zone for most of the surgical procedures, like insertion of endosseous implants, genioplasty during orthognathic surgery, bone harvesting from the chin and mandibular rehabilitation after trauma of the anterior region with screws and/or plates placement.<sup>[1]</sup>

Mesial to the mental foramen, the extension of the mandibular canal is referred as the mandibular incisive canal and it contains one of the terminal branches of the inferior alveolar nerve.

Several case reports describe neurosensory disturbances, edema, hematoma and failure of osseointegration of implants during or after surgical procedures in the interforaminal region of the mandible and these can be attributed to the presence of the mandibular incisive canal.<sup>[3, 4]</sup>

Cone beam computed tomography (CBCT) is considered as a useful tool for the radiographic evaluation of MIC. CBCT has been shown to improve the visibility of bony canals that cannot be clearly observed on regular panoramic or other intraoral radiograph.<sup>[5]</sup> Chen et al,<sup>[6]</sup> emphasized the effectiveness of CBCT and three-dimensional reconstruction in the identification of important anatomical structures relevant for the preoperative assessment for surgical procedures in the anterior region of the mandible.

The mandibular incisive canal has varied course, with multi-morphic representation. It may present either unilaterally or bilaterally or may be absent. Few studies stated that presence of mandibular incisive canal vary according to population. So they was a need to study in our population. The number of cases with surgical intervention in the inter-foraminal area has increased considerably<sup>[7,8,9]</sup> and failure to ascertain the exact position of the neurovascular bundle in this region may lead to complication like transient or long term paresthesia of the associated region. The present study was

conducted to assess the prevalence of mandibular incisive nerve canal and to evaluate its average location and dimension by using Cone Beam Computed Tomography.

## **MATERIALS AND METHODS:**

The retrospective study consisted of 50 CBCT examinations of the mandible taken from 50 patients who were referred for various dental procedures. Patients with any pathological abnormalities were excluded from the study design. This research was approved by the institutional ethical committee. The scans were sourced from CBCT machine SOREDEX CRANEX 3D with ON DEMAND 3D software using the following set of exposure parameters for each patient. The scans were set at 90KV and 10mA, as recommended by the manufacturer with fields of view (FOV) 61x78mm of high resolution of 300µm voxel size respectively.

The courses of the mandibular incisive canal were assessed in images reconstructed into multiple-plane views (axial, panoramic and cross-sectional views) and the images were analyzed and the measurements were done using the tools given in the ON DEMAND 3D software.

The image was first examined for the presence or absence of the canal the presence of the canal was noted to be unilateral or bilateral. The identified canals were analyzed. The nerve tracking tool was used to measure the length

from the origin to the end of the visible nerve canal (Figure-1). In particular, the measurements made were:

1. Length of the incisive canal (origin to apex)
2. Diameter of the incisive canal at its origin
3. Distance from the origin of incisive canal to base of the mandible
4. Distance from the apex of incisive canal to base of the mandible
5. Distance from the origin of incisive canal to buccal cortex of the mandible
6. Distance from the apex of incisive canal to buccal cortex of the mandible
7. Distance from the origin of incisive canal to lingual cortex of the mandible
8. Distance from the apex of incisive canal to lingual cortex of the mandible

Cross sectional image of the CBCT was used to measure the distance of the nerve canal (both at the origin and the apex) to the inferior border of the mandible [Figure2]. Length of the incisive canal and also the diameter (origin to apex) [figure3, 4.] The axial plane was used to measure the length distance (both at the origin and also the apex) of the nerve to the buccal and lingual cortices, respectively [Figures 5]. The data was subjected to statistical analysis where descriptive analysis was performed. The prevalence in percentages was calculated for mandibular incisive canal (Table-1). The comparison between the mean values

was performed with the unpaired t-test for (right & left side) (table-3). All statistical assessments were considered significant if  $p < 0.05$ .

## RESULTS:

The study group consisted of 23 males and 27 females, age ranging from 40-80 years with a mean age of 54 years, 2% of the patients were edentulous.

### PREVALENCE OF MIC

The analysis of the results showed that MIC could be seen in 95 % of the cases (50 patients, 95 canals). In 92 % of the cases (46 patients) it was found bilaterally; and in 6 % (3 patients), unilaterally. In 2% of the cases (1 patient) it was absent. As shown in table 1.

The mean Diameter of the incisive canal at its origin was 1.7 mm +/- 0.51 mm. the length of incisive canal at origin to apex was  $13.7 \pm 5$  mm. The distance between the origin of incisive canal and buccal plate, as well as with the lingual plates were  $4.19 \pm 1.2$  mm and  $4.1 \pm 1.0$  mm, and the distance between the apex of incisive canal with buccal plate, as well as with the lingual plates were  $4.7 \pm 1.3$  mm and  $4.15 \pm 1.07$  mm. as shown in table 2. the mean length of incisive canal on right side and left side was  $13.4 \pm 4.6$  mm and  $14 \pm 6.4$  mm respectively. No much significant difference between the values on right and left side. Except for the distance from apex to lingual cortex.

## DISCUSSION:

Studies have reported that panoramic radiographs failed to detect the incisive canal because of super imposition of various anatomical structures in 2D image.<sup>[13,11,14,7]</sup> Hence, it is logical to assume that, the study of the interforaminal area of the mandible using CBCT becomes mandatory. In the cross-sectional images of CBCT scans, MIC appears as a round hypodense area within the Mandibular trabecular bone surrounded by a hyperdense rim representing the canal walls. As reported by Al-Ani et al<sup>[15]</sup>

The MIC was visible in all (100%) CBCT images, in a study conducted by Al-Ani et al.<sup>[15]</sup> which was similar to that of other authors have also found a high prevalence of MIC using CBCT, with a variable visibility of 83-97.5%. There was 93% visualization of MIC by Apostolakis and Brown,<sup>[16]</sup> 91% by Makis et al<sup>[1]</sup> and 93.7% by Parnia et al. [17] whereas Pires et al.<sup>[10]</sup> have found that the MIC was present in 83% CBCT images. In spiral CT scans 93% of visualization of MIC was shown by Jacobs et al<sup>[7]</sup> In CBCT scans 78.75% (63 cases) showed the presence of MIC by Huang et al. [18] In this study the prevalence of MIC using CBCT, with a variable visibility of 98 % (50 cases).

For all CBCT images examined, the mean length of the incisive canal for the right side was  $13 \pm 4.6$  mm and for the left side was  $14 \pm 6.4$ mm. Pires et al.<sup>[10]</sup> verified MIC lengths as  $7.1 \pm 4$  mm and  $6.6 \pm 3.7$  mm for the right and left side,

respectively. Another finding was that the MIC is in close proximity to the buccal plate ( $4.62 \pm 1.41$ mm) which is similar to studies conducted by Tepper G et al.<sup>[19]</sup>

Length of the incisive canal was similar to study conducted by De Andrade et al. The mean Diameter of MIC was 1.7 mm  $\pm 0.51$  mm accordance with the study reported by Huang et al.<sup>[18]</sup> The Distance of the incisive canal to the lower border of the mandible was 8.95-8.88mm as compared with 9.4– 11.15mm accordance with the study reported by De Andrade et al<sup>[24]</sup> Apostolakis and Brown and Rosa et al<sup>[16]</sup> Reported that MIC was also nearer to the buccal plate and alveolar process in its closest position. In this study the canal runs more medial course increasing its distance from the lingual cortex. Mardinger et al.<sup>[11]</sup> reported an incisive canal direction proceeding from the buccal plate towards the lingual plate. The distances between the origin of incisive canal and buccal plate, as well as between the origin of incisive canal and lingual plate were  $4.19 \pm 1.2$ mm and  $4.1 \pm 1.0$ mm, respectively. The distances between the apex of incisive canal and buccal plate, as well as between the apex of incisive canal and lingual plate were  $4.7 \pm 1.3$ mm and  $4.15 \pm 1.07$ mm, respectively.

Regarding gender there was no significant difference when comparing the proximity of the MIC to the buccal and lingual cortex. The mean values and

SD of the diameter of MIC for males and females were 1.61 mm  $\pm$  0.41 mm and 1.46 mm  $\pm$  0.35 mm, respectively. The kappa statistics indicated an overall score of 0.74 for the inter observer agreement for identification of the MICs and a somewhat lower score (0.55) for the inter observer agreement.

This study demonstrated a high degree of occurrence of MIC's identified on CBCT scans, these data are in union with other observational studies.<sup>[7,20 and 16]</sup> Our study confirmed the high reliability of CBCT in the identification of fine structures (e.g. MICs). The mean diameter of the incisive canal found in this study was 1.8mm which is similar to the study conducted by Jacobs et al.<sup>[7]</sup> Similar or only slight difference was found in the data reported by other authors. For instance, Obradovic et al.<sup>[21]</sup> found that the MIC ranged from 0.48 mm to 2.9 mm on cadaver mandibles; Pires et al.<sup>[10]</sup> observed diameters from 0.4 mm to 4.6 mm on CBCT scans; diameters of 1.0 mm to 6.6 mm on CBCT examinations were reported by Uchida et al.<sup>[22]</sup> In the present study we found

differences between the diameter of the canal on both sides and also between genders. Further studies can be conducted by taking large group of population and it can aid in forensics for the person /gender identity/variation.

## CONCLUSION:

The clinical significance of this study lies in the mapping of the incisive canal and its anatomical proximity during surgical procedures in order to avoid potential injury to the incisive mandibular nerve using CBCT, which could clearly show the three-dimensional structure and adjacent structure of the MIC. One of the most easy and relevant location for placing an implant is the anterior mandible. Clinician should be alert while operating. As anatomical variations can be diversified, causing complications. All anatomical considerations have to be visualized, analyzed in preoperative planning itself that can help in enhance quality and prevent disasters. All surgical procedures should be carefully planned to improve patient quality of life than degrading the same.

## REFERENCE:

1. Makris N, Stamatakis H, Syriopoulos K, Tsiklakis K, van der Stelt PF. Evaluation of the visibility and the course of the mandibular incisive canal and the lingual foramen using cone-beam computed tomography. Clin. Oral Impl. Res. [21], [2010]; [766–77].
2. Ramesh AS, Rijesh K, Sharma A, Prakash R, Kumar A, Karthik. The prevalence of mandibular incisive nerve canal and to evaluate its average location and dimension in Indian population. J Pharm Bioall Sci [2015];[7]: [594-6].
3. Wismeijer D, van Waas MA, Vermeeren JI, Kalk W. Patients' perception of sensory disturbances of the mental nerve before and after

- implant surgery: A prospective study of 110 patients. *Br J Oral Maxillofac Surg* [1997];[35]: [254-9].
4. Hirsch JM, Brånemark PI. Fixture stability and nerve function after transposition and lateralization of the inferior alveolar nerve and fixture installation. *Br J Oral Maxillofac Surg* [1995];[33]:[276-81].
  5. Juodzbaly G, Wang HL, Sabalys G (2010) Anatomy of mandibular vital structures. Part II: mandibular incisive canal, mental foramen and associated neurovascular bundles in relation with dental implantology. *J Oral Maxillofac Res.* doi:10.5037/jomr.[2010].[11][03-07].
  6. Chen Z, Chen D, Tang L, Wang F (2015) Relationship between the position of the mental foramen and the anterior loop of the inferior alveolar nerve as determined by cone beam computed tomography combined with mimics. *J Comput Assist Tomogr* [39]:[86–93].
  7. Jacobs R, Mraiwa N, vanSteenberghe D, Gijbels F, Quirynen M. Appearance, location, course, and morphology of the mandibular incisive canal: an assessment on spiral CT scan. *Dentomaxillofacial Radiology*. [2002];[31]:[322-7].
  8. Kütük N, Demirbaz AE, Gönen ZB, Topan C, Kiliç E, Etö OA, et al. Anterior Mandibular Zone Safe for Implants. *The Journal of Craniofacial Surgery*. [2013];[24]: e[405-8].
  9. Sokhn S, Nasseh I, Noujeim M. Using cone beam computed tomography to determine safe regions for implant placement. *General Dentistry*. [2011];[59]:e[72-7].
  10. Pires CA, Bissada NF, Becker JJ, Kanawati A, Landers MA. Mandibular Incisive Canal: Cone Beam Computed Tomography. *Clinical Implant Dentistry and Related Research*. [2012];[14]:[67-73].
  11. Mardinger O, Chaushu G, Arensburg B, Taicher S, Kaffe I. Anatomic and radiologic course of the mandibular incisive canal. *Surgical and Radiologic Anatomy*. [2000];[22]:[157-61].
  12. FUENTES, R.; ARIAS, A.; BUCCHI, C.; SARAVIA, D. & DIAS, F. Prevalence and morphometric characteristics of the mandibular incisive canal through panoramic radiographs in a Chilean population. *Int. J. Morphol.*, [2017]. [35(3):[931-937].
  13. Mraiwa N, Jacobs R, Moerman P, Lambrichts I, vanSteenberghe D, Quirynen M. Presence and course of the incisive canal in the human mandibular interforaminal region: two-dimensional imaging versus anatomical observations. *Surgical and Radiologic Anatomy*. [2003];[25]:[416-23].
  14. Sahman H, Sekerci AE, Sisman Y, Payveren M. Assessment of the visibility and characteristics of the mandibular incisive canal: cone beam computed tomography versus panoramic radiography. *The International Journal of Oral and Maxillofacial Implants*. [2014];[29]:[71-8].
  15. Al-Ani O, Nambiar P, Ha KO, Ngeow WC. Safe zone for bone harvesting

- from the interforaminal region of the mandible. Clin Oral Implants Res. [2013];[24] Suppl A[100]:[115-21].
16. Apostolakis D, Brown JE. The anterior loop of the inferior alveolar nerve: prevalence, measurement of its length and a recommendation for interforaminal implant installation based on cone beam CT imaging. Clinical Oral Implants Research. [2012];[23]:[1022-30].
  17. Parnia F, Moslehifard E, Hafezeqoran A, Mahboub F, Mojaver-Kahnamoui H. Characteristics of anatomical landmarks in the mandibular interforaminal region: A cone-beam computed tomography study. Medicina Oral Patologia Oral y Cirugia Bucal. [2012];[17]:e[420-5].
  18. Huang H, Liu P, Li X, Pei Z, Yang X, Bai S, et al. Mandibular incisive canal by cone beam CT. Hua Xi Kou Qiang Yi Xue Za Zhi. [2013];[31]:[479-82].
  19. Tepper G, Hofschneider UB, Gahleitner A, Ulm C. Computed tomographic diagnosis and localization of bone canals in the mandibular interforaminal regions for prevention of bleeding complications during implant surgery. The International Journal of Oral & Maxillofacial Implants.[ 2001];[16]:[68-72].
  20. Santos T, Gomes AA, Melo DG, Melo AR, Cavalcante JR, Araújo LG, et al. Evaluation of reliability and reproducibility of linear measurements of cone-beam-computed tomography. Indian Journal of Dental Research. [2012];[23]:[473-8].
  21. Obradovic O., Todorovic L., Pesic V., PejkoVIC B., Vitanovic V. Bulletin du Groupement international pour la Recherche Scientifique en Stomatologie et Odontologie, [1993] ,36[3-4], [109-113].
  22. Uchida Y, Yamashita Y, Goto M, Hanihara T. Measurement of anterior loop length for the mandibular canal and diameter of the mandibular incisive canal to avoid nerve damage when installing endosseous implants in the interforaminal region. Journal of Oral and Maxillofacial Surgery.[ 2007];[67]:[744-50].
  23. Pereira-Maciél, Patrícia, Emerson Tavares-de-Sousa, and Marcelo-Augusto Oliveira-Sales. "The Mandibular Incisive Canal and Its Anatomical Relationships: A Cone Beam Computed Tomography Study." Medicina Oral, Patología Oral y Cirugía Bucal [2015]: [20.6] : e[723–e728].
  24. De Andrade E, Otomo-Corgel J, Pucher J, Ranganath KA, St George N. The intraosseous course of the mandibular incisive nerve in the mandibular symphysis. The International Journal of Periodontics and Restorative Dentistry. [2001];[21]:[591–7].

**TABLES:**

Table 1: Prevalence of mandibular incisive canal

No of CBCT scans evaluated	50(100%)
Incisive canal present bilaterally	46 (92%)
Incisive canal present unilaterally	3 (6%)
Incisive canal not present	1 (2%)

Table2: Values of various dimensions of the mandibular incisive canal (MIC) to various landmarks

Dimensions of the MIC	Mean	Std. Deviation
Length of the incisive canal (origin to apex)	13.7387	5.60709
Diameter of the incisive canal at its origin	1.7650	0.51859
Distance from the origin of incisive canal to baseof the mandible	8.9539	2.53661
Distance from the apex of incisive canal to baseof the mandible	8.8812	1.98977
Distance from the origin of incisive canal tobuccal cortex of the mandible	4.1972	1.24659
Distance from the apex of incisive canal to buccalcortex of the mandible	4.7286	1.31883
Distance from the origin of incisive canal tolingual cortex of the mandible	4.1122	1.01590
Distance from the apex of incisive canal tolingual cortex of the mandible	4.1510	1.07216

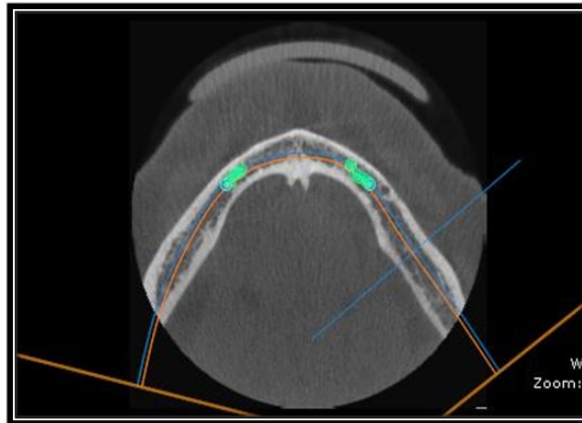
Table3: Comparison between groups of various dimensions of the mandibular incisive canal (MIC) to various landmarks

Dimensions of the incisive nerve	GROUP	N	Mean	Std. Deviation	p value
Length of the incisive canal	RIGHT	46	13.4148	4.67664	.578
	LEFT	44	14.0773	6.47724	
Diameter of the incisive canal at its origin	RIGHT	46	1.6985	0.42293	.215
	LEFT	44	1.8345	0.59980	
Distance from the origin of incisive canal to base of the mandible	RIGHT	46	8.7691	2.86562	.483
	LEFT	44	9.1470	2.15622	
Distance from the apex of incisive canal to base ofthe mandible	RIGHT	46	8.8733	2.16581	.969
	LEFT	44	8.8895	1.81261	
Distance from the origin of incisive canal to buccal cortex of the mandible.	RIGHT	46	4.1443	1.30095	.683
	LEFT	44	4.2525	1.19962	
Distance from the apex of incisive canal to buccal cortex of the mandible	RIGHT	46	4.6243	1.16939	.447
	LEFT	44	4.8375	1.46463	
Distance from the origin of incisive canal to lingual cortex of the mandible	RIGHT	46	4.2035	1.01403	.387
	LEFT	44	4.0168	1.02069	
Distance from the apex of incisive canal to lingual cortex of the mandible	RIGHT	46	4.3998	.11267	.024*

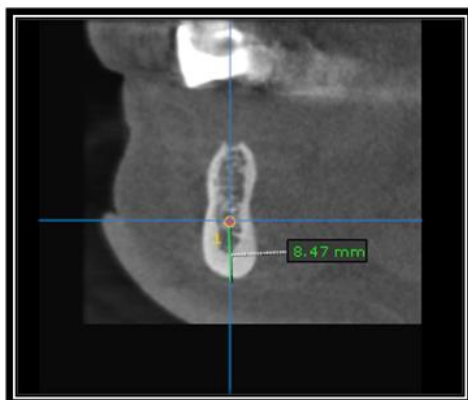


**FIGURES:**

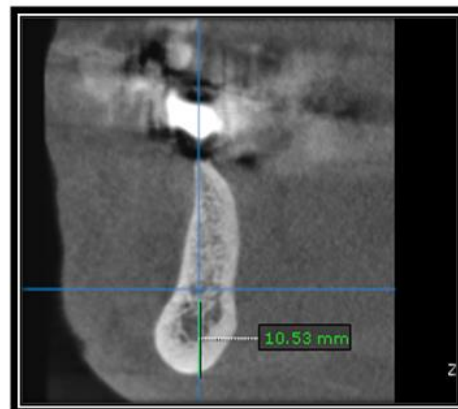
**Figure1:** The nerve tracking done to measure the length of MIC from the origin to apex



**Fig: 2** Distance of incisive canal to base of the mandible both at the (a) Apex and the (b) origin.



**2a**



**2b**

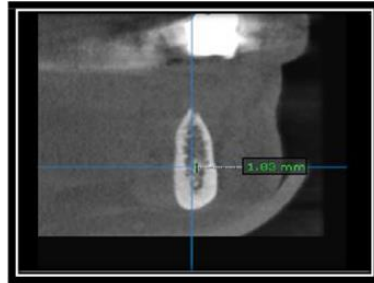
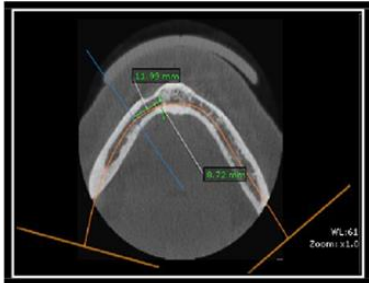


Fig3: Length of the incisive canal (origin to apex) Fig4: Diameter of the MIC at its origin

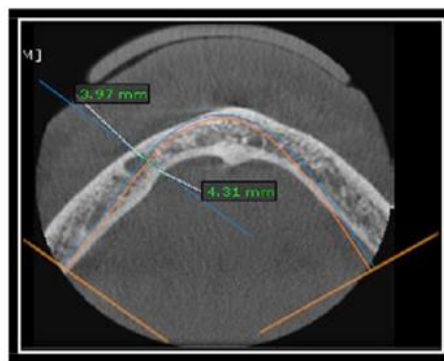
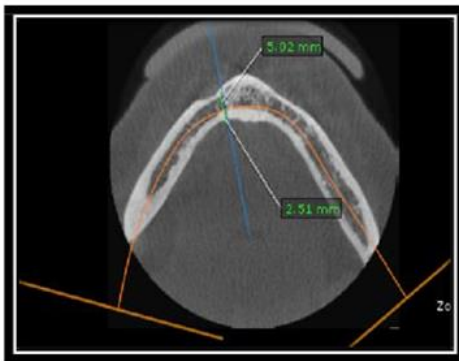


Fig5: Distance of mandibular incisive canal from the buccal and lingual cortices both at the (b) origin and the (a) apex.